

STATE-OF-THE-ART CLINICAL ARTICLE

Brain Abscess**Glenn E. Mathisen and J. Patrick Johnson***From the Infectious Disease Service, UCLA–Olive View Medical Center, Sylmar, and the UCLA Neurosurgery Service, UCLA Center for Health Sciences, Los Angeles, California*

Before the late 1800s, brain abscess was an almost uniformly fatal condition that was rarely diagnosed before autopsy. The pioneering work of the English surgeon William Macewan led to remarkable breakthroughs in the treatment of this condition [1]. With an improved knowledge of cranial surgical anatomy and the development of new surgical techniques, he showed that selected patients could be cured with drainage of the abscess. Further progress was made after World War II, when antibiotics such as penicillin and chloramphenicol were introduced.

Advances in the diagnosis and treatment of brain abscess during the past 20 years have led to continued reductions in the mortality associated with brain abscess. The advent of CT scanning in 1974, the introduction of stereotactic brain biopsy and aspiration techniques, and the availability of newer antimicrobials have all contributed to this improved outlook. During this same period, there have been changes in the epidemiology of this condition, with a decreased incidence of otogenic brain abscess and an increased incidence of brain abscess among organ transplant recipients and other immunocompromised patient populations. The management of brain abscess has become increasingly complicated and requires close cooperation between infectious diseases specialists and neurosurgeons. Herein, we will review key aspects of the clinical presentation of brain abscess as well as recent advances in the diagnosis and treatment of the condition.

Pathophysiology

Brain abscess is a focal, intracerebral infection that begins as a localized area of cerebritis and develops into a collection of pus surrounded by a well-vascularized capsule. A standard method of classifying brain abscesses is to classify them on the basis of the likely entry point of the infection (table 1) [2]. This system allows practitioners to predict the most likely microbial flora in the abscess and select the optimal empirical

antimicrobial therapy. The brain is remarkably resistant to bacterial and fungal infection; brain abscesses in humans are quite uncommon despite the frequency of both overt and occult bacteremia. This resistance is due in part to the brain's abundant blood supply and the relatively impermeable blood-brain barrier formed by the capillary-endothelial tight junctions. A similar situation is seen by researchers working with experimental brain abscess models; induction of an abscess usually requires direct inoculation of organisms into the animal's brain, since brain abscess following experimentally induced bacteremia is rare [3]. Although certain underlying brain pathologies such as previous stroke [4], intracerebral hematoma [5], and an underlying neoplasm [6] may serve as a nidus for abscess formation, in most cases there is no apparent predisposing brain lesion.

The most common source of microbial infection remains direct or indirect cranial infection arising from the paranasal sinuses, middle ear, and teeth. Seeding of the brain presumably occurs via transit of infecting bacteria through the valveless emissary veins that drain these regions and permit either direct or retrograde flow into the venous drainage systems of the brain. Although dental and sinus infections remain an important source of brain abscess, aggressive and widespread therapy of chronic otitis media has led to a corresponding decrease in the incidence of otogenic-related temporal lobe and cerebellar brain abscess. Entry of bacteria into the brain following penetrating brain injury is common; however, the likelihood of brain abscess following such injuries is surprisingly low, even when patients are treated with less-aggressive surgical approaches [7]. Metastatic seeding of the brain from distant extracranial sources remains an important route of infection; the microbial pathogens in this situation are quite varied and depend on the original source of the bacteremia.

Despite all these potential routes, it should be recognized that 20%–30% of cases are identified as "cryptic" brain abscess for which no obvious source can be identified. In a recent case report, the authors described the rare case of a patient with an echocardiographically proven patent foramen ovale who developed a brain abscess [8]. Perhaps such intracardiac lesions (with occult bacteremia from an abdominal source) account for some of the cryptic cases identified in previous reports, although larger studies would be needed to identify the frequency and clinical relevance of such lesions.

Received 12 May 1997; revised 17 June 1997.

Reprints or correspondence: Dr. Glenn E. Mathisen, Infectious Disease Service, UCLA–Olive View Medical Center, Department of Medicine, Room 2B182, 14445 Olive View Drive, Sylmar, California 91342.

Clinical Infectious Diseases 1997;25:763–81

© 1997 by The University of Chicago. All rights reserved.
1058-4838/97/2504-0001\$03.00

Table 1. Brain abscess in adults: microbiology and antimicrobial therapy.

Source of abscess	Site of abscess	Microbial flora	Antimicrobial therapy* [†]
Paranasal sinus	Frontal lobe	Aerobic streptococci (usually "Streptococcus milleri" group) Anaerobic streptococci <i>Haemophilus</i> species <i>Bacteroides</i> species (non- <i>fragilis</i>) <i>Fusobacterium</i> species	Penicillin + metronidazole or (Cefotaxime + metronidazole [‡])
Otogenic infection	Temporal lobe, cerebellum	<i>Streptococcus</i> species Enterobacteriaceae <i>Bacteroides</i> species (includes <i>B. fragilis</i>) <i>Pseudomonas aeruginosa</i>	Penicillin + metronidazole + ceftazidime
Metastatic spread	Multiple cerebral lesions common, especially in middle cerebral artery distribution, but any lobe can be involved	Depends on source Endocarditis <i>Staphylococcus aureus</i> Viridans streptococci Urinary tract Enterobacteriaceae Pseudomonaceae Intra-abdominal <i>Streptococcus</i> species Enterobacteriaceae Anaerobes Lung abscess <i>Streptococcus</i> species <i>Actinomyces</i> species <i>Fusobacterium</i> species	Nafcillin + metronidazole + cefotaxime
Penetrating trauma	Depends on site of wound	<i>Staphylococcus aureus</i> <i>Clostridium</i> species Enterobacteriaceae	Nafcillin + cefotaxime
Postoperative		<i>Staphylococcus epidermidis</i> <i>Staphylococcus aureus</i> Enterobacteriaceae Pseudomonaceae	Vancomycin + ceftazidime

* Suggested antimicrobial therapy for initial empiric treatment; antibiotic selection will vary depending on clinical situation and culture results.

[†] Recommended antibiotic dosages for a 70-kg patient (dosing may need adjustment in patients with underlying renal or liver disease): penicillin, 2–4 million units iv q4h; metronidazole, 500 mg iv q6h; cefotaxime, 1–2 g iv q4–8h (maximum dose, 12 g/d); ceftazidime, 1–2 g iv q4–8h (maximum dose, 12 g/d); nafcillin, 2 g iv q4h; vancomycin, 1 g iv q12h.

[‡] Demonstrated efficacy in two studies with limited numbers of patients.

Experimental models of brain abscess have increased our understanding of the neuropathology and the clinical evolution of these lesions. With use of CT scanning techniques, a series of stages has been described that parallels the human situation [9]. In the "early cerebritis stage" (days 1–3), direct inoculation of organisms into brain parenchyma leads to a focal area of inflammation and edema. Expansion of the cerebritis and the beginning development of a necrotic central focus are seen in the "late cerebritis stage" (days 4–9). The establishment of a ring-enhancing capsule of well-vascularized tissue with early appearance of peripheral gliosis and/or fibrosis is seen in the "early capsule stage" (days 10–14). Finally, during the "late capsule stage" (beyond day 14), host defenses act to wall off the abscess, and a well-formed capsule develops. Although the mechanisms and timing of these events in humans may be different, findings with use of modern scanning techniques suggest a similar progression, and these insights are

important in subsequent discussions about antimicrobial therapy and the timing (and nature) of surgical intervention.

Clinical Presentation

The clinical presentation of brain abscess is influenced by a number of factors including the size and location of the abscess, the virulence of the infecting organism(s), and the presence of any underlying systemic conditions. In a typical case of pyogenic brain abscess, headache is clearly the most common presenting symptom and is seen in almost all patients who are able to give a history. The nature of the headache has no particular distinguishing features, although it is often characterized by a dull aching that is poorly localized. This initial, somewhat nonspecific presentation accounts for the frequent delays in diagnosis and the difficulty in distinguishing early

brain abscess from more common causes of headache. An extremely severe headache of abrupt onset is less commonly seen and is more likely to be a symptom of acute bacterial meningitis or subarachnoid hemorrhage. Rupture of the brain abscess into the ventricular space is often fatal and presents as sudden worsening of a preexisting headache accompanied by new onset of meningismus [10]. Other signs of increased intracranial pressure (nausea, vomiting, drowsiness, lethargy, and stupor) may occur and suggest an advanced case that requires immediate attention.

A common misconception among physicians concerns the frequency with which fever is found during the initial clinical presentation of brain abscess. In some series fever occurs in <50% of cases, and its absence should not be used to exclude the diagnosis [11, 12]. The presence of focal neurological findings (e.g., hemiparesis, hemisensory deficits, aphasia, and ataxia) depends on the location of the abscess, and these findings are seen in approximately one-third to one-half of cases. Papilledema is present in $\leq 25\%$ of cases and signifies serious intracranial hypertension mandating immediate CT scanning and neurosurgical consultation. Infections of the cranial vault (dental abscess, otitis media, or sinusitis) may be a clue to the underlying diagnosis and should be sought in any suspected case. The infrequency and nonspecific presentation of brain abscess account for the ease with which it may be overlooked. Unfortunately, the prognosis is much poorer for patients who present with significant alterations in mental status, and a high index of suspicion is necessary to recognize the condition as early as possible [13].

Similar to the clinical symptomatology and physical examination findings, there are no laboratory data that are pathognomic of brain abscess. Patients frequently have normal leukocyte counts, and the erythrocyte sedimentation rate—while usually elevated—is sometimes normal. Blood cultures are commonly negative but should be performed, as they may occasionally yield the pathogen. Review of the records of hospitalized patients may uncover evidence of a previous bacteremia or infection that may be responsible for the current brain abscess. Performance of lumbar puncture in patients with brain abscess is potentially dangerous and rarely provides useful clinical information. The risk of brainstem herniation following lumbar puncture in such patients is significant and generally outweighs the benefit of any laboratory information obtained [12]. Examination of CSF usually shows a nonspecific elevated protein level and cell count, but these parameters may be normal; CSF cultures are positive only in rare cases.

Careful culturing of abscess material obtained at the time of surgery provides the best opportunity to make a microbiological diagnosis. When meticulous attention is paid to the proper handling of clinical specimens, the culture yield has approached 100% in some studies [11, 14]. This result is related to improved anaerobic transport techniques and prompt plating of infected material on appropriate culture media [15, 16]. A patient's clinical condition sometimes requires institution of ther-

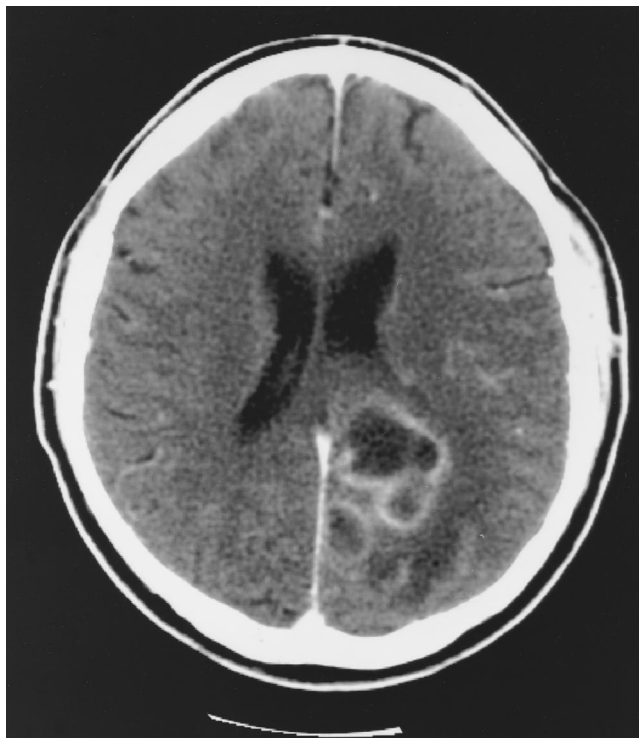

Figure 1. CT scan with intravenous contrast of the brain of a 47-year-old diabetic male who presented with headache and right-sided hemiparesis; an irregular 4.0 \times 5.0-cm ring-enhancing lesion is evident in the left occipital lobe, consistent with a brain abscess.

apy before surgery is performed; however, therapy can often be delayed until diagnostic needle aspiration has been attempted in patients who are clinically stable. Although the incidence of sterile cultures is higher for patients who have already received antimicrobial therapy, any material obtained should still be sent to the laboratory for culture and gram staining. A positive gram stain may help guide therapy even when a culture is negative. Careful attempts to obtain material for culture are important, since a knowledge of the etiologic agent may allow for more thoughtful and targeted antimicrobial therapy.

Imaging Studies

The availability of CT and MRI scanning has clearly revolutionized the diagnosis and management of brain abscess [17, 18]. The use of intravenous iodinated contrast material for CT scanning helps demonstrate lesions not visualized with a noncontrast scan. On a CT scan (figure 1), early cerebritis appears as a focal area of edema (hypodensity) that enhances following injection of intravenous contrast material. Further evolution of the process results in the appearance of the classic ring-enhancing lesion associated with a mature brain abscess. Although such a pattern suggests the development of a peripheral capsule, care should be exercised in overinterpreting the

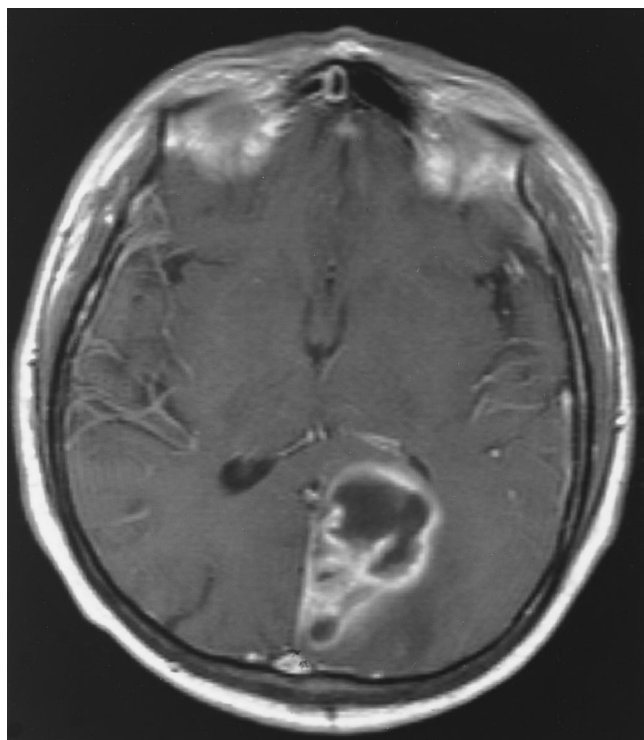


Figure 2. T1-weighted MRI scan of the brain of the patient in figure 1, obtained after administration of an intravenous gadolinium contrast agent; a thin-walled, irregular, septated capsule (with contrast enhancement) with central hypointensity is evident.

scan; such a pattern may also occur in the cerebritis stage, before a significant collection of pus has developed [19]. In cases of suspected cerebritis, a delayed repeated scan (obtained 30–60 minutes later) will often show “filling in” of the central hypodense area by contrast material. This finding suggests that the lesion is still in the cerebritis stage, and a central, necrotic area has yet to develop.

A common problem is the difficulty in differentiating metastatic brain abscess from metastatic tumor lesions [20]. Brain abscesses are frequently located in watershed regions between vascular distributions. These abscesses have hypodense centers surrounded by smooth, regular thin-walled capsules with areas of peripheral enhancement. After injection of intravenous contrast medium, tumors are more likely to appear as areas with irregular borders and diffuse enhancement. Although neuro-radiologists may predict pathology on the basis of scan appearances, brain tumors can completely mimic brain abscess, and pathological confirmation may be required for definitive therapy if uncertainty remains. We have seen patients with radiological diagnoses of “multiple brain metastases” who received radiation therapy and who were later found to have multiple brain abscesses.

MRI scanning demonstrates soft-tissue resolution and imaging detail that are superior to those achieved with CT scanning [18]. On T1-weighted sequences (figure 2), brain ab-

scesses appear hypointense and show ring enhancement following administration of intravenous gadolinium. On T2-weighted sequences, the typical mature brain abscess has a hyperintense central area of pus surrounded by a well-defined hypointense capsule and surrounding edema (figure 3). These features allow staging of the lesion and suggest that a well-developed abscess is more likely to contain purulent material when surgical drainage is attempted. Serial weekly or biweekly CT or MRI scanning provides the necessary information on the response to therapy and aids in the timing of repeated surgery, should it be necessary. Review of the scans with a neuroradiologist and neurosurgeon may provide additional insights into the management of a specific case.

Radionuclide brain scans have been largely replaced by CT and MRI scanning in the diagnosis of brain abscess. Indium-III-labeled leukocyte scanning may allow differentiation of brain abscess from tumor in questionable cases, although tumors may occasionally yield false-positive results [21, 22]. Thallium-201 brain single photon emission computed tomography (SPECT) has shown promising results for differentiating toxoplasma encephalitis from intracerebral lymphoma in patients with AIDS [23]. The usefulness of SPECT scanning for diagnosing pyogenic brain abscess is unclear, since there has been a case report of a false-positive scan for a patient with this condition [24].

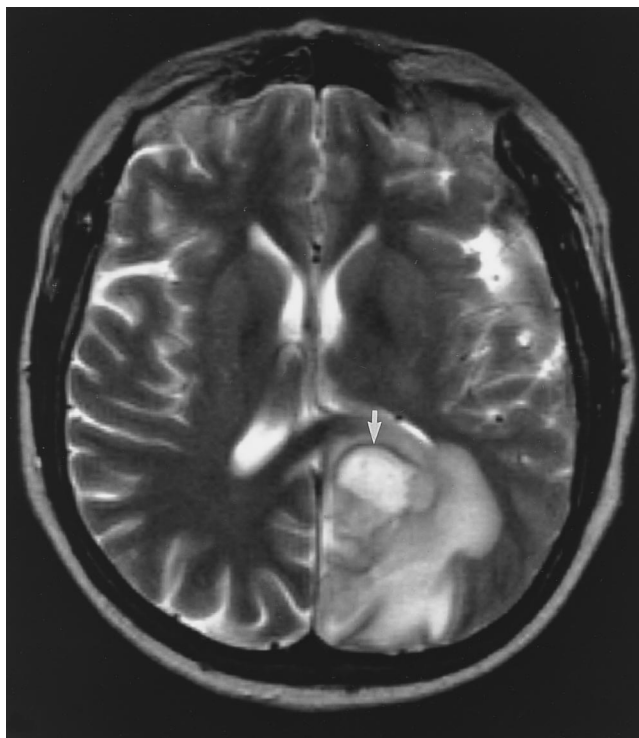


Figure 3. T2-weighted MRI scan of the brain of the patient in figure 1 shows a hyperintense abscess cavity surrounded by a hypointense capsule (arrow) and surrounding edema (hyperintense on scan).

Therapy

The treatment for brain abscess is a team approach, with collaboration between an infectious diseases specialist, neurologist, neuroradiologist, and neurosurgeon. Modern imaging techniques allow early recognition of cerebritis and/or abscess and permit rapid and precise localization of brain lesions that require surgical intervention. Stereotactic needle aspiration permits therapeutic drainage and provides diagnostic specimens for culture and special studies. Empirical antimicrobial therapy can be started on the basis of gram stain results and the presumptive source of the abscess. Serial imaging studies permit monitoring of therapeutic response and identify recurrent or secondary lesions that require repeated drainage. No randomized controlled trials of therapies for brain abscess have been conducted because brain abscesses are relatively uncommon. Despite these limitations, reasonable recommendations regarding therapy can be based on the results of retrospective studies and previous clinical experience.

Antimicrobial therapy. Brain abscesses are frequently polymicrobial, and the most common etiologic organisms in clinical series have been microaerophilic streptococci (viridans streptococci) and anaerobic bacteria [2]. Additional organisms such as *Staphylococcus aureus* and facultative anaerobic gram-negative bacteria (e.g., the Enterobacteriaceae) are also seen, depending on the underlying source (table 1). Initial antibiotic coverage for all these organisms should be considered for critically ill patients. In most cases, attempts to biopsy the lesion to obtain a specimen for culture are essential, since the isolation of pathogenic bacteria allows for more selective antimicrobial therapy. The recommendations in table 1 should be considered guidelines until more definitive microbiological data are available; optimal selection of antimicrobial therapy will often vary depending on the circumstances of individual cases.

Brain abscesses that arise from intracranial extension of sinus infection are usually due to microaerophilic streptococci (e.g., "Streptococcus milleri" group) and anaerobic organisms (e.g., *Bacteroides* species, *Fusobacterium* species, and anaerobic streptococci). In this situation, combination therapy with high-dose penicillin G (10–20 million units per day) and metronidazole is recommended. Some specialists add a third-generation cephalosporin (e.g., cefotaxime) to provide coverage for *Haemophilus* species or rare facultative anaerobic gram-negative bacteria. Brain abscesses associated with a dental procedure or dental abscesses may contain a greater variety of organisms (including *Actinomyces* species) but should respond to similar antimicrobial regimens [25]. When brain abscess arises from an otitic source, coverage for Enterobacteriaceae and *Pseudomonas aeruginosa* should be included because these organisms are sometimes found in brain abscess associated with chronic ear infection. The microbiology of metastatic brain abscess that occurs following bacteremia depends on the original source of the bacteremia. The initial antimicrobial coverage should be chosen with knowledge of the likely pathogens at the suspected site of entry.

The high incidence of *S. aureus* in brain abscesses due to open brain injury merits a brief course of prophylactic antibiotics at the time of the initial surgery [26]. More prolonged therapy may select for more virulent organisms and should not be administered unless a brain abscess is strongly suspected. Infection with facultative gram-negative organisms or *Clostridium* species [27] may also be seen in this situation if the wound has been significantly contaminated with soil at the time of the injury. Brain abscesses associated with neurosurgical procedures are fortunately rare, and when they occur they are usually due to *Staphylococcus epidermidis* [28]. Vancomycin therapy should be part of the initial regimen in such cases until culture results are available.

Appropriate antimicrobial therapy for brain abscess depends on choosing antibiotics that are able to penetrate the abscess cavity and have activity against the suspected pathogens. Although there are considerable data on CSF antimicrobial levels in cases of bacterial meningitis, there is limited information available on antimicrobial penetration into brain abscess cavities. Some studies suggest that the blood-brain barrier is different than the blood-CSF barrier, and reliable predictions of intracavity antimicrobial levels cannot always be made on the basis of CSF levels [29].

Relatively few studies have been done that measure antimicrobial concentrations within brain abscess cavities, and most of these studies contain limited numbers of patients. High-dose penicillin G reaches measurable therapeutic concentrations within brain abscess pus in most situations despite the drug's relatively poor CSF penetration. Although penicillin G is usually effective against susceptible organisms, in some cases it may be inactivated in pus, and bacteria may still be cultured despite adequate drug concentrations [2]. Limited data are available on penetration of the semisynthetic penicillins (e.g., oxacillin and nafcillin) into abscess fluid; however, some studies suggest that levels of these drugs may be variable [30]. At the present time, there are no clinical data that would preclude use of the semisynthetic penicillins in the treatment of brain abscess as long as the pathogenic organism is susceptible.

First-generation cephalosporins (e.g., cefazolin) have relatively poor CNS penetration and are not recommended for the treatment of brain abscess. Although vancomycin generally has poor CSF penetration (CSF levels are <10% of serum levels), in a recent case of *S. aureus* brain abscess, the drug demonstrated excellent penetration into brain abscess fluid (90% of serum levels) following prolonged therapy [31]. Although the presence of a tumor in this case may have increased the penetration of vancomycin into the patient's brain, this report does provide support for vancomycin's use in the treatment of brain abscess.

For many years, chloramphenicol was the standard of therapy for brain abscess because of this drug's antimicrobial spectrum, excellent oral absorption, and good CNS penetration. Although it remains an effective antibiotic for this condition, its lack of bactericidal activity and potential side effects make

it a less attractive agent for first-line therapy. Metronidazole has an excellent pharmacokinetic profile, with good oral absorption and excellent penetration into CSF and brain abscess cavities [32]. Metronidazole's excellent bactericidal activity against strict anaerobes makes it an important component of most antimicrobial regimens for brain abscess. It should be used in combination with an antibiotic active against microaerophilic streptococci (e.g., penicillin), since polymicrobial infection is common in cases of brain abscess, and streptococci and aerotolerant anaerobes are resistant to metronidazole. Since neurotoxic side effects (seizure, somnolence, and peripheral neuropathy) may occasionally occur during therapy with metronidazole, careful attention should be paid to dosing in patients with hepatic failure.

The specific role of the newer antimicrobial agents in the management of brain abscess is evolving, but recent studies suggest that these drugs may be acceptable alternatives in many situations. Third-generation cephalosporins are attractive because of their CSF penetration and their usefulness in the treatment of bacterial meningitis. Cefotaxime is active against many of the bacteria that cause brain abscess, and it penetrates into brain abscess cavities in concentrations greater than the MIC₅₀ for most pathogens [33]. Desacetylcefotaxime, a more lipophilic metabolite of cefotaxime, also has antibacterial activity and accumulates within abscess cavities to an even greater degree than the parent compound. High-dose cefotaxime (3 g given intravenously t.i.d.) has been effective in the treatment of brain abscess when used in combination with metronidazole [34, 35].

Moxalactam has excellent antianaerobic activity and has been found to be efficacious in the treatment of brain abscess in a series of 10 patients who received the drug intravenously (1 g q8h) in conjunction with repeated needle aspirations for therapeutic drainage [36]. Good intra-abscess levels (mean level = 4.18 µg/mL; range = 0–10.9 µg/mL), which increased with repeated administration and more prolonged therapy, were achieved in this study. However, the potential for vitamin K-related bleeding disorders that is associated with high-dose moxalactam therapy may limit the usefulness of this drug for brain abscess.

Ceftazidime has also been used in the treatment of brain abscess, and one trial has demonstrated that this drug has good penetration into abscess cavities, with levels high enough to provide bactericidal activity against most pathogens [37]. Both ceftriaxone and ceftizoxime have been used successfully in the treatment of relatively small numbers of patients; the efficacy of these drugs would be expected to parallel that of cefotaxime, although limited data are available [38]. A study of ampicillin/sulbactam demonstrated therapeutic success in the treatment of 11 patients with brain abscess; intracavitary antimicrobial levels were variable but adequate in most cases [39].

Imipenem has been used successfully in the treatment of both cerebral nocardiosis [40] and pyogenic brain abscess [41, 42]. Because of this drug's reported neurotoxicity [43], its use

for CNS infections should probably be limited to the treatment of brain abscess due to more-resistant pathogens when few other therapeutic options are available. Meropenem is a new carbapenem antimicrobial that is related to imipenem. It has a similar broad antimicrobial spectrum and is reportedly associated with a lower incidence of neurotoxicity. A recent case report documented its use in the successful treatment of an *Enterobacter cloacae* brain abscess in a 7-year-old child with leukemia [44]. Although limited data are available, meropenem's usefulness in the treatment of bacterial meningitis suggests that the drug may play a useful role in therapy for brain abscess, particularly in cases due to more-resistant pathogens [45]. Additional studies are needed before it can be recommended for routine cases.

Quinolones have good CNS penetration and have shown excellent antibacterial activity against gram-negative facultative anaerobes such as Enterobacteriaceae and Pseudomonaceae. A recent case of salmonella brain abscess in an infant who did not respond to treatment with cefotaxime and chloramphenicol was successfully treated with ciprofloxacin [46]. Although quinolones are promising alternatives for the treatment of brain abscess, they should be used with some caution because they can lower seizure thresholds.

Despite the limited clinical experience, the newer antimicrobial agents clearly offer additional options and possibly increased efficacy for the treatment of brain abscess. Recent trends towards increased use of home intravenous antimicrobial therapy and oral antimicrobial therapy will undoubtedly increase the use of some of these agents in the future.

The appropriate duration of antimicrobial therapy for brain abscess remains unclear. A 6–8-week course of parenteral antibiotics has traditionally been recommended, provided that the etiologic organisms are susceptible and adequate surgical drainage can be established. Some investigators believe that in certain situations, shorter courses of treatment may be possible. Sjölin et al. [34] recently suggested that a 3-week course of parenteral therapy may be adequate in some cases. In this study [34], all patients were treated with surgical excision in addition to antimicrobial therapy, and the outcomes for these patients cannot automatically be extrapolated to patients treated with different regimens. Decisions about length of therapy need to be made on a case-by-case basis and depend upon factors such as the antimicrobial susceptibilities of the infecting organism, size of the abscess, adequacy of surgical drainage, and the patient's response to therapy, as determined clinically or radiographically. Pending further clinical studies, in most cases a prolonged course (6–8 weeks) of parenteral antimicrobial therapy is indicated, especially in cases where the adequacy of surgical drainage is unclear.

Although the efficacy and necessity of additional therapy are unclear, many clinicians would recommend an additional 2–3 month course of oral antimicrobial therapy to clear up any "residual" infection and prevent relapse. The antimicrobials selected should have predictable oral absorption and good CSF

penetration, if possible, and selection of the antibiotic(s) should be based on available culture and susceptibility results. Follow-up should include clinical examinations and serial CT or MRI scans (obtained bimonthly or monthly) to document resolution of the abscess. Although most lesions completely disappear when therapy is prolonged, a small area of enhancement on the CT scan may remain despite adequate therapy [17].

There have been a number of more-recent case reports demonstrating successful nonoperative treatment of brain abscess with antibiotics alone [47–49]. This approach may be appropriate for clinically stable patients who are poor candidates for surgery or for patients with surgically inaccessible lesions. Small lesions (<2 cm) located in the better-vascularized cortical areas are more likely to respond to antibiotics alone [50, 51]. The major drawbacks to this approach appear to be the uncertainties (and potential toxicities) involved in prolonged administration of empirical antimicrobial therapy and the possibility of serious clinical deterioration (e.g., intraventricular rupture of the brain abscess) if surgery is delayed. Cases treated in this manner may require more-prolonged parenteral treatment (up to 12 weeks in some cases), and follow-up should include careful clinical and radiographic monitoring. Although selected patients may be candidates for empirical antimicrobial therapy, we believe that an approach that includes diagnostic and therapeutic needle aspiration is more likely to lead to a shorter overall course of treatment.

Surgical procedures: general considerations. The surgical management of pyogenic brain abscesses has evolved significantly in recent decades because of advances in medical therapy and the development of more precise and less-invasive surgical techniques. Surgical treatment of brain abscess previously required open craniotomy and drainage or excision of the lesion [52]. This procedure has largely been replaced by a minimally invasive, closed-drainage procedure performed under local anesthesia and mild sedation (e.g., with midazolam or morphine) and CT scanner guidance [38, 53–55]. Two different techniques of closed-needle biopsy can be performed. Both require CT guidance, but the more precise (1–2-mm accuracy) “stereotactic” procedure requires that a frame be attached to a patient’s head to permit targeting of individual lesions. This procedure necessitates special equipment and requires up to 24 hours to arrange and coordinate.

The “freehand” procedure is performed in the CT scanner by using scalp markers for localization and has an accuracy of 4–5 mm. This biopsy requires common, readily available equipment and can be accomplished on an emergency basis in ~1 hour. Abnormal results of clotting studies and the presence of thrombocytopenia are contraindications to performing a closed brain-biopsy procedure, and these abnormalities must be corrected before any surgical procedure is attempted. Since the majority of brain abscesses occur superficially over the convexities of the hemispheres, a closed, minimally invasive needle biopsy procedure can be effectively performed in many cases.

For the freehand procedure, a preoperative CT scan must be obtained to initially plan localization with the placement of scalp markers over the approximate location of the abscess. A repeated scan obtained with the scalp markers in place allows exact localization of the underlying lesion. The scalp overlying the abscess is prepared sterilely, and a small incision is infiltrated with local anesthetic. A 5-mm incision is made precisely over the abscess, and a twist drill (4–5 mm bore) is used to make a small hole in the cranium, just deep enough to penetrate the dura. A 13-gauge (3-mm bore) Field-Lee brain-biopsy needle is placed through the incision, parallel to the plane of the CT scanner, and advanced a predetermined distance (measured on the CT monitor) into the abscess cavity. The exact position of the biopsy needle in the abscess is confirmed by obtaining a repeated CT scan through the area of interest. The biopsy needle can be repositioned or redirected if necessary.

A liquefied brain abscess under pressure will often drain spontaneously after the biopsy needle stylet is removed; however, some gentle aspiration or saline irrigation may be required to obtain a satisfactory biopsy specimen and to achieve drainage. The risks of hemorrhage or other complications of needle biopsy procedures are generally quite low. Repeated drainage procedures can be performed by using the same techniques if an abscess recurs or a new abscess appears on subsequent CT scans. An advantage of this technique is that the entire procedure can be done in the CT suite within a relatively short period of time without the highly specialized equipment needed for a formal stereotactic procedure in the operating room.

A formal stereotactic biopsy and drainage procedure should be performed for abscesses located in deeper critical regions (e.g., the brainstem, cerebellum, or diencephalic structures adjacent to the ventricle) [38, 52–54]. This type of stereotactic procedure requires considerable planning in advance and specialized equipment. It involves attaching a frame to the patient’s head, and the patient undergoes CT or MRI scanning to acquire the localizing coordinates necessary for computer-generated targeting of the lesion. Patients are usually transferred to the operating room with the head frame in place, and the stereotactic procedure is performed with computerized assistance under the direction of a neurosurgeon. More recently, frameless stereotactic technology has been developed that allows similar CT or MRI targeting of the lesion on the basis of the surface anatomy of the head. This technology eliminates the need for a frame to be attached to patients’ heads [56].

Open craniotomy for therapeutic aspiration or abscess excision requires general anesthesia and is now performed infrequently as a result of the development of the closed drainage and aspiration techniques described above. Complete excision of the abscess and the surrounding capsule appears to be required only in patients with multiloculated abscesses (for whom closed-needle aspiration procedures have failed) or in cases due to more-resistant pathogens (e.g., fungi or *Nocardia* species). Some authors have recommended the placement of drains

into the abscess cavity for postsurgical drainage and antibiotic irrigation [57, 58]; however, this procedure is probably not necessary in most cases, given the current availability of more powerful antimicrobial therapy. Intracavitary administration of antimicrobials may be of value only in patients with large, poorly resolving abscesses that remain culture positive despite the administration of parenteral therapy [57, 59]. Intracavitary amphotericin B may also be of use for the treatment of fungal brain abscess [60].

Recent studies suggest that needle aspiration is as effective as abscess excision in the management of most cases of brain abscess [13, 55, 61]. In the modern era, most patients can be treated initially with closed-needle aspiration, and surgical excision can be reserved for abscesses that fail to resolve or that are caused by resistant pathogens.

The availability of CT scanning and modern stereotactic techniques has greatly enhanced the detection of multiple brain abscesses [50, 51]. In the era before the advent of CT scanning, this condition was associated with high mortality and frequently remained unrecognized until autopsy. More-recent studies suggest that survival rates for patients with multiple abscesses are similar to those for patients with single abscesses [51]. Although modern stereotactic techniques permit greater surgical access to brain abscesses, it may not be feasible to drain all lesions, and successful therapy may depend on the resolution of multiple lesions with antimicrobial therapy alone.

Antimicrobial treatment of small or inaccessible abscesses is more likely to be successful if the identity of the pathogen(s) has been determined after diagnostic needle aspiration of a larger, more-accessible lesion has been performed. Mamelak et al. [51] recommend needle aspiration of all large lesions (those >2.5 cm) and prolonged (6–8 weeks) intravenous antimicrobial therapy that is based on culture results obtained at the time of the initial aspiration. Small (<2.0 cm) cortical lesions detected at an early cerebritis stage may respond to antimicrobials alone. Alternatively, deep subcortical white-matter lesions are believed to have a poorer blood supply and more frequently require surgical intervention [50]. Careful follow-up of lesions with serial CT scans (obtained weekly during the initial phase) allows reevaluation of therapy and consideration of further surgical intervention if a patient's condition clinically deteriorates or an abscess enlarges.

Intraventricular rupture of a brain abscess represents a serious complication that is associated with an extremely high (>80%) mortality rate. Treatment is difficult; one group [10] has recommended an aggressive approach that includes open craniotomy with debridement of the abscess cavity. This procedure is followed by placement of a ventriculostomy catheter, which permits external drainage and allows intrathecal administration of antimicrobials. Delays in the diagnosis of brain abscess and failure to initiate timely surgical intervention are risk factors for this complication. Patients who have

large abscesses located close to the ventricular system may benefit from early surgical intervention to prevent intraventricular rupture.

Adjunctive therapy. The use of corticosteroids to control the cerebral edema associated with brain abscess has not been studied in humans in a well-controlled, randomized clinical trial. Studies of the use of corticosteroids in experimental animal models of brain abscess have provided potentially conflicting results. An early study of corticosteroid use in a model of *S. aureus* brain abscess showed that administration of dexamethasone interfered with granulation tissue formation as well as bacterial clearance [62]. A later study showed that the use of corticosteroids tended to reduce the concentration of certain polar antibiotics (e.g., benzylpenicillin) in infected tissue [63]; more-lipophilic antimicrobials (e.g., metronidazole) were not affected by corticosteroid use.

A more recent trial on the effect of dexamethasone in experimentally induced brain abscess showed some delay in collagen deposition (resulting in a thinner abscess wall at 8 days); however, there was no significant adverse effect on ultimate abscess wall thickness, the extent of the inflammatory process, or the overall mortality [64]. Antimicrobials were not administered in this study, making the results regarding the effect of corticosteroids on the efficacy of antimicrobial therapy difficult to interpret. A review of several clinical series showed no significant difference in patient outcome regardless of the use of corticosteroids [12, 13, 65].

Corticosteroids may be beneficial in patients with raised intracranial pressure and potentially life-threatening complications such as impending cerebral herniation. High-dose corticosteroid therapy (e.g., intravenous or oral dexamethasone, given in a dosage of 10 mg q6h) is given initially and is tapered over 3–7 days after the patient's condition stabilizes. A short course of high-dose corticosteroids is generally safe but should probably be reserved for patients with life-threatening cerebral edema or impending cerebral herniation. Prolonged use of corticosteroids should be discouraged, since corticosteroids may decrease antimicrobial penetration or impair clearance of certain pathogens such as *Nocardia* species. Severe brain edema may necessitate the administration of intravenous mannitol and intubation with forced hyperventilation (i.e., maintenance of PCO₂ at 30–35 mm Hg) to treat significant elevations in intracranial pressure. In rare cases, placement of a ventriculostomy catheter for CSF drainage to relieve intracranial pressure may prove lifesaving.

Seizures are frequent complications of brain abscess and may occur in 25%–50% of cases during the initial period of hospitalization. Acute seizures are treated with intravenous lorazepam in 1-mg doses until they stop, and anticonvulsants (e.g., diphenylhydantoin or carbamazepine) are administered to prevent further seizures. For patients with no history of seizures, it is our practice to administer anticonvulsants prophylactically during the early stage of treatment and for a minimum of 3 months after surgery. Whether seizure prophylaxis should

be continued for longer periods is a question that is difficult to answer.

For patients followed up for long periods (≤ 30 years in one study), the incidence of subsequent seizures approached 70% [66]. We currently recommend that patients undergo neurological evaluations several months after antibiotic treatment of the abscess is completed and the symptoms have resolved. If the results of an electroencephalogram are normal, consideration can be given to slow withdrawal of medication, with close observation for the recurrence of seizures. Patients whose electroencephalograms are markedly abnormal should probably continue taking medication indefinitely. These decisions should be made in consultation with a neurologist and neurosurgeon who are observing the patient. Although some authors have suggested that the incidence of seizures is higher among patients who have undergone open craniotomy with abscess excision (rather than needle aspiration), more recent series have demonstrated no clear evidence that either technique of surgical management is more likely to result in long-term seizures [55, 61].

Special Clinical Situations

Cerebellar and brainstem abscesses. Cerebellar abscesses are most commonly associated with chronic ear infection and mastoiditis. Improved treatment of children's ear infections during the past few decades has led to a decreasing incidence of both temporal-lobe and cerebellar abscesses. Although cerebellar abscesses occur most commonly during childhood and early adulthood, some investigators have observed a bimodal distribution of cerebellar abscess, with a second peak in the sixth decade of life [67]. A clinical presentation with classical cerebellar neurological findings (ataxia, nystagmus, and cranial nerve findings) may be seen; however, patients more commonly present with nonspecific symptoms of nausea, vomiting, and headache [67, 68]. Cerebellar abscesses may be poorly visualized on CT scans because of the presence of bony artifacts from temporal bone structures; MRI scanning is more accurate and should be performed for all patients with a suspected posterior fossa lesion.

The appropriate management of cerebellar abscess is slightly controversial. The authors of older studies have recommended posterior fossa craniotomy with total excision of the abscess [68]. In a more recent series, it was suggested that needle aspiration (combined with high-dose intravenous antibiotics) is effective in most cases [67]. The decision about the appropriate surgical approach is often dictated by the presenting symptoms and the rate of progression. The small volume of the posterior fossa raises the concern for cerebellar or brainstem herniation; immediate surgical decompression should be performed for comatose patients or those with signs and symptoms suggestive of brainstem compression.

Brainstem abscesses are rare and have been associated with a high mortality until relatively recent times [49]. Patients are

often afebrile, and neurological signs and symptoms may be more suggestive of tumor or demyelinating disease. The classic findings of a well-defined brainstem syndrome are frequently lacking because the abscess is more likely to extend longitudinally along fiber tracts in the brainstem rather than expand transversely. The microbiology of brainstem abscesses is similar to that of cortical pyogenic abscesses. In countries with a high prevalence of tuberculosis, there is an increased incidence of brainstem abscess due to *Mycobacterium tuberculosis* [69]. This entity is quite rare in developed countries but should be considered in patients from areas where tuberculosis is endemic. Brainstem infection with organisms such as *Listeria monocytogenes* and *Propionibacterium acnes* may produce brainstem encephalitis (rhombencephalitis) that closely mimics a brainstem abscess [70].

MRI scanning is essential for the diagnosis of brainstem abscess because MRI scanning is the best technique for imaging the brainstem and posterior fossa. Stereotactic needle aspiration of a brainstem abscess, followed by prolonged antimicrobial therapy, appears to be the treatment of choice and has resulted in remarkably good clinical outcomes in several reports [54, 71]. Individual case reports of brainstem abscesses treated with prolonged (≤ 12 weeks in some cases) parenteral antimicrobial therapy alone suggest that this approach may also be successful in some patients [49, 72]. Nevertheless, in general we believe that in most cases it is best to identify the pathogen and that surgical drainage should be performed if possible.

Posttraumatic abscess. Brain abscess that develops following head injury is an uncommon complication that is most often seen in patients with open skull fractures or penetrating brain trauma. Brain abscess may rarely be seen in patients who have sustained closed skull fractures, especially those with associated dural tears or those in whom residual intracerebral bone fragments or debris is present [17]. Patients with penetrating brain injury should undergo early operation with thorough wound debridement and closure of dural tears. A brief course of perioperative antibiotics should be given as a prophylactic measure; however, there is no reason to give patients a prolonged course of antimicrobials unless active infection is a serious possibility. With the institution of these measures, the incidence of intracranial infection (meningitis and brain abscess) following head trauma has been surprisingly low.

For the small percentage of patients who develop posttraumatic brain abscess, there is often a significant delay from the time of injury until the abscess is recognized. One study showed a mean interval of 113 days from the time of injury until the diagnosis of brain abscess [26]. This may be related to the difficulty in distinguishing posttraumatic brain edema and necrosis from cerebral infection. In rare cases, the site of brain injury may be seeded from a postcraniotomy infection. *S. aureus* is the most common pathogen recovered from posttraumatic brain abscesses; however, infections due to *S. epidermidis*, gram-negative bacteria (Pseudomonaceae species and

Enterobacteriaceae species) [73], anaerobes [27], and *Nocardia* species [74] may also be recovered. Abscesses that develop following trauma are frequently multiloculated and may contain foreign bodies such as bone fragments, scalp hair, or other debris introduced at the time of injury. These features make it difficult to cure this condition with antimicrobial therapy and needle aspiration alone. Most cases require open craniotomy with abscess excision or debridement to effect a cure [26].

A special type of posttraumatic brain abscess occurs in children who develop frontal lobe abscess following penetrating orbital trauma from pencils or wooden toys. The seriousness of these injuries often goes unrecognized, since healing of the external wound over the eye occurs rapidly, and the possibility of brain injury is initially overlooked [75, 76]. The superior orbital roof is very thin and affords little resistance to a penetrating injury into the frontal lobe. There is a high frequency of subsequent brain abscess because foreign bodies introduced into the wound at the time of injury act as a nidus for infection [77]. Orbital CT scanning will demonstrate orbital fractures that are missed with plain films, and MRI scanning can identify wood fragments not seen with other imaging techniques [78].

Neurosurgical and ophthalmologic consultations should be obtained if a superior orbital fracture is suspected; in such a case, early surgical intervention with wound debridement is indicated to prevent frontal lobe abscess [75]. *S. aureus* is the most common pathogen isolated, and appropriate antimicrobial coverage should include a semisynthetic penicillin or vancomycin.

Brain abscess in children. This is an uncommon problem in pediatrics; however, children under the age of 15 years account for almost 25% of cases in some brain abscess series [79, 80]. The association of temporal-lobe and cerebellar abscesses with chronic otitis media and mastoiditis, discussed previously, is often seen in children. The improved treatment of ear infections in childhood has resulted in a significant decrease in the incidence of otitic brain abscess in developed countries. In addition to drainage of the intracranial abscess, management of these cases usually requires mastoidectomy to prevent recurrence of the intracranial process [81]. Frontal lobe abscess remains an important intracranial complication of acute sinusitis in children [82–84]. For reasons that are unclear, the disease is most commonly seen in male adolescents. Patients present with headache, fever, and, in some cases, alterations in levels of consciousness [85]. A high index of suspicion must be maintained for this condition, since clinical findings are often subtle and routine CT scans may initially be negative [86]. Aggressive surgical management of both brain abscess and sinusitis is necessary. Although sinus surgery may be delayed, experience suggests that early surgery is more likely to prevent relapse of intracranial infection [82–87].

Brain abscess is an uncommon problem in neonates and is only rarely a sequela of bacterial meningitis due to group B streptococci or *Escherichia coli*. Although meningitis due to other facultative gram-negative organisms (e.g., *Citrobacter*

diversus, *Proteus* species, *Serratia marcescens*, or *Enterobacter* species) is infrequent, it is associated with concomitant brain abscess in a high percentage (>75%) of cases [88–90]. The risk of brain abscess is sufficiently increased that children should be evaluated for brain abscess if they develop bacteremia or meningitis with these organisms. This condition has a high associated mortality (>75%), and the majority of survivors have significant long-term intellectual impairment. The management of these cases requires aggressive surgical drainage in addition to antimicrobial therapy.

Cyanotic congenital heart disease (CCHD) is a significant predisposing factor for brain abscess in children and accounts for 6%–50% of cases in published series [91]. The highest incidence of this complication appears to be among children with cardiac defects such as tetralogy of Fallot or transposition of the great vessels; however, any condition resulting in a significant right-to-left shunt appears to increase the risk. Decreased arterial oxygenation and saturation and an increased hemoglobin level (increased blood viscosity) may cause focal areas of brain ischemia that serve as nidi for infection [92]. Despite the presence of significant cyanosis, children below the age of 2 years rarely develop brain abscess. The peak incidence is between 4 years and 7 years of age, although cases of brain abscess may occur in adults with CCHD [93]. The most common organisms isolated are viridans streptococci (microaerophilic *Streptococcus*), anaerobic streptococci, and occasional *Haemophilus* species [91].

Earlier correction of the underlying cardiac defect may reduce the likelihood of developing brain abscess; however, patients who undergo palliative procedures that allow some degree of right-to-left shunt still remain at significant risk until total correction can be performed. The mortality associated with brain abscess in patients with CCHD is quite high (30%–40%), and aggressive therapy with antibiotics and surgical decompression (needle aspiration or excision) should be instituted as early as possible. The trend towards early total correction of congenital heart lesions suggests that brain abscess in these patients will become less common in the future.

Fungal brain abscess. Fungal brain abscess is most commonly seen in immunocompromised patients such as those with diabetes and those receiving corticosteroids or other immunosuppressive therapies [94, 95]. The clinical presentation of brain abscess in immunocompromised patients is different from that of typical pyogenic brain abscesses. Immunocompromised patients have a poor inflammatory response and are less likely to complain of constitutional symptoms or signs such as headache or meningismus. Fever is quite common in these cases, and neurological symptoms may be initially overshadowed by other signs of disseminated fungemia such as pneumonia. Overt neurological findings such as seizure and stroke are also common, and their presence should suggest the possibility of cerebral infection in the patient at risk for such infection.

Lesions in immunocompromised patients detected on CT or MRI scans, are less likely to show enhancement and sur-

rounding vasogenic edema than are similar lesions in noncompromised patients. This lack of ring enhancement on CT scanning is believed to be an indication of an inadequate inflammatory response and a poor prognostic factor [19, 96]. In general, CNS fungal infection in immunocompromised patients is associated with a high mortality rate despite aggressive surgery and antifungal therapy. Nevertheless, early recognition of this infection can lead to successful treatment, particularly if leukocyte counts return to normal or the dosage of immunosuppressive agents can be reduced.

Aspergillus species are the most common cause of fungal brain abscess in transplant recipients and other severely immunosuppressed patients [94, 95, 97]. Although the course of the disease may be subacute or chronic in some cases, CNS aspergillosis is usually characterized by rapid progression and a high mortality rate [98]. Because of the organism's propensity to cause vascular thrombosis, a clinical presentation suggesting ischemia, with evidence of stroke or intracerebral hemorrhage on a CT scan, should suggest the possibility of CNS aspergillosis. These early lesions are easily missed on CT scans because of minimal enhancement, but they should be readily apparent on T2-weighted MRI images. Although the organisms may occasionally be cultured from extracerebral sites, definitive diagnosis usually requires brain biopsy.

Early recognition with surgical debridement and aggressive antifungal therapy may result in survival if the patient's immune system recovers or medical immunosuppression can be modified. Although amphotericin B is the treatment of choice, therapy with combination antifungal agents (e.g., amphotericin B plus flucytosine or amphotericin B plus rifampin) is often recommended on the basis of in vitro synergy data [96]. The standard surgical management of these cases includes open craniotomy with aggressive debridement [61, 96]; however, recent case reports suggest that some individuals may respond to stereotactic drainage alone in combination with high-dose antifungal therapy [99]. The use of newer agents such as liposomal amphotericin B and itraconazole may offer some advantages in treating patients with intracranial aspergillosis, but experience with these regimens is quite limited, and no definitive recommendations can be made at the present time [100].

Candidiasis of the CNS typically presents as meningoencephalitis with diffuse brain microabscesses that are usually too small to be seen on CT or MRI scans. Macroabscesses due to *Candida* species are quite uncommon but may be seen in both transplant recipients [94] and nonimmunocompromised patients who develop intravenous catheter-associated fungemia [101, 102]. Treatment with aggressive surgical debridement and antifungal therapy (e.g., amphotericin B plus flucytosine) may be successful if it is instituted promptly. The role of fluconazole in the management of CNS candidiasis is unclear, but case reports indicate the utility of the drug [103] as well as the potential for the development of fungal resistance and for treatment failure [104].

Mucormycosis is an infection due to fungi of the order Mucorales, including *Mucor* species, *Rhizopus* species, and *Absidia* species, and is typically seen in patients with diabetic ketoacidosis, patients receiving corticosteroids, intravenous drug users, and patients who are severely immunocompromised with prolonged neutropenia [105]. In diabetic patients with rhinocerebral mucormycosis (diabetic ketoacidosis, orbitofacial cellulitis, or nasal eschar), extension of the *Mucor* species from infected sinuses into the vasculature of the cavernous sinus region and frontal lobes typically produces localized cerebral infarcts. A fungal brain abscess or cerebritis is a common complication of this process, especially in patients who survive for any length of time. The presentation of mucormycosis in patients with lymphoma or leukemia may be similar; however, CNS signs may be overshadowed by more widespread pulmonary, cutaneous, or gastrointestinal involvement in these patients [106].

Appropriate therapy for this condition involves radical surgical debridement in addition to aggressive antifungal therapy. In vitro laboratory studies have demonstrated antimicrobial synergy between amphotericin B and rifampin; however, the clinical benefit of combination therapy remains unproven [105]. The mortality associated with this condition remains high, and the chance of survival is best in cases that are recognized early and are treated promptly and aggressively.

Brain abscess following CNS infection with soil-associated fungi may occur in both healthy hosts and immunocompromised patients. *Coccidioides immitis* usually causes chronic meningitis, but brain abscess due to this fungus may be seen in diabetics and other immunocompromised patients [107]. Infection due to both *Blastomyces dermatitidis* [108] and *Histoplasma capsulatum* [109, 110] can present as an isolated brain abscess or as a brain abscess that is part of a systemic infection. Brain abscess following infection with dematiaceous fungi and related species in both healthy and immunocompromised hosts has been well described [111]. Organisms such as *Xylohypha bantiana* (*Cladosporium trichoides*) [112–114], *Fonsecaea pedrosoi* [115] and *Scedosporium apiospermum* (*Pseudallescheria boydii*) [116, 117] typically produce brain abscess following CNS infection. A history of exposure to soil or organic material may be a risk factor for this type of infection. Efforts to obtain tissue for culture and microscopic examination are vital, since some of these organisms (e.g., *P. boydii*) may be resistant to amphotericin B and require alternative antifungal agents.

Multiple fungal pathogens may be seen in the same patient who is immunocompromised. In a recent report of a bone marrow transplant recipient with both CNS and pulmonary findings, the authors described the isolation of multiple pathogens including *F. pedrosoi* in a lung biopsy specimen, *Aspergillus fumigatus* from a nasal swab specimen, and *Emmericella nidulans* from a brain biopsy specimen [118]. Empirical antifungal therapy based on the nasal swab culture results alone may have been misleading, and in cases such as this, efforts

should be made to identify all potential pathogens. When infection due to these organisms presents as a brain abscess, surgical excision and aggressive antifungal therapy are usually required to achieve a cure.

Tuberculosis. *M. tuberculosis* is a rare cause of brain abscess; however, this organism should be considered in patients with disseminated tuberculosis or in individuals from areas where tuberculosis is endemic. Changes in public health policies during the 1970s and the emergence of the AIDS epidemic have led to a resurgence in all forms of CNS tuberculosis, including tuberculomas and tuberculous brain abscess [119–121]. A tuberculoma is not considered a true abscess; it is a focal mass of dense granulomatous inflammatory tissue that contains epithelioid cells and giant cells. A tuberculous brain abscess (TBA) is a focal collection of pus containing abundant acid-fast bacilli (AFB) surrounded by a dense capsule consisting of vascular granulation tissue. This condition is more commonly seen in immunocompromised patients who are unable to mount a granulomatous inflammatory response [122, 123]. Although both conditions may appear similar on CT images, an MRI scan permits differentiation because a TBA typically produces a higher-intensity signal on T2-weighted scans than does a tuberculoma [124, 125].

The possibility of tuberculoma or TBA should be considered for patients with a brain mass who have CSF findings compatible with tuberculous meningitis or for patients who have evidence of extracranial tuberculous disease [126]. In some cases, such patients may have normal CSF findings, and the diagnosis is delayed until a brain biopsy is performed. Monno et al. [127] have suggested the potential value of PCR testing for HIV-infected patients with suspected focal intracranial tuberculosis; PCR assays of CSF were positive for *M. tuberculosis* for all patients, even when CSF findings were otherwise normal [127].

The limited clinical experience with TBA makes definitive recommendations concerning therapy difficult. Some authors recommend early excision of the lesion because the thick, fibrotic capsule of a fully developed TBA hampers catheter drainage [128]. Other reports have suggested that treatment with prolonged antituberculous chemotherapy may be adequate—especially in patients who have relatively early lesions with poorly formed capsules [122]. We recommend initial diagnostic needle aspiration, followed by prolonged (at least 1 year) antituberculous chemotherapy, for patients with suspected TBA. Open surgical excision may be reserved for patients with enlarging mass lesions or for those who fail to respond to antimicrobial therapy alone.

Nocardia brain abscesses. Nocardia brain abscess may occur as an isolated CNS lesion without evidence of extracranial disease or may occur as part of a “disseminated” infection in association with pulmonary or cutaneous diseases [129, 130]. Although cerebral nocardiosis is frequently seen in patients with defects in cell-mediated immunity (e.g., those receiving

corticosteroids or transplant patients), >50% of patients have no apparent predisposing risk factor [131]. The signs and symptoms of cerebral nocardiosis can sometimes be subtle; however, all patients with suspected pulmonary nocardia infection should undergo brain imaging to rule out subclinical CNS disease. The presence of cavitary lung lesions in patients at risk for nocardiosis should prompt aggressive attempts to obtain sputum samples to help confirm the presence of the disease. *Nocardia* species can be difficult to culture, and they grow relatively slowly on conventional media. If nocardiosis is suspected, the laboratory should be notified so that proper measures can be taken to isolate the organism.

The therapy for nocardia infections is difficult because patients frequently lack adequate immunologic defenses and the organism is relatively resistant to many antimicrobials. Oral sulfadiazine (6–12 g/d) remains the treatment of choice for most patients. The combination trimethoprim-sulfamethoxazole (TMP-SMZ) has been shown to have synergistic activity in vitro in some studies and is appropriate therapy if given in adequate doses. Although either of these regimens is recommended as first-line therapy, there have been clear examples of treatment failure with sulfadiazine or TMP-SMZ [132]. Animal models of cerebral nocardiosis have demonstrated the superiority of combination antimicrobial regimens containing imipenem (e.g., imipenem plus TMP-SMZ or imipenem/cefotaxime) over treatment with cefotaxime or TMP-SMZ alone [133, 134]. Case reports have documented the efficacy of several combination regimens, including ceftriaxone/amikacin [135], sulfadiazine/cefotaxime [136], ceftriaxone/minocycline [137], and imipenem/amikacin [40].

Susceptibility testing of *Nocardia* isolates may be helpful in the selection of an effective regimen; however, such testing has not been standardized, and in vitro test results may not always correlate with in vivo results [138]. Mamelak et al. [131] emphasized the high mortality associated with nocardia brain abscess (30% of immunocompromised patients with this infection die) and some of the complexities involved in therapeutic decision making [131]. Although needle aspiration was successful in some cases, these authors found that craniotomy and total excision were usually required for cure—especially for immunocompromised patients or for those with large, multiloculated abscesses. Other reports have documented successful treatment of nocardia brain abscess following treatment with a combination of stereotactic needle aspiration and antimicrobial therapy [136, 139].

Cerebral nocardiosis is associated with a high mortality and a significant incidence of relapse. Therapy with high-dose sulfadiazine or TMP-SMZ is appropriate for most patients, but combination regimens containing imipenem or third-generation cephalosporins should be considered for immunocompromised patients and those for whom therapy appears to be failing. In many cases, needle aspiration or surgical excision is required for cure. Most patients require a prolonged course (≤ 1 year) of oral antimicrobials to prevent relapse of the infection.

Brain abscess in patients with AIDS. HIV testing should be considered for all patients with unexplained cerebral mass lesions. The most common cause of a brain mass in patients with AIDS is toxoplasmosis, and antimicrobial therapy (e.g., pyrimethamine/sulfadiazine or pyrimethamine/clindamycin) should be started pending results of serological testing [140]. Patients who fail to respond to therapy or have negative serologies may still have toxoplasmosis but should be reevaluated for the presence of other infections or CNS neoplasms. In this situation, consideration should be given to performing CT-guided needle aspiration for establishing a definitive diagnosis. Although radiographic patterns may suggest specific pathogens, there is considerable overlap, and it may be difficult to differentiate toxoplasmosis from other pyogenic processes [141].

Patients with AIDS will occasionally develop brain abscess due to the common bacterial pathogens [142, 143]; however, organisms that require some component of cell-mediated immunity for control represent a special problem. Brain abscess due to salmonellosis; *L. monocytogenes* [144], *Nocardia* species [145], tuberculosis [119–121, 123, 125], coccidioidomycosis [107], blastomycosis [146], and histoplasmosis [147] have all been reported in patients with AIDS. Even *Trypanosoma cruzii* (the cause of Chagas' disease) may cause brain abscess in patients with AIDS, particularly those from areas of endemicity such as Latin America [148]. A case of both toxoplasmosis and *M. tuberculosis* brain abscess has been reported [104], emphasizing the possibility of polymicrobial infection in patients with AIDS.

An HIV-infected patient with a focal CNS lesion should receive initial therapy for cerebral toxoplasmosis. Additional antibiotic coverage may be appropriate, depending on the likelihood of other etiologic pathogens and the initial response to antimicrobial therapy. Diagnostic needle aspiration should be considered for patients who do not respond to empirical therapy.

Parasitic brain abscess. *Toxoplasma gondii* is the most common cause of parasitic brain abscess, as has already been discussed in the previous section. Other causes of parasite-associated brain abscess are exceedingly rare in developed countries. Amebic liver abscess may rarely be associated with brain abscess or meningoencephalitis secondary to infection with *Entamoeba histolytica* [149, 150]. Patients usually have positive amebic serologies, but material obtained from the abscess (liver or brain) is often negative for parasites on microscopic examination. A recent case report demonstrated that abscess fluid may be positive for *E. histolytica* by PCR [149]. Although the associated mortality is high, surgical drainage of the abscess, followed by antimicrobial therapy with metronidazole, appears to be the treatment of choice.

Neurocysticercosis, a CNS infection due to the larval form of *Taenia solium*, frequently presents with headache, fever, and focal CNS lesions. The lesions may mimic brain abscess on radiographs; however, the presence of cystic or calcified lesions

on a brain scan, in association with an appropriate exposure history, should allow differentiation of these lesions from pyogenic brain abscess in most cases [151]. Serology (e.g., ELISA) is quite sensitive and fairly specific for this condition and is of additional help in confirming the diagnosis. On rare occasions, parasitic larvae from organisms such as *Strongyloides stercoralis* or *Ascaris lumbricoides* that are migrating through the brain may cause a brain abscess, particularly if the larvae are colonized with intestinal bacteria [152]. Although extremely rare, such a phenomenon may account for some otherwise inexplicable cases [153].

Outcome

The most successful predictor of clinical outcome for patients with brain abscess is the extent of neurological compromise at the time of presentation and diagnosis. The mortality is higher among patients with symptoms of short duration, severe mental status changes, and rapidly progressing neurological impairment [13]. Factors such as the size and number of abscesses may play a role in outcome, but only to the extent of their effect on the initial neurological status. The outcome is poorer and the mortality is higher for immunocompromised patients; this finding reflects the difficulty of treating patients with a severely compromised immune system who are infected with resistant pathogens.

Summary

The past 20 years have seen major advances in the diagnosis and management of brain abscess, with a corresponding improvement in the survival rates. The advances in radiographic scanning, the availability of new antimicrobials, and the development of novel surgical techniques have all contributed to the decreases in associated morbidity and mortality. The relative rarity of brain abscess and the frequent delays in making the diagnosis render this condition a significant challenge for the clinician. A high index of suspicion is required so that effective therapy can be instituted as soon as possible. Close coordination of care between neurosurgeons and infectious diseases specialists is increasingly important in the complicated management of brain abscess. Adequate abscess drainage and appropriate antimicrobial therapy remain the cornerstones of proper treatment of this condition.

References

1. Canale DJ. William Macewen and the treatment of brain abscesses: revisited after one hundred years. *J Neurosurg* 1996;84:133–42.
2. Gortvai P, De Louvois J, Hurley R. The bacteriology and chemotherapy of acute pyogenic brain abscess. *Br J Neurosurg* 1987;1:189–203.
3. Molinari GF, Smith L, Goldstein MN, Satran R. Brain abscess from septic cerebral embolism: an experimental model. *Neurology* 1973;23:1205–10.

4. Chen S-T, Tang L-M, Ro L-S. Brain abscess as a complication of stroke. *Stroke* **1995**;26:696–8.
5. Bert F, Maubec E, Gardye C, Branger C, Lambert-Zechovsky N. Staphylococcal brain abscess following hematogenous seeding of an intracerebral hematoma [letter]. *Eur J Clin Microbiol Infect Dis* **1995**;14:366–7.
6. Shimomura T, Hori S, Kasai N, Tsuruta K, Okada H. Meningioma associated with intratumoral abscess formation—case report. *Neurol Med Chir (Tokyo)* **1994**;34:440–3.
7. Saba MI. Surgical management of missile injuries of the head. In: Schmidek HH, Sweet WH, eds. *Operative neurosurgical techniques*. Vol. 1. 3rd ed. Philadelphia: W.B. Saunders, **1995**:89–104.
8. Dethy S, Manto M, Kentos A, et al. PET findings in a brain abscess associated with a silent atrial septal defect. *Clin Neurol Neurosurg* **1995**;97:349–53.
9. Britt RH, Enzmann DR, Yeager AS. Neuropathological and computerized tomographic findings in experimental brain abscess. *J Neurosurg* **1981**;55:590–603.
10. Zeidman SM, Geisler FH, Olivi A. Intraventricular rupture of a purulent brain abscess: case report. *Neurosurgery* **1995**;36:189–93.
11. Mathisen GE, Meyer RD, George WL, Citron DM, Finegold SM. Brain abscess and cerebritis. *Rev Infect Dis* **1984**;6(suppl 1):S101–6.
12. Chun CH, Johnson JD, Hofstetter M, Raff MJ. Brain abscess—a study of 45 consecutive cases. *Medicine (Baltimore)* **1986**;65:415–31.
13. Seydoux C, Francioli P. Bacterial brain abscesses: factors influencing mortality and sequelae. *Clin Infect Dis* **1992**;15:394–401.
14. De Louvois J, Gortvai P, Hurley R. Bacteriology of abscesses of the central nervous system: a multicentre prospective study. *Br Med J* **1977**;2:981–4.
15. De Louvois J. Bacteriological examination of pus from abscesses of the central nervous system. *J Clin Pathol* **1980**;33:66–71.
16. Edelstein MAC. Laboratory diagnosis of anaerobic infections in humans. In: Finegold SM, ed. *Anaerobic infections in humans*. New York: Academic Press, **1989**:111–35.
17. Whelan MA, Hilal SK. Computed tomography as a guide in the diagnosis and follow-up of brain abscesses. *Radiology* **1980**;135:663–71.
18. Haines AB, Zimmerman RD, Morgello S, et al. MR imaging of brain abscesses. *AJR Am J Roentgenol* **1989**;152:1073–85.
19. Enzmann DR, Britt RH, Yeager AS. Experimental brain abscess evolution: computed tomographic and neuropathologic correlation. *Radiology* **1979**;133:113–22.
20. Coulam CM, Seshul M, Donaldson J. Intracranial ring lesions: can we differentiate by computed tomography? *Invest Radiol* **1980**;15:103–12.
21. Palestro CJ, Swyer AJ, Kim CK, Muzinic M, Goldsmith SJ. Role of indium-111 labeled leukocyte scintigraphy in the diagnosis of intracerebral lesions. *Clin Nucl Med* **1991**;16:305–8.
22. Bellotti C, Aragno MG, Medina M, et al. Differential diagnosis of CT-hypodense cranial lesions with indium-111-oxine-labeled leukocytes. *J Neurosurg* **1986**;64:750–3.
23. Ruiz A, Gaaz WI, Post JD, et al. Use of thallium-201 brain SPECT to differentiate cerebral lymphoma from toxoplasma encephalitis in AIDS patients. *AJNR Am J Neuroradiol* **1994**;15:1885–94.
24. Krishna L, Slizofski WJ, Katsetos CD, et al. Abnormal intracerebral thallium localization in a bacterial brain abscess. *J Nucl Med* **1992**;33:2017–9.
25. Ingham HR, High AS, Kalbag RM, Sengupta RP, Tharagannet D, Selkon JB. Abscess of the frontal lobe of the brain secondary to covert dental sepsis. *Lancet* **1978**;2:497–9.
26. Patir R, Sood S, Bhatia R. Post-traumatic brain abscess: experience of 36 patients. *Br J Neurosurg* **1995**;9:29–35.
27. Domingo Z. Clostridial brain abscesses. *Br J Neurosurg* **1994**;8:691–4.
28. Loftus CM, Biller J. Brain abscess. In: Rengachary SS, Wilkins RH, eds. *Principles of neurosurgery*. London: Wolfe Publishing, **1994**:24–7.
29. Kramer PW, Griffith RS, Campbell RL. Antibiotic penetration of the brain: a comparative study. *J Neurosurgery* **1969**;31:295–302.
30. De Louvois J, Gortvai P, Hurley R. Antibiotic treatment of abscesses of the central nervous system. *Br Med J* **1977**;2:985–7.
31. Levy RM, Gutin PH, Baskin DS, Pons VG. Vancomycin penetration of a brain abscess: case report and review of the literature. *Neurosurgery* **1986**;18:632–6.
32. Ingham HR, Selkon JB. Metronidazole and brain abscess [letter]. *Lancet* **1982**;2:613–4.
33. Sjölin J, Ericksson N, Arneborn P, Cars O. Penetration of cefotaxime and desacetylcefotaxime into brain abscesses in humans. *Antimicrob Agents Chemother* **1991**;35:2606–10.
34. Sjölin J, Lilja A, Eriksson N, Arneborn P, Cars O. Treatment of brain abscess with cefotaxime and metronidazole: prospective study on 15 consecutive patients. *Clin Infect Dis* **1993**;17:857–63.
35. Gómez J, Poza M, Martínez M, Martínez-Lage J, Hernández JL, Valdés M. Use of cefotaxime and metronidazole for treating cerebral abscesses. [letter]. *Clin Infect Dis* **1995**;21:708.
36. Yamamoto M, Jimbo M, Ide M, Tanaka N, Umebara Y, Hagiwara S. Penetration of intravenous antibiotics into brain abscesses. *Neurosurgery* **1993**;33:44–9.
37. Green HT, O'Donoghue MAT, Shaw MDM, Dowling C. Penetration of ceftazidime into intracranial abscess. *J Antimicrob Chemother* **1989**;24:431–6.
38. Skrap M, Melatini A, Vassallo A, Sidoti C. Stereotactic aspiration and drainage of brain abscesses. Experience with 9 cases. *Minim Invasive Neurosurg* **1996**;39:108–12.
39. Akova M, Akalin HE, Korten V, Ozgen T, Erbenig A. Treatment of intracranial abscesses: experience with sulbactam/ampicillin. *J Chemother* **1993**;5:181–5.
40. Krone A, Schaal KP, Brawanski A, Schuknecht B. Nocardial cerebral abscess cured with imipenem/amikacin and enucleation. *Neurosurg Rev* **1989**;12:333–40.
41. Asensi V, Carton JA, Maradona JA, et al. Imipenem therapy of brain abscesses. *Eur J Clin Microbiol Infect Dis* **1996**;15:653–7.
42. Asensi V, Carton JA, Maradona JA, et al. Therapy of brain abscess with imipenem—a safe therapeutic choice? [letter]. *J Antimicrob Chemother* **1996**;37:200–3.
43. Wong VK, Wright HT Jr, Ross LA, Mason WH, Inderlied CB, Kim KS. Imipenem/cilastin treatment of bacterial meningitis in children. *Pediatr Infect Dis J* **1991**;10:122–5.
44. Meis JFGM, Groot-Loonen J, Hoogkamp-Korstanje JAA. A brain abscess due to multiply-resistant *Enterobacter cloacae* successfully treated with meropenem [letter]. *Clin Infect Dis* **1995**;20:1567.
45. Lopez G, Meropenem Study Group. Meropenem versus cefotaxime or ceftriaxone for bacterial meningitis [abstract no 638]. In: Program and abstracts of the 33rd Interscience Conference on Antimicrobial Agents and Chemotherapy (New Orleans). Washington, DC: American Society for Microbiology, **1993**.
46. Wessalowski R, Thomas L, Kivit J, Voit T. Multiple brain abscesses caused by *Salmonella enteritidis* in a neonate: successful treatment with ciprofloxacin. *Pediatr Infect Dis J* **1993**;12:683–8.
47. Boom WH, Tuazon CU. Successful treatment of multiple brain abscesses with antibiotics alone. *Rev Infect Dis* **1985**;7:189–99.
48. Barsom AH, Lewis HC, Cannillo KL. Nonoperative treatment of multiple brain abscesses. *Surg Neurol* **1981**;16:283–7.
49. Carpenter JL. Brain stem abscesses: cure with medical therapy, case report, and review. *Clin Infect Dis* **1994**;18:219–26.
50. Dyste GN, Hitchon PW, Menezes AH, VanGilder JC, Greene GM. Stereotactic surgery in the treatment of multiple brain abscesses. *J Neurosurg* **1988**;69:188–94.
51. Mamelak AN, Mampalam TJ, Obana WG, Rosenblum ML. Improved management of multiple brain abscesses: a combined surgical and medical approach. *Neurosurgery* **1995**;36:76–86.

52. Itakura T, Yokote H, Ozaki F, Itatani K, Hayashi S, Komai N. Stereotactic operation for brain abscess. *Surg Neurol* **1987**;28:196–200.
53. Lunsford LD. Stereotactic drainage of brain abscesses. *Neurol Res* **1987**;9:270–4.
54. Stapleton SR, Bell BA, Uttley D. Stereotactic aspiration of brain abscesses: is this the treatment of choice? *Acta Neurochir (Wien)* **1993**;121:15–9.
55. Mampalam TJ, Rosenblum ML. Trends in the management of bacterial brain abscesses: a review of 102 cases over 17 years. *Neurosurgery* **1988**;23:451–8.
56. Laborde G, Klimek L, Harders A, Gilsbach J. Frameless stereotactic drainage of intracranial abscesses. *Surg Neurol* **1993**;40:16–21.
57. Broggi G, Franzini A, Peluchetti D, Servello D. Treatment of deep brain abscesses by stereotactic implantation of an intracavitary device for evacuation and local application of antibiotics. *Acta Neurochir (Wien)* **1985**;76:94–8.
58. Mahmood A, Abad RM, Updegrove JH. Brain abscess treated by continuous antibiotic perfusion: technical note. *Neurol Res* **1993**;15:63–7.
59. Gentile G, Vagnozzi R, Giuffrè R, Venditti M, Martino P. Instillation of metronidazole into a brain abscess cavity [letter]. *Eur J Clin Microbiol Infect Dis* **1988**;7:582–3.
60. Camarata PJ, Dunn DL, Farney AC, Parker RG, Seljeskog EL. Continual intracavitary administration of amphotericin B as an adjunct in the treatment of aspergillus brain abscess: case report and review of the literature. *Neurosurgery* **1992**;31:575–9.
61. Leys D, Christiaens JL, Derambure P, et al. Management of focal intracranial infections: is medical treatment better than surgery? *J Neurol Neurosurg Psychiatry* **1990**;53:472–5.
62. Quartey GRC, Johnston JA, Rozdilsky B. Decadron in the treatment of cerebral abscess: an experimental study. *J Neurosurg* **1976**;45:301–10.
63. Kourtópoulos H, Holm SE, Norrby SR. The influence of steroids on the penetration of antibiotics into brain tissue and brain abscesses. An experimental study in rats. *J Antimicrob Chemother* **1983**;11:245–9.
64. Schroeder KA, McKeever PE, Schaberg DR, Hoff JT. Effect of dexamethasone on experimental brain abscess. *J Neurosurg* **1987**;66:264–9.
65. Yang, S-Y. Brain abscess: a review of 400 cases. *J Neurosurg* **1981**;55:794–9.
66. Legg NJ, Gupta PC, Scott DF. Epilepsy following cerebral abscess: a clinical and EEG study of 70 patients. *Brain* **1973**;96:259–68.
67. Brydon HL, Hardwidge C. The management of cerebellar abscess since the introduction of CT scanning. *Br J Neurosurg* **1994**;8:447–55.
68. Shaw MDM, Russell JA. Cerebellar abscess: a review of 47 cases. *J Neurol Neurosurg Psychiatry* **1975**;38:429–35.
69. Talamás O, Del Brutto OH, García-Ramos G. Brain-stem tuberculoma: an analysis of 11 patients. *Arch Neurol* **1989**;46:529–35.
70. Hall WA. Infectious lesions of the brain stem. *Neurosurg Clin N Am* **1993**;4:543–51.
71. Rajshekhar V, Chandy MJ. Successful stereotactic management of a large cardiogenic brain stem abscess. *Neurosurgery* **1994**;34:368–71.
72. Fulgham JR, Wijdicks EFM, Wright AJ. Cure of a solitary brainstem abscess with antibiotic therapy: case report. *Neurology* **1996**;46:1451–4.
73. Rish BL, Caveness WF, Dillon JD, Kistler JP, Mohr JP, Weiss GH. Analysis of brain abscess after penetrating craniocerebral injuries in Vietnam. *Neurosurgery* **1981**;9:535–41.
74. Poretz DM, Smith MN, Park CH. Intracranial suppuration secondary to trauma: infection with *Nocardia asteroides*. *JAMA* **1975**;232:730–1.
75. Bank DE, Carolan PL. Cerebral abscess formation following ocular trauma: a hazard associated with common wooden toys. *Pediatr Emerg Care* **1993**;9:285–8.
76. Foy P, Sharr M. Cerebral abscesses in children after pencil-tip injuries. *Lancet* **1980**;2:662–3.
77. Miller, CF II, Brodkey JS, Colombi BJ. The danger of intracranial wood. *Surg Neurol* **1977**;7:95–103.
78. Green BF, Kraft SP, Carter KD, Buncic JR, Nerad JA, Armstrong D. Intraorbital wood: detection by magnetic resonance imaging. *Ophthalmology* **1990**;97:608–11.
79. Woods CR Jr. Brain abscess and other intracranial suppurative complications. *Adv Pediatr Infect Dis* **1995**;10:41–79.
80. Brook I. Brain abscess in children: microbiology and management. *J Child Neurol* **1995**;10:283–8.
81. Singh B, Maharaj TJ. Radical mastoidectomy: its place in otitic intracranial complications. *J Laryngol Otol* **1993**;107:1113–8.
82. Rosenfeld EA, Rowley AH. Infectious intracranial complications of sinusitis, other than meningitis, in children: 12-year review. *Clin Infect Dis* **1994**;18:750–4.
83. Johnson DL, Markle BM, Wiedermann BL, Hanahan L. Treatment of intracranial abscesses associated with sinusitis in children and adolescents. *J Pediatr* **1988**;113:15–23.
84. Yen P-T, Chan S-T, Huang T-S. Brain abscess: with special reference to otolaryngologic sources of infection. *Otolaryngol Head Neck Surg* **1995**;113:15–22.
85. Singh B, Van Dellen J, Ramjetan S, Maharaj TJ. Sinogenic intracranial complications. *J Laryngol Otol* **1995**;109:945–50.
86. Saxton VJ, Boldt DW, Shield LK. Sinusitis and intracranial sepsis: the CT imaging and clinical presentation. *Pediatr Radiol* **1995**;25(suppl 1):S212–7.
87. Hoyt DJ, Fisher SR. Otolaryngologic management of patients with subdural empyema. *Laryngoscope* **1991**;101:20–4.
88. Ries M, Deeg KH, Heining U, Stehr K. Brain abscesses in neonates—report of three cases. *Eur J Pediatr* **1993**;152:745–6.
89. Kline MW. *Citrobacter* meningitis and brain abscess in infancy: epidemiology, pathogenesis, and treatment. *J Pediatr* **1988**;113:430–4.
90. Renier D, Flandin C, Hirsch E, Hirsch J-F. Brain abscesses in neonates: a study of 30 cases. *J Neurosurg* **1988**;69:877–82.
91. Sáez-Llorens XJ, Umaña MA, Odio CM, McCracken GH Jr, Nelson JD. Brain abscess in infants and children. *Pediatr Infect Dis J* **1989**;8:449–58.
92. Fischbein CA, Rosenthal A, Fischer EG, Nadas AS, Welch K. Risk factors for brain abscess in patients with congenital heart disease. *Am J Cardiol* **1974**;34:97–102.
93. Kagawa M, Takeshita M, Yato S, Kitamura K. Brain abscess in congenital cyanotic heart disease. *J Neurosurg* **1983**;58:913–7.
94. Hagensee ME, Bauwens JE, Kjos B, Bowden RA. Brain abscess following marrow transplantation: experience at the Fred Hutchinson Cancer Research Center, 1984–1992. *Clin Infect Dis* **1994**;19:402–8.
95. Hotson JR, Enzmann DR. Neurologic complications of cardiac transplantation. *Neurol Clin* **1988**;6:349–65.
96. Yuh WTC, Nguyen HD, Gao F, et al. Brain parenchymal infection in bone marrow transplantation patients: CT and MR findings. *AJR Am J Roentgenol* **1994**;162:425–30.
97. Green M, Wald ER, Tzakis A, Todo S, Starzl TE. Aspergillosis of the CNS in a pediatric liver transplant recipient: case report and review. *Rev Infect Dis* **1991**;13:653–7.
98. Shuper A, Levitsky HI, Cornblath DR. Early invasive CNS aspergillosis: An easily missed diagnosis. *Neuroradiology* **1991**;33:183–5.
99. Goodman ML, Coffey RJ. Stereotactic drainage of *aspergillus* brain abscess with long-term survival: case report and review. *Neurosurgery* **1989**;24:96–9.
100. Coleman JM, Hogg GC, Rosenfeld JV, Waters KD. Invasive central nervous system aspergillosis: cure with liposomal amphotericin B, itraconazole, and radical surgery—case report and review of the literature. *Neurosurgery* **1995**;36:858–63.
101. Burgert SJ, Classen DC, Burke JP, Blatter DD. Candidal brain abscess associated with vascular invasion: a devastating complication of vascular catheter-related candidemia. *Clin Infect Dis* **1995**;21:202–5.

102. Haruda F, Bergman MA, Headings D. Unrecognized candida brain abscess in infancy: two cases and a review of the literature. *Johns Hopkins Med J* **1980**;147:182–5.
103. Kamitsuka MD, Nugent NA, Conrad PD, Swanson TN. *Candida albicans* brain abscesses in a premature infant treated with amphotericin B, flucytosine and fluconazole. *Pediatr Infect Dis J* **1995**;14:329–31.
104. Epelbaum S, Laurent C, Morin G, Berquin P, Piussan C. Failure of fluconazole treatment in *Candida meningitis* [letter]. *J Pediatr* **1993**;123:168.
105. Sugar AM. Mucormycosis. *Clin Infect Dis* **1992**;14(suppl 1):S126–9.
106. Nussbaum ES, Hall WA. Rhinocerebral mucormycosis: changing patterns of disease. *Surg Neurol* **1994**;41:152–6.
107. Bañuelos AF, Williams PL, Johnson RH, et al. Central nervous system abscesses due to *Coccidioides* species. *Clin Infect Dis* **1996**;22:240–50.
108. Roos KL, Bryan JP, Maggio WW, Jane JA, Scheld WM. Intracranial blastomycosis. *Medicine (Baltimore)* **1987**;66:224–35.
109. Walpole HT, Gregory DW. Cerebral histoplasmosis. *South Med J* **1987**;80:1575–7.
110. Venger BH, Landon G, Rose JE. Solitary histoplasmosis of the thalamus: case report and literature review. *Neurosurgery* **1987**;20:784–7.
111. Sepkowitz K, Armstrong D. Space-occupying fungal lesions infections of the central nervous system. In: Scheld WM, Whitley RJ, Durack DT, eds. *Infections of the Central Nervous System*. New York: Raven, **1991**:741–64.
112. Aldape KD, Fox HS, Roberts JP, Ascher NL, Lake JR, Rowley HA. *Cladosporium trichoides* cerebral phaeohyphomycosis in a liver transplant recipient: report of a case. *Am J Clin Pathol* **1991**;95:499–502.
113. Buxi TBS, Prakash K, Vohra R, Bhatia D. Imaging in phaeohyphomycosis of the brain: case report. *Neuroradiology* **1996**;38:139–41.
114. Dixon DM, Walsh TJ, Merz WG, McGinnis MR. Infections due to *Xylohypha bantiana* (*Cladosporium trichoides*). *Rev Infect Dis* **1989**;11:515–25.
115. Santosh V, Khanna N, Shankar SK, et al. Primary mycotic abscess of the brain caused by *Fonsecaea pedrosoi*: case report. *J Neurosurg* **1995**;82:128–30.
116. Rüchel R, Wilichowski E. Cerebral *Pseudallescheria mycosis* after near-drowning. *Mycoses* **1995**;38:473–5.
117. Kershaw P, Freeman R, Templeton D, et al. *Pseudallescheria boydii* infection of the central nervous system. *Arch Neurol* **1990**;47:468–72.
118. Morris A, Schell WA, McDonagh D, Chaffee S, Perfect JR. Pneumonia due to *Fonsecaea pedrosoi* and cerebral abscesses due to *Emmericella nidulans* in a bone marrow transplant recipient. *Clin Infect Dis* **1995**;21:1346–8.
119. Farrar DJ, Flanigan TP, Gordon NM, Gold RL, Rich JD. Tuberculous brain abscess in a patient with HIV infection: case report and review. *Am J Med* **1997**;102:297–301.
120. Gettler JF, Garner BF. Long-term survival of an AIDS patient with a tuberculous cerebral abscess. *J Natl Med Assoc* **1996**;88:605–6.
121. Velasco-Martínez JJ, Guerrero-Espejo A, Gómez-Mampaso E, Navas-Elorza, García-Ribas G. Tuberculous brain abscess should be considered in HIV/AIDS patients [letter]. *AIDS* **1995**;9:1197–9.
122. Coppes MJ, Olivieri NF, Howes M, Pusic M, Gold R, Richardson SE. Mycobacterial brain abscess possibly due to *Bacille Calmette-Guérin* in an immunocompromised child. *Clin Infect Dis* **1992**;14:662–5.
123. Fischl MA, Pitchenik AE, Spira TJ. Tuberculous brain abscess and *Toxoplasma* encephalitis in a patient with the acquired immunodeficiency syndrome. *JAMA* **1985**;253:3428–30.
124. Gupta RK, Jena A, Sharma A, Guha DK, Khushu S, Gupta AK. MR imaging of intracranial tuberculomas. *J Comput Assist Tomogr* **1988**;12:280–5.
125. Kioumehri F, Dadsetan MR, Rooholamini SA, Au A. Central nervous system tuberculosis: MRI. *Neuroradiology* **1994**;36:93–6.
126. Schutte C-M, Van der Meyden CH, Labuscagne JH, Otto D. Lymph node biopsy as an aid in the diagnosis of intracranial tuberculosis. *Tuber Lung Dis* **1996**;77:285–6.
127. Monno L, Angarano G, Romanelli C, et al. Polymerase chain reaction for non-invasive diagnosis of brain mass lesions caused by *Mycobacterium tuberculosis*: report of five cases in human immunodeficiency virus-positive subjects. *Tuber Lung Dis* **1996**;77:280–4.
128. Ildan F, Gürsoy F, Gül B, Boyar B, Kihic C. Intracranial tuberculous abscess mimicking malignant glioma. *Neurosurg Rev* **1994**;17:317–21.
129. Filice GA, Simpson GL. Management of *Nocardia* infections. *Curr Clin Top Infect Dis* **1984**;5:49–64.
130. Lerner PI. Nocardiosis. *Clin Infect Dis* **1996**;22:891–905.
131. Mamelak AN, Obana WG, Flaherty JF, Rosenblum ML. Nocardial brain abscess: treatment strategies and factors influencing outcome. *Neurosurgery* **1994**;35:622–31.
132. Overkamp D, Waldmann B, Lins T, Lingenföls T, Petersen D, Eggstein M. Successful treatment of brain abscess caused by *Nocardia* in an immunocompromised patient after failure of co-trimoxazole. *Infection* **1992**;20:365–6.
133. Gombert ME, Aulicino TM, duBouchet L, Silverman GE, Sheinbaum WM. Therapy of experimental cerebral nocardiosis with imipenem, amikacin, trimethoprim-sulfamethoxazole, and minocycline. *Antimicrob Agents and Chemother* **1986**;30:270–3.
134. Gombert ME, du Bouchet L, Aulicino TM, Berkowitz LB. Antimicrobial synergism in the therapy of experimental cerebral nocardiosis. *J Antimicrob Chemother* **1989**;24:39–43.
135. Garlando F, Bodmer T, Lee C, Zimmerli W, Pirovino M. Successful treatment of disseminated nocardiosis complicated by cerebral abscess with ceftriaxone and amikacin: case report. *Clin Infect Dis* **1992**;15:1039–40.
136. Jansen C, Frénay HM, Vandertop WP, Visser MR. Intracerebral *Nocardia asteroides* abscess treated by neurosurgical aspiration and combined therapy with sulfadiazine and cefotaxime. *Clin Neurol Neurosurg* **1991**;93:253–5.
137. Kim J, Minamoto GY, Hoy CD, Grieco MH. Presumptive cerebral *Nocardia asteroides* infection in AIDS: treatment with ceftriaxone and minocycline [letter]. *Am J Med* **1991**;90:656–8.
138. Fried J, Hinthorn D, Ralstin J, Gerjarusak P, Liu C. Cure of brain abscess caused by *Nocardia asteroides* resistant to multiple antibiotics. *South Med J* **1988**;81:412–3.
139. Hall WA, Martinez AJ, Dummer JS, Lunsford LD. Nocardial brain abscess: diagnostic and therapeutic use of stereotactic aspiration. *Surg Neurol* **1987**;28:114–8.
140. Luft BJ, Remington JS. Toxoplasmic encephalitis in AIDS. *Clin Infect Dis* **1992**;15:211–22.
141. Walot I, Miller BL, Chang L, Mehringer CM. Neuroimaging findings in patients with AIDS. *Clin Infect Dis* **1996**;22:906–19.
142. Maniglia RJ, Roth T, Blumberg EA. Polymicrobial brain abscess in a patient infected with human immunodeficiency virus. *Clin Infect Dis* **1997**;24:449–51.
143. Rodriguez Barradas MC, Musher DM, Hamill RJ, Dowell M, Bagwell JT, Sanders CV. Unusual manifestations of pneumococcal infection in human immunodeficiency virus-infected individuals: the past revisited. *Clin Infect Dis* **1992**;14:192–9.
144. Patey O, Nedelec C, Emond JP, Mayorga R, N'Go N, Lafaix C. *Listeria monocytogenes* septicemia in an AIDS patient with a brain abscess. *Eur J Clin Microbiol Infect Dis* **1989**;8:746–8.
145. Idemyor V, Cherubin CE. Pleurocerebral *Nocardia* in a patient with human immunodeficiency virus. *Ann Pharmacother* **1992**;26:188–9.
146. Pappas PG, Pottage JC, Powderly WG, et al. Blastomycosis in patients with acquired immunodeficiency syndrome. *Ann Intern Med* **1992**;116:847–53.
147. Anaissie E, Fainstein V, Samo T, Bodey GP, Sarosi GA. Central nervous system histoplasmosis: an unappreciated complication of the acquired immunodeficiency syndrome. *Am J Med* **1988**;84:215–7.

148. Solari A, Saavedra H, Sepúlveda G, et al. Successful treatment of *Trypanosoma cruzi* encephalitis in a patient with hemophilia and AIDS. Clin Infect Dis **1993**;16:255–9.
149. Ohnishi K, Murata M, Kojima H, Takemura N, Tsuchida T, Tachibana H. Brain abscess due to infection with *Entamoeba histolytica*. Am J Trop Med Hyg **1994**;51:180–2.
150. Campbell S. Amebic brain abscess and meningoencephalitis. Semin Neurol **1993**;13:153–60.
151. White AC Jr. Neurocysticercosis: a major cause of neurological disease worldwide. Clin Infect Dis **1997**;24:101–15.
152. Masdeu JC, Tantulavanich S, Gorelick PP, et al. Brain abscess caused by *Strongyloides stercoralis*. Arch Neurol **1982**;39:62–3.
153. Kean BH. One doctor's adventures among the famous and infamous from the jungles of Panama to a Park Avenue practice. New York: Ballantine Books, **1990**:316–26.
- Rosenblum ML, Mampalam TJ, Pons VG. Controversies in the management of brain abscess. In: Little J, ed. Clinical neurosurgery. Baltimore: Williams and Wilkins, **1986**:603–32.
- Swartz MN. Central nervous system infections. In: Finegold SM, ed. Anaerobic infections in humans. San Diego: Academic Press, **1989**:155–212.
- Wispelwey B, Dacey RG, Scheld WM. Brain abscess. In: Scheld WM, Whitley RJ, Durack DT, eds. Infections of the central nervous system. 2nd ed. Philadelphia: Lippincott-Raven, **1997**:463–93.

Additional Reading

- Pauker SG, Kopelman RI. A rewarding pursuit of certainty. N Engl J Med **1993**;329:1103–7.

The “Conflict-of-Interest Policy” of the Office of Continuing Medical Education, UCLA School of Medicine, requires that faculty participating in a CME activity disclose to the audience any relationship with a pharmaceutical or equipment company which might pose a potential, apparent, or real conflict of interest with regard to their contribution to the program. The author reports no conflict of interest.