

## CORRESPONDENCE

**Is Human T-Cell Lymphotropic Virus Type I More Clever than Human Immunodeficiency Virus Type 1?**

SIR—Casseb [1] hypothesizes that human T-cell lymphotropic virus type I (HTLV-I) is “more clever” than human immunodeficiency virus type 1 (HIV-1). One of his reasons is that HTLV-I, unlike HIV-1, has “an exceptionally low capability for causing death in the host.” “Cleverness” is not a biological concept but rather an anthropomorphism. Casseb probably is referring to the biological success of a virus.

The only measure of the success of an organism is Darwinian—that is, successful viruses transmit more copies of their genes to new hosts, and unsuccessful ones transmit fewer (or none, thus dying out completely). As has been pointed out, it is not necessarily in the evolutionary interest of a virus to have low pathogenicity [2]. For example, some arthropod-borne viruses are transmitted more efficiently when their host is debilitated and unable to fend off insect vectors. HIV-1 seems to be particularly successful in transmitting itself to new hosts, although most transmissions probably take place when the host is feeling well. It is probable that host death caused by HIV-1 is merely an unfortunate (from the host's point of view) epiphenomenon, although in fact we do not know if this is the case. HTLV-I may seem “clever” because it does not cause host mortality, but we cannot say that HIV-1 is less “clever” because it often kills its host. HIV-1, however deadly, seems to be remarkably evolutionarily successful at this point in time, and there seems to be no shortage of hosts for the virus to infect in the future.

**Daniel B. Hrdy**

*Division of Infectious and Immunologic Diseases,  
University of California Davis Medical Center,  
Sacramento, California*

**References**

1. Casseb J. Is human T-cell lymphotropic virus type I more clever than human immunodeficiency virus type 1? *Clin Infect Dis* **1998**;27:1309–10.
2. Ewald P. *Evolution of infectious diseases*. New York: Oxford University Press, 1994.

Reprints or correspondence: Dr. Daniel B. Hrdy, 21440 Road 87, Winters, CA 95694.

**Clinical Infectious Diseases** 1999;29:1356

© 1999 by the Infectious Diseases Society of America. All rights reserved.  
1058-4838/1999/2905-0059\$03.00

**Reply**

SIR—Hrdy points out that HIV type 1 (HIV-1) seems to be remarkably successful evolutionarily. This observation is not in disagreement with my published hypothesis [1]. I agree that

viral adaptation in the host is critical for biological success, and it is usually driven by natural selection. However, my point was that human T cell lymphotropic virus type I (HTLV-I) is better adapted to humans than is HIV-1 at this time. The reason is that it is a less pathogenic virus, and so has more time for transmission. Natural viral adaptation is slow and gradual, and in the case of HTLV-I in humans, it has probably taken thousands of years. In contrast, HIV-1 has not had time to adapt; it is thought to have begun infecting humans much more recently, only a few decades ago [2].

During adaptation, the transmission of some genes may contribute to the stability of the host cell, such as happens with the genes *tax/rex* of HTLV-I. Although similar genes are present in HIV-1, this adaptation, which is quite clever, has not been reported in HIV infection [3]. HIV-1 without the *nef* gene is less pathogenic, and the progression of HIV-1 disease seems to be only attenuated [4]. HIV-1 infection has the capacity to develop into the deadly immunosuppression state after 7–14 years, and this length of time seems to be enough to explain the millions of infections worldwide. However, during this time, the virulence of HIV-1 does not decrease, although we may be able to reduce it in the future with the use of new antiretroviral agents.

Ebola virus is a good example of virulence-defeating viral adaptation [5]. Even though Ebola virus infection is the most pathogenic and transmissible viral disease in humans, few cases have been reported. These cases usually appear in short outbreaks that disappear when all the hosts have died. It seems that Ebola virus is a very new pathogen in humans and is not well adapted. If one agrees that evolutionary success is dependent upon adaptation in the host, reliable transmission, and low pathogenicity, then HTLV-I has been more successful than HIV-1.

**Jorge Casseb**

*Emílio Ribas Institute of Infectious Diseases and Laboratory of Immunogenetics and Experimental Transplantation, Medical School at São Paulo University, São Paulo, Brazil*

**References**

1. Casseb J. Is human T-cell lymphotropic virus type I more clever than human immunodeficiency virus type 1? *Clin Infect Dis* **1998**;27:1309–10.
2. Zhu T, Korber BT, Nahmias AJ, Hooper E, Sharp PM, Ho DD. An African HIV-1 sequence from 1959 and implications for the origin of the epidemic. *Nature* **1998**;391:594–5.
3. Kirchhoff F, Greenough TC, Brettler DB, Sullivan JL, Desrosiers RC. Absence of intact *nef* sequences in a long-term survivor with non-progressive HIV-1 infection. *N Engl J Med* **1995**;332:228–32.
4. Learmont JC, Geczy AF, Mills J, et al. Immunologica and virologic status after 14 to 18 years of infection with an attenuated strain of HIV-1. A report from the Sydney Blood Bank Cohort. *N Engl J Med* **1999**;340:1715–22.
5. Peters CJ, LeDuc JW. An introduction to Ebola: the virus and the disease. *Clin Infect Dis* **1999**;29(Suppl 1):S9–16.

Reprints or correspondence: Dr. Jorge Casseb, Avenue Doctor Arnaldo 455, 2d Floor, Room 2345, São Paulo, Brazil 01246-903 (J31@hotmail.com).

**Clinical Infectious Diseases** 1999;29:1356-7

© 1999 by the Infectious Diseases Society of America. All rights reserved.  
1058-4838/1999/2905-0060\$03.00

## Risk of *Candida* Infection from Contaminated Aortic Valve Allografts

SIR—We note the recent case report by Kuehnert et al. [1] of *Candida albicans* endocarditis following the use of an aortic valve allograft. Culture of a tissue specimen from the allograft was positive for *C. albicans* during tissue bank processing, but culture of a sample of the allograft was negative after disinfection in a solution that included amphotericin B and fluconazole. The concentration of these antifungal agents and the temperature and duration of exposure were not reported, since such data are the proprietary information of Cryolife (Marietta, GA). Kuehnert et al. remind us that decontamination processes for allografts may not always be effective. They suggest that processing protocols may need to be standardized in accordance with newer recommendations such as those of Gall and colleagues [2], which allude to discarding valves with fungal contamination at trimming. The editorial response [3] to the report by Kuehnert et al. states the following: "The severity of fungal endocarditis and the lack of efficacy of a disinfection process that involves soaking the valve in an antimicrobial solution containing amphotericin B and fluconazole show the necessity to discard the allograft in case of fungal contamination." Both the case report and the accompanying editorial response tend to favor the practice of the American Association of Tissue Banks, which is to routinely discard valves with positive fungal cultures; however, it must be pointed out that disinfecting solutions used by both the American Association of Tissue Banks and the Prince Charles Hospital [2] do not contain any antifungal agents.

Allograft valves have been used in our hospital since 1962 [4]. Our antimicrobial solution contains one antifungal agent, amphotericin B (at the relatively high concentration of 25 mg/L) [5]. Tissue is exposed to 2 changes of this solution at 4°C for a total of 48 h. Tissue specimens for fungal culture are obtained three times after disinfection: immediately after 48 h of treatment with antimicrobial solution [5]; immediately before cryopreservation, after being kept in antibiotic-free medium for ≤7 days; and after being thawed at the time of grafting. From 1985 to December 1998, we processed 1621 allograft tissues: 1348 aortic valves, 224 pulmonary valves, and 49 sections of aorta. We reviewed our records and found that during this time, 51 allografts with positive predisinfection and negative post-disinfection fungal cultures were grafted into patients. From the 51 fungal culture-positive allografts, 52 fungal isolates were recovered: 29 filamentous fungi (e.g., *Aspergillus* and *Penicil-*

*ium* species) and 23 yeasts (of which 14 were *C. albicans* and 9 were other *Candida* species). There have been 2 cases of fungal endocarditis in Auckland, New Zealand, during this period, but neither case was associated with allograft tissue.

Although our own experience is small (23 patients with previously *Candida*-positive allografts over 13 years), there may be other investigators (e.g., Cryolife) who could provide more extensive data that would allow estimation of the incidence of subsequent candidal endocarditis. It is unlikely that such a complication of allografting would go unreported; therefore, a reasonably accurate estimate should be obtainable.

Our data suggest that amphotericin B is an effective agent for disinfecting allografts contaminated with *Candida* species so that they are suitable for grafting into patients. Although the use of antifungal agents in disinfecting solutions may never guarantee total freedom from risk of subsequent *Candida* endocarditis, it is not our experience that they are "ineffective" in removing fungi from potential allografts. In our situation, unless there is a substantial increase in tissue donation, nonuse of allografts with positive predisinfection fungal cultures will result in the greater use of mechanical and bioprosthetic valves. Before any protocol that involves mandatory discarding of all valves with a positive predisinfection fungal culture is adopted, or indeed recommended, more information on the possible risk of subsequent endocarditis is needed. Only then can this risk be balanced against the use of another valve type.

**Marianne G. Strickett, Lois C. Armiger,  
Arthur J. Morris, and David A. Haydock**

*Departments of Microbiology and Cardiovascular Surgery, Green Lane  
Hospital, Auckland, New Zealand*

## References

1. Kuehnert MJ, Clark E, Lockhart SR, Soll DR, Chia J, Jarvis WR. *Candida albicans* endocarditis associated with a contaminated aortic valve allograft: implications for regulation of allograft processing. *Clin Infect Dis* 1998; 27:688-91.
2. Gall K, Smith S, Willmette C, Wong M, O'Brien M. Allograft heart valve sterilisation: a six-year in-depth analysis of a twenty-five-year experience with low dose antibiotics. *J Thorac Cardiovasc Surg* 1995; 110:680-7.
3. Joly V, Carbon C. Editorial response: unfortunate in vitro selection of resistant *Candida albicans* with severe clinical consequences. *Clin Infect Dis* 1998; 27:692-4.
4. Barratt-Boyes BG, Roche AHG. A review of aortic valve homografts over a six and one-half year period. *Ann Surg* 1969; 170:483-92.
5. Strickett MG, Barratt-Boyes BG, MacCulloch D. Disinfection of human heart valve allografts with antibiotics in low concentration. *Pathology* 1983; 15: 457-62.

Reprints or correspondence: Dr. Arthur Morris, Microbiology Laboratory, Green Lane Hospital, Green Lane West, Auckland, New Zealand (arthurm@ahsl.co.nz).

**Clinical Infectious Diseases** 1999;29:1357

© 1999 by the Infectious Diseases Society of America. All rights reserved.  
1058-4838/1999/2905-0061\$03.00

## Reply

SIR—We thank Strickett et al. for sharing their data concerning disinfection of allograft tissues contaminated with fungal organisms. They have extensive experience with tissue bank processing and report that 51 of 1621 allograft tissues collected and processed from 1985–1998 were found to be positive for fungal organisms (23 for *Candida* species), but after being proven culture-negative on three occasions after disinfection in a solution containing amphotericin B, these allografts were subsequently implanted into patients. Strickett et al. imply that since no episodes of allograft-associated fungal endocarditis were reported from Auckland, New Zealand (the city in which their institution is located) during the 13 years that the data were collected, their disinfection process for these allografts was successful.

We remain concerned about the use of allografts known to have been contaminated with fungal organisms. Disinfection sometimes can be ineffective in removing fungal organisms from allograft tissue and, as our case report illustrates, may result in postimplantation fungal endocarditis caused by a highly resistant organism [1]. The data of Strickett et al. are interesting but raise a number of questions. What is their overall disinfection failure rate? Of the allografts found to be contaminated with fungi after disinfection, how many were culture-positive at each of the occasions when a tissue sample was routinely cultured? What is their procedure when culture of an allograft specimen obtained at the time of grafting turns positive after the time of implantation?

We understand that allograft tissues are a limited and valuable resource and agree that provision of data by tissue bank processing facilities would be helpful to evaluate differences in processing of allograft tissue found to be contaminated with fungal organisms. However, we question the benefit of a policy that advocates the use of disinfected allografts known to have been contaminated with fungal organisms if there is a risk of fungal endocarditis in the recipient when the disinfection process fails. Until sufficient data are available to show that the benefits of such a policy outweigh this risk, we agree with the recommendation of the American Association of Tissue Banks that allograft valves with positive fungal cultures be discarded.

**Matthew J. Kuehnert and William R. Jarvis**  
Hospital Infections Program, Centers for Disease Control  
and Prevention, Atlanta, Georgia

## Reference

1. Kuehnert MJ, Clark E, Lockhart SR, Soll DR, Chia J, Jarvis WR. *Candida albicans* endocarditis associated with a contaminated aortic valve allograft: implications for regulation of allograft processing. Clin Infect Dis 1998; 27:688–91.

Reprints or correspondence: Dr. Matthew J. Kuehnert, Hospital Infections Program, Centers for Disease Control and Prevention, 1600 Clifton Road, Mailstop E-69, Atlanta, GA 30333 (mgk8@cdc.gov).

**Clinical Infectious Diseases** 1999;29:1358

© 1999 by the Infectious Diseases Society of America. All rights reserved.  
1058-4838/1999/2905-0062\$03.00

---

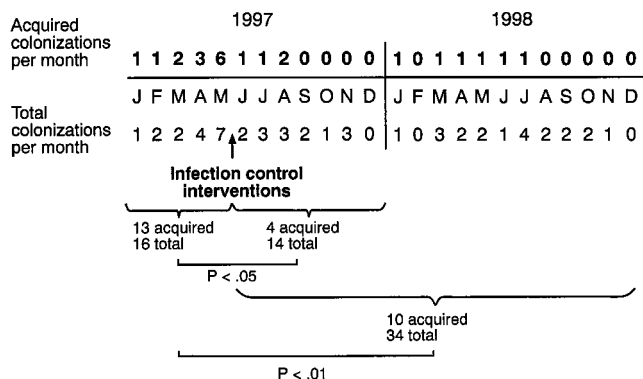
## Computer Keyboards as Reservoirs for *Acinetobacter baumannii* in a Burn Hospital

SIR—In the January 1999 issue of *Clinical Infectious Diseases*, there were 2 articles plus an editorial about *Acinetobacter* [1–3]. One of the articles was from Hong Kong [1], and the other was from Germany [3], thereby indicating the widespread distribution of this increasingly emerging nosocomial pathogen. In one of these articles, Wisplinghoff et al. [3] found that prior nosocomial colonization with *Acinetobacter baumannii* at a distant site was strongly associated with the acquisition of *A. baumannii* bloodstream infections in burn patients; they aptly concluded that their data underscore the need for effective control measures for this emerging nosocomial problem.

In the past few years at our pediatric burn hospital here in the United States, we too have become increasingly aware of the presence of *A. baumannii* and have developed improved control measures because of this microbe. In contrast to the studies from Germany and France, which showed *A. baumannii* was highly endemic in hospitals there, we found the microorganism is not highly endemic in our hospital. Of the 587 acute burn patients admitted to our hospital between January 1996 and December 1998, only 8.3% had cultures of specimens obtained at admission that yielded *Acinetobacter*. Further, our rate of transfer of *A. baumannii* to patients tends to be quite low; specifically, in 1996 and 1998, only 4.2% of our acute burn patients acquired *Acinetobacter* colonization (less than 1 transfer per month).

In the spring of 1997, however, we noticed an increase in the number of acquired *A. baumannii* colonizations in our pediatric burn patients (figure 1). Cultures of environmental specimens showed that *Acinetobacter* was on various surfaces in the patients' rooms, especially on the plastic covers that fit over the bedside computer keyboards. Observation revealed that gloved patient care staff moved back and forth between the patient and the keyboard and that ungloved support staff, who never touched the patient, entered and retrieved data from the same computer. We hypothesized that the ungloved personnel were contaminating the keyboard with *A. baumannii* that was then picked up by the gloved patient care staff who transferred it to the patient. In essence, the keyboard was acting as an *A. baumannii* reservoir, a hypothesis that is consistent with studies showing that *Acinetobacter* species can survive for long periods on dry surfaces [4, 5].

Two control measures were instituted. First, it was required



**Figure 1.** Effect of computer keyboard-related infection control interventions on number of acquired *Acinetobacter baumannii* colonizations in a burn hospital.

that all personnel put on gloves before using the computer and that those gloves be removed before the person left the room, thereby preventing the support staff from contaminating the keyboards with *Acinetobacter* or from carrying the microorganism from one keyboard to another. Historically, these computers were introduced into the patients' rooms in the last half of 1996 and were used increasingly in 1997. At the time of our investigation in early 1997, it was discovered that there were no specific procedures for the disinfection of the plastic covers on the keyboards. Hence, as a second control measure, a defined cleaning procedure for the plastic keyboard covers was provided to the housekeeping staff, and this procedure was followed daily.

These two control measures were initiated at the end of May 1997 with the result that the number of acquired *A. baumannii* colonizations during the last 7 months of 1997 was significantly less ( $P < .05$ ,  $\chi^2$  test) than the number in the first 5 months (figure 1). These control measures have remained in place, and the transfer of this microorganism has remained low (figure 1). Although other factors may have been involved in the 1997 spring outbreak of acinetobacter transfers, the temporal relationship of the introduction of computers at the bedside before the increase in *A. baumannii* transfers and the significant decrease in these transfers once two control parameters relative to keyboard use were instituted strongly suggest that the keyboards were acting as reservoirs for transfer of this microorganism to the patients. It should be noted that, consistent with the findings of the German study [3], two of the acquired colonizations in our patients were associated with blood cultures positive for *A. baumannii*; both of these colonizations were successfully resolved.

This investigation provides an example of how various departments (housekeeping, nursing, support staff, infection control, etc.) need to and can work together to provide the effective control measures that Wisplinghoff et al. [3] so appropriately

recommended at the conclusion of their case-control study of *A. baumannii* bloodstream infections in burn patients.

**Alice N. Neely, Matthew P. Maley,  
and Glenn D. Warden**  
*Shriners Burns Hospitals, Cincinnati, Ohio*

#### References

1. Siau H, Yuen K-Y, Ho P-L, Wong SSY, Woo PCY. *Acinetobacter* bacteremia in Hong Kong: prospective study and review. *Clin Infect Dis* 1999;28:26-30.
2. Seifert H. Editorial response: acinetobacter bacteremia in the tropics. *Clin Infect Dis* 1999;28:31-2.
3. Wisplinghoff H, Perbix W, Seifert H. Risk factors for nosocomial bloodstream infections due to *Acinetobacter baumannii*: a case-control study of adult burn patients. *Clin Infect Dis* 1999;28:59-66.
4. Getchell-White SI, Donowitz LG, Groschel DHM. The inanimate environment of an intensive care unit as a potential source of nosocomial bacteria: evidence for long survival of *Acinetobacter calcoaceticus*. *Infect Control Hosp Epidemiol* 1989;10:402-7.
5. Wendt C, Dietze B, Dietz E, Ruden H. Survival of *Acinetobacter baumannii* on dry surfaces. *J Clin Microbiol* 1997;35:1394-7.

Reprints or correspondence: Dr. Alice N. Neely, Shriners Burns Hospital, 3229 Burnet Avenue, Cincinnati, OH 45229-3095 (anneely@juno.com).

**Clinical Infectious Diseases** 1999;29:1358-9

© 1999 by the Infectious Diseases Society of America. All rights reserved.  
1058-4838/1999/2905-0063\$03.00

#### Reply

**SIR**—Neely et al. add another important inanimate reservoir to the long list of reservoirs that are implicated in the nosocomial transmission of *Acinetobacter baumannii*. This emerging nosocomial pathogen has been found to contaminate medical equipment (such as mechanical ventilator tubings, room humidifiers, pressure monitoring devices, intravascular catheters, and temperature probes) as well as the patient's immediate environment (including pillows, mattresses, and bed rails) [1]. Neely et al. identified computer keyboards as the main reservoir that was responsible for a dramatic increase in *A. baumannii* cross-transmission in a burns hospital. They convincingly demonstrated that targeted infection control measures, including the use of gloves before using the computer and thorough disinfection of the plastic keyboard covers, effectively controlled this outbreak. Their report illustrates that unrecognized contamination of environmental surfaces in the rooms of patients colonized with *A. baumannii* may contribute to nosocomial cross-transmission, in particular, if these surfaces are not included in routine disinfection protocols (such as is the case with computer keyboards). Similarly, during a period of high endemicity in a burns unit, we identified the endemic *A. baumannii* strain on various surfaces in the immediate environment of a patient, including bed linen, a medication table, and the display of an overbed monitor [2].

Boyce and coworkers [3] recently demonstrated the role of

environmental contamination with methicillin-resistant *Staphylococcus aureus* in the epidemiology of this pathogen. They also found that nurses who had no direct contact with affected patients but who touched contaminated inanimate surfaces contaminated their gloves with the endemic methicillin-resistant *S. aureus* strain. Unlike these researchers, Neely and colleagues did not confirm their observations by molecular strain typing to demonstrate the clonal identity of *A. baumannii* recovered from patients and environmental specimens. However, their epidemiological data strongly support their conclusion. Further studies are necessary to establish the levels of contamination with *A. baumannii* as well as the implications of persistence of these organisms on environmental surfaces that are important for patient-to-patient transmission.

**Harald Seifert and Hilmar Wisplinghoff**

*Institute of Medical Microbiology and Hygiene,  
University of Cologne, Cologne, Germany*

**References**

1. Bergogne-Bérézin E, Towner KJ. Acinetobacter spp. as nosocomial pathogens: microbiological, clinical and epidemiological features. Clin Microbiol Rev 1996; 9:148–65.
2. Seifert H, Boullion B, Schulze A, Pulverer G. Plasmid DNA profiles of Acinetobacter baumannii: clinical application in a complex endemic setting. Infect Control Hosp Epidemiol 1994; 15:520–8.
3. Boyce JM, Potter-Bynoe G, Chenevert C, King T. Environmental contamination due to methicillin-resistant Staphylococcus aureus: possible infection control implications. Infect Control Hosp Epidemiol 1997; 18:622–7.

Reprints or correspondence: Dr. Harald Seifert, Institute of Medical Microbiology and Hygiene, University of Cologne, Goldenfelsstrasse 19-21, 50935 Cologne, Germany (harald.seifert@uni-koeln.de).

**Clinical Infectious Diseases** 1999;29:1359–60

© 1999 by the Infectious Diseases Society of America. All rights reserved.  
1058-4838/1999/2905-0064\$03.00

---

**Necrotizing Fasciitis Associated with *Klebsiella pneumoniae* Liver Abscess**

SIR—We read with interest the article by Dylewski and Dylewski [1] that described an Indian patient with necrotizing fasciitis associated with *Klebsiella pneumoniae* liver abscess. Metastatic soft-tissue infections in conjunction with klebsiella liver abscess are rare [2–4]. However, the case reported by Dylewski and Dylewski is not the first reported case of necrotizing fasciitis in association with klebsiella liver abscess. In 1996, Chou and Kou [4] described a Taiwanese patient with *K. pneumoniae* liver abscess in conjunction with endophthalmitis and necrotizing fasciitis. Here we describe two other patients with similar manifestations.

A 71-year-old man with diabetes was admitted to the hospital for evaluation of a 2-week history of fever, chills, and right

upper abdominal pain. He had progressively painful swelling on the left eye 4 days after the onset of fever and a 10-day history of left leg swelling with erythema. Physical examination showed an acutely ill man with a temperature of 37.5°C. His left eye was blind with extensive hypopyon, severe proptosis, and moderate edema and erythema in the eyelid. His left lower leg had marked swelling with induration and severe tenderness. Laboratory studies disclosed the following: initial WBC count,  $13.1 \times 10^9/L$ ; serum glucose level, 203 mg/dL; serum albumin level, 1.8 g/dL; and alkaline phosphatase level, 651 U/L. A CT scan of the abdomen showed an 8-cm intrahepatic abscess, bilateral renal abscesses, and a pancreatic abscess. A presumptive diagnosis of liver abscess with endogenous endophthalmitis was made, and therapy with ceftriaxone was started.

Sonography-guided percutaneous drainage and fasciotomy were performed, and necrotizing fasciitis was observed. Cultures of pus specimens from the liver abscess and left leg both yielded *K. pneumoniae*. The two isolates belonged to capsular serotype K1. On hospital day 11, the left eye was eviscerated and the skin grafted was normalized. The patient was discharged 53 days after admission. He remained free of liver abscess for 1 year of follow-up.

A 40-year-old man with diabetes presented with a 1-week history of fever, chills, nausea, and vomiting and a 3-day history of painful swelling on the left leg. At the time of physical examination, his temperature was 37.9°C. The left leg had marked swelling and severe tenderness. Laboratory studies disclosed the following pertinent values: WBC count,  $28.6 \times 10^9/L$ ; hemoglobin level, 85 g/L; serum glucose level, 313 mg/dL; serum albumin level, 1.7 g/dL; alkaline phosphatase level, 485 U/L; and total bilirubin level, 6.8 mg/dL. A presumptive diagnosis of necrotizing fasciitis was made, and fasciotomy was performed immediately.

Cultures of blood and a left leg wound specimen both yielded *K. pneumoniae*. On the next day, a CT scan of the abdomen showed multiple low-density poorly enhanced nodules in both lobes of the liver and a large subcapsular hematoma in the left kidney. Therapy with parenteral cefazolin and gentamicin was administered for 37 days. He remained asymptomatic during 2 years of follow-up.

Diabetes is an apparent risk factor for klebsiella liver abscess in Taiwan [2–5]. All 4 patients described in the literature who had liver abscess and fasciitis also had diabetes, either for several years or at the time of presentation [1, 4]. It is worth investigating further to determine the relationship between diabetes and klebsiella liver abscess with fasciitis. To our knowledge, this is the first time that *K. pneumoniae* capsular serotype K1 has been reported in conjunction with liver abscess and endophthalmitis.

There are few data on the role of *K. pneumoniae* capsular serotypes in liver abscess and endophthalmitis. Noble et al. [6] had described 1 endogenous endophthalmitis patient due to *Klebsiella aerogenes* serotype K2. In northern Taiwan, *Kleb-*

*siella* serotype K1 is the most common serotype of *Klebsiella* isolates causing bacteremia [7]. We speculate that serotype K1 of *K. pneumoniae* might be the predominant strain causing liver abscess in Taiwan.

**Bor-Shen Hu, Yeu-Jun Lau, Zhi-Yuan Shi,  
and Yu-Hui Lin**

Section of Infectious Diseases, Department of Internal Medicine,  
Taichung Veterans General Hospital, Taichung, Taiwan,  
Republic of China

#### References

1. Dylewski JS, Dylewski I. Necrotizing fasciitis with *klebsiella* liver abscess. Clin Infect Dis **1998**;27:1561–2.
2. Cheng DL, Liu YC, Yen MY, et al. Pyogenic liver abscess: clinical manifestations and value of percutaneous catheter drainage treatment. J Formos Med Assoc **1990**;89:571–6.
3. Chang FY, Chou MY, Fan RL, et al. A clinical study of *Klebsiella* liver abscess. J Formos Med Assoc **1988**;87:282–7.
4. Chou FF, Kou HK. Endogenous endophthalmitis associated with pyogenic hepatic abscess. J Am Coll Surg **1996**;182:33–6.
5. Chou FF, Sheen-Chen SM, Chen YS, et al. The comparison of clinical course and results of treatment between gas-forming and non-gas-forming pyogenic liver abscess. Arch Surg **1995**;130:401–5.
6. Noble CJ, Winch J, Munton CG. Metastatic endophthalmitis [letter]. J Infect **1983**;6:100–1.
7. Peng HL, Wang PY, Wu JL, et al. Molecular epidemiology of *Klebsiella pneumoniae*. Chin J Microbiol Immunol **1991**;24:264–71.

Reprints or correspondence: Dr. Bor-Shen Hu, 160 Taichung Harbor Road Sec. 3, Section of Infectious Diseases, Department of Internal Medicine, Taichung Veterans General Hospital, Taichung, Taiwan, Republic of China (bsh@vghtc.vghtc.gov.tw).

**Clinical Infectious Diseases** 1999;29:1360–1

© 1999 by the Infectious Diseases Society of America. All rights reserved.  
1058-4838/1999/2905-0065\$03.00

#### Reply

SIR—We are pleased to see that additional cases of necrotizing fasciitis in association with *klebsiella* liver abscess are being reported from Taiwan. For the record, our patient acquired his illness in June 1994, and we had tried to have our report published in this and other journals over a period of 3 years. It was only after the review article by Wang et al. [1] that our case report was allowed to be published as a letter. Of note, the article by Chou and Kou [2] was not found in the references listed in the bibliographies done by Dr. Wang and ourselves. A MEDLINE search of the literature using the key words “*klebsiella* liver abscess” and “necrotizing fasciitis” did not turn up the article by Chou and Kou, and even their abstract does not mention necrotizing fasciitis. There are no details given in the report on how the diagnosis was made.

We appreciate Hu et al. pointing out the case reported by Chou and Kou and two new cases of necrotizing fasciitis with

*klebsiella* liver abscess. Fortunately, this association remains a rare occurrence in North America.

**Joe Dylewski and Irving Dylewski**

St. Mary's Hospital, Montreal, Quebec, Canada

#### References

1. Wang J-H, Liu Y-C, Lee SS-J, et al. Primary liver abscess due to *Klebsiella pneumoniae* in Taiwan. Clin Infect Dis **1998**;26:1434–8.
2. Chou FF, Kou HK. Endogenous endophthalmitis associated with pyogenic hepatic abscess. J Am Coll Surg **1996**;182:33–6.

Reprints or correspondence: Dr. Joe Dylewski, St. Mary's Hospital, 3830 La-combe Avenue, Montreal, Quebec H3T 1M5, Canada (joe.dylewski@smhc.qc.ca).

**Clinical Infectious Diseases** 1999;29:1361

© 1999 by the Infectious Diseases Society of America. All rights reserved.  
1058-4838/1999/2905-0066\$03.00

#### Orbital Cellulitis Due to *Streptococcus pneumoniae* in a Previously Healthy Adult

SIR—We read with great interest the brief report of adult pneumococcal cellulitis by Parada and Maslow [1]. The authors stated that “pneumococcal cellulitis was universally associated with bacteremia” and summarized that “pneumococcal skin infections represent 2 distinctive clinical syndromes: facial cellulitis in persons with systemic lupus erythematosus and hematologic disorders and limb cellulitis in persons with diabetes mellitus and substance abuse.” We describe a case of *Streptococcus pneumoniae* orbital cellulitis without bacteremia in a previously healthy adult.

A 77-year-old woman with a medical history of coronary artery disease and hypertension was in her usual state of good health when she started to have a dull aching pain in her left eye while she was playing bridge. She looked in the mirror and noticed mild redness in her left eye. The next day, her left eye was more red with intense pain and more swollen, and the skin below the eye was hard as a rock. The swelling became so severe that the patient had to pull down her lower eyelid to see. The patient denied fever, chills, headache, impairment of vision, nausea, vomiting, or diarrhea. She denied any history of trauma, sinus disease, or insect bite. She presented to the emergency department.

Her temperature was 37.1°C; pulse rate, 80; respiratory rate, 18; and blood pressure, 106/72 mm Hg. There was markedly congested conjunctiva of the left eye with marked indurated swelling of the lower eyelid that extended to the maxillary area. The patient also had difficulty looking outward (lateral gaze) with her left eye. There was purulent discharge from the left eye. The rest of her physical examination was unremarkable. The white blood cell count was  $16.5 \times 10^9/L$  (95% neutrophils). A CT scan of the orbits showed marked soft-tissue swelling

involving the left orbit with no evidence of orbital extension of cellulitis or bony erosive changes. A CT scan of the paranasal sinuses was unremarkable.

The patient was treated with 2 g of intravenous ceftriaxone in the emergency department after blood specimens for cultures were obtained; culture of the purulent eye discharge was also performed. The patient was seen by an ophthalmologist whose diagnosis was left orbital cellulitis with sixth cranial nerve palsy; her vision was 20/30 in both eyes. She was treated with cefazolin (1 g intravenously every 8 h) on the second day of hospitalization; at this time, the patient started to feel better with a mild decrease in her pain and swelling below the eye. The patient's condition continued to improve with a marked decrease in pain and swelling of the left eye, and she had no problem with her lateral gaze. She was discharged on the third day; her medication at discharge was cephalexin, and she recovered uneventfully.

Cultures of blood obtained at admission had no growth. Culture of the left eye drainage yielded moderate growth *S. pneumoniae* resistant to penicillin (MIC, 1.5  $\mu\text{g/mL}$ ) but susceptible to ceftriaxone (MIC, 0.5  $\mu\text{g/mL}$ ) and cefotaxime (MIC, 1.0  $\mu\text{g/mL}$ ). Disk diffusion tests revealed that the *S. pneumoniae* isolate was susceptible to cefazolin, clindamycin, and vancomycin but resistant to erythromycin and tetracycline.

Periorbital cellulitis due to *S. pneumoniae* is known to occur in children [2–4], but *S. pneumoniae* orbital cellulitis with infections of orbital contents marked by proptosis and ophthalmoplegia is rare. DiNubile et al. [5] described a case of *S. pneumoniae* orbital cellulitis of the right eye in an adult with insulin-dependent diabetes mellitus, retinopathy, blindness, and an enucleated right eye. Our patient had no compromising underlying disease and was in a state of good health except for

a history of coronary artery disease and hypertension. Her blood cultures had no growth. Similar to the case reported by DiNubile et al, *S. pneumoniae* was cultured from eye drainage from our patient, and she recovered uneventfully.

The pathogenesis of orbital cellulitis in our patient is not clear. The CT scan of her paranasal sinuses was unremarkable, and she had no documented bacteremia. Furthermore, there was no history of trauma or surgery. Nevertheless, *S. pneumoniae* should be added to the list of organisms capable of causing orbital cellulitis in previously healthy adults.

**Sameh Naseib<sup>1</sup> and Chatrchai Watanakunakorn<sup>1,2</sup>**

<sup>1</sup>Department of Internal Medicine, St. Elizabeth Health Center, Youngstown, and <sup>2</sup>Northeastern Ohio Universities College of Medicine, Rootstown, Ohio

#### References

1. Parada JP, Maslow JN. Adult pneumococcal cellulitis: case report and review. *Clin Infect Dis* **1999**;28:918.
2. Thirumoorthi MC, Asmar BI, Dajani AS. Violaceous discoloration in pneumococcal cellulitis. *Pediatrics* **1978**;62:492–3.
3. Sankrithi LM, Lipuma JJ. Clinically inapparent meningitis complicating periorbital cellulitis. *Pediatr Emerg Care* **1991**;7:28–9.
4. Shapiro ED, Wald ER, Brozanski BA. Periorbital cellulitis and paranasal sinusitis: a reappraisal. *Pediatr Infect Dis* **1982**;1:91–4.
5. DiNubile MJ, Albornoz A, Stumacher RJ, et al. Pneumococcal soft-tissue infections: possible association with connective tissue diseases. *J Infect Dis* **1991**;163:897–900.

Reprints or correspondence: Dr. C. Watanakunakorn, St. Elizabeth Health Center, 1044 Belmont Avenue, P.O. Box 1790, Youngstown, OH 44501-1790.

**Clinical Infectious Diseases** **1999**;29:1361–2

© 1999 by the Infectious Diseases Society of America. All rights reserved.  
1058-4838/1999/2905-0067\$03.00