

Paradoxical Response to Antituberculous Therapy in Infliximab-Treated Patients with Disseminated Tuberculosis

Carolina Garcia Vidal,¹ Serena Rodríguez Fernández,¹ Javier Martínez Lacasa,¹ Miquel Salavert,³ Rafael Vidal,² Mónica Rodríguez Carballeira,¹ and Javier Garau¹

¹Service of Internal Medicine, Hospital Mutua de Terrassa, University of Barcelona, and ²Service of Pneumology, Hospital Vall d'Hebrón, Universitat Autònoma de Barcelona, Barcelona, and ³Infectious Diseases Unit, Hospital La Fe, Valencia, Spain

Six of 284 patients treated with infliximab developed active tuberculosis. Four (67%) of these patients had a paradoxical response to antituberculous therapy. Physicians should be aware of the increased risk of a paradoxical response in this population and should consider the use of corticosteroids when a paradoxical reaction is suspected.

Infliximab is a monoclonal antibody against TNF- α that has been approved for the treatment of patients with autoimmune diseases [1, 2]. A growing number of opportunistic infections have been reported after exposure to this drug [3], the most important of which is tuberculosis (TB). Keane et al. [4] reported 70 cases of TB among 147,000 patients who had received infliximab, for an estimated incidence of 47.6 cases per 100,000 persons in this population.

Clinical deterioration during antituberculous therapy in patients whose cases have initially improved is known as a "paradoxical reaction." Although the association between infliximab exposure and further development of TB is well known, to our knowledge, no cases of paradoxical reaction in patients treated with infliximab and active TB have been reported to date. We describe 4 patients with TB and a paradoxical reaction to anti-TB treatment and offer a plausible explanation for this phenomenon.

Methods. We retrospectively reviewed data from 3 acute-

care referral centers in Spain on all patients who had been treated with infliximab and who had developed active TB during the period 1999–2003. Diagnosis of active TB was made by isolation of *Mycobacterium tuberculosis*. Paradoxical reaction was defined as worsening of preexisting tuberculous lesions or the development of new lesions not attributable to the normal course of disease in a patient whose condition initially improved with antituberculous treatment and in whom paradoxical reaction occurred ≥ 1 month after the initiation of therapy.

Table 1 summarizes the demographic and clinical characteristics of the patients. All patients had an autoimmune disease that was poorly controlled by conventional treatments, which led to treatment with infliximab. None of the patients had a previous history of TB. Additional information is given below, as case reports.

Case reports. Patient 1 started infliximab therapy in February 2002. Two months afterward, she presented with fever, night sweats, and cough. Physical examination revealed left supraclavicular adenopathy. Findings of a chest radiograph were suggestive of miliary disease. A CT scan of the thorax revealed multiple bilateral small nodules in the lung parenchyma. Acid-fast bacilli were observed in a bronchoalveolar lavage fluid specimen. Transbronchial biopsy revealed caseating granulomas. Cultures were positive for *M. tuberculosis*, which was susceptible to all drugs. Infliximab therapy was discontinued, and anti-TB treatment was initiated, with progressive improvement. The patient was readmitted to the hospital 5 weeks later with reappearance of fever and a marked increase in the size of the supraclavicular adenopathy. Surgical excision of the mass was performed. Caseating granulomas were documented, and the results of cultures were negative. After a full 9-month course of treatment, the patient recovered uneventfully.

Patient 2 started infliximab and methotrexate therapy in February 2000. Twenty-four months after the initiation of infliximab therapy (at the 18th dose), fever and night sweats occurred, and the patient was admitted to hospital. Physical examination showed a supraclavicular lymph node. A CT scan of the thorax revealed multiple, bilateral, small pulmonary nodules consistent with miliary TB. The results of sputum smear examinations and cultures were negative. Anti-TB therapy was initiated, and infliximab therapy was stopped. Two months later, the patient presented with a progressive increase in the size of the cervical lymph nodes. She eventually required excision of the lymphadenopathic mass (figure 1). Biopsy revealed caseating granulomas, and cultures yielded *M. tuberculosis* that was susceptible to all drugs. A 9-month course of treatment

Received 14 July 2004; accepted 22 October 2004; electronically published 4 February 2005.

Reprints or correspondence: Dr. Javier Garau, Service of Internal Medicine, Hospital Mutua de Terrassa, Plaza Dr. Robert n° 5, 08221 Terrassa, Barcelona, Spain, (jagarau@terra.es).

Clinical Infectious Diseases 2005;40:756–9

© 2005 by the Infectious Diseases Society of America. All rights reserved.
1058-4838/2005/4005-0020\$15.00

Table 1. Demographic and clinical characteristics of patients with paradoxical reaction (PR) to antituberculosis therapy.

Characteristic	Patient			
	1	2	3	4
Age, years	49	48	56	21
Sex	F	F	M	M
Underlying disease	Rheumatoid arthritis	Rheumatoid arthritis	Ankylosing spondylitis	Crohn disease
PPD test result	Negative	Negative	Negative	Not known
Time between first dose of infliximab and TB diagnosis, months	2	24	2	1
Clinical manifestations of TB	Miliary TB and lymph node disease	Miliary TB and lymph node disease	Pulmonary and pleural TB	Anal TB
TB treatment	Isoniazid, rifampin, pyrazinamide	Isoniazid, rifampin, pyrazinamide, ethambutol	Isoniazid, rifampin, pyrazinamide	Isoniazid, rifampin, pyrazinamide
Time between diagnosis of TB and PR, weeks	5	8	8	16
Clinical manifestation(s) of PR	Progressive swelling of lymph nodes	Progressive swelling of lymph nodes	Progression of infiltrates and pleural effusion	Progressive swelling of inguinal lymph nodes
Microbiologic status of TB at the time of PR				
Biopsy findings	Caseating granulomas	Caseating granulomas	...	Caseating granulomas
Culture results	Negative	<i>Mycobacterium tuberculosis</i> ^a	ND	Negative
Sputum smear findings	AFB	...
Treatment of PR	Surgery	Surgery	Systemic steroid therapy	NSAID
Duration of TB treatment, months	9	9	12	9
Duration of follow-up, months	3	... ^b	26	14

NOTE. AFB, acid-fast bacilli; ND, not done; NSAID, nonsteroid anti-inflammatory drug; TB, tuberculosis.

^a Culture was of a lymph node specimen; the *M. tuberculosis* isolate was susceptible to all drugs.

^b As of 31 January 2005, treatment was ongoing.

was given, with complete resolution of symptoms. Ten months after completion of treatment, without reintroduction of infliximab therapy, the patient presented with fever and abdominal pain. A CT scan showed the presence of an intra-abdominal lymphadenopathic mass. Lymph node biopsy revealed caseating granulomas, and cultures were positive again for *M. tuberculosis*. As of 31 January 2005, anti-TB treatment was still ongoing, and the patient is doing well.

Patient 3 started infliximab therapy in September 2001. Two months later, he was admitted to the hospital because of fever, dyspnea, and cough. The findings of a physical examination were normal. Chest radiography revealed a right-upper lobe infiltrate and bilateral pleural effusions. A sputum smear tested positive for acid-fast bacilli. *M. tuberculosis* that was susceptible to all drugs was recovered from a pleural fluid culture. Anti-TB treatment was initiated, and infliximab therapy was discontinued. Two months later, the patient had a new flare-up of his toxic syndrome, and CT revealed progression of previous infiltrates, a new cavitated infiltrate, and persistent pleural effusions. A sputum smear tested positive for acid-fast bacilli. Treatment with prednisone (1 mg/kg q.d.) was added to his regimen, with an excellent clinical response. Anti-TB treatment was given for 1 year, with complete resolution of TB.

Patient 4 started infliximab therapy in May 2001. Four weeks later, he was admitted to the hospital because of fever and

intersphinteric fistula recurrence. Physical examination revealed fever and an anal ulcer. The results of a PPD test were positive. The findings on a chest radiograph were normal. Acid-fast bacilli were observed in the ulcer exudate. Cultures of the exudate yielded *M. tuberculosis* that was susceptible to all drugs. Anti-TB therapy was initiated, and infliximab therapy was stopped. Four months later, the patient presented with fever, malaise, a persistent anal ulcer, and a progressive increase in the size of the inguinal lymph nodes. Biopsy revealed granulomas, and the results of cultures were negative. The diagnosis of paradoxical reaction was made, and treatment with a nonsteroid anti-inflammatory drug (NSAID) was initiated. The lymphadenopathic mass progressively improved. A 9-month treatment course was completed, and the patient recovered uneventfully.

Results and discussion. During the period of 1999–2003, a total of 284 patients had been exposed to infliximab at acute care centers in the study. During the 42-month period of observation, 6 patients (2.1%) developed active TB. All exhibited unusual clinical manifestations. Paradoxical reaction was observed in 4 (67%) of these patients. The most common clinical presentations were fever, swelling of a preexisting adenopathic node, reappearance of pleural effusion, and occasional occurrence of cavitation of preexisting lung infiltrates. In all cases, no other causes to explain the clinical worsening were found.

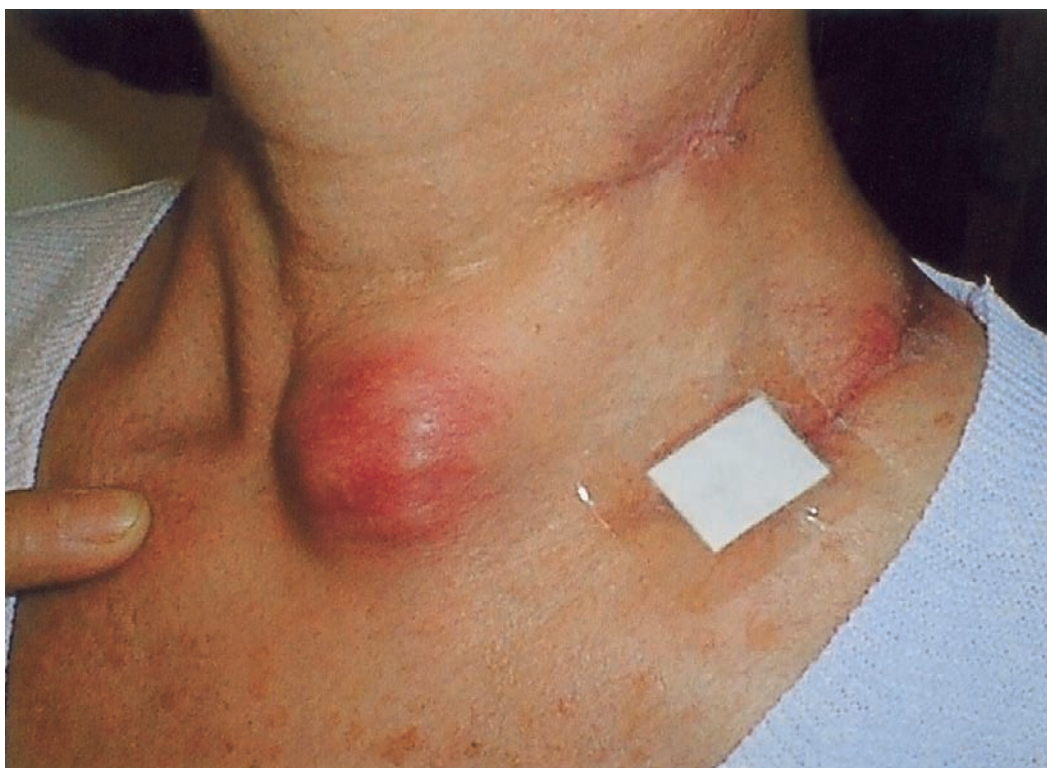


Figure 1. Massive increase in size of the lymphadenopathic mass in patient 2 two months after the initiation of antituberculous treatment

One patient was treated with high-dose steroid therapy, and another was treated with NSAID, with progressive improvement of symptoms. Surgical resection of the adenopathic mass was required for the other 2 patients.

Gardam et al. [5] have estimated that the rate of TB among European recipients of infliximab is 173 cases per 100,000 persons per year. Clinical presentation of TB in this population is usually extrapulmonary and is frequently disseminated, suggesting a poor host response to this infection.

TNF- α is an inflammatory cytokine that plays an essential role in normal immune function. Infliximab binds TNF- α [6], resulting in the loss of the ability by the macrophage to sequester mycobacteria through phagocytosis, with subsequent loss of control of dissemination of the infection, as well as failure in the induction of mycobacterial apoptosis [5]. Another TNF- α -neutralizing agent, etanercept, forms less-stable complexes with TNF receptors, and it is claimed that the development of active TB should be a less common event among etanercept recipients than among those treated with infliximab. In a retrospective analysis of 117,000 patients who were treated with etanercept, 13 (0.01%) developed active TB [7]. The prevalence of preexisting latent TB infection is likely to be an important factor.

Paradoxical reaction during receipt of anti-TB treatment has been well described in HIV-infected patients who initiated antiretroviral treatment concomitantly. It has been proposed that

the paradoxical reaction is the result of an excessive inflammatory response in the context of immune reconstitution and increased antigen exposure after receipt of TB therapy [8, 9]. Paradoxical reaction has been described in up to 35% of these patients and in up to 5% of HIV-uninfected patients [9, 10]. To our knowledge, paradoxical reaction among patients who had been treated with infliximab and who develop active TB infection has not been previously described. Lipoarabinomannan, other proteins, and lipoprotein mycobacterial constituents induce TNF [11, 12], activating the cytokine cascade. Exposure to lipoarabinomannan was postulated as one of the steps in the genesis of paradoxical reaction by Chien and Johnson [8]. Increased exposure to these antigens after TB chemotherapy and immunologic reconstitution secondary to discontinuation of infliximab could be postulated as a genesis of paradoxical reaction, as occurs in HIV-infected patients.

After infliximab therapy is withdrawn, its effects will persist for 3 or 4 weeks, depending on the dose [6]; this could explain the latent period between the initiation of treatment and the development of the paradoxical reaction. Also, deranged baseline immune responses in patients with autoimmune disease could also play a complementary role.

No changes in or discontinuations of anti-TB treatment are necessary when a paradoxical reaction occurs. Early recognition and treatment of this complication with systemic corticosteroid therapy may result in a more favorable outcome [9, 10, 13].

We suggest prolongation of treatment to a period of 9–12 months. In some of our patients, paradoxical reactions were quite dramatic, and surgery was required. Maintenance of low doses of anti-TNF- α and use of steroids or NSAIDs should be considered, because immunologic regulation could be beneficial for these patients.

In summary, with consideration of all of the limitations of a retrospective analysis, our experience suggests that patients who develop TB after infliximab exposure are at increased risk of having a paradoxical reaction. The current policy of discontinuation of the drug should be reevaluated, and consideration should be given to the possibility of continuing infliximab therapy when active TB is controlled.

Acknowledgments

Financial support. Fundació Mutua de Terrassa (grant 067).

Potential conflicts of interest. All authors: no conflicts.

References

1. Keating GM, Perry CM. Infliximab: an updated review of its use in Crohn's disease and rheumatoid arthritis. *BioDrugs* **2002**; 16:111–48.
2. Criscione LG, St Clair EW. Tumor necrosis factor- α antagonists for the treatment of rheumatic diseases. *Curr Opin Rheumatol* **2002**; 14: 204–11.
3. Greenberg S. Infections in the immunocompromised rheumatologic patient. *Crit Care Clin* **2002**; 18:931–56.
4. Keane J, Gershon S, Wise RP, et al. Tuberculosis associated with infliximab, a tumour necrosis factor alpha-neutralizing agent. *N Engl J Med* **2001**; 345:1098–104.
5. Gardam M, Keystone E, Menzies R, et al. Anti-tumour necrosis factor agents and tuberculosis risk: mechanisms of action and clinical management. *Lancet Infect Dis* **2003**; 3:148–55.
6. Markham A, Lamb HM. Infliximab. *Drugs* **2000**; 59:1341–59.
7. Culy C, Keating G. Etanercept. *Drugs* **2002**; 62:2493–537.
8. Chien J, Johnson J. Paradoxical reactions in HIV and pulmonary TB. *Chest* **1998**; 114:933–6.
9. Narita M, Ashkin D, Hollender E, Pitchenik A. Paradoxical worsening of tuberculosis following antiretroviral therapy in patients with AIDS. *Am J Respir Crit Care Med* **1998**; 158:157–61.
10. Cheng V, Ho P, Lee R, Chan K, Woo P, Lau S, Yuen K. Clinical spectrum of paradoxical deterioration during antituberculosis therapy in non-HIV-infected patients. *Eur J Clin Microbiol Infect Dis* **2002**; 21:803–9.
11. Moreno C, Taverne J, Mehlert A, et al. Lipoarabinomannan from *Mycobacterium tuberculosis* induces the production of tumour necrosis factor from human and murine macrophages. *Clin Exp Immunol* **1989**; 76:240–5.
12. Wallis RS, Amir-Tahmasseb M, Ellner JJ. Induction of interleukin 1 and tumor necrosis factor by mycobacterial proteins: the monocyte Western blot. *Proc Natl Acad Sci* **1990**; 87:3348–52.
13. Safdar A, Brown A, Kraus D, Malkin M. Paradoxical reaction syndrome complicating aural infection due to *Mycobacterium tuberculosis* during therapy. *Clin Infect Dis* **2000**; 30:625–7.