

## De Novo Autoimmune Hepatitis during Immune Reconstitution in an HIV-Infected Patient Receiving Highly Active Antiretroviral Therapy

Jacqueline G. O'Leary,<sup>1</sup> Kimon Zachary,<sup>2</sup> Joseph Misdraji,<sup>3</sup> and Raymond T. Chung<sup>1</sup>

<sup>1</sup>Gastrointestinal and <sup>2</sup>Infections Disease Units, Department of Medicine, and <sup>3</sup>Department of Pathology, Massachusetts General Hospital and Harvard Medical School, Boston, Massachusetts

**Immune reconstitution inflammatory syndrome is typically seen in human immunodeficiency virus–seropositive patients who commence antiretroviral therapy. In patients who experience this syndrome, the immune system's reconstitution leads to a response directed against pathogens or autoantigens. We report, to our knowledge, the first case of autoimmune hepatitis caused by immune reconstitution.**

Initiation of antiretroviral therapy can cause immune reconstitution inflammatory syndrome (IRIS). IRIS is an inflammatory response to pathogens present in the host, most commonly *Mycobacterium tuberculosis*, *Mycobacterium avium* complex, *Cryptococcus* species, *Histoplasma capsulatum*, *Toxoplasma gondii*, *Pneumocystis jirovecii*, cytomegalovirus, herpes viruses, and JC virus. Increases in aminotransferase levels may be seen after the initiation of antiretroviral therapy in HIV-seropositive patients with underlying hepatitis B or C virus coinfection. However, the robust immune response may also be directed at autoantigens. The induction of autoimmune diseases has been reported to occur as part of IRIS. For instance, autoimmune thyroid disease, sarcoidosis, and autoimmune arthritides have been reported in HIV-seropositive patients who start antiretroviral therapy [1–3]. Unlike pathogen-mediated IRIS, the precise autoantigens that trigger IRIS are unknown. However, autoimmunity likely results from disruption in peripheral tolerance in a genetically susceptible host [4]. Here,

we report a case of autoimmune hepatitis as a manifestation of IRIS.

**Case report.** A 44-year-old African American woman with HIV infection, a CD4 cell count of 269 cells/mm<sup>3</sup>, and an HIV load of 4927 copies/mL commenced antiretroviral therapy (with tenofovir, emtricitabine, and efavirenz) in April 2005, when her alanine aminotransferase (ALT) level was 26 U/L and her total bilirubin was 0.3 mg/dL. Her HIV load decreased to <50 copies/mL, and by September 2005, her CD4 cell count had increased to 526 cells/mm<sup>3</sup>.

Her past medical history was notable for Graves disease, which was diagnosed on the basis of the patient's hyperthyroidism and exophthalmos. She had been treated with radioactive iodine in 1999. Since then, she had received maintenance treatment with levothyroxine, with a normal free T4 level. She was not taking any over-the-counter medications or herbs.

The patient drank 0–2 alcoholic beverages per month and had no history of drug use. She contracted HIV through heterosexual sex with a previous long-term partner. The patient had not been sexually active since receiving her diagnosis of HIV infection. Her family history was significant for Graves disease in her mother. There was no family history of liver disease.

In September 2005, the patient's ALT level was 26 U/L, and her total bilirubin level was 0.3 mg/dL. On 18 January 2006, her ALT level was 245 U/L, and her total bilirubin level was 0.4 mg/dL. Antiretroviral therapy was discontinued, but her aminotransferase levels continued to increase. On 3 March 2006, her ALT level was 940 U/L and her total bilirubin was 2.1 mg/dL (figure 1).

The patient's physical examination was remarkable for findings of icteric sclera and mild exophthalmos. No lymphadenopathy was found. There were no thyroid abnormalities noted. The liver span was 11 cm in the midclavicular line, with mild tenderness along the entire palpable liver edge. There was no shifting dullness, and no spleen tip was palpated. She had no asterixis or any signs or symptoms of encephalopathy. No spider angioma was identified.

The patient's other pertinent laboratory findings included the following laboratory values: international normalized ratio, 1.5; albumin level, 3.7 g/dL; antinuclear antibody titer, 1:160; anti-smooth muscle antibody titer, 1:160; and IgG level, 2640 mg/dL. Test results were negative for antibodies to hepatitis viruses A, B, C, and E; serologic test results were negative for cytomegalovirus and Epstein bar virus; and hepatitis B and C

Received 22 July 2007; accepted 29 August 2007; electronically published 30 November 2007.

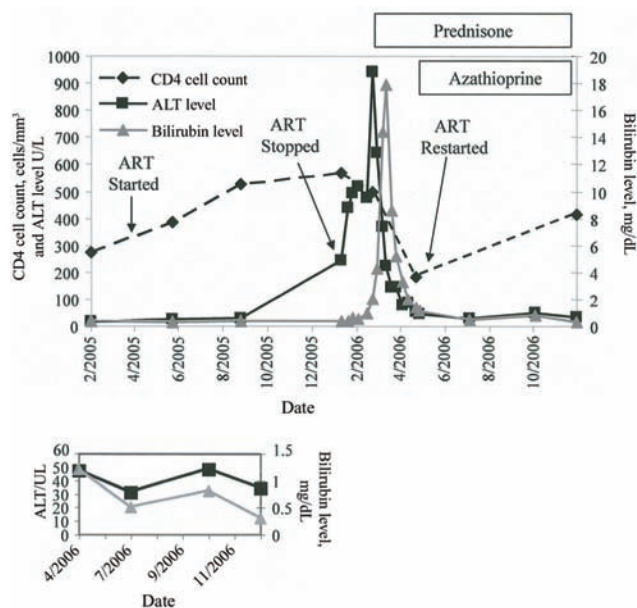
Reprints or correspondence: Dr. Raymond T. Chung, Gastrointestinal Unit, Dept. of Medicine, Massachusetts General Hospital, Warren 1007, 55 Fruit St., Boston, MA 02114 (rtchung@partners.org).

**Clinical Infectious Diseases** 2008;46:e12–4

© 2007 by the Infectious Diseases Society of America. All rights reserved.

1058-4838/2008/4601-00E3\$15.00

DOI: 10.1086/524082



**Figure 1.** Graphic representation of CD4 cell count, alanine aminotransferase (ALT) level, and total bilirubin level in response to antiretroviral therapy (ART) and steroid therapy.

viral loads were undetectable. The patient's ceruloplasmin, renal function, and platelet counts were all normal.

Liver biopsy demonstrated panlobular hepatitis, with lobular disarray, multifocal bridging necrosis, focal pan-acinar necrosis, and lobular collapse (figure 2). The inflammatory infiltrate predominantly included lymphocytes. Plasma cells were also present, with a small number of eosinophils. The results of an immunohistochemical stain for cytomegalovirus and in situ hybridization for Epstein-Barr virus–encoded RNA were negative.

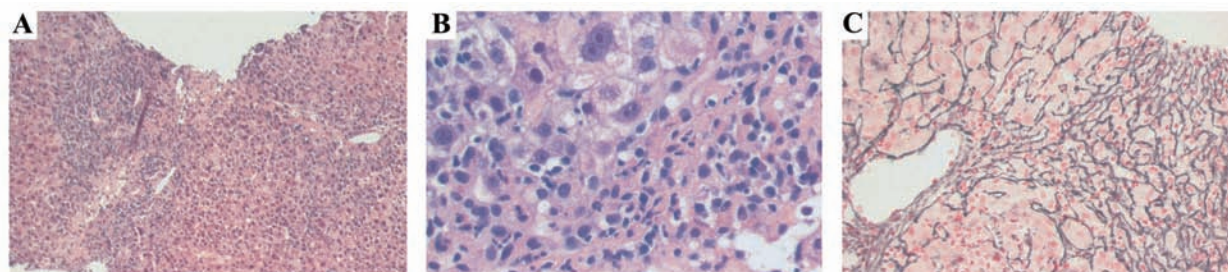
Given the liver biopsy results, laboratory values, and positive antinuclear antibody and anti-smooth muscle antibody, a diagnosis of autoimmune hepatitis was made. The patient had

an autoimmune hepatitis score of 22; a score >15 indicates definite autoimmune hepatitis [5]. She responded to prednisone (60 mg per day), with a prompt decrease in her ALT level to 369 U/L on 16 March 2006 (figure 1). As is usually seen in severe acute liver injury, the improvement in the bilirubin level lagged behind the improvement in the ALT level. Therefore, on 21 March 2006, the bilirubin level reached a peak of 17.9 mg/dL, whereas the ALT level had decreased to 226 U/L. Once her bilirubin level had decreased to 2 mg/dL (on 21 April 2006), the patient initiated azathioprine therapy. Her prednisone dose was tapered as her azathioprine dosage was increased to 150 mg per day (2 mg/kg per day).

When the patient's prednisone dose was tapered to 2.5 mg, she developed a minor flare, during which her ALT level increased to 48 U/L. Her prednisone dose was increased to 10 mg, and this flare resolved. After the mild flare, her azathioprine dosage was increased to 200 mg per day (2.5 mg/kg per day), and her prednisone dose was once again tapered. In May 2006, the patient restarted the identical antiretroviral therapy regimen (tenofovir, emtricitabine, and efavirenz), without event. Her CD4 cell count increased from 183 to 415 cells/mm<sup>3</sup>.

**Discussion.** IRIS is typically seen in HIV-seropositive patients who commence antiretroviral therapy. During IRIS, reconstitution of the immune system is accompanied by a response directed against pathogens or autoantigens. This is, to our knowledge, the first reported case of autoimmune hepatitis triggered by immune reconstitution in an HIV-seropositive patient. The patient had compelling evidence of autoimmune hepatitis, including characteristic histologic findings, a prompt response to corticosteroid therapy, and a history of autoimmune disease. Her minor flare in the ALT level with withdrawal of steroids and her ability to tolerate reintroduction of the identical antiretroviral regimen further supported the diagnosis of autoimmune hepatitis over drug-related hepatotoxicity or infection with an undisclosed pathogen.

Interestingly, a case of autoimmune hepatitis was reported



**Figure 2.** A, Liver biopsy demonstrating panlobular hepatitis with bridging necrosis. A necroinflammatory septum links a central vein (right) with an expanded portal area (left). Original magnification,  $\times 100$ . B, High-magnification view of the inflammatory infiltrate in the periportal region showing a mixture of inflammatory cells, including occasional clusters of plasma cells (right). Original magnification,  $\times 400$ . C, Reticulin stain demonstrating collapse of the hepatic plates, with condensation of the reticulin fibers between the central vein (left) and portal tract (right). Original magnification,  $\times 200$ .

in a patient who, 2 years later, received a diagnosis of HIV infection, with a CD4 cell count of 216 cells/mm<sup>3</sup> [6]; this patient had aminotransferase levels of 3–5 times the upper limit of normal, an antinuclear antibody of 1:320, an elevated IgG level, and a liver biopsy showing minimal focal periportal inflammation and moderate steatosis. Initiation of antiretroviral therapy normalized his aminotransferase levels within 3 months. The authors hypothesized that HIV infection itself was responsible for triggering autoimmune hepatitis through molecular mimicry. Although this is an intriguing hypothesis, given the paucity of inflammation in the liver biopsy specimen, it is difficult to conclude that this patient had autoimmune hepatitis.

The precise mechanism causing the emergence or unmasking of autoimmune conditions in HIV-positive patients who commence antiretroviral therapy remains unclear, but it is likely to be related to loss of peripheral tolerance. The thymus should eliminate all autoreactive T cells [4]. However, if autoreactive T cells escape central tolerance induction, then peripheral tolerance should be achieved through costimulatory molecules on antigen-presenting cells or through suppression by T regulatory cells. We hypothesize that, with the resurgence of CD4 help in our patient, there was unmasking of a CD8 cell response to autoantigens. In addition, it is possible that HIV infection may have depleted CD4 T regulatory cells that were not replenished sufficiently during immune reconstitution. Regardless of the mechanism, the temporal relationship in this case appears to be clear.

In summary, we have reported the first case, to our knowl-

edge, of autoimmune hepatitis to occur during immune reconstitution in an HIV-infected person. Therefore, for clinicians who care for HIV-infected persons, autoimmune hepatitis should be included in the differential diagnosis of increased aminotransferase levels in patients during immune reconstitution with antiretroviral therapy and should be considered to be an additional clinical manifestation of IRIS.

## Acknowledgments

**Financial support.** American Association for the Study of Liver Diseases (J.G.O.).

**Potential conflicts of interest.** All authors: no conflicts.

## References

1. Lipman M, Breen R. Immune reconstitution inflammatory syndrome in HIV. *Curr Opin Infect Dis* **2006**; 19:20–5.
2. Foulon G, Wislez M, Naccache JM, et al. Sarcoidosis in HIV-infected patients in the era of highly active antiretroviral therapy. *Clin Infect Dis* **2004**; 38:418–25.
3. Calabrese LH, Kirchner E, Shrestha R. Rheumatic complications of human immunodeficiency virus infection in the era of highly active antiretroviral therapy: emergence of a new syndrome of immune reconstitution and changing patterns of disease. *Semin Arthritis Rheum* **2005**; 35:166–74.
4. Kamradt T, Mitchison NA. Tolerance and autoimmunity. *N Engl J Med* **2001**; 344:655–64.
5. Alvarez F, Berg PA, Bianchi FB, et al. International Autoimmune Hepatitis Group Report: review of criteria for diagnosis of autoimmune hepatitis. *J Hepatol* **1999**; 31:929–38.
6. German V, Vassiloyanakopoulos A, Sampaziotis D, et al. Autoimmune hepatitis in an HIV infected patient that responded to antiretroviral therapy. *Scand J Infect Dis* **2005**; 37:148–51.