

Escherichia coli Pyomyositis: An Emerging Infectious Disease among Patients with Hematologic Malignancies

Karen J. Vigil,¹ James R. Johnson,⁴ Brian D. Johnston,⁴ Dimitrios P. Kontoyiannis,³ Victor E. Mulanovich,³ Issam I. Raad,³ Herbert L. DuPont,² and Javier A. Adachi^{1,2,3}

¹Medical School and ²School of Public Health, The University of Texas Health Science Center at Houston, and ³The University of Texas M. D. Anderson Cancer Center, Houston; and ⁴Veterans Affairs Medical Center and University of Minnesota, Minneapolis

Background. Pyomyositis is typically caused by gram-positive bacteria, especially *Staphylococcus aureus*. Few cases of *Escherichia coli* pyomyositis have been reported, including only 1 involving a patient with a hematologic malignancy.

Methods. The clinical microbiology database at The M. D. Anderson Cancer Center (Houston, TX) was reviewed for the period January 2003 through December 2007 to identify cases of *E. coli* pyomyositis. Clinical characteristics, laboratory and radiologic findings, treatment, and outcomes were recorded. Available isolates underwent phylogenetic group determination, virulence genotyping, multilocus sequence typing, repetitive-element polymerase chain reaction, and pulsed-field gel electrophoresis.

Results. Six cases of *E. coli* pyomyositis were identified. All patients were receiving chemotherapy for a hematologic malignancy; 5 were severely neutropenic. Three patients became hypotensive, 2 required intensive care, and 2 (33%) died, despite receiving carbapenem therapy. All *E. coli* isolates were fluoroquinolone resistant; 55% produced an extended-spectrum β -lactamase (ESBL). Five of 6 available isolates belonged to phylogenetic group B2, had similar virulence factor profiles, exhibited > 95% similar repetitive-element polymerase chain reaction profiles, and represented sequence type ST131; however, all had unique pulsed-field gel electrophoresis profiles.

Conclusions. *E. coli* pyomyositis has emerged as a serious problem among our patients with hematologic malignancy. It usually is caused by members of *E. coli* ST131, a recently identified cause of fluoroquinolone-resistant, ESBL-positive *E. coli* infection worldwide. Awareness of this emerging syndrome and the usual causative agent is important to ensure appropriate management when febrile, neutropenic patients with hematologic malignancy exhibit signs of localized muscle infection.

Escherichia coli is the most common cause of gram-negative bacteremia [1], including among patients with cancer [2], and constitutes a serious threat to compromised hosts. *E. coli* sepsis has substantial associated morbidity, mortality, and health care costs, with an estimated 40,000 deaths per year in the United States and a calculated cost between 1.1 and 2.8 billion dollars per year [3].

Pyomyositis, an acute bacterial infection of skeletal

muscle, is caused by *Staphylococcus aureus* or other gram-positive organisms in >90% of cases. Extraintestinal pathogenic *E. coli* (ExPEC) can cause infections at a wide variety of anatomical sites, including the urinary tract, bloodstream, meninges, lungs, and other organs and tissues. However, to date, only 14 cases of *E. coli* pyomyositis in adults have been reported [4–13], only one of which involved a patient with a hematologic malignancy. Moreover, the characteristics of the causative bacteria have not been studied.

We recently encountered a case of *E. coli* pyomyositis in a neutropenic patient with acute myeloid leukemia. This prompted us to assess the frequency of *E. coli* pyomyositis in patients with cancer at our institution, to describe the clinical features of this syndrome, and to determine the phenotypic and molecular characteristics of the responsible *E. coli* strains.

Received 19 June 2009; accepted 21 September 2009; electronically published 28 December 2009.

Reprints or correspondence: Dr Javier A. Adachi, The University of Texas–M. D. Anderson Cancer Center, 1515 Holcombe Blvd, Unit 1460, Houston, TX 77030 (jaadachi@mdanderson.org).

Clinical Infectious Diseases 2010;50:374–80

© 2010 by the Infectious Diseases Society of America. All rights reserved.
1058-4838/2010/5003-0011\$15.00
DOI: 10.1093/cid/cir106

MATERIALS AND METHODS

To capture recent cases of *E. coli* pyomyositis at our institution, we screened the medical records of all 5793 consecutive patients known to have had *E. coli* isolated from any site at The University of Texas–M. D. Anderson Cancer Center (MDACC) during the preceding 5-year period (January 2003 to December 2007), as identified via the institution's clinical microbiology laboratory database. The diagnosis of pyomyositis was based on a typical clinical presentation (ie, fever and pain in the involved muscle[s]), confirmed by compatible radiologic findings, such as edema in the muscle tissue noted by computerized tomography or magnetic resonance imaging. *E. coli* was considered to be the causative agent if *E. coli* was isolated from a muscle abscess or, if no abscess culture was done, from blood.

Data collection. Medical records of patients with pyomyositis were reviewed retrospectively. Demographic data, underlying disease, clinical features of the pyomyositis episode, laboratory and radiologic findings, treatment, and outcomes were recorded.

Clinical microbiology. Species identity was confirmed by use of API 20E (bioMérieux). Antimicrobial susceptibility was determined according to Clinical and Laboratory Standards Institute guidelines using the Vitek legacy system (bioMérieux, Durham NC) and Clinical and Laboratory Standards Institute–specified interpretive criteria. Extended-spectrum β -lactamase (ESBL) production was determined using Vitek cards containing cefotaxime and cefotaxime plus clavulanate.

Phylogenetic analysis and virulence genotyping. *E. coli* phylogenetic groups (A, B1, B2 and D) and virulence genotypes for 51 ExPEC-associated virulence genes and 13 *papA* (P fimbrial structural subunit) alleles were determined by multiplex polymerase chain reaction (PCR) [14, 15]. Isolates were categorized as ExPEC if positive for ≥ 2 of: *papA* and/or *papC* (P fimbriae; counted as one), *sfa/foc* (S and F1C fimbriae), *afa/dra* (Dr-binding adhesins), *iutA* (aerobactin system), and *kpsM* II (group 2 capsules). The O25b *rfb* (lipopolysaccharide) variant and *bla*_{CTX-M-15} (which encodes the CTX-M-15 ESBL) were detected by PCR [16].

Clonal analysis. Broad clonal group relationships were assessed by repetitive-element-based PCR profiling (rep-PCR) and multilocus sequence typing (MLST). Rep-PCR was done using the DiversiLab microbial typing system (Bacterial BarCodes) [17]. Six *E. coli* bloodstream isolates from patients without pyomyositis were included as controls. MLST was performed based on allelic profiles for 7 housekeeping genes (<http://mlst.ucc.ie>). To resolve distinct strains, pulsed-field gel electrophoresis (PFGE) analysis of *Xba*I-restricted total DNA was done according to a standardized protocol [18].

RESULTS

Six cases of *E. coli* pyomyositis were identified among MDACC patients from 2003 through 2007 (Table 1). Significantly more cases of *E. coli* pyomyositis per total number of *E. coli* unique bloodstream infections occurred during the final year of the study period (ie, 2007; 4 [2.4%] of 163) than during the first 4 years (ie, 2003–2006; 2 [0.3%] of 622; $P = .01$).

The mean age of the 6 case patients (4 men and 2 women) with pyomyositis was 53 years (range, 38–67 years). All 6 patients had an underlying hematologic malignancy (leukemia in 5 and lymphoma in 1) and were receiving chemotherapy or high-dose steroids plus fluoroquinolone prophylaxis. Five of six patients had been severely neutropenic (neutrophil count, < 500 neutrophils/ μ L) for ≥ 3 days (range, 3–13 days) before the clinical onset of pyomyositis. The single nonneutropenic patient was receiving high-dose steroids (equivalent to 120 mg of prednisone daily) for graft-vs-host disease from a recent allogeneic stem cell transplant.

When pyomyositis was diagnosed, 5 of the 6 patients had involvement of the calves, whereas 2 additionally had involvement of the thigh. Magnetic resonance imaging showed diffusely abnormal T2 signal intensity within the musculature, consistent with edema and suggestive of myositis (Figure 1A). Three patients had frank abscesses detected in the involved muscle(s) on days 5, 14, and 16, respectively, after the initial pyomyositis diagnosis (Figure 1B). Neutrophil counts had already recovered in these 3 patients at the time the abscesses appeared. In each instance, the abscess was aspirated and yielded *E. coli* as the only pathogen.

Three patients (50%) developed hypotension and required transfer to the intensive care unit. All 6 patients were treated with a carbapenem; 3 also received amikacin. Two patients (33%) died; 1 had fulminant sepsis, whereas the other never recovered from his underlying malignancy and the infection.

E. coli was isolated from blood (all 6 subjects) and, if cultured, abscess contents (all 3 subjects with abscesses). In each instance, *E. coli* was the only organism isolated. All 9 *E. coli* isolates (100%) were fluoroquinolone resistant (Table 2), significantly greater than the overall prevalence of fluoroquinolone resistance among all *E. coli* isolated from any site at our institution during the study period (2551 [44%] of 5793; $P < .001$). Moreover, 5 (55%) of the isolates (3 blood and 2 abscess isolates), all from 2007, were ESBL positive (Table 2). Thus, the prevalence of ESBL-positive isolates was significantly greater among the pyomyositis isolates than among other clinical *E. coli* isolates, both during the overall study period (5 [55%] of 9 vs 144 [2.5%] of 5793; $P < .001$) and especially during the most recent year, 2007 (5 [83%] of 6 vs 85 [7%] of 1194; $P < .001$).

Six of 9 *E. coli* isolates from the pyomyositis episodes were available for molecular analysis, including the blood isolates from patients 1, 3, 4, and 5, and both the blood and abscess

Table 1. Clinical Characteristics of 6 Hematologic Malignancy Patients with Pyomyositis due to *Escherichia coli*

Patient	Date of diagnosis	Age, years/sex	Cancer diagnosis	Chemotherapy (cycle/day)	ANC, neutrophils/ μ L	Duration of severe neutropenia, days ^a	Prophylactic antimicrobial agent	Site of muscle involvement	Hypotension	Abscess	ICU admission	Outcome
1	April 2004	51/M	AML	Fludarabine, Ara-C, topotecan (1/14)	0.2	5	Levofloxacin	Calf, distal thigh	No	No	No	Died
2	August 2004	38/F	BL	Hyper CVAD, rituximab (5/14)	0.2	5	Levofloxacin	Calves	Yes	Yes	Yes	Survived
3	August 2007	50/M	AML	Idarubicin, cytarabine, (1/9)	0.1	3	Levofloxacin	Calf	Yes	Yes	No	Survived
4	August 2007	64/M	CLL	Zevalin, FCR (1/59)	3.6	NA	Moxifloxacin	Calf	No	No	No	Survived
5	October 2007	67/F	AML	Clofarabine (1/18)	0.3	13	Levofloxacin	Axilla	Yes	No	Yes	Died
6	December 2007	52/M	ALL	Hyper CVAD, dasatinib (1/15)	0.1	5	Levofloxacin	Calf, thigh	No	Yes	No	Survived

NOTE. ALL, acute lymphoblastic leukemia; AML, acute myeloid leukemia; Ara-C, arabinoside/cytosine; BL, Burkitt lymphoma; CLL, chronic lymphocytic leukemia; CVAD, cyclophosphamide, vincristine, adriamycin, dexamethasone; FCR, fludarabine, cyclophosphamide, rituximab; IDA, intensive care unit; NA, not available.

^a Duration of severe neutropenia was defined as an ANC of <500 neutrophils/ μ L prior to diagnosis of pyomyositis.

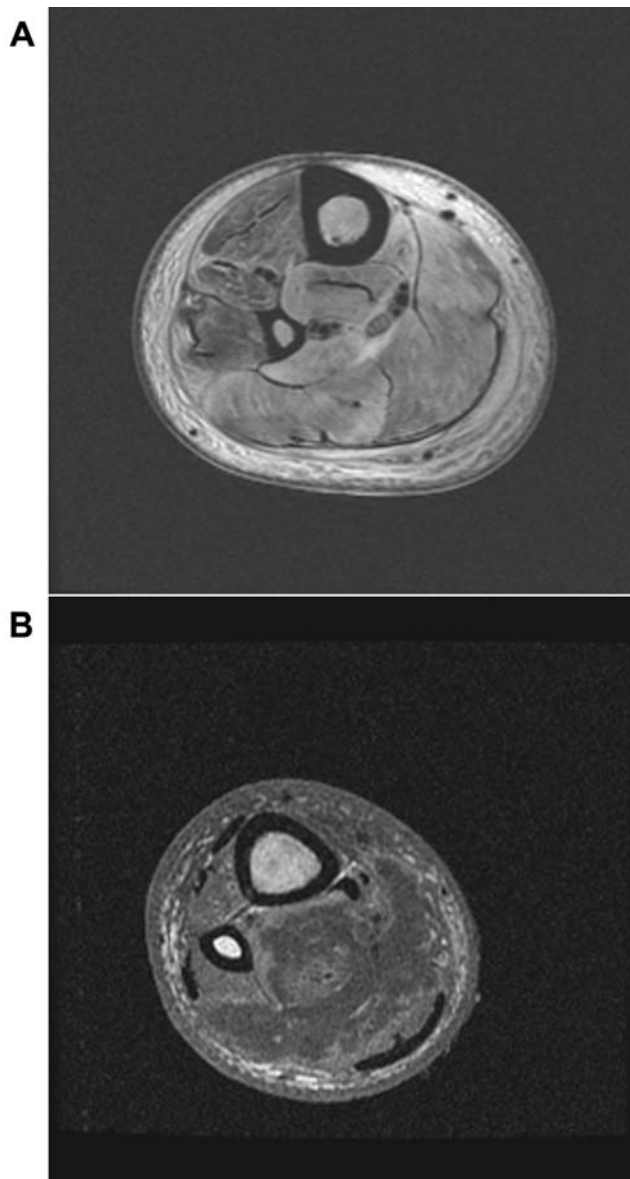


Figure 1. Magnetic resonance images showing pyomyositis cases without and with abscess formation. *A*, Axial T2-weighted spin-echo magnetic resonance image showing edema of the leg muscles. *B*, T1-weighted magnetic resonance image showing a large irregular abscess confined in the posterior compartment of the calf with surrounding edema.

isolates from patient 6. All 6 available isolates met the molecular definition of ExPEC, and 5 of 6 (ie, all but patient 6's blood isolate, which was from phylogenetic group D), were from group B2. The 5 group B2 isolates exhibited fairly similar virulence factor profiles that included genes for adhesins (*iha* and *fimH*, +/- *afa/dra*), a toxin (*sat*), siderophore receptors (*iha*, *fyuA*, and *iutA*), group 2 capsule (*kpsM* II, with its K2 and K5 variants), and miscellaneous other traits (*usp*, *traT*, *ompT*, and *malX*) (Table 3). In contrast, the group D blood isolate from patient 6 exhibited a distinct virulence profile.

According to rep-PCR, the 5 group B2 pyomyositis isolates exhibited >95% similar profiles and, thus, clustered closely together in a dendrogram (Figure 2), suggesting a common clonal group background. The group D strain stood apart, connected to the above cluster at the 66% similarity level. Five arbitrarily selected nonpyomyositis *E. coli* strains exhibited diverse rep-PCR profiles, all <85% similar to one another or to the pyomyositis isolate profiles (data not shown), suggesting diverse clonal group backgrounds.

In confirmation of the rep-PCR findings, MLST showed the 5 group B2 pyomyositis isolates to exhibit the same combination of alleles across the 7 sequenced loci, in a pattern corresponding to sequence type ST131. Consistent with their ST131 background, all 5 isolates exhibited the O25b *rfb* allele and were resistant to 2–7 antimicrobial classes (median, 4 antimicrobial classes) each (Tables 2 and 3). Two of the ST131 isolates were ESBL positive; one of these exhibited (ST131-associated) *bla*_{CTX-M-15}. However, according to PFGE analysis, each of the 5 ST131 isolates represented a distinct PFGE type, as defined at the 94% profile similarity level. Three of these ST131-associated PFGE types were unique to this study. In contrast, 2 had been encountered previously in isolates from New York and Cleveland, Ohio, in a large PFGE reference library involving 250 ST131 isolates from 32 US and international locales (J.R.J., unpublished data).

DISCUSSION

E. coli pyomyositis is a rare clinical syndrome that has emerged as a new and often quite serious or fatal infectious complication among hematologic malignancy patients at our institution. The literature through 2008 contained only a few case reports of pyomyositis due to *E. coli*; these occurred mostly in immunosuppressed or chronically ill patients, but not in patients with hematologic malignancies [7–13]. Moreover, a recent review of pyomyositis in patients with hematologic malignancies found the most common causative organism to be *S. aureus* (as for pyomyositis generally) and included no cases due to *E. coli* [19]. Only in 2009 was the first case of *E. coli* pyomyositis reported in a patient with a hematologic malignancy (ie, acute myeloid leukemia) [6]. Interestingly, like most of our patients, this patient had calf involvement and was neutropenic when pyomyositis occurred [6].

By definition, all our patients had the typical presentation of pyomyositis, with fever and tenderness over the involved muscle area and characteristic computerized tomography or magnetic resonance imaging findings. Pyomyositis traditionally has been divided into 3 stages. Stage 1 involves inflammation, but aspiration of the muscle will not yield pus; stage 2 usually occurs 2–3 weeks later, with a clinically apparent frank abscess; and stage 3 has associated signs of toxicity [20]. In contrast to many published pyomyositis cases, none of our patients had a

Table 2. Antimicrobial Susceptibility Profiles of 9 *Escherichia coli* Isolates from Patients with Hematologic Malignancy with Pyomyositis due to *E. coli*

Patient, source	Antimicrobial agent ^a										
	ESBL	Amikacin	Gentamicin	Tobramycin	Aztreonam	Ceftriaxone	Cefepime	Ciprofloxacin	Levofloxacin	Piperacillin-tazobactam	Trimethoprim-sulfamethoxazole
1: Blood	–	S	R	S	S	S	S	R	R	S	R
2											
Blood	–	S	R	S	S	S	S	R	R	S	R
Abscess	–	S	R	S	S	S	S	R	R	S	R
3											
Blood	–	S	S	R	S	S	S	R	R	S	S
Abscess	+	R	S	R	R	R	R	R	R	R	S
4: Blood ^b	+ ^b	R	S	S	I	R	R	R	R	I	R
5: Blood	+	S	S	S	R	R	R	R	R	S	S
6											
Blood	+	S	R	R	R	R	R	R	R	S	R
Abscess	+	S	R	S	R	R	R	R	R	S	R

NOTE. ESBL, extended-spectrum β-lactamase; I, intermediate; R, resistant; S, susceptible; +, ESBL production present; –, ESBL production absent.

^a All isolates were susceptible to imipenem and meropenem (data not shown).

^b Positive for *bla*_{CTX-M-15}.

frank muscle abscess on initial presentation. Possible explanations include that the patients (1) presented early in the disease (ie, in stage 1) or (2) were neutropenic, making them unable to mount a full inflammatory response to infection. The latter hypothesis is supported by our finding that the 3 patients who developed an abscess did so only after recovering their neutrophil counts, despite ongoing treatment with appropriate antibiotics.

The clinical course of *E. coli* pyomyositis is usually benign. However, in our case series, 50% of the patients required intensive care unit transfer secondary to hypotension, and 33% died. In general, pyomyositis has been reported to have an attributable mortality of 1% in immunocompetent hosts [21] and 11% in patients with hematologic malignancies [19]. The mortality associated specifically with pyomyositis due to *E. coli*

has not been reported previously. However, considering the published cases of pyomyositis secondary to *E. coli* [6–13], we could calculate an associated mortality of 33%. This is identical to the mortality observed in our study and higher than that of *E. coli* bloodstream infection in patients with cancer (14%) (K.J.V., unpublished data). These findings suggest that both host immunosuppression and bacterial virulence contribute to disease outcome.

All of our pyomyositis isolates were resistant to fluoroquinolones. Both selective pressure from extensive use of antibiotics and clonal spread have been postulated to contribute to the emergence of fluoroquinolone resistance. Each of these factors was present in our patients. Supporting the selection hypothesis, all patients were receiving fluoroquinolones as prophylaxis. Supporting the clonal spread hypothesis, 5 of the 6 isolates

Table 3. Molecular Analysis of 6 *Escherichia coli* Isolates from Patients with Hematologic Malignancy and Pyomyositis due to *E. coli*

Patient, ^a source	Phylogenetic group	O type	O		Adhesin			Toxin: <i>sat</i>	Siderophore		Protectin or invasins			Miscellaneous			
			CTX-M-15	ST131	<i>afa/dra</i>	<i>iha</i>	<i>fimH</i>		<i>iutA</i>	<i>fyuA</i>	<i>kpsM II</i>	K2	K5	<i>malX</i>	<i>usp</i>	<i>traT</i>	<i>ompT</i>
1: Blood	B2	O25	–	+	–	+	+	+	+	+	+	–	+	+	+	+	+
3: Blood	B2	O25	–	+	+	+	+	+	+	+	+	+	–	+	+	+	+
4: Blood	B2	O25	+	+	+	+	+	+	+	+	+	+	–	+	+	+	+
5: Blood	B2	O25		+	–	+	+	+	+	+	+	–	+	+	+	+	+
6																	
Blood	D	–	–	–	+	+	+	–	+	+	+	+	–	–	–	+	–
Abscess	B2	O25	–	+	–	+	+	+	+	+	+	+	–	+	+	+	+

NOTE. *afa/draBC*, afimbrial Dr-binding adhesins; *fimH*, type I fimbriae; *fyuA*, yersiniabactin receptor; *iha*, adhesin-siderophore receptor; *iutA*, aerobactin receptor; *kpsM II*, group 2 capsule synthesis (variant K2 and K5); *malX*, pathogenicity island marker; *ompT*, outer membrane protease; *sat*, secreted auto-transporter toxin; *traT*, serum resistance associated; *usp*, uropathogenic specific protein.

^a The blood and abscess isolate from patient 2 and the abscess isolate from patient 4 were not available for testing.

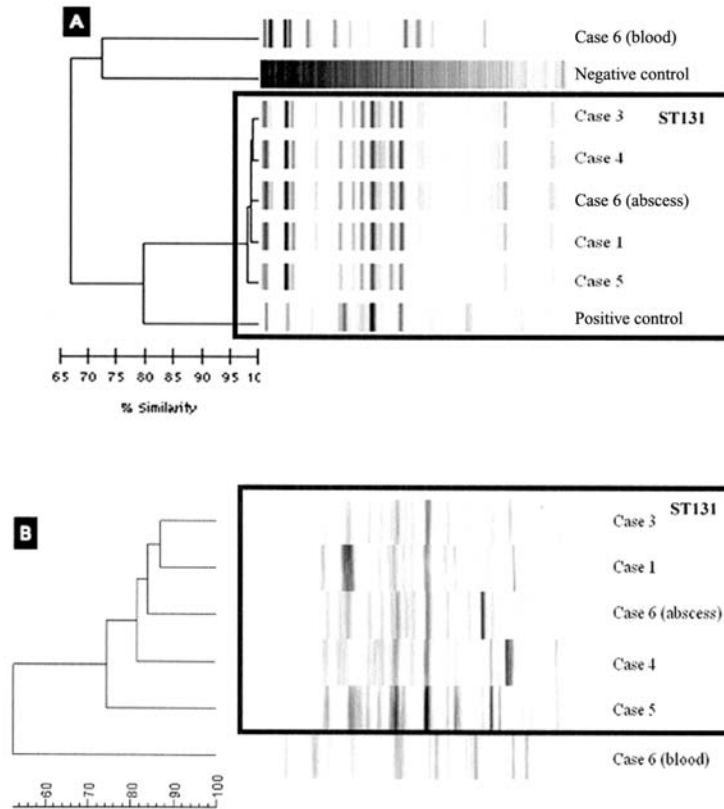


Figure 2. Repetitive element-based polymerase chain reaction (rep-PCR; *A*) and pulsed-field gel electrophoresis (PFGE) profiles (*B*) of 6 *Escherichia coli* isolates from 5 hematologic malignancy patients with pyomyositis. Rectangles enclose the ST131 isolates. Note the homogenous rep-PCR profiles of the ST131 isolates, compared with their more diverse PFGE profiles.

available for molecular analysis derived from the same *E. coli* lineage (ie, ST131). Notably, the diversity of PFGE types noted among the 5 ST131 isolates—and the fact that 2 of these PFGE types have been encountered previously at other centers—indicate that our cases are part of the global dissemination of ST131, not just a localized point-source outbreak in our institution or community.

Recent analyses of European and Canadian fluoroquinolone-resistant *E. coli* urine isolates found that the most prominent subset within the study populations was *E. coli* ST131 [16, 22], which not long previously had been first reported as an emerging cause of CTX-M-15-positive *E. coli* infections on multiple continents [23]. Our finding that ST131 accounted for 5 of 6 pyomyositis cases establishes that this globally disseminated clonal group is capable of causing not only cystitis and bloodstream infections, as previously described, but also tissue-invasive disease. Moreover, on the basis of the dissimilar (presumably, non-ST131) rep-PCR profiles of the 5 comparison nonpyomyositis *E. coli* blood isolates, we can infer that at our institution ST131 is specifically associated with pyomyositis (5 of 6 pyomyositis isolates vs 0 of 5 nonpyomyositis bloodstream isolates; $P = .015$).

Our ST131 *E. coli* pyomyositis isolates exhibited virulence profiles (Table 3) similar to those observed among previously reported *E. coli* ST131 isolates, whether CTX-M-15-positive or negative [16, 23, 24]. Additional study is needed to determine whether some of these virulence genes play a direct role in pathogenesis of pyomyositis or whether they are simply markers for this clonal group.

In summary, we report the emergence of *E. coli* pyomyositis as a distinctive and quite serious (even fatal) infectious disease syndrome among patients with hematologic malignancy at MDACC. Almost all cases were caused by members of a recently described, virulent, multidrug-resistant *E. coli* lineage, ST131 (O25:H4), that has been identified as an emerging cause of fluoroquinolone-resistant and ESBL (typically CTX-M-15)-positive extraintestinal *E. coli* infection worldwide. Awareness of this emerging syndrome and the predominant causative clonal group is important to ensure rapid institution of early and appropriate management when febrile neutropenic patients with hematologic malignancy exhibit localized muscle pain. In addition, relevant risk factors, reservoirs, transmission pathways, and virulence mechanisms of *E. coli* ST131 need to be defined to inform the development of effective measures to

prevent further dissemination and emergence of this threatening new pathogen.

Acknowledgments

We thank Dr. Jeffrey Tarrand, Ms. Ruth Reitzel, and Ms. Tanya Dvorak for their support.

Potential conflicts of interest. J.R.R. has been a consultant for Ortho-McNeil and has received grants or contracts from Merck, Bayer, Procter and Gamble, Wyeth-Ayerst, and Rochester Medical. D.P.K. is an investigator for Merck and a consultant for Merck and Schering-Plough; has received grants and research support from Merck, Enzon, and Fujisawa/Astellas; is in the speaker's bureau of Merck, Pfizer, Enzon, and Fujisawa/Astellas; has been a speaker for Enzon and Fujisawa/Astellas; and is on the advisory board of Merck and Schering-Plough. I.I.R. is a consultant for Clorox, Cubist, and Cook; has received grants from Cubist, Schering-Plough, Versicor, Enzon, Pfizer, Wyeth, and Cook; is on the speaker's bureau of Merck, Schering-Plough, Pfizer, and Cook; and has royalties related to patents licensed to American Medical Systems, Horizon Medical Products, and TyRx on which he is a coinventor. H.L.D. has consulted with, has received honoraria for speaking, and has received research grants from Salix Pharmaceutical Company; has received a consulting fee from Romark Institute for Medical Research; has received research grants from Optimer Pharmaceuticals and IOMAI Corporation; has received honoraria for consulting and/or speaking from McNeil Consumer Healthcare and Merck Vaccine Division. All other authors: no conflicts.

References

1. Wisplinghoff H, Bischoff T, Tallent SM, Seifert H, Wenzel RP, Edmond MB. Nosocomial bloodstream infections in US hospitals: analysis of 24,179 cases from a prospective nationwide surveillance study. *Clin Infect Dis* **2004**; 39(3):309–317.
2. Klustersky J, Ameye L, Maertens J, et al. Bacteraemia in febrile neutropenic cancer patients. *Int J Antimicrob Agents* 2007; 30(Suppl 1): S51–S59.
3. Russo TA, Johnson JR. Medical and economic impact of extraintestinal infections due to *Escherichia coli*: focus on an increasingly important endemic problem. *Microbes Infect* **2003**; 5(5):449–456.
4. Barbot R, Morand C, Skopinski S, Albisson E, Portron Y, Coutant G. Pyomyositis of adductor muscles caused by *Escherichia coli* in an immunocompetent patient living in a temperate climate. *Rev Med Interne* **2009**.
5. Brook I, Frazier E. Aerobic and anaerobic microbiology of pyomyositis. *Infect Dis Clin Practice* **1999**; 8(5):252–256.
6. Chiu SK, Chang FY. Pyomyositis caused by extended-spectrum beta-lactamase-producing *Escherichia coli* in a patient with acute myeloid leukemia. *Int J Infect Dis* **2008**; 13(3):e85–e87.
7. Cone LA, Lamb RB, Graff-Radford A, et al. Pyomyositis of the anterior tibial compartment. *Clin Infect Dis* **1997**; 25(1):146–148.
8. Hall RL, Callaghan JJ, Moloney E, Martinez S, Harrelson JM. Pyomyositis in a temperate climate presentation, diagnosis and treatment. *J Bone Joint Surg Am* **1990**; 72:1240–1244.
9. Johnson JR, Gajewski A, Lesse AJ, Russo TA. Extraintestinal pathogenic *Escherichia coli* as a cause of invasive nonurinary infections. *J Clin Microbiol* **2003**; 41(2):5798–5802.
10. Jou IM, Chiu NT, Yang CY, Lai KA. Pyomyositis—with special reference to the comparison between extra—and intrapelvic muscle abscess. *Southeast Asian J Trop Med Public Health* **1998**; 29:835–840.
11. Lortholary O, Jehl F, Petitjean O, Cohen P, Tarral E, Guillemin L. Polymicrobial pyomyositis and bacteremia in a patient with AIDS. *Clin Infect Dis* **1994**; 19(3):552–553.
12. Tumeç SS, Butler GJ, Maguire JH, Nagel JS. Pyogenic myositis: CT evaluation. *J Comput Assist Tomogr* **1988**; 12:1002–1005.
13. Vilades C, Garcia-Queralt R, Rivas I, Vidal F, Richart C. Pyomyositis due to *Escherichia coli* in a patient infected by HIV. *Br J Rheumatol* **1994**; 33(4):404–405.
14. Clermont O, Bonacorsi S, Bingen E. Rapid and simple determination of the *Escherichia coli* phylogenetic group. *Appl Environ Microbiol* **2000**; 66:4555–4558.
15. Johnson JR, Stell AL. Extended virulence genotypes of *Escherichia coli* strains from patients with urosepsis in relation to phylogeny and host compromise. *J Infect Dis* **2000**; 181:261–272.
16. Johnson JR, Menard M, Johnston B, Kuskowski MA, Nichol K, Zhanel GG. Epidemic clonal groups of *Escherichia coli* as a cause of antimicrobial-resistant urinary tract infections in Canada (2002–2004). *Antimicrob Agents Chemother* **2009**; 53(7):2733–2739.
17. Vigil KJ, Adachi JA, Aboufaycal H, et al. Multidrug-resistant *Escherichia coli* bacteremia in cancer patients. *Am J Infect Control* **2009**; 37: 741–745.
18. Ribot EM, Fair MA, Gautam R, et al. Standardization of pulsed-field gel electrophoresis protocols for the subtyping of *Escherichia coli* O157:H7, *Salmonella*, and *Shigella* for PulseNet. *Foodborne Pathog Dis* **2006**; 3(1):59–67.
19. Falagas ME, Rafailidis PI, Kapaskelis A, Peppas G. Pyomyositis associated with hematological malignancy: case report and review of the literature. *Int J Infect Dis* **2008**; 12(2):120–125.
20. Chiedozi LC. Pyomyositis: review of 205 cases in 112 patients. *Am J Surg* **1979**; 137(2):255–259.
21. Crum NF. Bacterial pyomyositis in the United States. *Am J Med* **2004**; 117(5):420–428.
22. Cagnacci S, Gualco L, Debbia E, Schito GC, Marchese A. European emergence of ciprofloxacin-resistant *Escherichia coli* clonal groups O25:H4-ST 131 and O15:K52:H1 causing community-acquired uncomplicated cystitis. *J Clin Microbiol* **2008**; 46(8):2605–2612.
23. Nicolas-Chanoine MH, Blanco J, Leflon-Guibout V, et al. Intercontinental emergence of *Escherichia coli* clone O25:H4-ST131 producing CTX-M-15. *J Antimicrob Chemother* **2008**; 61(2):273–281.
24. Clermont O, Lavollay M, Vimont S, et al. The CTX-M-15-producing *Escherichia coli* diffusing clone belongs to a highly virulent B2 phylogenetic subgroup. *J Antimicrob Chemother* **2008**; 61(5):1024–1028.