Advance Access publication 25 January 2011

Renal tubular dysgenesis and reversible hypocalvaria after intrauterine exposure to an angiotensin receptor blocker

Sir,

We report an infant with renal tubular dysgenesis (RTD) and hypocalvaria after intrauterine exposure to an angiotensin receptor blocker (ARB), in whom RTD is irreversible but hypocalvaria reversible.

A female infant was delivered at a gestational age of 35 weeks and 4 days, weighing 1,878 grams, to a gravid 4, para 4, 37-year-old woman, who received an ARB because of hypertension. The mother received olmesartan medoxomil (40 mg/day) during pregnancy. Ultrasound examination revealed oligohydramnios and intrauterine growth restriction. The infant developed anuria and respiratory distress, requiring mechanical ventilation. Serum creatinine was 3.36 mg/dL on Day 4. Serum concentrations of olmesartan medoxomil on Days 1 and 3 were 21.8 ng/mL and 14.7 ng/mL, respectively. Peritoneal dialysis (PD) was started. The mechanical ventilation was stopped at 1 month.

The infant was transferred to our hospital. Physical examination revealed a widened anterior fontanel and defects of temporal, occipital and parietal bones but no deformity of limbs. Serum creatinine was 1.98 mg/dL. Ultrasound examination revealed large kidneys with high echogenicity. The cranial computed tomography (CT) revealed hypoplasia of temporal, occipital and parietal bones (Figure 1A). At 2 months, some potion of urine passed and gradually increased to 80–160 mL/day. A renal biopsy was performed, revealing poor differentiation between proximal and distal convoluted tubules and increased intertubular mesenchyme (Figure 1B), indicative of RTD. Most tubules were small and collapsed. Some dilated tubules and tubular necrosis as well as dilated Bowman's capsules, lacking the glomerular tuft, were noted. At 5 months, she was discharged with dialysis. In a recent follow-up at 6 months, serum creatinine was 2.95 mg/dL. The cranial CT showed normal cranial bones. Her growth remains poor, at a weight 2,625 grams, but cognitive development is increasingly progressing.

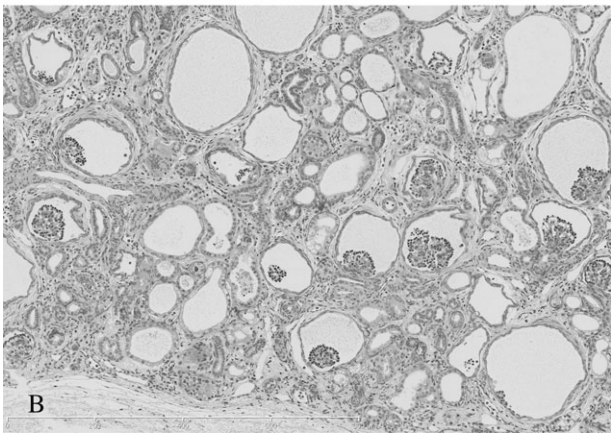

Fig. 1. (**A**): The cranial computed tomography (CT) at 1 month of age reveals calvarial hypoplasia, including hypoplasia of temporal bones. (**B**): A renal biopsy at 3 months of age reveals poor differentiation between proximal and distal convoluted tubules and increased intertubular mesenchyme. Most tubules were small, collapsed, and surrounded by connective tissue. Some dilated tubules and tubular necrosis are noted. There are some dilated Bowman's capsules, lacking the glomerular tuft (magnification ×100, Periodic Acid-Schiff staining).

Table 1 summarizes the clinical characteristics of the reported infants with hypocalvaria and/or RTD after intrauterine exposure to agents that inhibit the renin–angiotensin system (RAS). Three infants after exposure to angiotensin-converting enzyme inhibitors [1] and four infants after exposure to ARBs [2–4], includiing our patient (Case 7), were reported. Of four infants after exposure to ARBs, one developed hypocalvaria alone [3]. All infants with hypocalvaria and acute renal failure, except one case [4], died or remained dependent on PD, suggesting a poor prognosis of these infants. Our patient showed growth of the calvarial bones as described [1, 4], but remained dependent on PD because of RTD with dilated Bowman's capsules lacking the glomerular tuft. This glomerular change, characteristic of severe RTD, was found in three infants with poor outcome [1]. Our observation, together with previous cases, suggests that kidney damage, depending on the severity of RAS inhibition-induced hypotension and/or hypoxia during fetal life, is irreversible and a determinant of outcome, whereas hypocalvaria is reversible.

Downloaded from https://academic.oup.com/ckj/article/4/2/141/329446 by guest on 19 April 2024

Table 1. Review of infants with hypocalvaria and/or RTD after intrauterine exposure to the agents that inhibit RAS[a]

Case	Clinical feature	Inhibitors of RAS	Renal histopathology	Outcome	References
1	ARF, IGR, deformities of hand and foot, oligohydramnios, PH, RD, small calvarial bones	Captopril[b]	RTD, dilated Bowman's capsules	Died after birth	[1]
2	ARF, RD, small calvarial plates	Lisinopril[b]	RTD, dilated Bowman's capsules	Survived with PD	[1]
3	ARF, IGR, large fontanels, oligohydramnios, PH, RD, short arms and legs, widened sutures	Enalapril[b]	RTD, dilated Bowman's capsules	Died after birth	[1]
4	Deformities of limbs and face, HC, oligohydramnios, PH	Losartan[c]	NA	Fetal death	[2]
5	HC, oligohydramnios	Losartan[c]	NA	Survived with normal renal function	[3]
6	ARF, HC, limb deformities, oligohydramnios, RD	Valsartan[c]	NA	Survived with normal renal function	[4]
7	ARF, HC, oligohydramnios, RD (present case)	Olmesartan medoxomil[c]	RTD, dilated Bowman's capsules, lacking glomerular tuft	Survived with PD	

[a]ARF, acute renal failure; HC, hypocalvaria; IGR, intrauterine growth restriction; NA, not available; PD, peritoneal dialysis; PH, pulmonary hypoplasia; RAS, renin-angiotensin system; RD, respiratory distress; RDT, renal tubular dysgenesis.
[b]Angiotensin-converting enzyme inhibitors.
[c]Angiotensin II type-I receptor blocker.

Conflict of interest statement. None declared.

[1]Department of Pediatrics
[2]Department of Urology, Social Insurance Chukyo Hospital, Nagoya, Aichi, Japan
[3]Department of Pediatrics, Anjo Kosei Hospital, Anjo, Aichi, Japan
[4]Department of Developmental Pediatrics, Nagoya University Graduate School of Medicine, Nagoya, Aichi, Japan

Akio Yamada[1]
Yoshikazu Tsuji[2]
Yuich Kato[3]
Norishi Ueda[4]

Correspondence and offprint requests to: Akio Yamada; E-mail: akio_yamada@chukyo-hosp.jp

1. Pryde PG, Sedman AB, Nugent CE, Barr M Jr.. Angiotensin-converting enzyme inhibitor fetopathy. *J Am Soc Nephrol* 1993; 3: 1575–1582
2. Saji H, Yamanaka M, Hagiwara A, Jeri R. Losartan and fetal toxic effects. *Lancet* 2001; 357: 363
3. Nayar B, Singhal A, Aggarwal R, Malhotra N. Losartan induced fetal toxicity. *Indian J Pediatr* 2003; 70: 923–924
4. Vendemmia M, Garcia-Méric P, Rizzotti A *et al.* Fetal and neonatal consequences of antenatal exposure to type 1 angiotensin II receptor-antagonists. *J Matern Fetal Neonatal Med* 2005; 18: 137–140

doi: 10.1093/ndtplus/sfq209

Downloaded from https://academic.oup.com/ckj/article/4/2/141/329446 by guest on 19 April 2024