



Endoscopic ultrasound for perianal Crohn's disease: Disease and fistula characteristics, and impact on therapy

Adi Lahat^{a,*}, Yehudit Assulin^a, Marc Beer-Gabel^a, Yehuda Chowers^b

^a Department of Gastroenterology, Chaim Sheba Medical Center and Sackler School of Medicine, Tel Aviv University, Tel Aviv, Israel

^b Department of Gastroenterology, Rambam Medical Center and the Bruce Rappaport faculty of Medicine, Technion, Haifa, Israel

Received 22 May 2011; received in revised form 22 August 2011; accepted 5 September 2011

KEYWORDS

Perianal Crohn's disease;
Endoscopic ultrasound;
Fistula;
Treatment

Abstract

Background and aim: Appropriate treatment of perianal fistulas in Crohn's disease (CD) involves accurate anatomic evaluation. EUS is an accepted imaging method for this purpose.

The aim of the current study was to evaluate the clinical and endosonographic characteristics of perianal fistula in CD and to assess its impact on therapy.

Methods: All CD patients referred to the Sheba medical center from June 2004 to August 2008 for EUS examination of perianal fistulas were included. Perianal fistulas were diagnosed based on a clinical examination revealing at least one perianal cutaneous orifice. Demographic, clinical and therapeutic data was obtained. EUS was performed using an ultrasound scanner producing a 360° cross sectional image of the anal sphincters.

Results: Fifty six patients were included in the study. Four patients were excluded from the final analysis: 3 because no fistula could be detected by EUS, and one due to inability to tolerate the examination. The mean CD duration was 10 ± 9.16 years (range 1–37). Mean perianal disease duration was 5.3 ± 6.5 (range 1–29) years. 27 patients had perianal involvement at presentation. Among the fistulas diagnosed, 13 were simple (25%) and 39 were (75%) complex.

No correlation was found between CD duration or location, patients' age and gender or fistula location with fistula type or complexity.

EUS results influenced patient management in 86% of the patients.

Conclusions: CD-associated perianal fistulas are mainly complex. EUS is a well tolerated and informative imaging modality, with significant impact on treatment.

© 2011 European Crohn's and Colitis Organisation. Published by Elsevier B.V. All rights reserved.

* Corresponding author at: Department of Gastroenterology, Chaim Sheba Medical Center, Tel Hashomer 52651, Israel. Tel.: +972 3 5302197, +972 6667501(mobile); fax: +972 3 5302060.

E-mail address: zokadi@gmail.com (A. Lahat).

1. Introduction

Crohn's disease (CD) is a chronic inflammatory disorder that may involve any segment of the gastrointestinal tract. Complications of CD include fistula and abscess formation, bowel perforations and fibrotic strictures. CD patients may develop fistulas between different bowel segments (enteroenteric fistula), a bowel segment and the skin (enterocutaneous), or a bowel segment and an adjacent organ (enterovaginal, enterovesical, enterouterine). Perianal fistulas may originate from penetrating rectal ulcers or from inflamed anal canal glands.^{1–3} The overall incidence of fistula formation among CD patients ranges between 17 and 50%,^{4–6} of which 54% are perianal.⁴ Perianal involvement is a cause for significant morbidity and diminished quality of life in these patients. Fistulas are more common in patients with colonic disease, mainly with rectal involvement, but can be found in patients with an intact colon as well. Perianal fistula can be the first manifestation of CD in as many as 10% of patients and in some it precedes the onset of disease by a few years.⁵ Despite the described epidemiology of fistulas in CD, little or no information is available on whether specific disease phenotypes correlate with distinct fistula types or with a particular distribution of simple and complex fistulas. Such information can be one of the factors which affect therapeutic decisions. Diagnosis and management of perianal fistula in CD are still suboptimal. Appropriate treatment involves accurate evaluation of fistula anatomy.¹ Examination under anesthesia (EUA) allows for fistula evaluation, classification and treatment.⁷ However, this technique requires passage of metal probes into the fistula tract under general anesthesia and therapeutic intervention may result in proctectomy. Accordingly, it is recommended to perform imaging prior to surgical intervention.⁷ Therefore, in recent years, less invasive imaging modalities such as pelvic magnetic resonance imaging (MRI) and anorectal Endoscopic ultrasound (EUS) have been used for fistula evaluation. A study comparing the accuracy of MRI and EUS to EUA showed approximately 90% agreement in both modalities. Combining two modalities reached 100% accuracy.⁸

There are relatively few data regarding endosonographic findings in CD-associated perianal fistula imaging and even less information is available regarding the impact of the diagnostic yield of this examination. Therefore, the primary aim of the current study was to evaluate the clinical and endosonographic characteristics of perianal fistula in CD, and to assess the relationship between fistula and disease characteristics. Our secondary aim was to assess the impact of EUS imaging on fistula treatment in a consecutive series of patients.

2. Materials and methods

2.1. Patients

This was a retrospective observational study. All CD patients referred to the Sheba medical center from June 2004 to August 2008 for EUS examination of perianal fistulas were included. Patients presented with single or multiple draining perianal and/or rectovaginal fistulas. Patients were eligible for inclusion if they were previously diagnosed with CD based on endoscopy, radiology and histology findings and if the disease was complicated by single or multiple draining perianal fistulas. Perianal fistulas were diagnosed based on a clinical

examination revealing at least one perianal cutaneous orifice. The patients' demographic, clinical and therapeutic information was obtained for analysis by chart review. The study was approved by the institutional ethical committee.

2.2. EUS

EUS was performed by one of two experienced operators using an ultrasound scanner (Hawk type 2102; B-K Medical, Herlev, Denmark, transducer tip 6004) equipped with a 7-MHz rotating transducer (type 1850, focal range: 2–4.5 cm) covered by a hard sonolucent cone (diameter 1.7 cm) filled with water, producing a 360° cross sectional image of the anal sphincters.

The endoprobe was advanced just beyond the rectum with the patient in the left lateral decubitus position. Serial radial images were performed with slow withdrawal of the scope.

Fistula tracts were visualized as hypoechogenic tubelike lesions. Hydrogen peroxide (3%) was used as a contrast medium after which fistula tracts were seen as bright and hyperechogenic. The following characteristics of the fistula were recorded: classification of the primary fistula tract according to Parks et al.⁹ (intersphincteric, transsphincteric, extrasphincteric, suprasphincteric), presence of secondary tracts, location of the internal opening and fluid collections. Fistulas were classified as complex or simple according to definitions summarized at the American Gastroenterological association (AGA) medical position statement regarding perianal CD.¹⁰ Briefly, a simple fistula was defined as low, has a single external opening, has no associated abscess, and if no evidence for rectovaginal fistula or anorectal stricture was evident. A complex fistula was defined if it was high, or had one or more of the following characteristics; multiple external openings, complicated by an abscess, associated with rectovaginal fistula or anorectal stricture. No sedation was used during the procedures.

Examples of complex versus simple perianal fistulas are shown on Figs. 1 and 2, respectively.

2.3. Statistical analysis

The chi-square test was used to assess the relation between fistula type (simple or complex) and gender, location of disease throughout the GIT and location of fistula (anterior or posterior). The *t* test was used to examine the differences in age, disease duration and duration of perianal disease when comparing between patients with simple or complex fistula. A *p* value <0.05 was considered statistically significant.

3. Results

Fifty six patients were included in the study, 33 men and 23 women. Their mean age was 34.5 ± 12.8 year (range 76–15 years).

Three patients diagnosed as suffering from perianal fistula by clinical examination were excluded from final analysis since the EUS findings did not correlate with this diagnosis. One of these patients was diagnosed as suffering from anterior fibrosis of the IAS (internal anal sphincter) with no active fistula and a Small sphincter defect at 41°, another was found to

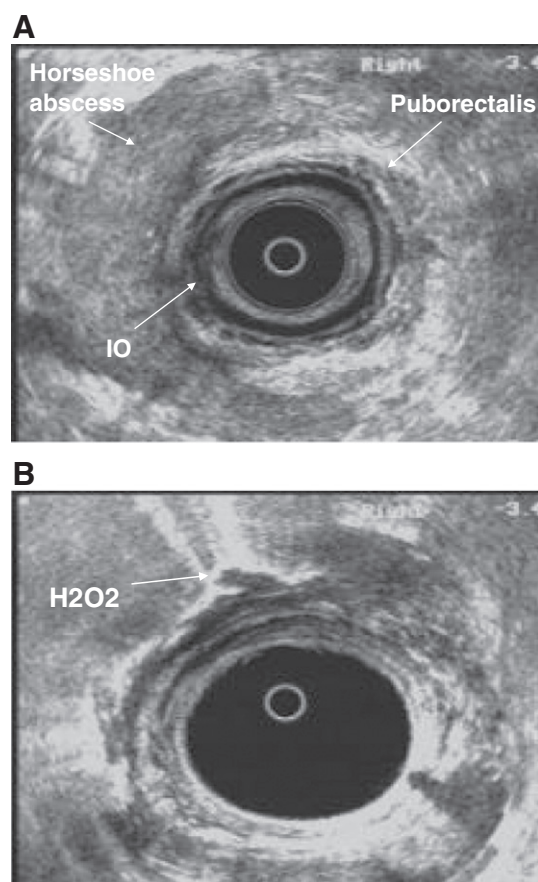


Figure 1 Complex fistula with posterior horseshoe abscess. A complex fistula in a 35 year old patient diagnosed with ileal and perianal disease since 2001. Physical examination revealed a left draining fistula through an external orifice (EO) located 7 cm from the anal margin and another EO in the right gluteus located 7 cm from the anal margin. EUS revealed an internal orifice located high in the IAS (internal anal sphincter) (1A). There was a large, high (at the level of puborectalis muscle) posterior horseshoe abscess linked to the IO (internal orifice) which involved 3/4 of the anal canal circumference (1B). Injection of H₂O₂ into the left EO showed clear communication with both EO (picture 1B) and enhancement of the abscess cavity.

have asymmetry of the external anal sphincter (EAS), and the third patient had small right subcutaneous sinus with no external orifice and no fistula.

One patient was not able to tolerate the examination and was referred to perianal inspection under general anesthesia. Therefore, the final analysis included 52 patients with EUS proven perianal fistula.

3.1. Disease characteristics

Among analyzed patients the mean duration of CD was 10 ± 9.16 years (range 1–37) and the mean duration of perianal symptoms was 5.3 ± 6.5 (range 1–29) years. Twenty seven patients had perianal involvement at presentation. In five patients perianal disease preceded the diagnosis of CD. Most of the patients had CD with colonic involvement; either

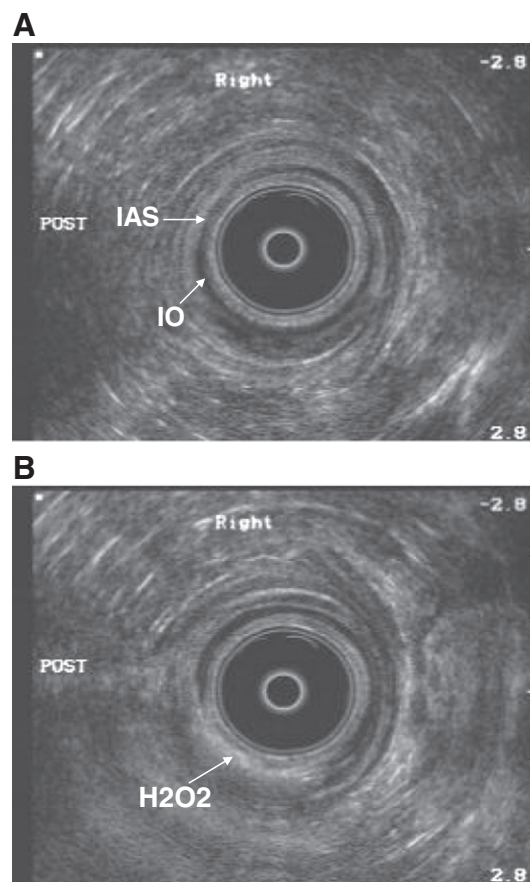


Figure 2 Simple low trans-sphincteric fistula. A simple, low trans-sphincteric fistula in a 17 year old patient diagnosed with ileal and perianal disease since 2005. Physical examination showed an external orifice located 3 cm from the left anal margin. EUS showed an internal orifice (IO) located at the mid IAS (internal anal sphincter) on the left (2A). Enhancement of fistulous tract after injection of H₂O₂ (2B).

isolated,¹⁴ or combined with ileal involvement (20). Eighteen patients had ileal disease only (Table 1).

At the time of EUS performance, twenty two patients (42.3%) were treated with immunosuppressive agents including azathioprine or 6-mercaptopurine (22) either alone⁹ or in combination with other drugs.¹³ Fifteen patients (28.8%) received infliximab only,⁶ or in combination with other drugs.⁹ Nine patients were treated with antibiotics such as metronidazole and/or ciprofloxacin (Four patients with antibiotics only and 6 patients combined with other drugs), 4 patients received steroids, all in combination with other drugs. Twelve patients were treated with 5-ASA; 7 as a single agent and 5

Table 1 Disease characteristics.

Timing of perianal disease, n (%)	Proceeding CD diagnosis 5 (9.6)	At presentation 27 (52)	During disease course 20 (38.4)
Disease location n (%)	Terminal ileum 18 (34.6)	Colon 14 (27)	Ileocolon 20 (38.5)

in combination with other drugs. Five patients were not receiving any treatment at the time of the examination.

Detailed disease characteristics regarding perianal disease timing, disease location and treatments are shown in Tables 1 and 2, respectively.

3.2. EUS characteristics

Complete EUS examination was feasible in 55 of the 56 patients enrolled. In one patient the procedure had to be stopped due to excessive pain.

Injection of H₂O₂ was feasible in 19 (34%) of patients. Among the fistulas diagnosed, 13 were simple (25%) and 39 (75%) were complex fistulas. The morphologic characteristics of the simple and complex fistulas are shown in Tables 3 and 4, respectively.

3.3. Correlation between fistula characteristics, disease characteristics and patient demography

The duration of perianal disease or time from CD diagnosis and disease location were not correlated with type of fistulas or their complexity. Seventy four percent of patients with ileocolonic or colonic disease had complex fistula, compared to 72% of patients with ileal disease only ($p=ns$).

Neither the age nor the gender of patients correlated with type or complexity of fistulas. Fistula location (anterior vs. posterior) did not correlate with their type or complexity.

3.4. Impact on therapy

At the time of the study, all treatment decisions were taken only after perianal imaging and consideration of EUS results. The impact of the examination on therapy was defined as a therapeutic decision that was affected by EUS results. In our cohort the management of 45 patients (80% of patients enrolled and 86% of patients with fistula on EUS) was affected by the EUS findings. Treatment decisions according to EUS findings are summarized in Table 5. As shown, in 17 patients EUS detected an undrained abscess which was not suspected previously based on physical examination or laboratory results. Abscess detection led to therapeutic interventions that included abscess drainage in all patients, and seton insertion after drainage in 10 patients out of 17. In 13 out of 17 patients with a complex fistula in which an undrained abscess was not detected, the results of the EUS enabled a safe start

Table 3 Morphologic characteristics of simple fistulas (n=13).

Inj H2O2	Sub div	Seton	Location	Low/high
Yes 3	Trans 7	Yes 4	Ant 8	Low 13
No 10	Inter 5 Extra 1	No 19	Post 5	

of anti TNF- α treatment without fearing septic complications. In four patients from this group the characterization of fistula anatomy and the absence of abscess enabled curative surgical treatment (2 patients) or usage of biologic glue for this purpose (2 patients). In 11 patients a simple fistula without abscess was detected. Of these, in three patients the fistula anatomy (low, shallow fistula) made the seton superfluous, and the seton was removed. In 8 patients the simple anatomy of the fistula guided the treating physician to choose a more traditional therapy (immunomodulators and antibiotics) rather than anti-TNF agents.

Patients in whom treatment was unchanged included: patients in whom no abscess was found,³ patients with small, simple asymptomatic fistula⁷ and a patient with incomplete examination.¹

4. Discussion

In this study the ultrasonic characteristics of perianal fistula in CD patients were assessed. We observed that the majority of fistulas were complex, and that fistula characteristics did not correlate with disease characteristics. Furthermore, the results of the ultrasonic examination had an important impact on patient care.

We observed that 75% of the fistulas were complex, 44% were associated with abscesses and that 32 patients (61%) had undergone at least one perianal surgery. The high percent of complex fistulas in our study is in agreement with a recent study,¹¹ in which 22 patients out of 34 (65%) had complex fistulas as well. However, in the current study further information regarding fistula morphology and precise location is added.

Three out of 23 (13%) women suffered from a rectovaginal fistula, and none had anolabial fistula. This frequency is lower compared to that found by Ng et al.¹¹ – where 5 patients out of 22 women (23%) had rectovaginal fistula and 2 patients (9%) had anolabial fistulas. The existence of complex perianal

Table 2 Medical therapy at the time of EUS.

Drug	Total n (%)	Single treatment (%)	Combination therapy (%)
5-ASA	12 (23)	7 (13.5)	5 (9.6)
Steroids	4 (7.7)	0	4 (7.7)
Antibiotics (metronidazole \pm ciprofloxacin)	10 (19.2)	4 (7.7)	6 (11.5)
Immunomodulators	22 (42)	9 (17)	13 (25)
Infliximab	15 (28.8)	6 (11.5)	9 (17)

Table 4 Morphologic characteristics of complex fistulas (n=39).

Inj H2O2	Sub div	Seton	Abscess	Location	Low/high
Yes 16	Trans 16	Yes 11	Yes 23	Ant 19	Low 26
No 23	Inter 10 Extra 1	No 28	No 16	Post 19	High 13
.	Horseshoe 8 Rectovag 3 Horseshoe + rectovag 1			Ant + post 1	

Table 5 Treatment decisions according to EUS findings.

EUS findings	Undrained abscess	Complex fistula without undrained abscess	Simple fistula without undrained abscess
Treatment	Abscess drainage ± seton insertion—17 patients	Anti TNF treatment—13 patients Operation/biologic glue for fistula closure—4 patients	Antibiotic/Immunomodulators for fistula closure—8 patients Seton removal—3 patients

fistula cannot be predicted by disease characteristics such as duration of CD, duration of perianal disease, or the location of CD in small or large bowel. This observation reiterates the importance of imaging in addition to clinical assessment.

Indeed, clinical assessment of fistulas is suboptimal and imaging is considered necessary for complete evaluation. For example, while determining treatment results using MRI, both Bell et al.¹² and Van Assche et al.¹³ observed that in many patients treated with infliximab the fistula track persisted despite external coetaneous healing.

Furthermore, in two recent studies, fistula imaging was shown to be beneficial not only for assessment of treatment outcome, but also for management decisions.^{14,15} In these studies, EUS results were used to guide medical and surgical therapeutic decisions (e.g. when to remove the seton drainage or to stop medical treatment) with a clear beneficial effect. This conclusion is also supported by the ECCO (European Crohn's and Colitis Organization) guidelines for the management of CD, which recommend imaging with MRI or EUS for all fistulas for which medical and/or surgical treatment is considered¹⁶ and by the AGA technical report for treating fistulizing CD⁷ as well. The results of our study support the importance of imaging and emphasize the complexity of perianal fistulas in CD.

In our observational study, EUS results were used to guide therapeutic decisions. The fact that treatment was guided by EUS results in 86% of patients with perianal fistula emphasizes the significant impact of this imaging modality on therapy and the importance of precise anatomic characterization of the fistula for tailoring patient-specific treatments. Although such conclusion was better supported by a randomized study comparing treatment with or without imaging and not in an observational study, current guidelines and the preliminary results of others make such a study ethically challenging.

This study had a number of weaknesses. A possible referral bias may have occurred because of the tertiary nature of the department. Additionally, patients in our series were referred for EUS by a variety of physicians, some of them working in other medical centers. This prevented the performance of routine long term follow up. Finally, the observational nature of the study combined with the fact that no comparison to other imaging modalities was performed, prohibits assessment of the relative impact of EUS compared to other imaging techniques. Our patients did not undergo other imaging modalities. According to literature, combining two imaging modalities reached an accuracy of 100%, and this is considered to be the diagnostic gold standard.⁸ However, in common practice it is not always feasible. In the aforementioned publication EUS alone reached 91% accuracy. Furthermore, both Spradlin et al. and Schwartz et al.^{14,15} used EUS only for guiding

therapeutic decisions. Others have used pelvic MRI as a single modality,^{12,13} indicating that the use of a single modality is common.

In conclusion, CD-associated perianal fistulas are mainly complex, and necessitate precise anatomic demonstration for optimizing therapeutic decisions. EUS is a well tolerated highly accurate imaging modality, resulting in a significant therapeutic impact.

Acknowledgments

Adi Lahat performed data collection, analysis of data and drafted the manuscript.

Yehudit Assulin performed the EUS examinations, data collection and statistical analysis.

Marc Beer-Gabel performed the EUS examinations, data collection and participated in the design of the study.

Yehuda Chowers conceived of the study, participated in its design and helped drafting the manuscript.

References

1. Judge TA, Lichtenstein GR. Treatment of fistulizing Crohn's disease. *Gastroenterol Clin North Am* 2004;**33**:421–54.
2. Schwartz DA, Pemberton JH, Sandborn WJ. Diagnosis and treatment of perianal fistulas in Crohn disease. *Ann Intern Med* 2001;**135**:906–18.
3. Schwartz DA, Herdman CR. Review article: the medical treatment of Crohn's perianal fistulas. *Aliment Pharmacol Ther* 2004;**19**:953–67.
4. Schwartz DA, Loftus Jr EV, Tremaine WJ, Panaccione R, Harmsen WS, Zinsmeister AR, et al. The natural history of fistulizing Crohn's disease in Olmsted County, Minnesota. *Gastroenterology* 2002;**122**:875–80.
5. Hellers G, Bergstrand O, Ewerth S, Holmström B. Occurrence and outcome after primary treatment of anal fistulae in Crohn's disease. *Gut* 1980;**21**:525–7.
6. Solomon MJ. Fistulae and abscesses in symptomatic perianal Crohn's disease. *Int J Colorectal Dis* 1996;**11**:222–6.
7. Sandborn WJ, Fazio VW, Feagan BG, Hanauer SB. American Gastroenterological Association Clinical Practice Committee. AGA technical review on perianal Crohn's disease. *Gastroenterology* 2003;**125**:1508–30.
8. Schwartz DA, Wiersema MJ, Dudiak KM, Fletcher JG, Clain JE, Tremaine WJ, et al. A comparison of endoscopic ultrasound, magnetic resonance imaging, and exam under anesthesia for evaluation of Crohn's perianal fistulas. *Gastroenterology* 2001;**121**:1064–72.
9. Parks AG, Gordon PH, Hardcastle JD. A classification of fistula-in-ano. *Br J Surg* 1976;**63**(1):1–12.

10. American Gastroenterological Association medical position statement. Perianal Crohn's disease. *Gastroenterology* 2003;**125**: 1503–7.
11. Ng SC, Plamondon S, Gupta A, Burling D, Swatton A, Vaizey CJ, et al. Prospective evaluation of anti-tumor necrosis factor therapy guided by magnetic resonance imaging for Crohn's perineal fistulas. *Am J Gastroenterol* 2009;**104**:2973–80.
12. Bell SJ, Halligan S, Windsor ACJ, Williams AB, Wiesel P, Kamm MA. Response of fistulating Crohn's disease to infliximab treatment assessed by magnetic resonance imaging. *Aliment Pharmacol Ther* 2003;**17**:387–93.
13. Van Assche G, Vanbeckevoort D, Bielen D, Coremans G, Aerden I, Noman M, et al. Magnetic resonance imaging of the effects of infliximab on perianal fistulizing Crohn's disease. *Am J Gastroenterol* 2003;**98**:332–9.
14. Spradlin NM, Wise PE, Herline AJ, Muldoon RL, Rosen M, Schwartz DA. A randomized prospective trial of endoscopic ultrasound to guide combination medical and surgical treatment for Crohn's perianal fistulas. *Am J Gastroenterol* 2008;**103**(10):2527–35.
15. Schwartz DA, White CM, Wise PE, Herline AJ. Use of endoscopic ultrasound to guide combination medical and surgical therapy for patients with Crohn's perianal fistulas. *Inflamm Bowel Dis* 2005;**11**(8):727–32.
16. Caprilli R, Gassull MA, Escher JC, et al. European evidence based consensus on the diagnosis and management of Crohn's disease: special situations. *Gut* 2006;**55**(Suppl 1):i36–58.