



Effect of intensive granulocyte and monocyte adsorptive apheresis in patients with ulcerative colitis positive for cytomegalovirus

Takumi Fukuchi ^a, Hiroshi Nakase ^{b,*}, Minoru Matsuura ^b, Takuya Yoshino ^b, Takahiko Toyonaga ^b, Katsuyuki Ohmori ^c, Satoshi Ubukata ^a, Aya Ueda ^a, Takaaki Eguchi ^a, Hiroshi Yamashita ^a, Dai Ito ^a, Kiyoshi Ashida ^a

^a Department of Gastroenterology and Hepatology, Osakafu Saiseikai Nakatsu Hospital, Osaka, Japan

^b Department of Gastroenterology and Hepatology, Graduate School of Medicine, Kyoto University Hospital, Kyoto, Japan

^c Department of Clinical Laboratory, Graduate School of Medicine, Kyoto University Hospital, Kyoto, Japan

Received 30 August 2012; received in revised form 17 November 2012; accepted 6 December 2012

KEYWORDS

Ulcerative colitis;
Granulocyte and monocyte
adsorptive apheresis;
Cytomegalovirus

Abstract

Background and aim: Cytomegalovirus (CMV) exacerbates ulcerative colitis (UC) refractory to immunosuppressive therapies. The conditions under which CMV reactivation occurs in patients with UC, however, is unclear. In addition, the diagnostic and treatment strategies for UC positive for CMV have not been established. Granulocyte and monocyte adsorptive apheresis (GMAA) is natural biological therapy for UC in which the granulocytes/macrophages producing inflammatory cytokines are removed. We investigated the rate of colonic CMV reactivation and the efficacy of GMAA in active UC patients positive for CMV without concomitant corticosteroid (CS) therapy.

Methods: Fifty-one active UC patients without concomitant CS therapy were enrolled. Colonic CMV reactivation was examined by real-time polymerase chain reaction (PCR) using biopsy specimen and/or histological examination. All patients were treated with intensive GMAA (twice per week). Rates of clinical remission and mucosal healing were compared between UC patients positive and negative for CMV.

Results: Of 51 patients, 15 (29.4%) were diagnosed as CMV positive. The clinical remission rates following intensive GMAA did not differ between UC patients positive and negative for CMV (73.3% vs 69.4%, $p=0.781$). Proportion of patients achieving mucosal healing was also similar

* Corresponding author at: Department of Gastroenterology and Hepatology, Graduate School of Medicine, Kyoto university Hospital, 54 Kawahara-cho, Shogoin, Sakyo-ku, Kyoto, 606-8507, Japan. Tel.: +81 75 751 4319; fax: +81 75 751 4303.

E-mail addresses: takuleotakuleo@yahoo.co.jp (T. Fukuchi), hiropy_n@kuhp.kyoto-u.ac.jp (H. Nakase), minomats@kuhp.kyoto-u.ac.jp (M. Matsuura), takuyayoshino@gmail.com (T. Yoshino), toyo.necco@gmail.com (T. Toyonaga), ohmori@kuhp.kyoto-u.ac.jp (K. Ohmori), fgdnq486@yahoo.co.jp (S. Ubukata), ejieji@hotmail.co.jp (A. Ueda), egugu0515@yahoo.co.jp (T. Eguchi), onakaryoko@gmail.com (H. Yamashita), daiito0423@yahoo.co.jp (D. Ito), 25001@nakatsu.saiseikai.or.jp (K. Ashida).

between these two groups. CMV-DNA became negative in all UC patients positive for CMV who achieved clinical remission 1 week after completion of intensive GMAA.

Conclusions: Intestinal inflammation might trigger CMV reactivation in a subpopulation of active UC patients without CS treatment. GMAA could be a promising option for active UC positive for CMV.

© 2012 European Crohn's and Colitis Organisation. Published by Elsevier B.V. All rights reserved.

1. Introduction

Cytomegalovirus (CMV) is a double-stranded DNA virus and a member of the human herpes virus family.¹ CMV infection is a common viral infection in humans, occurring in approximately 50% to 80% of adults, depending on the population studied.^{2–4} Once the infection is acquired, CMV infection persists in a latent state, similar to other herpes virus infections.^{4–7} Viral replication of CMV, however, can be reactivated under conditions of immunosuppression, such as organ transplantation and immunosuppressive treatment.^{4–6} The pathogenicity of CMV in a flare-up of ulcerative colitis (UC) remains unclear, but colonic CMV reactivation is considered to be an exacerbating factor in patients with UC patients refractory to immunosuppressive therapies because of the poor prognosis of UC patients with concomitant CMV infection.^{4,8–12} Furthermore, in addition to immunosuppressive treatment, the disease activity itself can predispose patients with UC to reactivation of latent CMV in the colonic tissues.^{8,9} Therefore, it is very important to establish optimal modalities of diagnosing colonic CMV reactivation.

Among the various modalities used to diagnose CMV infection, histological examination, including inclusion body and immunohistochemistry (IHC) for CMV, together with virological analysis using peripheral blood samples, such as serology, blood CMV viral load determined by antigenemia, and quantitative real-time polymerase chain reaction (PCR), have been mainstays of the diagnosis. In contrast, real-time PCR assay using colonic tissues samples (tissue PCR) is recommended by the European Crohn's and Colitis Organization guidelines as an alternative to IHC for CMV to investigate the presence of colonic CMV reactivation in immunomodulatory refractory cases of inflammatory bowel disease (IBD), because the CMV-DNA load can be high in colonic tissue even when IHC and other modalities using peripheral blood samples for CMV infection are all negative.⁴ Yoshino et al. reported the usefulness of quantitative real-time PCR assays using colonic biopsy specimens for early detection of colonic CMV reactivation in patients with refractory UC, and demonstrated that colonic CMV reactivation occurred mainly in inflamed colonic mucosa.¹³ Furthermore, Roblin et al. recently reported that CMV-DNA was detected in inflamed intestinal tissues whereas no trace of the CMV-DNA was detected in the endoscopically normal colonic tissue.¹⁴ Of note, the patients enrolled in their study were all naïve to intravenous corticosteroids or cyclosporine treatment, which generally lead to colonic CMV reactivation with histological lesions. These data suggest that colonic CMV reactivation in inflamed tissue might easily occur in a subpopulation of active UC patients without immunosuppressive treatment, depending on their immune condition. Therefore, it is clinically important to check the CMV-DNA load in colonic tissue for monitoring CMV

infection and selecting anti-inflammatory therapy without stimulating CMV reactivation.

Granulocyte and monocyte adsorptive apheresis (GMAA) is an extracorporeal therapy performed with the Adacolumn (JIMRO, Gunma, Japan), which selectively depletes granulocytes and monocytes from the peripheral blood.^{15–17} Several previous studies reported achieving a high remission rate in patients with active UC following GMAA therapy, and Sakuraba's group and our data suggest that intensive GMAA (twice per week) induces higher clinical and endoscopic remission compared with weekly GMAA.^{18,19} In addition, our recent data and previous case series revealed that GMAA could be a suitable therapeutic option for patients with active UC prior to starting corticosteroid (CS) therapy because of a striking difference in the clinical response to GMAA between steroid-naïve and steroid-dependent patients.^{19–21} Furthermore, it was recently reported that GMAA could be safe for UC patients with a history of CMV infection due to the avoidance of colonic CMV reactivation compared with UC patients treated with immunosuppressive drugs.²² Theoretically, GMAA removes granulocytes and monocytes/macrophages, where CMV infection is latent and reactivates. GMAA does not affect colonic CMV reactivation. These findings together suggest that intensive GMAA might be optimal therapy for the induction of remission in UC patients with colonic CMV reactivation.

In the present study, we investigated (1) the rate of CMV infection in UC patients not receiving corticosteroids by using tissue PCR, and (2) compared the efficacy and safety of intensive GMAA between UC patients with CMV infection and UC patients without CMV infection.

2. Materials and methods

2.1. Patients

From January 2010 to July 2011, a total of 51 patients with moderate to severe active UC were enrolled in this study. The diagnosis of UC was based on clinical, endoscopic, radiological, and histological findings. Fecal bacterial culture yielded no specific pathogens in any of the patients. Patients with UC who were older than 17 years were consecutively recruited if they had newly or relapsing active disease. None of the patients had received corticosteroid treatment. Moderate to severe active UC was defined as a Clinical Activity Index (CAI)²³ higher than 7.

2.2. Assessment of endoscopic severity

Endoscopic severity of UC was assessed using the Mayo Endoscopic Score²⁴ (Mayo-ES) as follows: normal or inactive

disease = score 0; erythema, decrease of vascular pattern and mild friability as mild disease = score 1; marked erythema, lack of vascular pattern, friability, erosions as moderate disease = score 2; spontaneous bleeding and ulceration as severe disease = score 3.

2.3. CMV antigenemia

The antigenemia assay was performed using a monoclonal antibody against a CMV structural protein of the 65 kDa lower-matrix phosphoprotein (C7HRP or C10C11).

2.4. Histopathological examination

Colonic biopsy specimens were obtained from inflamed colonic mucosa, fixed in formalin, embedded in paraffin, and stained with hematoxylin and eosin (H&E), and IHC was performed using anti-CMV monoclonal antibodies (clones: DDG9/CCH2, DAKO, Tokyo, Japan).^{25,26} The results positive for CMV in IHC were further categorized as typical if the CMV IHC-positive cells had nuclear enlargement, and negative if CMV-positive IHC staining was not seen.²⁶

2.5. Quantitative real-time PCR in inflamed colonic mucosa (mucosal-PCR)

DNA for the real-time PCR assay was extracted from inflamed colonic mucosa obtained at endoscopic examination using a QIAamp DNA Blood Mini Kit (Qiagen, Tokyo, Japan) according to the manufacturer's instructions. The assay was performed using an ABI Prism 7700 Sequence Detector System (PerkinElmer Applied Biosystems, San Jose, CA) as described previously.⁷ Oligonucleotide primers specific for the immediate early gene were used for CMV-DNA amplification. The sequence of the upstream primer was 5'-GACTAGTGTGATGCTGGCCAAG-3', and that of the downstream primer was 5'-GCTACAATAGCCTCTT CCTCATCTG-3'. The 6-carboxyfluorescein-labeled probe was 5'-AGCCTGAGGTTATCAGTGAATGAAGCGCC-3'. The PCR conditions were as follows: incubation at 95°C for 10 min, 50 cycles of 95°C for 15 s, followed by incubation at 62°C for 1 min. Cases in which the CMV-DNA copy number was over 10 copies/ μ g DNA were defined as positive for CMV infection.^{12,22}

2.6. Diagnosis of colonic CMV reactivation

Cases in which CMV was detected by at least one of the two methods above (histological examination with immunohistochemistry and/or quantitative real-time PCR) were diagnosed as positive for colonic CMV reactivation.

2.7. Treatment

Intensive GMAA treatments were performed as previously described with no CS therapy and no antiviral therapy, irrespective of whether the patients were CMV positive or negative.^{18,19} The maximum number of GMAA sessions allowed was 10 (Fig. 1). Blood access was obtained through the antecubital vein in one arm, and the return to the patient was through the antecubital vein in the contralateral arm, both through a 19-gauge needle. GMAA was performed

at a flow rate of 30 mL/min for 60 min, with the aim to expose 1800 mL blood/session (one session). None of the UC patients positive for CMV received antiviral therapy, and adverse events were recorded at each visit during intensive GMAA.

2.8. Assessment

We investigated the detection rate of colonic CMV reactivation in patients with moderate to severe UC and without CS. Next, we examined the clinical factors related to colonic CMV reactivation by comparing several clinical parameters between CMV-positive and CMV-negative UC patients. Moreover, we evaluated the efficacy of intensive GMAA between those patients. The primary efficacy of intensive GMAA was evaluated based on the clinical remission rate at weeks 2, 4, and 6. Clinical remission was defined as CAI \leq 4. Secondary efficacy was evaluated based on the Mayo-ES. We compared the Mayo-ES between CMV-positive and CMV-negative UC patients at 1 week after the completion of intensive GMAA. The proportion of patients with mucosal healing 1 week after the completion of intensive GMAA was determined. Mucosal healing was defined as Mayo-ES of 0 or 1, in accordance with the report of Rutgeets et al. and our group.^{19,27}

2.9. Statistical analysis

Data are presented as mean \pm SE. Categorical and continuous data were compared using a two-tailed Fisher exact test and Student's *t*-test. A *p* value of less than 0.05 was considered statistically significant.

Table 1 Clinical characteristics of 51 patients with active UC without corticosteroids.

Age (years)	38.2 \pm 2.2
Sex (male/female)	27/24
Disease duration (months)	53.3 \pm 10.8
Disease location	
Left-sided	44 (86.3)
Pancolitis	7 (13.7)
Clinical Activity Index	10.4 \pm 0.5
Mayo Endoscopic Score	2.3 \pm 0.1
Previous treatment	
5-ASA	
No. patients	29 (56.9)
Dose (mg/day)	1549.0 \pm 201.6
AZA/6MP	
No. patients	14 (27.5)
Dose (mg/day)	10.4 \pm 2.7

Number of patients is shown for sex, disease location, and No. patients of previous treatment with 5-ASA and AZA/6-MP. Data are presented as mean \pm SE for age, disease duration, Clinical Activity Index, Mayo Endoscopic Score, and dose of previous treatment with 5-ASA and AZA/6MP. 5-ASA, 5-aminosalicylate acid; AZA, azathioprine; 6MP, 6-mercaptopurine. Values in parentheses are percentages of all 51 patients with UC.

Table 2 Detection rate of cytomegalovirus (CMV) infection in patients with active UC without corticosteroids.

CMV infection	No. patients	CMV-DNA		IHC	H&E	Antigenemia
		Inflamed mucosa	Non-inflamed mucosa			
Positive	15	15 (100%)	0	3 (20.0%)	0	1 (6.7%)
Negative	36	0	0	0	0	0
Total	51	15 (29.4%)	0	3 (5.9%)	0	1 (2.0%)

Number of patients is shown. IHC, immunohistochemistry; H&E, hematoxylin and eosin. Values in parenthesis on horizontal line of CMV positive are percentages of all 15 patients with UC positive for CMV. Values in parenthesis on horizontal line of CMV negative are percentages of all 36 patients with UC negative for CMV. Values in parenthesis on horizontal line of total are percentages of all 51 patients with UC.

3. Results

3.1. Clinical characteristics

The clinical characteristics of 51 UC patients without CS therapy are summarized in Table 1. Mean patient age was 38.2 ± 2.1 years old (range 17–62 years), and mean CAI was 10.4 ± 0.5 . The extent of the disease was pancolitis (13.7%) and left-sided colitis (86.3%). The mean Mayo-ES was 2.29 ± 0.06 . Of the 51 patients, 29 patients (56.9%) had been treated with 5-aminosalicylate acid (5-ASA) and 14 patients (27.5%) had

been treated with azathioprine (AZA)/6-mercaptopurine (6MP) (Table 1).

3.2. Detection rate of CMV infection in active UC patients without CS therapy

Of the 51 patients, 15 (29.4%) were diagnosed as positive for colonic CMV reactivation (Table 2). CMV-DNA was detected in the inflamed colonic mucosa of all 15 patients, and histological examination was positive in three (6.7%) of these UC patients. Patients negative for CMV-DNA in the colonic mucosa were negative for both CMV antigenemia and histologic examination.

3.3. Differences in the clinical parameters between UC patients without CS therapy positive or negative for CMV

We compared differences in the age, sex, disease location, CAI, and Mayo-ES between CMV-positive and CMV-negative UC patients. Other than disease duration, these clinical parameters did not differ between groups (Table 3). Importantly, the positive rate of CMV-DNA was significantly lower in UC patients treated with AZA/6MP than in those without (Table 3).

Table 3 Comparison of clinical parameters of patients with active UC positive for CMV treated by intensive granulocyte and monocyte adsorptive apheresis (GMAA) with no corticosteroids between diagnosed cytomegalovirus positive and negative.

	CMV positive (n = 15)	CMV negative (n = 36)	p-value
Age (years)	42.9 ± 3.8	36.2 ± 2.4	0.14
Sex (male/female)	7/8	20/16	0.562
Disease duration (months)	18.7 ± 7.1	67.8 ± 14.4	0.037
Disease location			
Left-sided	13 (86.7)	31 (86.1)	0.958
Pancolitis	2 (13.3)	5 (13.9)	
Previous treatment			
5-ASA			
No. patients	6 (40.0)	23 (63.9)	0.117
Dose (mg/day)	1233.3 ± 421.5	1680.6 ± 225.7	0.317
AZA/6-MP			
No. patients	1 (6.7)	13 (36.1)	0.032
Dose (mg/day)	1.7 ± 1.7	14.0 ± 3.6	0.037
Clinical Activity Index	10.3 ± 0.8	10.4 ± 0.6	0.959
Mayo Endoscopic Score	2.2 ± 0.1	2.3 ± 0.1	0.786

Number of patients is shown for sex, disease location, and No. patients of previous treatment with 5-ASA and AZA/6-MP. Data are presented as mean \pm SE for age, disease duration, dose of previous treatment with 5-ASA and AZA/6-MP, Clinical Activity Index and Mayo Endoscopic Score. 5-ASA, 5-aminosalicylate; AZA, azathioprine; 6-MP, 6-mercaptopurine. Values in parenthesis on vertical line of CMV positive are percentages of all 15 patients with UC positive for CMV. Values in parentheses on vertical line of CMV negative are percentages of all 36 patients with UC negative for CMV.

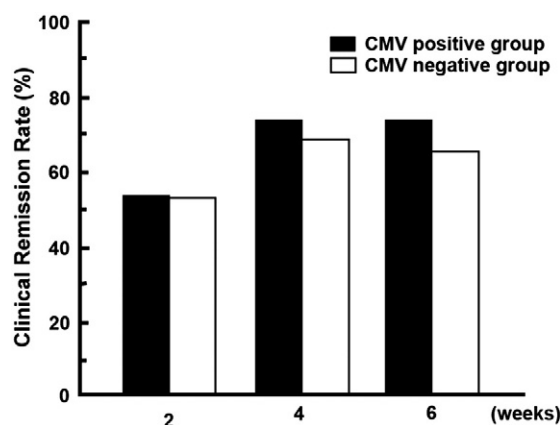


Figure 1 The clinical remission rate following intensive GMAA. There was no significant difference in the clinical remission rate following intensive GMAA treatment between UC patients positive for cytomegalovirus (CMV) and UC patients negative for CMV.

3.4. Clinical efficacy of intensive GMAA treatment

Two weeks after starting intensive GMAA, 53.3% of UC patients that were CMV positive went into clinical remission compared with 52.7% of those who were CMV negative. At 6 weeks, 73.3% of the UC patients positive for CMV receiving intensive GMAA had a clinical remission in comparison with 69.4% of those negative for CMV ($p=0.781$). There was no significant difference in the clinical remission rate following treatment with intensive GMAA between UC patients that were CMV positive and those that were CMV negative (Fig. 1). Mean time to clinical remission was 17.8 ± 2.0 days in UC patients that were CMV positive and 20.0 ± 1.8 days for those that were CMV negative ($p=0.496$). Mean number of GMAA sessions to clinical remission was 5.1 ± 0.6 sessions in UC patients that were CMV positive and 5.7 ± 0.4 sessions for those that were CMV negative ($p=0.420$). One patient transiently complained of headache and nausea. No other serious side effects were observed throughout intensive GMAA treatment.

3.5. Mucosal healing induced by intensive GMAA treatment

We investigated the association between the efficacy of intensive GMAA on mucosal healing and CMV infection in patients with UC. Upon initiating intensive GMAA, the Mayo-ES was 2.2 ± 0.1 in patients with UC that were CMV-positive and 2.3 ± 0.1 in those that were CMV-negative ($p=0.786$; Table 3). At 1 week after the completion of intensive GMAA, the Mayo-ES was 1.1 ± 0.3 in UC patients that were CMV-positive and 1.0 ± 0.2 in those that were CMV-negative ($p=0.829$; Fig. 2A). There was no significant difference in the proportion of patients who achieved mucosal healing by intensive GMAA between patients with

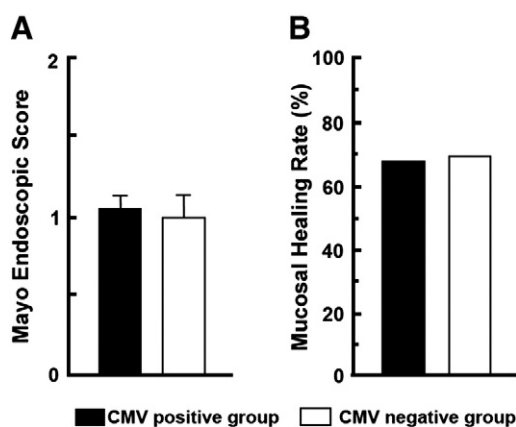


Figure 2 Mayo Endoscopic Score and mucosal healing rate 1 week after the completion of intensive GMAA treatment. The Mayo Endoscopic Score was not significantly different 1 week after completing the intensive GMAA treatment between UC patients that were CMV-positive and those that were CMV-negative (A). The mucosal healing rate was not significantly different 1 week after completing the intensive GMAA treatment between UC patients that were CMV-positive and those that were CMV-negative (B).

UC that were positive or negative for CMV (66.7% vs. 69.4%, $p=0.846$; Fig. 2B).

3.6. Disappearance of CMV infection after intensive GMAA treatment in UC patients positive for CMV

To evaluate the effect of intensive GMAA on CMV infection in patients with UC, we compared the CMV-DNA load before and after intensive GMAA. At 1 week after the completion of intensive GMAA, 11 of 15 patients positive for CMV (73.3%) became negative for CMV (Table 4). In addition, all of these 11 patients achieved clinical remission only 1 week after the completion of intensive GMAA. Moreover, 10 of 11 patients (90.9%) simultaneously achieved mucosal healing (Table 4; Cases 1–11). On the other hand, four patients who were still positive for CMV at 1 week after the completion of intensive GMAA did not achieve clinical remission (Table 4; Cases 12–15).

Moreover, we observed the clinical outcome of patients with positive IHC in comparison with those with negative IHC. Two of 3 UC patients (66.7%) with CMV-DNA (+)/IHC (+), who achieved clinical remission and mucosal healing, became negative for both CMV-DNA and IHC after GMAA (Table 4; Cases 1, 2), while the remaining one, who could not achieve clinical remission and mucosal healing, was still positive for both CMV-DNA and IHC (Table 4; Cases 12). On the other hand, 9 of 12 patients (75%) with CMV-DNA (+)/IHC (–) achieved clinical remission after GMAA and 8 of those (66.7%) achieved mucosal healing (Table 4; Cases 3–10, 13–15). In this study, we could not observe any difference of the effect of GMAA between the UC patients with CMV-DNA (+)/IHC (+) and those with CMV-DNA (+)/IHC (–).

3.7. The factors associated with CMV persistence or clearance by intensive GMAA in patients with UC positive for CMV before treatment

We compared as age, sex, disease duration, disease location, previous treatment, copy numbers of mucosal-PCR, IHC positive rate, CAI and Mayo-ES between UC patients positive for CMV before treatment CMV persistence and clearance at 1 week after the completion of intensive GMAA. However, possible clinical factors associated with CMV persistence were not identified in this study (Table 5).

4. Discussion

The findings of the present study revealed that colonic CMV reactivation occurred in the inflamed colonic mucosa of patients with active UC that were not receiving CS therapy. Intensive GMAA was safe and effective for inducing rapid clinical remission in UC patients positive for CMV, resulting in the disappearance of CMV-DNA in their colonic mucosa. Further, our findings suggested that intestinal inflammation of UC could trigger the colonic CMV reactivation whether or not immunosuppressive therapies were used, and that GMAA is a promising therapy for UC with concomitant CMV infection and does not reactivate CMV.

CMV infection is a well-known complication in immunosuppressed patients, such as after bone marrow trans-

Table 4 Change in the Clinical Activity Index, Mayo Endoscopic Score, CMV-DNA and IHC in inflamed mucosa in 15 patients with UC positive for CMV following intensive GMAA.

	CAI		Mayo-ES		CMV-DNA (copies/ μ g DNA)		IHC	
	Before GMAA	After GMAA	Before GMAA	After GMAA	Before GMAA	After GMAA	Before GMAA	After GMAA
Case 1	9	3	3	1	10	0	+	-
Case 2	7	1	2	0	10	0	+	-
Case 3	15	1	3	0	260	0	-	-
Case 4	16	1	2	0	2800	0	-	-
Case 5	9	1	2	0	550	0	-	-
Case 6	9	1	2	0	80	0	-	-
Case 7	8	1	2	0	29,000	0	-	-
Case 8	12	3	2	1	790	0	-	-
Case 9	10	2	3	0	44,000	0	-	-
Case 10	7	3	2	0	230	0	-	-
Case 11	7	4	2	2	22,000	0	-	-
Case 12	12	5	2	2	800	110	+	+
Case 13	10	5	2	3	8900	1500	-	-
Case 14	8	11	3	3	10	340	-	-
Case 15	16	11	2	3	3600	190	-	-
Mean	10.3 \pm 0.8	3.4 \pm 1.4	2.3 \pm 0.1	1.1 \pm 0.3	7536.0 \pm 3457.8	142.7 \pm 100.2		

Cases 1–11 were patients with UC who achieved clinical remission following intensive GMAA. Cases 12–15 were patients with UC who did not achieve clinical remission following intensive GMAA. Means are presented as mean \pm SE for CAI, Mayo-ES, and CMV-DNA in inflamed mucosa. After GMAA; 1 week after completion of intensive GMAA. CAI, Clinical Activity Index; Mayo-ES, Mayo Endoscopic Score, IHC, immunohistochemistry; +, positive for IHC; -, negative for IHC.

plantation and HIV infection.^{5,6} CMV is associated with steroid refractoriness in IBD.^{8,9} The role of CMV in the induction of inflammation and its relationship with immunosuppressive therapies is not clear, however, because the virological criteria for diagnosing CMV infection are not standardized.

Detection of the antigen (pp65 antigenemia assay) or CMV-DNA by PCR in the blood, which can quantify the viral load and is generally applied for the diagnosis of CMV infection, are not necessarily useful for diagnosing CMV-induced colitis because gastrointestinal disease related to CMV infection can occur even when CMV is not detected in the blood. The detection of CMV in biopsy specimens by histological examination, such as the detection of inclusion bodies and IHC, has been the golden standard for diagnosis of the involvement of CMV in gastrointestinal diseases.²⁸ It is important to note, however, that histological markers of CMV disease in the colonic tissue can be negative even if the CMV-DNA load is high at the tissue level. Yoshino et al. reported the usefulness of a mucosal PCR method for detecting colonic CMV reactivation in patients with UC.¹³ Recently, Roblin et al. reported the importance of determining the CMV-DNA load by PCR because this quantitative detection of CMV-DNA in the intestinal tissue could predict resistance to steroid treatment in patients with UC.¹⁴ The European Crohn's and Colitis Organization guidelines recommended the use of tissue PCR as an alternative to IHC for investigating colonic CMV reactivation in immunomodulatory-refractory cases of IBD.⁴ Thus, in this regard, application of the mucosal PCR method for evaluating CMV infection in this study is considered reasonable.

The present study showed that the 29.4% of UC patients not receiving CS were CMV positive. Our data are consistent with the findings of both Roblin and Domènech that mucosal

inflammation in UC, rather than immunosuppressive therapy such as with CS, contributes to the colonic CMV reactivation in intestinal tissue.^{14,29} An interesting finding was that the positive rate of CMV-DNA was significantly lower in UC patients treated with AZA/6MP than in those without. In vitro data showing the proliferation of CMV in fibroblasts inhibited by AZA/6MP support our clinical observation.³⁰ On the other hand, Yoshino et al. reported that the 56.7% of patients with UC refractory to immunosuppressive therapies were CMV-positive.¹³ Based on our data and previous reports, whether or not UC patients exhibit CMV-DNA in the inflamed mucosa might depend on both patient's immune condition and subsequent immunosuppressive therapy.

Several studies have reported conflicting data regarding the endoscopic findings in UC patients with colonic CMV reactivation. Suzuki et al. reported a correlation between the presence of irregular punched-out and longitudinal ulcerations with colonic CMV reactivation.³¹ Yoshino et al., however, demonstrated that the endoscopic findings did not differ between UC patients under immunosuppressive therapies that were positive or negative for CMV-DNA.¹³ Roblin et al. reported the lack of a correlation between CMV-DNA tissue load and endoscopic findings.¹⁴ In the present study, we observed no significant difference in the endoscopic score between UC patients without CS treatment that were positive or negative for CMV-DNA. Although these data suggest that the use of different criteria to define colonic CMV reactivation leads to different results, clearly distinguishing between UC patients that are CMV positive and those that are CMV negative by endoscopic findings alone is difficult.

There is no standardized therapeutic regimen for UC patients with concomitant CMV infection. Although there are

Table 5 Comparison of clinical parameters of patients with active UC positive for CMV treated by intensive granulocyte and monocyte adsorptive apheresis (GMAA) with no corticosteroids between those disappearance or staying appearance for CMV.

	CMV disappearance (n=11)	CMV appearance (n=4)
Age (years)	45.4±4.8	36.0±4.9
Sex (male/female)	5/6	2/2
Disease duration (months)	20.3±9.3	14.3±9.4
Disease location		
Left-sided	10 (90.9)	3(75)
Pancolitis	1(9.1)	1 (25)
Previous treatment		
5-ASA		
No. patients	4 (36.4)	2 (50)
Dose (mg/day)	1750.0±1030.8	1045.5±458.3
AZA/6-MP		
No. patients	10 (90.9)	0
Dose (mg/day)	2.3±2.3	0
CMV-DNA (copies/μg DNA)	9175.5±4618.2	1302.5±788.1
IHC (positive/negative)	2/9	1/3
Clinical Activity Index		
Before GMAA	9.9±0.9	11.5±1.7
After GMAA	1.9±0.3	8.0±1.7
Clinical remission by GMAA	11 (100)	0
Mayo Endoscopic Score		
Before GMAA	2.3±0.2	2.3±0.3
After GMAA	0.5±0.2	2.8±0.3
Mucosal healing by GMAA	10 (90.9)	0

Number of patients is shown for sex, disease location, No. patients of previous treatment with 5-ASA and AZA/6-MP, IHC, clinical remission by GMAA and mucosal healing by GMAA. Data are presented as mean±SE for age, disease duration, dose of previous treatment with 5-ASA and AZA/6-MP, CMV-DNA, Clinical Activity Index before and after GMAA and Mayo Endoscopic Score before and after GMAA. 5-ASA, 5-aminosalicylate; AZA, azathioprine; 6-MP, 6-mercaptopurine, IHC, immunohistochemistry. Values in parenthesis on vertical line of CMV disappearance are percentages of all 11 patients with UC positive for CMV treated by intensive GMAA. Values in parentheses on vertical line of CMV appearance are percentages of all 4 patients with UC positive for CMV treated by intensive GMAA. Clinical remission was defined as Clinical Activity Index ≤4. Mucosal healing was defined as Mayo Endoscopic Score of 0 or 1.

several reports of the effect of antiviral treatments on UC patients with colonic CMV reactivation refractory to CS therapy,^{10–12,14,29,32} a precise method of identifying patients whose disease improves with antiviral therapy has not yet been established. Thus, it remains unclear how and when to start antiviral treatment for UC patients with concomitant CMV infection. Roblin et al. revealed striking data indicating that UC patients with a tissue CMV-DNA load above 250 copies/mg required early antiviral treatment.¹⁴ Their data demon-

strated the importance of evaluating the tissue CMV-DNA load in UC patients to identify those positive for tissue CMV-DNA who should be treated with antiviral treatment. Their data suggested that a higher level of CMV-DNA in the colonic mucosa could affect the efficacy of immunomodulatory treatments, and antiviral treatment might be required to prevent further colonic CMV reactivation during immunosuppressive treatment for patients with a high CMV-DNA load. In this regard, the best way to treat UC patients with concomitant CMV infection might be to reduce colonic inflammation without inducing colonic CMV reactivation.

It is well established that the CMV-specific cluster of differentiation (CD) 4⁺ T-cells, CD 8⁺ T-cells, and γδ T-cells is important for controlling and restricting viral replication in hosts with CMV persistent infection.^{5,6} The production of tumor necrosis factor (TNF)-α is strongly associated with colonic CMV reactivation.⁵ The GMAA system used in this study is a natural biological therapy for selectively removing granulocytes/macrophages from the peripheral blood that reduces the production of inflammatory cytokines such as TNF-α, interleukin (IL)-6, and IL-8, without reducing lymphocytes. Moreover, the number of CD14⁺ monocytes producing TNF-α is reduced from the peripheral blood by GMAA.^{33–35} These anti-inflammatory mechanisms of GMAA might comprise a promising treatment for UC patients with concomitant CMV infection. In fact, Yoshino et al. reported that GMAA did not induce colonic CMV reactivation in UC patients with a history of CMV infection.²² In the present study, the clinical remission rate and mucosal healing following intensive GMAA did not differ significantly between UC patients positive for CMV and UC patients negative for CMV. A similar tendency was observed for the mucosal healing ratio. Notably, CMV-DNA in the colonic mucosa became negative in all UC patients positive for CMV that achieved clinical remission after intensive GMAA. These data strongly suggest that GMAA could be an optimal therapeutic strategy for patients with active UC that are CMV-positive.

In conclusion, our mucosal PCR data demonstrated that 29.4% of patients with active UC prior to the administration of CS were positive for CMV. This finding indicates that local intestinal inflammation can trigger colonic CMV reactivation in a subpopulation of patients with active UC. Additional immunosuppressive therapies, including CS, might also induce colonic CMV reactivation in these patients, yielding refractory UC. Moreover, our present data showed that intensive GMAA therapy was promising for UC patient positive for CMV because 73.3% of these patients achieved clinical remission with disappearance of CMV after completion of intensive GMAA. These data strongly suggest that GMAA therapy could reduce colonic inflammation without affecting CMV reactivation. However, additional clinical trials should be required to confirm the efficacy of GMAA in UC patients positive for CMV.

Conflict of interest

None.

Acknowledgments

We thank Dr. Hideto Senzaki (Department of Clinical Pathology, Osakafu Saiseikai Nakatsu Hospital) for histological examination.

Funding

This work was supported by JSPS KAKENHI 21590810 (to H.N.), 23590940 (to M.M.) from Ministry of Education, Culture, Sports, Science and Technology of Japan, and by Health and Labour Sciences Research Grants for Research on Intractable Diseases from the Ministry of Health, Labour and Welfare, Japan.

Each author's contribution

Care of patients, drafting of the article – Takumi Fukuchi
Critical revision of the article, obtaining of funding –

Hiroshi Nakase

Drafting of the article, obtaining of funding – Minoru Matsuura

Critical revision of the article – Takuya Yoshino

Drafting of the article – Takahiko Toyonaga

Care of patients – Katsuyuki Ohmori

Care of patients – Satoshi Ubukata

Care of patients – Aya Ueda

Care of patients – Takaaki Eguchi

Care of patients – Hiroshi Yamashita

Care of patients – Dai Ito

Care of patients, drafting of the article – Kiyoshi Ashida

References

- McGavran MH, Smith MG. Ultrastructural, cytochemical, and microchemical observations on cytomegalovirus (salivary gland virus) infection of human cells in tissue culture. *Exp Mol Pathol* 1965;**76**:1–10.
- Pass RF. Epidemiology and transmission of cytomegalovirus. *J Infect Dis* 1985;**152**:243–8.
- Goodgame RW. Gastrointestinal cytomegalovirus disease. *Ann Intern Med* 1993;**119**:924–35.
- Rahier JF, Ben-Horin S, Chowers Y, Conlon C, De Munter P, D'Haens G, et al. European evidence-based consensus on the prevention, diagnosis and management of opportunistic infections in inflammatory bowel disease. *J Crohns Colitis* 2009;**3**:47–91.
- Crough T, Khanna R. Immunobiology of human cytomegalovirus: from bench to bedside. *Clin Microbiol* 2009;**22**:76–98.
- Gandhi MK, Khanna R. Human cytomegalovirus: clinical aspects, immune regulation, and emerging treatments. *Lancet Infect Dis* 2004;**4**:725–38.
- Tanaka N, Kimura H, Iida K, Saito Y, Tsuge I, Yoshimi A, et al. Quantitative analysis of cytomegalovirus load using a real-time PCR assay. *J Med Virol* 2000;**60**:455–62.
- Nakase H, Matsumura K, Yoshino T, Chiba T. Systematic review: cytomegalovirus infection in inflammatory bowel disease. *J Gastroenterol* 2008;**43**:735–40.
- Nakase H, Yoshino T, Ueno S, Uza N, Mikami S, Matsuura M, et al. Importance of early detection of cytomegalovirus infection in refractory inflammatory bowel disease. *Inflamm Bowel Dis* 2007;**13**:364.
- Vega R, Bertrán X, Menacho M, Domènech E, Moreno de Vega V, Hombrados M, et al. Cytomegalovirus infection in patients with inflammatory bowel disease. *Am J Gastroenterol* 1999;**94**:1053–6.
- Cottone M, Pietrosi G, Martorana G, Casà A, Pecoraro G, Oliva L, et al. Prevalence of cytomegalovirus infection in severe refractory ulcerative and Crohn's colitis. *Am J Gastroenterol* 2001;**96**:773–5.
- Papadakis KA, Tung JK, Binder SW, Kam LY, Abreu MT, Targan SR, et al. Outcome of cytomegalovirus infection in patients with inflammatory bowel disease. *Am J Gastroenterol* 2001;**96**:2137–42.
- Yoshino T, Nakase H, Ueno S, Uza N, Inoue S, Mikami S, et al. Usefulness of quantitative real-time PCR assay for early detection of cytomegalovirus infection in patients with ulcerative colitis refractory to immunosuppressive therapies. *Inflamm Bowel Dis* 2007;**13**:1516–21.
- Roblin X, Pillot S, Berthelot P, Del Tedesco E, Phelip JM, et al. Cytomegalovirus load in inflamed intestinal tissue is predictive of resistance to immunosuppressive therapy in ulcerative colitis. *Am J Gastroenterol* 2011;**106**:2001–8.
- Shimoyama T, Sawada K, Hiwatashi N, Sawada T, Matsueda K, Munakata A, et al. Safety and efficacy of granulocyte and monocyte adsorption apheresis in patients with active ulcerative colitis: a multicenter study. *J Clin Apher* 2001;**16**:1–9.
- Saniabadi AR, Hanai H, Takeuchi K, Umemura K, Adachi T, Shima C, et al. Adacolumn, an adsorptive carrier based granulocyte and monocyte apheresis device for the treatment of inflammatory and refractory disease associated with leucocytes. *Ther Apher Dial* 2003;**7**:48–59.
- Hanai H, Watanabe F, Takeuchi K, Iida T, Yamada M, Iwaoka Y, et al. Leukocyte adsorptive apheresis for the treatment of active ulcerative colitis: a prospective, uncontrolled, pilot study. *Clin Gastroenterol Hepatol* 2003;**1**:28–35.
- Sakuraba A, Motoya S, Watanabe K, Nishishita M, Kanke K, Matsui T, et al. An open-label prospective randomized multicenter study shows very rapid remission of ulcerative colitis by intensive granulocyte and monocyte adsorptive apheresis as compared with routine weekly treatment. *Am J Gastroenterol* 2009;**104**:2990–5.
- Fukuchi T, Nakase H, Ito D, Yamashita H, Matsuura M, Nagatani Y, et al. Rapid induction of mucosal healing by intensive granulocyte and monocyte adsorptive apheresis in active ulcerative colitis patients without concomitant corticosteroid therapy. *Aliment Pharmacol Ther* 2011;**34**:583–5.
- Yamamoto T, Umegae S, Matzumoto K. Safety and clinical efficacy of granulocyte and monocyte adsorptive apheresis therapy for ulcerative colitis. *World J Gastroenterol* 2006;**12**:520–5.
- Tanaka T, Okanobu H, Yoshimi S, Murakami E, Kogame A, Imagawa H, et al. In patients with ulcerative colitis, adsorptive depletion of granulocytes and monocytes impacts mucosal level of neutrophils and clinically is most effective in steroid naïve patients. *Dig Liver Dis* 2008;**40**:731–6.
- Yoshino T, Nakase H, Matsuura M, Matsumura K, Honzawa Y, Fukuchi T, et al. Effect and safety of granulocyte-monocyte adsorption apheresis for patients with ulcerative colitis positive for cytomegalovirus in comparison with immunosuppressants. *Digestion* 2011;**84**:3–9.
- Lichtiger S, Present DH, Kornbluth A, Gelernt I, Bauer J, Galler G, et al. Cyclosporin in severe ulcerative colitis refractory to steroid therapy. *N Engl J Med* 1994;**330**:1841–5.
- Schroeder KW, Tremaine WJ, Ilstrup DM. Coated oral 5-aminosalicylic acid therapy for mildly to moderately active ulcerative colitis. A randomized study. *N Engl J Med* 1987;**317**:1625–9.
- Plachter B, Nordin M, Wirgart BZ, Mach M, Stein H, Grillner L, et al. The DNA-binding protein P52 of human cytomegalovirus reacts with monoclonal antibody CCH2 and associates with the nuclear membrane at late times after infection. *Virus Res* 1992;**24**:265–76.
- Chemaly RF, Yen-Lieberman B, Castilla EA, Reilly A, Arrigain S, Farver C, et al. Correlation between viral loads of cytomegalovirus in blood and bronchoalveolar lavage specimens from lung transplant recipients determined by histology and immunohistochemistry. *J Clin Microbiol* 2004;**42**:2168–72.
- Rutgeerts P, Sandborn WJ, Feagan BG, Reinisch W, Olson A, Johanns J, et al. Infliximab for induction and maintenance therapy for ulcerative colitis. *N Engl J Med* 2005;**353**:2462–76.
- Kandiel A, Lashner B. Cytomegalovirus colitis complicating inflammatory bowel disease. *Am J Gastroenterol* 2006;**101**:2857–65.
- Domènech E, Vega R, Ojanguren I, Hernández A, Garcia-Planella E, Bernal I, et al. Cytomegalovirus infection in ulcerative colitis:

- a prospective, comparative study on prevalence and diagnostic strategy. *Inflamm Bowel Dis* 2008;**14**:1373–9.
30. Shiraki K, Ishibashi M, Okuno T, Kokado Y, Takahara S, Yamanishi K, et al. Effects of cyclosporine, azathioprine, mizoribine, and prednisolone on replication of human cytomegalovirus. *Transplant Proc* 1990;**22**:1682–5.
 31. Suzuki H, Kato J, Kuriyama M, Hiraoka S, Kuwaki K, Yamamoto K. Specific endoscopic features of ulcerative colitis complicated by cytomegalovirus infection. *World J Gastroenterol* 2010;**16**: 1245–51.
 32. Wada Y, Matsui T, Matake H, Sakurai T, Yamamoto J, Kikuchi Y, et al. Intractable ulcerative colitis caused by cytomegalovirus infection: a prospective study on prevalence, diagnosis, and treatment. *Dis Colon Rectum* 2003;**46**:S59–65.
 33. Kashiwagi N, Sugimura K, Koiwai H, Yamamoto H, Yoshikawa T, Saniabadi AR, et al. Immunomodulatory effects of granulocyte and monocyte adsorption apheresis as a treatment for patients with ulcerative colitis. *Dig Dis Sci* 2002;**6**:1334–41.
 34. Kanai T, Hibi T, Watanabe M. The logics of leukocytapheresis as a natural biological therapy for inflammatory bowel disease. *Expert Opin Biol Ther* 2006;**6**:453–66.
 35. Hanai H. Leucocytapheresis for inflammatory bowel disease in the era of biologic therapy. *Eur J Gastroenterol Hepatol* 2008;**20**: 596–600.