0163-769X/98/$03.00/0
Endocrine Reviews 19(6): 828–843

Adrenocorticotropin Insensitivity Syndromes

ADRIAN J. L. CLARK AND ANGELA WEBER*

Departments of Endocrinology (A.J.L.C.), St. Bartholomew's and the Royal London School of Medicine and Dentistry, West Smithfield, London EC1A 7BE, United Kingdom; and Children's Hospital (A.W.), Technical University Dresden, D-01307 Dresden, Germany

I. Introduction

ACTH INSENSITIVITY syndromes comprise an uncommon group of disorders that, current evidence suggests, have at least three different molecular etiologies. The aim of this review is to examine the various forms of clinical presentation in conjunction with the current knowledge of the molecular and genetic background of these diseases, which as will be seen, reveals some interesting and unexpected physiological and anatomical relationships.

The principal pathways by which ACTH stimulates adrenal steroidogenesis are summarized in Fig. 1. The syndrome of ACTH insensitivity was originally described by Shepard *et al.* (1) in 1959 in a paper entitled "Familial Addison's Disease," which reported the case of two sisters who had what has subsequently become known most frequently as familial glucocorticoid deficiency, isolated glucocorticoid deficiency, adrenal unresponsiveness to ACTH, or hereditary unresponsiveness to ACTH. For uniformity, and since it was the first of these terms to be coined and has been most frequently used in the literature, we continue to refer to this disorder as familial glucocorticoid deficiency (FGD), although the other terms are equally descriptive (MIM*202200).

Although it had been recognized previously as a variant of FGD, the other distinct syndrome of ACTH insensitivity that we shall discuss was identified as such in a paper by Allgrove *et al.* in 1978 (2). This syndrome became known as Allgrove syndrome or, more recently, as the triple A syndrome for reasons that will be described. As we shall show, this is a distinct clinical and genetic entity that shares with FGD only the feature of ACTH insensitivity.

II. Familial Glucocorticoid Deficiency

A. Clinical presentation

The typical presentation of patients with ACTH insensitivity is almost always as a consequence of glucocorticoid deficiency. Excessive skin pigmentation as a result of high circulating ACTH is occasionally reported as one of the primary complaints. Since these disorders are inherited diseases (see below), it might be expected that glucocorticoid deficiency should be manifest in the neonatal period. Although this is true for some patients, many are not diagnosed until infancy or later childhood.

The nature of the clinical presentation in the neonate differs from that in later childhood and in most patients takes the form of hypoglycemia (3–8). This may not be profound and usually responds to more frequent feeding. Often these patients are significantly jaundiced and may require phototherapy (4, 5, 7, 8). In some cases this appears to result from a transient hepatitis, which may be glucocorticoid dependent (9). Perhaps surprisingly, excessive pigmentation of the skin is occasionally seen within the first month of life (3, 4, 10), although this phenomenon is usually first noted between 5 and 12 months (1, 3, 6, 11) or even later.

Hypoglycemia, sometimes manifesting as convulsions, is often a presenting feature in infancy and childhood. Alternatively, children may present at this time with a significant infective episode that may be fatal (1). Others will exhibit frequent minor infections, which take an unusually long time to disappear. Another occasional presenting feature of FGD is childhood asthma, which responds to replacement doses of glucocorticoid (*e.g.*, Ref. 7).

At presentation, a history of other features including frequent infective episodes, lethargy and malaise, failure to thrive, and unusual skin pigmentation can often be elicited. Such features would be entirely consistent with a diagnosis of childhood Addison's disease, and in many patients this is the initial working diagnosis. FGD differs from Addison's disease in one major respect however: patients with FGD

Address reprint requests to: Adrian J. L. Clark, Department of Endocrinology, St. Bartholomew's and the Royal London School of Medicine and Dentistry, West Smithfield, London EC1A 7BE, United Kingdom. E-mail: a.j.clark@mds.qmw.ac.uk

* Supported by a UK Wellcome Travelling Research Fellowship, a UK Wellcome Research Travel Grant, and a Fellowship (We1693/1–1) from the Deutsche Forschungsgemeinschaft, Germany. We also gratefully acknowledge the support of the UK Medical Research Council and the Joint Research Board of St. Bartholomew's Hospital.

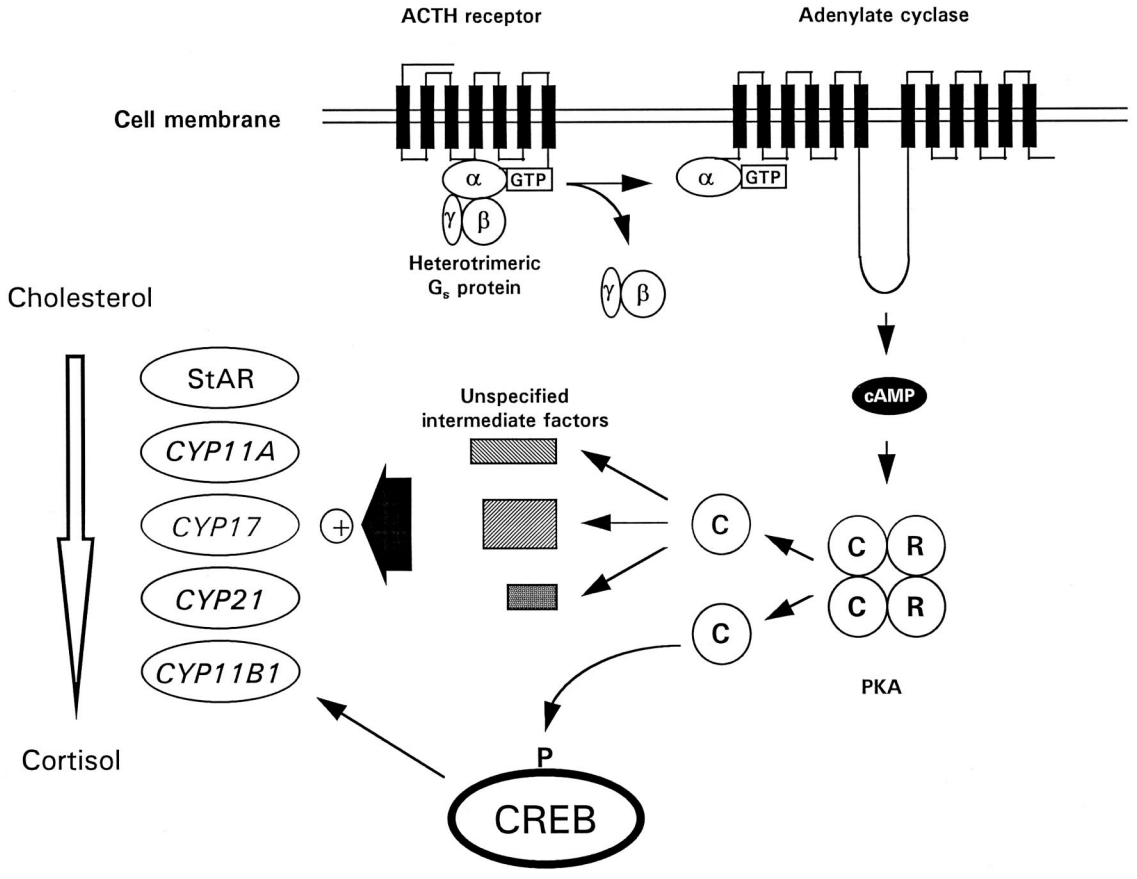

FIG. 1. Essential features of the mechanism of action of ACTH in stimulating steroidogenesis in the adrenal fasciculata cell. ACTH binds to and activates its cognate seven-transmembrane domain receptor at the cell surface, resulting in activation of the heterotrimeric G protein by exchange of GTP for GDP and dissociation of the α-subunit from the $\beta\gamma$-subunits. Gsα then stimulates membrane-associated adenylate cyclase to synthesize cAMP, which in turn activates protein kinase A (PKA) in the cytosol. The catalytic subunits of PKA dissociate and phosphorylate target factors, which include the cAMP response element binding protein (CREB). CREB and other unidentified factors which may also be substrates for PKA then activate the steroidogenic acute regulatory protein (StAR) protein and induce the transcription of the steroidogenic enzymes *CYP11A* (P450 scc), *CYP17* (17α-hydroxylase), *CYP21* (21-hydroxylase), and *CYP11B1* (11β-hydroxylase), which ultimately results in an increased rate of cortisol synthesis.

never develop mineralocorticoid deficiency, and thus no disturbance of electrolyte balance, no dehydration, and no salt wasting. This reflects the fact that mineralocorticoid production by the adrenal cortex is primarily under the control of angiotensin II and is relatively independent of ACTH, although ACTH can normally stimulate aldosterone production in the short term.

Other steroid products of the adrenal cortex are under the control of ACTH. In particular, androstenedione and dihydroepiandrosterone are mostly secreted from the zona reticularis cells from around 7 yr of age in the process known as adrenarche (12). Although considerable debate continues to surround the trigger for adrenarche, it is clear that ACTH is required for normal adrenal androgen secretion, since patients with FGD lack any evidence of an adrenarche and often have undetectable adrenal androgens (13).

Several patients with the clinical diagnosis of FGD have been reported to be unusually tall (1, 3, 7, 11, 14–17). No endocrinological explanation for this has been apparent, and when investigated, there do not appear to have been disturbances of the measurable components of the growth axis (7). Some patients show a marked acceleration of their bone age before puberty despite low or undetectable adrenal androgens or other sex steroids. Patients with adrenal failure resulting from other causes, such as autoimmune Addison's disease, are not unusually tall (18), and the excessive height usually predates any clinical intervention. Puberty is neither advanced nor delayed in these patients, and the enhanced stature is, in any case, apparent well before puberty begins. This phenomenon may be of significance in understanding the etiology of the disease (see below).

B. Investigation

The symptoms described above should lead to a measurement of an 0800 to 0900 h plasma cortisol, which in the normal child should exceed the minimum value quoted by the laboratory involved (usually 200–300 nmol/liter), and, especially in a stressed and sick child, should be significantly greater than this minimum level. The patient with FGD will almost always have a low or undetectable cortisol concentration. Occasionally, some patients have low normal cortisol values.

A plasma ACTH taken at the same time will inevitably be markedly elevated, and values of more than 1000 pg/ml are commonly found. Such findings suggest Addison's disease as the most likely cause. This diagnosis can often be rendered unlikely by demonstrating a normal electrolyte balance, and in support of this, renin and aldosterone measurements should be near normal in the supine patient with FGD, but will indicate aldosterone deficiency and a high renin in the patient with Addison's disease. This combination of a high ACTH with cortisol deficiency and a normal renin and aldosterone is indicative of an ACTH insensitivity syndrome, although, as outlined below, there may be some exceptions in the case of the triple A syndrome.

In fact, at initial presentation there may be minor disturbances of the renin-aldosterone axis in patients with FGD that probably result from the varying and opposing influences of 1) the absence of any ACTH stimulation of aldosterone production by the zona glomerulosa (5, 19); and 2) the underlying illness of patients with FGD at presentation as a result of infection or frequent hypoglycemia. As in any other patient, these disturbances may stimulate the renin-aldosterone axis. These influences may therefore result in a broad range of renin and aldosterone levels in patients with ACTH resistance, which may occasionally confuse the diagnosis.

In all patients, including those with less severe cortisol deficiency or in whom the diagnosis is in doubt for other reasons, a standard short ACTH stimulation test is required. Synthetic ACTH[1–24] (250 μg/m^2 body surface area; maximum 250 μg) is given intravenously, and plasma cortisol is measured after 30 and 60 min. Normally, cortisol should exceed the upper limit of normal for the laboratory involved (500–580 nmol/liter) in this time but will fail to achieve this level in patients with ACTH insensitivity, Addison's disease, or other adrenal disorders.

A number of other investigations may be used in excluding other diagnoses at this time. Although the clinical history and physical signs are not usually suggestive, it may be helpful to exclude congenital adrenal hyperplasia by measurement of plasma 17α-hydroxyprogesterone. Likewise, adrenoleukodystrophy could be excluded by measurement of very-long-chain fatty acids. Distinction between a diagnosis of FGD and the triple A syndrome may be more difficult, and this is discussed in more detail later. However, a Schirmer test of tear production and a barium swallow may make the diagnosis of the latter syndrome in this situation.

C. Treatment

After initial resuscitation, the treatment of ACTH insensitivity is relatively simple in that only glucocorticoid replacement with oral hydrocortisone is required. Occasionally oral dexamethasone has advantages in view of its longer action. As with any patient taking glucocorticoids, the dose needs to be increased in times of stress or injury. No mineralocorticoid replacement is needed.

We are aware anecdotally of patients who have been started on treatment for Addison's disease with glucocorticoid and mineralocorticoid replacement, who have, of their own accord, found it unnecessary to continue with the mineralocorticoid component, and who on reinvestigation were found to have FGD. For this reason it may be valuable for clinicians managing patients with childhood Addison's disease, and especially those cases in whom a sibling is affected, to reconsider the initial diagnostic criteria, since establishment of a diagnosis of FGD will alter the advice given to parents over the risk to further offspring. In addition, compliance with steroid replacement may be more effective if only one steroid needs to be replaced rather than two.

D. Pathogenesis

The first description of FGD highlighted the point that the diagnosis had been made in two sisters, and that therefore the disease was likely to be inherited (1). In other cases described shortly afterward, the familial nature of the disorder and the appearance of symptoms in the neonatal period supported this notion (15). The demonstration that the parents of these patients were healthy and had no adrenal abnormality, combined with reports of parental consanguinity (20), was suggestive of an autosomal recessive inheritance. However, Migeon *et al.* (3) reviewed six male patients with this disease and concluded that it may be X-linked, although they recognized that the data of others did not necessarily support this. Subsequent reports by many authors have supported the view that this is an autosomal recessive disorder of greater prevalence in consanguineous families (14).

A number of hypotheses have been put forward to explain the origin of FGD. These fall into four groups which are as follows:

1. A defect in the adrenal receptor for ACTH. This is the most frequent proposal made by the majority of authors who have speculated on this question (*e.g.*, Refs. 3 and 14) The main drawbacks to this proposal have been that since these patients become pigmented, their ACTH is able to act on the melanocyte. Second, the adrenal histology (see below) suggests a developmental failure of the adrenal gland, which may argue against a simple cell surface resistance to this hormone. Nevertheless, evidence favoring this hypothesis came from Smith *et al.* (21) who demonstrated defective ACTH binding to peripheral blood mononuclear cells in a patient with FGD, in contrast to normal binding characteristics in cells from a control subject (21). This is a somewhat surprising result in retrospect, since there is little evidence that the MC2 (ACTH) receptor is expressed in leukocytes, and it may have been the result of undertaking nonsaturated binding studies.

2. A defect in the intracellular signaling response to ACTH receptor stimulation is an obvious alternative to a receptor defect, although it suffers from the disadvantage that many or most intracellular signaling components are common to many other cell types and receptor systems that do not appear to function abnormally in these patients. However, some weight was given to this hypothesis by the findings of Yamaoka *et al.* (22) in 1992 who demonstrated normal peripheral blood mononuclear cell ACTH binding and cAMP generation, yet a failure to generate cortisol when cAMP was infused into the patient. They argued that this indicated that

the disease resulted from a postreceptor defect lying distal to cAMP generation.

3. A defect in adrenocortical development was proposed by those who had the opportunity to examine the adrenal glands removed pre- or postmortem from affected patients (11, 16). Since in most cases these glands seemed to show a failure of development of the zona fasciculata and reticularis, it was argued that this was the likely primary cause of the disorder. This proposal would of course be compatible with the inevitable hyperpigmentation of patients. The question of adrenal histology is discussed later in more depth (see *Section II.D.2*).

4. Degeneration of the adrenal gland was originally proposed by Moshang *et al.* (23) in view of the observation that some patients have progressed to develop mineralocorticoid deficiency, including the patient reported by Stempfel and Engel (15). As will be discussed later in this review, this progressive adrenal failure is frequently seen in patients with the triple A syndrome, and it is conceivable that there may be some error in the diagnosis of FGD and the triple A syndrome.

1. ACTH receptor defects in FGD. The human ACTH receptor was originally cloned in 1992 by Mountjoy *et al.* (24), who in the same paper reported the cloning of a second receptor for α-MSH, which was expressed in melanocytes. Shortly thereafter, three other distinct members of this family of receptors were cloned, which are named MC1, MC2, etc, and together they comprise the melanocortin receptor family (25–29). The principal biological features of each of these are listed in Table 1. It appears that although ACTH is an agonist for all of these receptors, the receptor that is expressed in adrenocortical cells and that is responsible for the steroidogenic actions of ACTH is the MC2 receptor, which is synonymous with the term ACTH receptor. None of the MSH peptides acts as an agonist on this receptor (30). In fact, there is good evidence that the MC5 receptor is also expressed in the adrenal cortex (31, 32), but its functional role there is currently obscure.

In 1993, shortly after the cloning of the MC2 receptor was reported, we had the opportunity of investigating this gene in a patient with a typical history of FGD, which had begun with neonatal hypoglycemia, followed by frequent and severe infections in childhood. We were able to demonstrate a homozygous missense point mutation in the patient and his similarly affected sibling (6). This mutation converted Ser74, which lies in the second transmembrane domain, to Ile (S74I) and segregated with the disease in the family. We and others have subsequently reported a number of different missense and nonsense mutations in this gene that occur in homozygous or compound heterozygous forms in patients with the disorder (7, 8, 10, 33, 34). In all cases these mutations cosegregate with the disease in the family. The current status of these published mutations is summarized in Table 2 and Fig. 2. In some cases the nature of the mutation will clearly lead to significant structural disruption of the receptor molecule, and it is to be expected that the receptor will be nonfunctional. In other cases it is less obvious why the mutation should lead to the disease. Investigation of these cases requires a system for expression of the mutant receptors in a cell type that allows proper comparison of their functional characteristics with those of the normal MC2 receptor. Achieving such a test system has been difficult.

We had some limited success in expressing the normal and S74I mutant receptor using a very high-efficiency system in Cos 7 cells (35). This system provided only poor levels of expression that were partly confounded by an endogenous melanocortin receptor in these cells. We were able to show that cells expressing the mutant receptor responded to ACTH, albeit requiring higher concentrations for an equivalent response. This finding is consistent with the clinical observation in some patients with this mutation that by elevating the plasma ACTH markedly, an adequate amount of cortisol can be produced by the adrenal to render the disease less severe than that with some other mutations.

Naville *et al.* (8) used a different system in which the mutant ACTH receptors were expressed in the M3 melanoma cell line, which has endogenous MC1 (α-MSH) receptors. They showed that the D107N, C251F, and 1347insA mutations lacked all cAMP-generating function in this system in contrast to the normal sequence receptor. Again, however, these results are confounded by the endogenous response derived from the MC1 receptor. Currently, our own strategy is to use the mouse Y6 cell line, a mutant derivative of the mouse Y1 adrenocortical cell line that fails to express the endogenous ACTH receptor (36). This line seems to be capable of expressing transfected ACTH receptors in the absence of any background and is providing promising results (Ref. 37 and L. L. K. Elias, A. Weber, G. D. Pullinger, A. Mirtella, and A. J. L. Clark, manuscript submitted). This suggests that an adrenal component is required for normal efficient MC2 receptor expression.

These studies indicate that mutations of the ACTH receptor can account for some cases of FGD, explaining the autosomal recessive nature of the disease. This also explains why these patients become pigmented, since this results from excessive ACTH stimulation of the MC1 receptor on cutaneous melanocytes. ACTH is an effective agonist at this receptor with only slightly greater EC_{50} values than α-MSH (24, 25).

It is notable that although activating mutations have been described in the case of a number of other G protein-coupled receptors, they have not been described in the case of the ACTH receptor. Two studies have examined the ACTH re-

TABLE 1. Summary of the features of the melanocortin receptor family and some of their apparent functions

Receptor	Ligand preferance	Site of expression	Function
MC1-R	α-MSH/ACTH > γ-MSH	Melanocytes +++	Pigmentation
MC2-R (ACTH-R)	ACTH only	Adrenal cortex >> adipocytes	Steroidogenesis
MC3-R	γ-MSH > α-MSH/β-MSH/ACTH	Brain, placenta	Various
MC4-R	α-MSH/β-MSH/ACTH > γ-MSH	Brain	Appetite regulation
MC5-R	α-MSH > β-MSH/ACTH > γ-MSH	Widespread	Unknown

TABLE 2. Summary of published and some unpublished ACTH receptor mutations and their probable functional consequences

Mutation	Functional consequence	Reference
Pro 27 Arg	Benign polymorphism	40
Ile 44 Met	Signal transduction defect	7
Ser 74 Ile	Intramolecular bond/signal transduction defect	6,7
Asp 103 Asn	Loss of ligand binding	Unpublished
Asp 107 Asn	Loss of ligand binding	8
1052delC	Truncated receptor (frameshift mutation)	Unpublished
Ser 120 Arg	Structural disruption of transmembrane domain 3	10
Arg 128 Cys	Loss of signal transduction	7
Arg 146 His	Loss of signal transduction	7,34
Thr 159 Lys	Structural disruption of transmembrane domain 4	Unpublished
1272delTA	Truncated receptor (frameshift mutation)	7
Arg 201 X	Truncated receptor	10
1374insA	Truncated receptor (frameshift mutation)	8
Cys 251 Phe	Loss of disulphide loop	8
Tyr 254 Cys	Interference with disulphide bonds	33
Pro 273 His	Disruption of conserved region of transmembrane domain 7	Unpublished

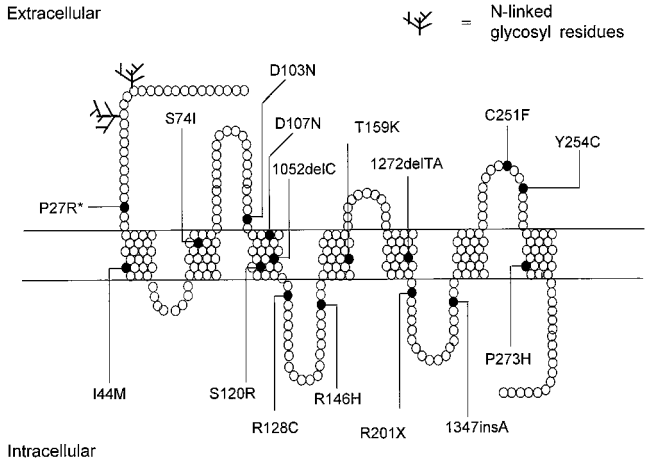

FIG. 2. Schematic two-dimensional representation of the human ACTH receptor showing the locations of all the polymorphisms and mutations published to date in patients with FGD. See Table 2 and text for details.

ceptor sequence in DNA obtained from a variety of adrenal tumors, and both reported no abnormalities (38, 39). This does not completely exclude this occurrence, but it must be an uncommon cause of adrenocortical hyperfunction and hyperplasia.

2. Genotype-phenotype correlations. As these expression studies suggest, different mutations are likely to disable the receptor to different degrees, making genotype-phenotype comparisons difficult. However, the S74I mutation that we originally described has proved to be the most prevalent of these mutations and we have now identified it in 10 individuals from 6 families in a homozygous form and as a compound heterozygote with a more severe mutation in 2 more unrelated cases. Many of these patients have a Scottish family background, and it seems highly likely that the founder mutation occurred in this region, probably in the past few centuries.

ACTH receptor mutations provide some interesting physiological points. Since a point mutation in both alleles of this gene can result in complete failure to secrete cortisol, there can be little doubt that the gene originally cloned by Mountjoy *et al.* (24) encodes the ACTH receptor, and that it is the only ACTH receptor. There is good evidence that adrenocortical cells also express the MC5 (MSH) receptor, which has been shown to respond *in vitro* to ACTH at high concentrations (31, 32). However, it appears that the high concentrations of ACTH found in untreated FGD are not sufficiently high to recruit this receptor for stimulation of cortisol production. An alternative and very probable explanation, however, is that the ACTH receptor has an essential role in the growth and development of the inner zones of the adrenal cortex, and that the MC5 receptor is unable to stimulate steroidogenesis simply because there are insufficient cells expressing this receptor and the steroidogenic enzyme genes in these patients.

There has long been a debate on the relative contributions of ACTH, other POMC-derived peptides, and other factors in adrenal growth. Since the ACTH receptor is highly specific for ACTH (30), it would seem that patients with FGD would provide an excellent model with which the role of ACTH could be defined. These patients consistently have small adrenal glands, suggesting an important role for ACTH. Few of these glands have become available for histological examination. However, adrenal sections obtained from a 3-yr-old girl who died from FGD caused by an S74I mutation are shown and compared with those from a child of the same age dying of nonadrenal disease (Fig. 3, A and B). The histological appearance suggests the presence of disorganized glomerulosa cells surrounding a normal adrenal medulla with no evidence of fasciculata or reticularis cells. This appearance is typical of several of the other examples of adrenal histology in FGD (1, 3, 11).

The heterozygous state for these ACTH receptor mutations is not associated with any disorder of the pituitary-adrenal axis. No obvious abnormalities of circulating ACTH or cortisol concentrations have been reported in heterozygotes. However, it may be that a more subtle test is required to reveal subclinical abnormalities, and for this reason the standard CRH test has been used. Tsigos *et al.* (10) reported that the heterozygote parents of a patient with the S120R and R201X mutations had slightly exuberant responses to CRH in a conventional CRH stimulation test. However, this effect may be explained by ethnic differences in the CRH response (40). We reported the responses to CRH in four subjects who were each heterozygous for a different ACTH receptor mutation (7). All had a normal response. It appears that the

results of CRH testing are greatly variable and may not be entirely reliable for this purpose.

3. Normal receptor FGD. Not all cases of FGD are associated with mutations within the coding region of the ACTH receptor. Of 37 families that we have studied to date, in only 14 families are affected cases associated with homozygous or compound heterozygous mutations. One possibility is that there are mutations in regions of the gene apart from the coding exon (such as the promoter). However, it is generally true that mutations in promoters are not a common cause of genetic disease.

As a result of the human genome-mapping project it is now relatively straightforward to identify highly polymorphic microsatellite repeat sequences at given locations in the genome. The ACTH receptor was mapped to the short arm of chromosome 18 (18p11.2) (41, 42); therefore, we investigated the proximity of a number of repeats in this region by performing linkage analysis in the families with ACTH receptor mutations. This approach revealed that the markers *D18S40* and *D18S44* were positioned on either side of the ACTH receptor gene at distances of 3 and 4 centimorgans, respectively (Ref. 43 and our unpublished observations). Such a distance, although large in physical terms, is satisfactory for the segregation studies proposed.

The results of this analysis indicate that, in the case of several of the FGD families without ACTH receptor mutations, the segregation analysis was not compatible with an etiological role for the ACTH receptor gene (43). This result is important since it makes it clear that the identical clinical phenotype of FGD can be caused by at least one other genetic defect. For ease of reference we have adopted the term FGD type 2 for the syndrome that is not linked to the ACTH receptor locus, in contrast to the term FGD type 1 for the disease caused by mutation of the ACTH receptor. For the remainder of this discussion we also use the term FGD type 2 for those patients who have a normal ACTH receptor-coding sequence and in whom linkage markers were uninformative. It is hoped that ultimately the causative gene for this syndrome will be identified, which may allow a more descriptive distinction between the etiologies of this disease.

4. Phenotypic distinctions. We have examined the clinical features of the two types of FGD in the hope of identifying distinctions between them that may help elucidate the nature of the defect in FGD type 2. No differences in ACTH, cortisol, ACTH stimulation tests, or other biochemical aspects were apparent. Likewise, the clinical presentation did not distinguish these disorders (44). However, an unexpected difference was found in the patients' heights. Thus whereas those patients with FGD type 2 have heights that fall within the normal distribution (± 2 SD), patients with ACTH receptor mutations have a mean height that is about 2 SDs greater than normal. This difference is statistically significant (44). These findings are summarized in Fig. 4.

Although it has not been studied systematically, no abnormalities in GH, GH dynamics, or insulin-like growth factor-I (IGF-I) have been identified in any of these tall patients to date. In some patients, it has been suggested that the rate of growth slows after hydrocortisone replacement is begun, but it is difficult to rule out a negative effect on growth of excessive glucocorticoid replacement. It seems probable that this observation tells us something about the etiology of FGD type 2, as well as revealing unexpected aspects of ACTH physiology.

A further possible distinction between the two types of FGD may be revealed by the adrenal histology. Kelch *et al.* (11) described the adrenal histology from a child who died after a 6-day coma and who was pigmented; this patient had a brother in whom a diagnosis of FGD had been made and who had responded well to glucocorticoid replacement. Adrenal sections from the first sibling are clearly different from those of other FGD patients (and from patients with the triple A syndrome) and show multinodular hyperplasia, with areas of focal calcification and lipid congestion with cholesterol-like clefts. (This implies extracellular lipid deposition and is distinct from the intracellular deposition seen in certain diseases.) We are aware of somewhat similar sections obtained from a patient that we have studied who had a normal sequence ACTH receptor (data not shown).

In summary, the molecular analysis of FGD has not only confirmed the etiological role of defects in the ACTH receptor in some cases, but has excluded it in others. It has revealed unexpected connections between the actions of ACTH and linear growth and has demonstrated with great clarity the essential need for ACTH in adrenocortical growth and development. Furthermore, it has indicated the existence of at least one other gene that, when defective, leads to an almost indistinguishable syndrome from that caused by ACTH receptor defects. The identification of this gene will, in turn, reveal much about ACTH and adrenal physiology.

III. Triple A Syndrome

A. Clinical features

1. Main features. In 1974, Counahan and West (45) described a patient who presented with isolated glucocorticoid deficiency causing severe hypoglycemia, punctate erosions of the cornea with superficial scarring as the result of absent lacrimation, and longitudinal fissuring of the fingertips with absent dermatoglyphs but without achalasia. There is one other report of a patient with FGD in whom achalasia was mentioned as an additional symptom (46). This patient later showed deficient tear production (alacrima) (W. Petrykowski, personal communication). In 1978 Allgrove *et al.* (2) first described two pairs of siblings with the combination of the symptoms of ACTH-resistant adrenal insufficiency, achalasia of the cardia, and alacrima, which has become known as Allgrove syndrome. Over the following years, a total of 61 families with 97 patients with the triad of adrenal insufficiency, achalasia, and alacrima have been reported, and the name triple A syndrome became established (MIM*231550).

This syndrome can be clearly distinguished from FGD by the presence of the additional features. It manifests itself during the first decade of life with severe hypoglycemic episodes that can cause sudden death as in 17 of the 97 described patients (2, 46–54). Although in most cases hypoglycemia and hyperpigmentation lead to the diagnosis, alac-

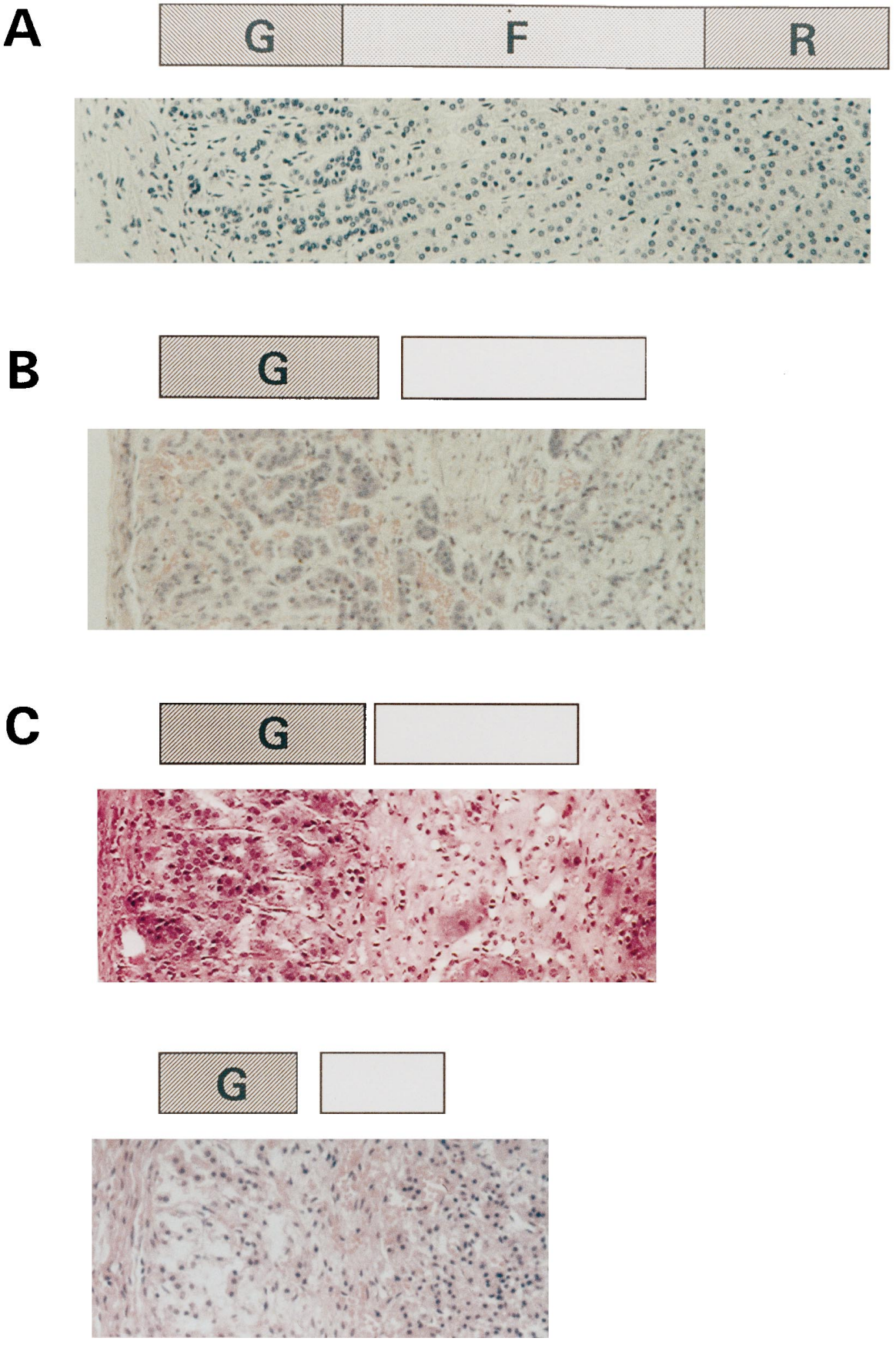

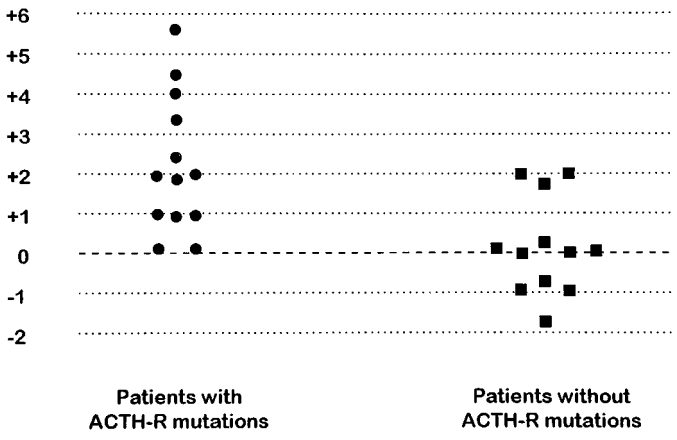

FIG. 4. Longitudinal height expressed as SD score (SDS) in 13 patients with FGD with (79) and 11 patients without (127) ACTH receptor mutations. [Reproduced by permission of Humana Press.]

rima or hypolacrima is probably the earliest and most consistent sign, which can easily be overlooked by parents and physicians (55). Orbital computerized tomography revealed absent or very small lacrimal glands in one patient in whom this was studied (48). The majority of patients have isolated glucocorticoid deficiency, but in about 15% mineralocorticoid production may also become impaired at a later time (47, 49, 50, 56–61). Adrenal insufficiency does not occur immediately postnatally but results from a progressive disorder leading to hypofunction of the adrenal gland at a variable time after birth (56, 60). Adrenal hypoplasia has been demonstrated by computerized tomography of the adrenal gland (62).

Achalasia of the cardia occurs in about 75% of all cases, the times of onset ranging from 0.5 to 16 yr. This symptom may precede adrenal insufficiency by about 1–4 yr (55, 60, 63). In fact, achalasia and gastric atonia (our unpublished observation) leading to recurrent or chronic pulmonary disease as a result of aspiration (64) may be the feature that causes the greatest threat to patient well being and is the most difficult to treat.

Patients presenting with the combination of achalasia and alacrima without adrenal failure have been described. This condition was defined as a distinct entity (MIM200440) named the achalasia-alacrima syndrome (65–72), but probably reflects the delayed penetrance of all the primary features of the triple A syndrome.

2. Associated features.

a. Neurological features. Since the original description of the disease, it has become apparent that many patients also suffer from, in addition to the three main features, progressive neurological symptoms, which often result in a disabling disease that considerably impairs the quality of life (60). Central, peripheral, and autonomic nervous systems may be involved. Some of the neurological symptoms may be partly attributable to the complications of hypoglycemic episodes leading to microcephaly, seizures, intellectual deterioration, and developmental delay (61).

Impairment of the central nervous system has been seen in the form of mental retardation (48, 51, 52, 57, 60, 61, 73–75) that can be progressive (48, 75), optic atrophy (47, 57), clumsiness, ataxia (55, 57, 61, 76), Parkinsonism (75), and hyperreflexia (46, 47, 52, 55, 60, 61, 74–78). Recurrent seizures have been described but, as stated above, may be due to hypoglycemic episodes in untreated patients (46, 49, 51, 56, 60, 61). Electroencephalography is normal (57, 75, 79), although in two cases mild dilation of the ventricles was seen on computed tomography scanning (75). In the case of Parkinsonian features, positron emission photometry scans have been performed in one subject using methyl spiperone and 18-F-L-flurodopa, which demonstrated diminished dopamine metabolism, storage, and binding in the striatum. However, these results do not provide an explanation for the mechanisms involved in neurological damage (75).

Sensorineural deafness may occur and brainstem auditory-evoked responses show a bilateral Stockard type II abnormality that is typical of a sensineural deficit and is characterized by amplitude reduction, elevation of the threshold intensity, and normal latencies (57, 60). In many patients a characteristic hypernasal speech is reported (2, 46–48, 52, 60, 74, 76, 77), which is due to an abnormally diminished motion of the lateral pharyngeal walls and incomplete velopharyngeal closure during plosive formation reflecting palatopharyngeal incompetence (48, 80).

The peripheral nervous system may also be affected. Some of the symptoms resemble those seen in patients with hereditary sensorimotor neuropathy such as muscle hypotonia, muscle weakness, progressive distal muscular atrophy, pes cavus, loss of deep sensibility, and other sensory impairment (48, 50, 52, 57, 60, 61, 74–78, 81). Electrophysiological investigation including nerve conduction studies and electromyography reveal slow conduction velocities of motor and sensory nerves consistent with mixed sensorimotor polyneuropathy with predominant axonal involvement with fibrillation potentials, motor unit drop-out, and enlarged motor unit potentials (48, 49, 52, 61, 75, 77–79). The histological appearances of muscle biopsy and sural nerve biopsy are summarized below (see *Section III.C.2.*).

About 30% of all patients suffer from autonomic impairment, which may be manifest by any of the following symptoms and signs: postural hypotension, impaired cardiovascular reflexes, cardiac dysrhythmias, unequal pupils, abnormal miosis after instillation of metacholine eye drops, absent or reduced sweating, abnormal responses to intradermal histamine, and impotence (48, 56, 60, 61, 74, 76–78, 82, 83). Gazarian *et al.* (61) have proposed the name "4A" syndrome to describe the appearance of these features. They suggested that the finding of one main symptom should prompt a search for other associated features.

FIG. 3. Histological appearance of the adrenal cortex in (A) a child who had died suddenly of nonendocrine causes (panel A), a 3-yr-old child who had died after overwhelming infection in FGD resulting from a homozygous mutation of the ACTH receptor (panel B), and two children who had died as a result of the triple A syndrome (panel C). Note the relative preservation of the zona glomerulosa in panels B and C indicated diagrammatically by the *shaded box* labeled G, with apparent replacement of the zona fasciculata and reticularis (boxes labeled F and R in the normal section) with nondescript cells. [Sections in panel C are reproduced with the generous permission of Professor Boehm, University of Freiburg, and Professor Siebenmann, University of Zurich.]

b. Dermatological features. In about 20% of all patients, skin abnormalities are present comprising hyperkeratosis of palms and soles with fine palmar creases, which may only be present in the early years of life (2, 49, 77), incompletely developed dermatoglyphs, fungiform papillae of the tongue, and cutis anserina ("gooseflesh") (45, 49, 55, 60, 61, 74, 79).

c. Other features. The clinical variability is reflected by a variety of associated symptoms that have been described in a minority of patients. Whether these are truly part of the triple A syndrome, or are features arising as a result of distinct etiological processes, or, in the case of osteoporosis, as a consequence of glucocorticoid replacement, is not clear. They include 1) significant short stature (47, 57, 60, 74); 2) microcephaly (52, 57); 3) osteoporosis (49); 4) lack of eye lashes (74); 5) dysmorphic facies with long narrow face, long philtrum, down-turned mouth, and thin upper lip (48, 55, 61); 6) poor wound healing (2, 61); 7) cleft palate (60); 8) multiple nasal polyps (60); 9) scoliosis (60); 10) long QT syndrome (62); and 11) hyperlipoproteinemia type IIb (62).

Other features that we have observed include one patient who presented with Noonan's syndrome-like symptoms including short stature, high arched palate, ptosis, hypertelorism, epicanthus, broad chest, short neck with pterygium colli, and low posterior hairline. Other patients have presented with hyperextensible joints, kyphosis, and a marked dental caries with periodontitis resulting in a nearly complete loss of secondary dentition (our unpublished observations).

In addition to the variability in the age of onset of the main features, there is a considerable inter- and intrafamilial variability of the associated symptoms suggesting either a contiguous gene defect, or, more probably, variable expression of the impaired gene (48, 50).

3. Inheritance. The triple A syndrome shows an autosomal recessive mode of inheritance. The evidence for this conclusion is that 1) the disease affects either sex with a relatively even sex ratio (48, 60); 2) patients are born to unaffected parents; and 3) there is an increased incidence of parental consanguinity (48, 50, 60, 61). There is no indication that the triple A syndrome is a mitochondrially encoded disease as there is no matrilineal inheritance. Preliminary genetic studies are suggestive of full penetrance of the disease with variable expression (84, 85). Affected children are reported from all continents of the world indicating that this rare disease is unlikely to have a single founder.

B. Treatment

Glucocorticoid and, if present, mineralocorticoid deficiency can easily be treated by replacement with hydrocortisone and fludrocortisone (9-α-fluoro-hydrocortisone), respectively. Symptomatic treatment of alacrima is possible with artificial tears (52). Achalasia may provide significant management problems that often require esophageal dilatation or Heller's cardiomyotomy (51). In severe cases it may be necessary to resort to gastrostomy feeding. Glucocorticoid replacement therapy seems to have no influence on the development and progression of neurological symptoms (80). Hence, no treatment strategies are available either for the variable and progressive neurological damage or for the other associated features.

C. Pathogenesis

The molecular cause of the triple A syndrome is still unknown. The unusual and varied combination of clinical features found in this disease provide a compelling and complex problem in attempting to understand its etiology. The evidence accumulated from the exclusion of other disease processes, histopathological studies, animal models, cytogenetics, candidate gene studies, and genome search strategies are reviewed below.

1. Exclusion of other disease processes. Thorough investigation of patients with triple A syndrome has ruled out the following disorders associated with or causing the disease: 1) autoimmune Addison's disease (no adrenal autoantibodies) (2, 57); 2) adrenoleukodystrophy (normal very-long-chain fatty acids) (52, 57, 75, 77, 86); 3) organic aciduria, carnitine deficiency, Refsum's disease (52); 4) thyroid dysfunction (normal thyroid hormones, no antithyroid antibodies) (47, 57, 62, 77).

2. Histological studies. Histological examination of the adrenal glands removed from patients who have died from this condition are few in number, but are consistent in revealing relative adrenal atrophy with an almost complete loss of the zona fasciculata and reticularis despite preservation of the zona glomerulosa and adrenal medulla (2, 46, 47). In this regard, there are considerable similarities to the adrenal histology of many patients with FGD. Representative adrenal sections from two patients with the triple A syndrome are shown in Fig. 3C. Other histopathological features include pituitary gland hyperplasia and hypertrophy of the corticotroph cells, consistent with primary adrenal failure (46).

Detailed neuropathological studies of patients who have developed neurological features of the disease are unfortunately lacking. Muscle biopsy indicates a denervation atrophy (77, 78), and sural nerve biopsy suggested a predominant axonal degeneration (52, 61, 77). Histology of the lower esophagus showed muscle hypertrophy with absence of ganglionic cells and only a few small nerve fibers on routine staining, in contrast to sections from the midesophagus where ganglion cells with large and small nerve fibers were seen (2).

3. Animal models. Animals exhibiting the complete combination of symptoms (adrenal insufficiency, achalasia, alacrima, neurological disorders) resembling those of patients with triple A syndrome do not exist. However, in 1992 Bartges and Nielson reported a 5-yr-old female standard poodle who presented with ACTH-resistant glucocorticoid deficiency with normal mineralocorticoid production and generalized intrathoracic megaesophagus (87). As in triple A syndrome patients, endogenous ACTH concentrations were markedly elevated. In addition this dog suffered from hypothyroidism, which was treated with L-T_4. After the dog was started on prednisolone treatment, the regurgitation ceased within 3 days and the megaesophagus resolved completely after a 3-month period, as indicated by thoracic radiography. This contrasts to human patients in whom the neurological fea-

tures and achalasia do not improve on glucocorticoid replacement (80). Unfortunately, the authors could not locate any littermates or ancestors of this dog who might have been of great value for genetic studies.

The view that this canine syndrome may have had a genetic basis comes from reports of two 'families' of standard poodles in which primary adrenal failure has been reported (88, 89). In these two pedigrees, female members were affected 4 times more often than males, suggesting a genetic or hormonal influence. It remains doubtful that this syndrome has any relevance to human ACTH insensitivity syndromes.

The mouse neurological mutant 'motor endplate disease' (*med*) is a neurological disorder characterized by early-onset progressive paralysis of the hind limbs, severe muscle atrophy, mild ataxia with degeneration of Purkinje cells, and juvenile lethality (90). The etiology of this disorder is discussed later in this article (see *Section III.E*).

4. Cytogenetic studies. In one early study, chromosomal abnormalities were not described in patients with triple A syndrome (57). However, recent studies using high-resolution banding techniques have revealed a variety of abnormalities in the heterochromatic region of chromosome 9q12 in affected patients. These include chromatid breaks, chromosome breaks, deletions, and marker chromosomes (S. C. Reshini, A. Weber, D. N. Finegold, A. J. L. Clark, and S. M. Gollin, in preparation). Precisely how this finding relates to the triple A locus on chromosome 12 (see below) is not clear. Linkage studies clearly exclude chromosome 9q12 as a potential triple A locus (see *Section III.D*).

5. Candidate gene studies. Several candidate genes have been proposed for the triple A syndrome. In view of the similarities between the endocrine and histological features of FGD and the triple A syndrome, it has long been proposed that defects in or near the ACTH receptor gene might also be responsible for the triple A syndrome (48, 60, 73, 77). This hypothesis is supported by numerous *in vitro* studies with ACTH and related peptides that identified it as having neuroactive, neurotrophic, and neurodevelopmental activity (91). Furthermore, there is evidence for an action of ACTH on the lacrimal gland leading to activation of a cAMP-dependent pathway that results in stimulation of protein phosphorylation and tear production (92, 93). Moore *et al.* (48) were unable to demonstrate any difference in either the affinity or capacity of lymphocyte ACTH binding between triple A patients, their siblings, and controls, using a conventional saturation assay and Scatchard analysis. It is possible, especially in view of the large affinity constants obtained, that this assay was measuring other melanocortin receptor subtypes.

Sequence analysis of the ACTH receptor gene was undertaken by ourselves in four unrelated patients and shown to be normal (94). Similar results have been reported by other groups (33, 50, 52, 53). This result does not rule out the possibility of mutations in flanking regions of the gene (*e.g.*, the promoter), and therefore we undertook a linkage study using two highly polymorphic dinucleotide repeat markers, *D18S40* and *D18S44*, which lie on chromosome 18p11.2 flanking the ACTH receptor locus at a genetic distance of 4 and 3 centimorgans (cM), respectively. Two-point linkage analysis was performed in 12 triple A syndrome families, which included 22 affected patients, and indicated log of the odds (lod) scores of less than −2 at a recombination fraction of 0.05 for both markers. The lod scores remained negative up to a recombination fraction of 0.30. Figure 5 shows a multipoint exclusion map of the region around the gene and provides conclusive evidence for the exclusion of the ACTH receptor as a candidate gene for the triple A syndrome.

As an alternative to a defect in the ACTH receptor locus, a disturbance of the cAMP signaling pathway has been proposed (2, 79). Várkonyi *et al.* demonstrated that theophylline infusion failed to stimulate a rise in plasma cortisol (62), although the latter observation could simply reflect the atrophy of the inner cortisol-producing zones of the adrenal cortex since, at least initially, Geffner *et al.* (73) demonstrated an increased cortisol secretion in response to theophylline in an affected patient. Heinrichs *et al.* (50) failed to demonstrate any gross abnormality in the levels of adenylate cyclase-stimulatory α_SG protein subunit. This work, however, did not exclude the possibility of the presence of more subtle mutations in the α_S subunit that would impair the transmission of the ACTH signal from receptor to effector. The weakness of the candidacy of any component of this system is that cAMP signaling is a widespread activity, and it may be

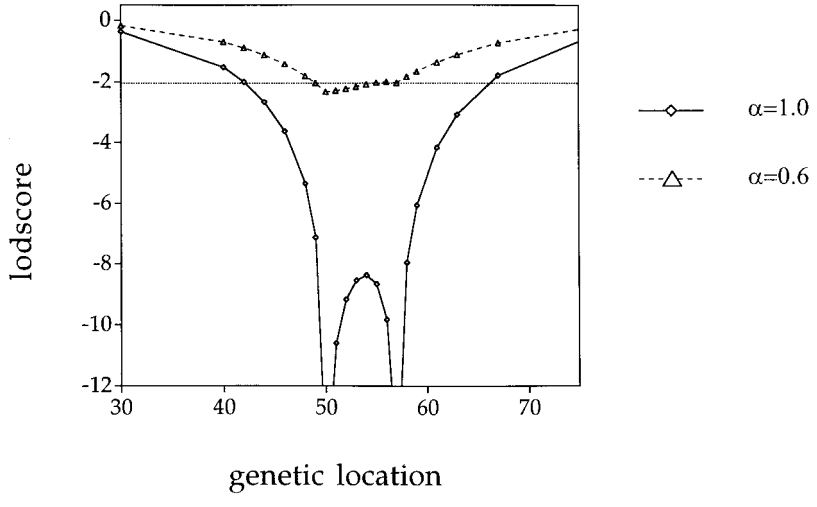

FIG. 5. Multipoint exclusion map in the region of the ACTH receptor gene locus in triple A syndrome. The *D18S40* and *D18S44* loci are shown at 50 and 57 map units, respectively. The two curves are computed assuming genetic homogeneity (α = 1.0) or genetic heterogeneity (α = 0.6) (our unpublished results).

difficult to explain the specificity of any defect primarily for adrenal, neuronal, and lacrimal tissue.

Tsao *et al.* (52) raised the question of whether mitochondrial respiratory chain enzymes could be involved in the pathogenesis of the disease. They demonstrated normal enzyme activities and no mitochondrial abnormalities, such as red ragged fibers, in a skeletal muscle biopsy, making a mitochondiopathy unlikely.

Geffner *et al.* pointed out the similarities to familial dysautonomia (Riley-Day syndrome, MIM*223900) and proposed a defect of the autonomic, or specifically the parasympathetic, nervous system or its transmitter(s) as the underlying mechanism to account for the diverse manifestations of the disorder (73). This hypothesis was taken up by several authors who claimed that many features of the triple A syndrome could be explained by a primary degeneration of cholinergic neurons resulting in a progressive loss of cholinergic function (48, 51, 60, 61, 77, 78, 80, 83). Support for this hypothesis comes from studies demonstrating that adrenal growth may be dependent on afferent neurons originating in the adrenal cortex and that the autonomic nervous system may play a role in regulating the growth and development of the adrenal cortex (95). The adrenal gland receives significant vagal (96) and thoracic splanchnic efferent innervation, which may serve to regulate function of both the adrenal medulla and cortex (97). Results from animal models underline the involvement of the autonomic nervous system in adrenal growth and corticosteroid release (98, 99).

Based on pathological studies in patients with classical achalasia, which show neuronal degeneration and reduction in neuron counts in the vagal nuclei of the brainstem, as well as in myenteric neurons of the esophageal body and lower esophageal sphincter (100), it was proposed that the primary lesion for achalasia in the triple A syndrome is extraesophageal, caused by either extrinsic neural structure changes or by defects in sympathetic or neuromuscular transmission due to defective transmitter synthesis, release, or metabolism (48, 51, 61, 73, 80). Although alacrima may occur as a consequence of absence or hypoplasia of the lacrimal gland (48), it has been shown that the lacrimal gland has autonomic nervous input (101), and so it is conceivable that a disruption of these pathways by a progressive, degenerative, neuropathic process would result in deficient tear production (61, 80). A similar neuropathic process presumably underlies the velo-pharyngeal incompetence (80).

In addition to the ACTH receptor gene, we have excluded several other genes that have been shown to influence adrenocortical function, lacrimal gland function, and esophageal motility, or which exert diverse functions as a neurotransmitter, neuromodulator, or neurotropic factor. Thus we were able to exclude vasoactive intestinal peptide (*VIP*), the type 1 VIP receptor (*VIPR1*), pituitary adenylate cyclase activating polypeptide (*PACAP*), the type 1 PACAP receptor (*ADCYAP1R1*), and neurotropin 3 (*NT3*) (84).

In view of the exclusion of these candidate genes and the absence of other obvious candidates, we reasoned that a genome-wide search for the triple A syndrome gene was warranted.

D. Mapping of the triple A syndrome gene

Moore *et al.* (48) described a large and highly inbred Métis Canadian family with triple A syndrome comprising eight affected members (48). This family has an explicit genealogy extending over six generations with multiple consanguinity loops, and as a first step we used only this family to screen for linkage. For this, we combined three microsatellite marker screening sets [UK MRC Human Genome Mapping Project primer set; Généthon, France (102); Microsatellite Center Berlin, Germany] comprising in total 345 mostly dinucleotide repeat markers spaced at approximately 10 cM intervals. Only markers from the pericentromeric region of the long arm of chromosome 12 suggested linkage to the triple A phenotype; a maximum pairwise lod score of 2.13 was obtained with marker *D12S355* at a recombination fraction of $\theta = 0.05$.

We then selected 7 additional families out of a series of 28 triple A families to test for linkage with additional closely spaced markers from this region. These families were of white European, Australian, Northern American, and Moroccan origin. Two families were consanguineous, and 4 families had two affected members. Investigating all 8 families together (19 patients, 25 unaffected siblings), we obtained a maximum lod score of 10.81 at a recombination fraction of zero with marker *D12S368* (84). Marker loci showing no recombination with the triple A trait represent the cosegregating segment. This was defined by the two markers, *D12S368* and *D12S1586*, which are approximately 4 cM apart.

The cosegregating segment maps to chromosome 12q13, which is shown in Fig. 6A (103). All patients deriving from consanguineous familes were found to be homozygous for all tested markers in this region. There was no evidence for locus heterogeneity; all families tested showed significant linkage only with markers from this segment of chromosome 12q13.

To define the smallest interval containing the triple A gene locus, we performed a haplotype analysis and identified the markers *D12S1629* (proximal) and *D12S312* (distal) as the borders of the triple A critical region. The genetic interval between these two flanking markers is approximately 6 cM (Fig. 6A) (84). Apart from the families with explicit consanguinity, three families apparently represented compound heterozygotes, at least at the marker level, and presumably at the triple A gene also. In addition, we performed a multipoint linkage analysis with nine markers from this region, revealing a maximum multipoint lod score of 13.18 at *D12S368*, and placing the triple A locus in the 6-cM interval between *D12S1629* and *D12S312* (Fig. 6B). Stratakis *et al.* (53) have confirmed the triple A gene locus on chromosome 12q13 by linkage analysis in four families.

By genetic analysis in a consanguineous Moroccan family, we recently revealed one sibling presenting with the full clinical picture of triple A syndrome, and one sibling aged 12 yr with only alacrima and mild signs of achalasia. This was the first indication that the achalasia-alacrima syndrome and the triple A syndrome may be one disease caused by mutations in the same gene (85). Hence, it will be worth studying

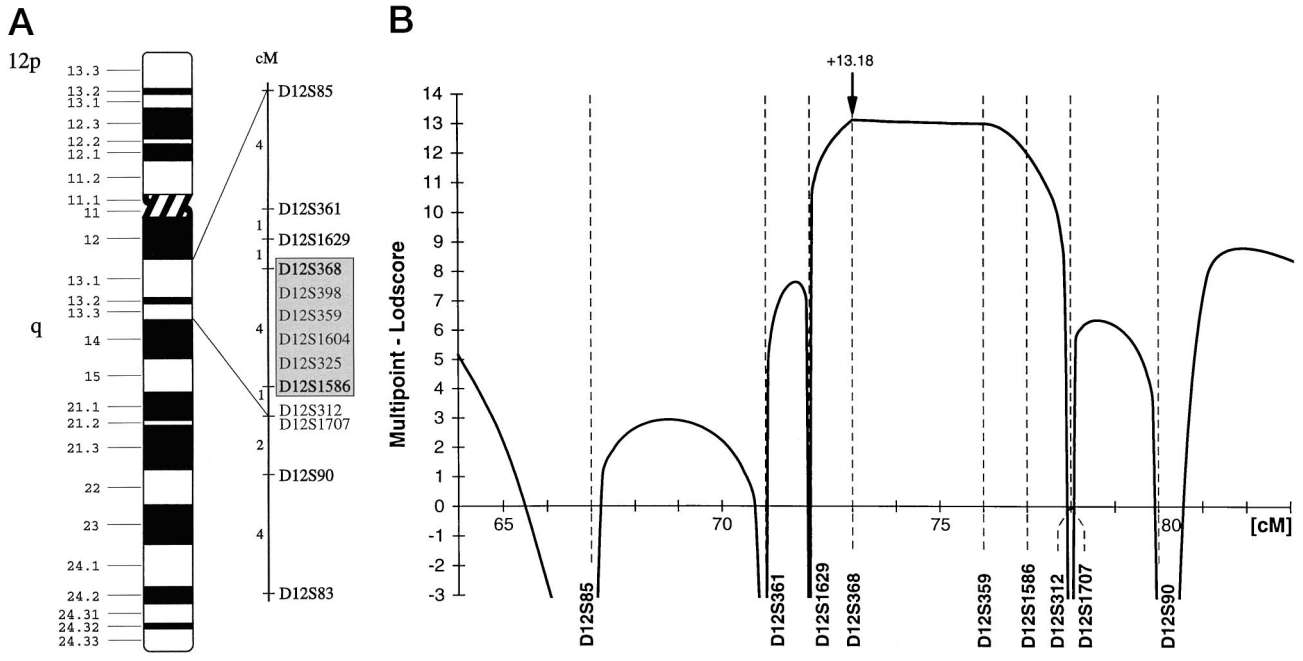

FIG. 6. A, Schematic presentation of chromosome 12 with details of the genetic map. The idiogram is at the 550-band level resolution according to ISCN 1995 (123). The genetic map is constructed using Généthon data (124); the correlation of physical and genetic location is according to Bray-Ward *et al.* (103). The *shaded box* indicates all markers from the cosegregating region of the triple A syndrome located on 12q13. [Parts of this figure are from A. Weber *et al.*: *Hum Mol Genet* 5:2061–2066, 1996 (84) by permission of Oxford University Press.] B, Multipoint lod scores between the triple A gene and markers *D12S85*, *D12S361*, *D12S1629*, *D12S368*, *D12S359*, *D12S1586*, *D12S312*, *D12S1707*, and *D12S90*. The x-axis indicates the genetic location coordinate according to the Généthon map (124); the zero coordinate is at the short arm telomere (12pter). [Parts of this figure are from A. Weber *et al.*: *Hum Mol Genet* 5:2061–2066, 1996 (84) by permission of Oxford University Press.]

families with the achalasia-alacrima syndrome in parallel in the future.

E. Candidate genes

To date, several known genes are mapped to the triple A critical region on chromosome 12q13. These are eight keratin genes forming the type II keratin gene cluster, a type I keratin gene (*KRT18*), the genes for *β-7* integrin (*ITGB7*), retinoic acid receptor gamma (*RARG*), the *trans*-acting transcription factor (*SP1*), the homeobox C5 (*HOXC5*), the zipper protein kinase (*ZPK*), and activin A receptor type II-like kinases 1 and 4 (*ACVRL1* and *ACVRL4*) (104–106). However, none of these genes appears as a strong candidate that could explain the entire triple A phenotype. The uncommon combination of the triple A symptoms makes a positional candidate gene approach very difficult. The involvement of the central, peripheral, and autonomic nervous systems as well as the adrenal and the progressive course of the disease in some patients suggest a defective neuromodulator or neurotrophic factor showing developmental and tissue-specific patterns of expression. A defective neuromodulator or even a mutant transcription factor for genes involved in the neuroendocrine system would serve as the best explanation for the apparent pleiotropic gene action (84).

The mapping of the triple A syndrome in the close vicinity of the type II keratin gene cluster and the dermatological symptoms in some triple A patients suggest an involvement of one or more keratin genes in the pathogenesis of this disorder. Hence, the hypothesis of a contiguous gene defect is supported by the phenotypic peculiarity of this syndrome. Furthermore, the expression pattern of the type II keratin genes resemble, at least in part, the pattern of the tissues involved in the triple A syndrome (107). The type II keratin gene cluster comprises eight keratin genes (*KRT1*, *−2*, *−3*, *−4*, *−5*, *−6A*, *−6B*, *−7*, and *−18*) (108). Mutations in genes of the type II keratin gene cluster have been described in epidermolytic hyperkeratosis, nonepidermolytic form of palmoplantar keratoderma (*KRT1*) (109, 110), ichthyosis bullosa of Siemens and exfoliativa (*KRT2*) (111, 112), epidermolysis bullosa simplex (*KRT5*) (113), and paronychia congenita (*KRT6A*) (114).

Marked caries with periodontitis resulting in a premature loss of primary and permanent dentition was seen in some triple A patients (see above). A link between palmoplantar hyperkeratosis and severe periodontitis is described for both the Papillon-Lefèvre syndrome (MIM*245000) and the Haim-Munk syndrome (MIM*245010). Hart *et al.* (115) demonstrated close linkage to markers near the type I and type II keratin genes on 12q13 and 17q21-q22. Laass *et al.* (116) demonstrated linkage of Papillon-Lefèvre syndrome to a 9-cM region on chromosome 11q22 containing a gene for ultrahigh sulfur-keratin (KRN1). This raises the question whether the dental and dermatological symptoms in some triple A patients are due to mutations in keratin gene(s) on 12q13. If there should be no mutations in the known keratin genes, other yet unidentified keratin genes in this region could be involved, as has been proposed by Yoon *et al.* (108).

Furthermore, the human homolog of the mouse *Scn8a* gene, encoding a voltage-gated sodium channel type VIII, was mapped to chromosome 12q13 by fluorescence *in situ*

hybridization (117). Mutations in *Scn8a* have been shown to be responsible for various mutants of the *med* phenotype characterized by severe muscle atrophy with progressive paralysis of preferentially the hind limbs, ataxia, and juvenile lethality (117–120). Burgess *et al.* (117) predicted that an impaired human *SCN8A* gene could be a candidate for a human neurological disease. In addition to the fact that some neurological features resemble those of *med* mutants, the juvenile lethality of some *med* mice remain unexplained. Hormone studies in these mice should reveal whether this feature is due to adrenal crisis. Hence, finemapping of human *SCN8A* is warranted to determine whether this gene lies within the triple A critical region.

The successful identification of the gene causing triple A syndrome may reveal novel aspects of cell signaling and neurodevelopment as well as of the regulation of adrenocortical function. Understanding the molecular defect of this disorder may allow presymptomatic testing of newborns in affected families and may permit the rational design of new therapeutic strategies preferentially aiming at the prevention of the severe neurological symptoms.

IV. Acquired ACTH Resistance

ACTH resistance is almost always an inherited disorder, the only possible exceptions being patients with autoimmune Addison's disease in which antibodies block the ACTH receptor. This is undoubtedly a rare occurrence. Kendall-Taylor *et al.* reported a study of IgG isolated from a patient with Addison's disease associated with the type 1 polyglandular syndrome and demonstrated that this inhibited ACTH-stimulated cortisol secretion by guinea pig adrenal cells (121). $(Bu)_2$cAMP, however, was able to bypass this block, and this was seen as evidence for the existence of anti-ACTH receptor antibodies. In a more extensive study, Wardle *et al.* (122) examined the effect of 29 Addison's disease patients' IgGs in the same type of bioassay. Although 12 samples inhibited ACTH-stimulated cortisol secretion, only 1 of these could be bypassed by $(Bu)_2$cAMP. It was concluded that ACTH receptor blocking antibodies were not a common cause of Addison's disease.

V. Conclusions

ACTH insensitivity syndromes are a group of rare, but probably underrecognized, diseases that result from three or more single-gene disorders. Untreated, they are potentially lethal, while glucocorticoid replacement alone in FGD is highly effective. In the current understanding of the pathogenesis of the triple A syndrome, steroid replacement is all that can be offered, and the neurological and gastrointestinal aspects of the disease can only be influenced by symptomatic treatment at present.

These diseases are fascinating in view of what they tell us about adrenal development and function. ACTH receptor mutations in patients with FGD have provided a unique insight into the role of this receptor. Unexpected effects such as the greater height of these patients remain to be explained. It seems highly probable that the next few years will reveal the identities of the gene (or genes) causing FGD type 2 and the triple A syndrome, which will undoubtedly provide further fascinating and important insights.

Acknowledgments

We would like to dedicate this review to the late Dr. David Grant, Consultant Endocrinologist to Great Ormond Street Hospital, London, who introduced us to these diseases and facilitated our studies in many ways.

We gratefully acknowledge the cooperation of all FGD and triple A families involved and the excellent information provided by their physicians. Our studies have benefitted from productive discussions with several endocinologists, most notably Professor Ashley Grossman and Dr. Martin Savage, St Bartholomew's and the Royal London School of Medicine and Dentistry. We also acknowledge the assistance of Dr. David Lowe, St Bartholomew's and the Royal London School of Medicine and Dentistry, in interpretation of the adrenal histology, and Dr. A. G. Howatson, Consultant Paediatric and Perinatal Pathologist, Royal Hospital for Sick Children, Glasgow, Professor Boehm, University of Freiburg, and Professor Siebenmann, University of Zurich, for providing histological blocks, slides, and sections of their patients. We are very grateful to Dr. Martin Farrall, Institute of Molecular Medicine, Oxford, for assistance with the exclusion of the ACTH receptor locus in the triple A syndrome.

References

1. **Shepard TH, Landing BH, Mason DG** 1959 Familial Addison's disease. Am J Dis Child 97:154–162
2. **Allgrove J, Clayden GS, Grant DB, Macaulay JC** 1978 Familial glucocorticoid deficiency with achalasia of the cardia and deficient tear production. Lancet 1:1284–1286
3. **Migeon CJ, Kenny FM, Kowarski A, Snipes CA, Spaulding JS, Finkelstein JW, Blizzard RM** 1968 The syndrome of congenital adrenocortical unresponsiveness to ACTH. Report of six cases. Pediat Res 2:501–513
4. **Monteleone JA, Monteleone PL** 1970 Hereditary adrenal unresponsiveness to ACTH—another case. Pediatrics 46:321–322
5. **Davidai G, Kahana L, Hochberg Z** 1984 Glomerulosa failure in congenital adrenocortical unresponsiveness to ACTH. Clin Endocrinol (Oxf) 20:515–520
6. **Clark AJL, McLoughlin L, Grossman A** 1993 Familial glucocorticoid deficiency associated with point mutation in the adrenocorticotropin receptor. Lancet 341:461–462
7. **Weber A, Toppari J, Harvey RD, Klann RC, Shaw NJ, Ricker AT, Nanto-Salonen K, Bevan JS, Clark AJL** 1995 Adrenocorticotropin receptor gene mutations in familial glucocorticoid deficiency: relationships with clinical features in four families. J Clin Endocrinol Metab 80:65–71
8. **Naville D, Barjhoux L, Jaillard C, Faury D, Despert F, Esteva B, Durand P, Saez JM, Begeot M** 1996 Demonstration by transfection studies that mutations in the adrenocorticotropin receptor gene are one cause of the hereditary syndrome of glucocorticoid deficiency. J Clin Endocrinol Metab 81:1442–1448
9. **Lacy DE, Nathavitharana KA, Tarlow MJ** 1993 Neonatal hepatitis and congenital insensitivity to adrenocorticotropin (ACTH). J Pediatr Gastroenterol Nutr 17:438–440
10. **Tsigos C, Arai K, Hung W, Chrousos GP** 1993 Hereditary isolated glucocorticoid deficiency is associated with abnormalities of the adrenocorticotropin receptor gene. J Clin Invest 92:2458–2461
11. **Kelch RP, Kaplan SL, Biglieri EG, Daniels GH, Epstein CJ, Grumbach MM** 1972 Hereditary adrenocortical unresponsiveness to adrenocorticotropic hormone. J Pediatr 81:726–736
12. **Ojeda SR, Andrews WW, Advis JP, White S** 1980 Recent advances in the endocrinology of puberty. Endocr Rev 1:228–257
13. **Weber A, Clark AJL, Perry LA, Honour JW, Savage MO** 1997 Diminished adrenal androgen secretion in familial glucocorticoid deficiency implicates a significant role for ACTH in the induction of adrenarche. Clin Endocrinol (Oxf) 46:431–437

14. **Franks RC, Nance WE** 1970 Hereditary adrenocortical unresponsiveness to ACTH. Pediatrics 45:43–48
15. **Stempfel RS, Engel FL** 1960 A congenital, familial syndrome of adrenocortical insufficiency without hypoaldosteronism. J Pediatr 57:443–451
16. **Thistlethwaite D, Darling JAB, Fraser R, Mason PA, Rees LH, Harkness RA** 1975 Familial glucocorticoid deficiency. Studies of diagnosis and pathogenesis. Arch Dis Child 50:291–297
17. **Soltesz G, Dillon MJ, Jenkins PA, Moore A, Aynsley-Green A** 1985 Isolated glucocorticoid deficiency: metabolic and endocrine studies in a 5 year old boy. Eur J Pediatr 143:297–300
18. **Grant DB, Barnes ND, Moncrieff MW, Savage MO** 1985 Clinical presentation, growth, and pubertal development in Addison's disease. Arch Dis Child 60:925–928
19. **Spark RF, Etzkorn JR** 1977 Absent aldosterone response to ACTH in familial glucocorticoid deficiency. N Engl J Med 297:917–920
20. **Williams HE, Freeman M** 1965 Primary familial Addison's disease. Aust Paediatr J 1:93–97
21. **Smith EM, Brosnan P, Meyer WJ, Blalock JE** 1987 An ACTH receptor on human mononuclear leukocytes. Relation to adrenal ACTH-receptor activity. N Engl J Med 317:1266–1269
22. **Yamaoka T, Kudo T, Takuwa Y, Kawakami Y, Itakura M, Yamashita K** 1992 Hereditary adrenocortical unresponsiveness to adrenocorticotropin with a postreceptor defect. J Clin Endocrinol Metab 75:270–274
23. **Moshang Jr T, Rosenfield RL, Bongiovanni AM, Parks JS, Amrhein JA** 1973 Familial glucocorticoid insufficiency. J Pediatr 82: 821–826
24. **Mountjoy KG, Robbins LS, Mortrud MT, Cone RD** 1992 The cloning of a family of genes that encode melanocortin receptors. Science 257:1248–1251
25. **Chhajlani V, Muceniece R, Wikberg JES** 1993 Molecular cloning of a novel human melanocortin receptor. Biochem Biophys Res Commun 195:866–873
26. **Gantz I, Konda Y, Tashiro T, Shimoto Y, Miwa H, Munzert G, Watson SJ, DelValle J, Yamada T** 1993 Molecular cloning of a novel melanocortin receptor. J Biol Chem 268:8246–8250
27. **Gantz I, Miwa H, Konda Y, Shimoto Y, Tashiro T, Watson SJ, DelValle J, Yamada T** 1993 Molecular cloning, expression, and gene localization of a fourth melanocortin receptor. J Biol Chem 268:15174–15179
28. **Roselli-Rehfus L, Mountjoy KG, Robbins LS, Mortrud MT, Low MJ, Tatro JB, Entwistle ML, Simerly RB, Cone RD** 1993 Identification of a receptor for gamma-melanotropin and other proopiomelanocortin peptides in the hypothalamus and limbic system. Proc Natl Acad Sci USA 90:8856–860
29. **Gantz I, Shimoto Y, Konda Y, Miwa H, Dickinson CJ, Yamada T** 1994 Molecular cloning, expression and characterization of a fifth melanocortin receptor. Biochem Biophys Res Commun 200:1214–1220
30. **Kapas S, Cammas FM, Hinson JP, Clark AJL** 1996 Agonist and receptor binding properties of adrenocorticotropin peptides using the cloned mouse ACTH receptor expressed in a stably transfected HeLa cell line. Endocrinology 137:3291–3294
31. **Griffon N, Mignon V, Facchinetti P, Diaz J, Schwartz JC, Sokoloff P** 1994 Molecular cloning and characterization of the rat fifth melanocortin receptor. Biochem Biophys Res Commun 200:1007–1014
32. **Labbe O, Desarnaud F, Eggerickx D, Vassart G, Parmentier M** 1994 Molecular cloning of a mouse melanocortin 5 receptor gene widely expressed in peripheral tissues. Biochemistry 33:4543–4549
33. **Tsigos C, Arai K, Latronico AC, DiGeorge AM, Rapaport R, Chrousos GP** 1995 A novel mutation of the adrenocorticotropin receptor (ACTH-R) gene in a family with the syndrome of isolated glucocorticoid deficiency, but no ACTH-R abnormalities in two families with the triple A syndrome. J Clin Endocrinol Metab 80: 2186–2189
34. **Slavotinek AM, Hurst JA, Dunger D, Wilkie AO** 1998 ACTH receptor mutation in a girl with familial glucocorticoid deficiency. Clin Genet 53:57–62
35. **Weber A, Kapas S, Hinson J, Grant DB, Grossman A, Clark AJL** 1993 Functional characterization of the cloned human ACTH receptor: impaired responsiveness of a mutant receptor in familial glucocorticoid deficiency. Biochem Biophys Res Commun 197:172–178
36. **Schimmer BP, Kwan WK, Tsao J, Qiu R** 1995 Adrenocorticotropin-resistant mutants of the Y1 adrenal cell line fail to express the adrenocorticotropin receptor. J Cell Physiol 163:164–171
37. **Elias LLK, Pullinger GD, Weber A, Clark AJL** 1997 Functional analysis of the I44M mutant ACTH receptor found in familial glucocorticoid deficiency. J Endocrinol 155:29
38. **Light K, Jenkins PJ, Weber A, Perrett C, Grossman A, Pistorello M, Asa SL, Clayton RN, Clark AJL** 1995 Are activating mutations of the adrenocorticotropin receptor involved in adrenal cortical neoplasia? Life Sci 56:1523–1527
39. **Latronico AC, Reincke M, Mendonca BB, Arai K, Mora P, Allolio B, Wajchenberg BL, Chrousos GP, Tsigos C** 1995 No evidence for oncogenic mutations in the adrenocorticotropin receptor gene in human adrenal neoplasms. J Clin Endocrinol Metab 80:875–877
40. **Yanovski JA, Yanovski SZ, Gold PW, Chrousos GP** 1993 Differences in the hypothalamic-pituitary-adrenal axis of black and white women. J Clin Endocrinol Metab 77:536–541
41. **Gantz I, Tashiro T, Barcroft C, Konda Y, Shimoto Y, Miwa H, Glover T, Munzert T, Yamada T** 1993 Localization of the genes encoding the melanocortin-2 (adrenocorticotropic hormone) and melanocortin-3 receptors to chromosomes 18p11.2 and 20q13.2-q13.3 by fluorescence *in situ* hybridization. Genomics 18:166–167
42. **Magenis RE, Smith L, Nadeau JH, Johnson KR, Mountjoy KG, Cone RD** 1994 Mapping of the ACTH, MSH, and neural (MC3 & MC4) melanocortin receptors in the mouse and human. Mamm Genome 5:503–508
43. **Weber A, Clark AJL** 1994 Mutations of the ACTH receptor gene are only one cause of familial glucocorticoid deficiency. Hum Mol Genet 3:585–588
44. **Clark AJL, Cammas FM, Watt A, Kapas S, Weber A** 1997 Familial glucocorticoid deficiency: one syndrome, but more than one gene. J Mol Med 75:394–399
45. **Counahan R, West R** 1974 Ocular and fingertip abnormalities in isolated glucocorticoid deficiency. J Pediatr 85:580–581
46. **Petrykowski W, Burmeister P, Böhm N** 1975 Familiäre Glucocorticoidinsuffizienz. Klin Padiatr 187:198–215
47. **Werder EA, Haller R, Vetter W, Zachmann M, Siebenmann R** 1975 Isolated glucocorticoid insufficiency. Helv Paediatr Acta 30:175–183
48. **Moore PSJ, Couch RM, Perry YS, Shuckett EP, Winter JSD** 1991 Allgrove syndrome: an autosomal recessive syndrome of ACTH insensitivity, achalasia and alacrima. Clin Endocrinol (Oxf) 34:107–114
49. **Dumic M, Radica A, Sabol Z, Plavöic V, Brkljacic L, Sarnavka V, Vukovi J** 1991 Adrenocorticotropic hormone insensitivity associated with autonomic nervous system disorders. Eur J Pediatr 150: 696–699
50. **Heinrichs C, Tsigos C, Deschepper J, Drews R, Collu R, Dugardeyn C, Goyens P, Ghanem GE, Bosson D, Chrousos GP, Van Vliet G** 1995 Familial adrenocorticotropin unresponsiveness associated with alacrima and achalasia: biochemical and molecular studies in two siblings with clinical heterogeneity. Eur J Pediatr 154:191–196
51. **Nihoul-Fékété C, Bawab F, Lortrat-Jacob S, Arhan P, Pellerin D** 1989 Achalasia of the esophagus in childhood: surgical treatment in 35 cases with special reference to familial cases and glucocorticoid deficiency association. J Pediatr Surg 24:1060–1063
52. **Tsao CY, Romshe CA, Lo WD, Wright FS, Sommer A** 1994 Familial adrenal insufficiency, achalasia, alacrima, peripheral neuropathy, microcephaly, normal plasma very long chain fatty acids, and normal muscle mitochondrial respiratory chain enzymes. J Child Neurol 9:135–138
53. **Stratakis CA, Lin JP, Pras E, Rennert OM, Bourdony CJ, Chan WY** 1997 Segregation of Allgrove (triple-A) syndrome in Puerto Rican kindreds with chromosome 12 (12q13) polymorphic markers. Proc Assoc Am Physicians 109:478–482
54. **Yordam N, Kandemir N** 1996 Familial glucocorticoid deficiency: clinical spectrum and endocrine details in five Turkish children. Horm Res 46[Suppl] 92
55. **Hübschmann K** 1995 Achalasie, Alakrimie und Cortisolmangel - das Allgrove Syndrom. Klin Padiatr 207:126–129

56. **Lanes R, Plotnick LP, Bynum TE, Lee PA, Casella JF, Fox CE, Kowarski AA, Migeon CJ** 1980 Glucocorticoid and partial mineralocorticoid deficiency associated with achalasia. J Clin Endocrinol Metab 50:268–270
57. **Ehrich E, Aranoff G, Johnson WG** 1987 Familial achalasia associated with adrenocortical insufficiency, alacrima, and neurological abnormalities. Am J Med Genet 26:637–644
58. **Fernbach SK, Poznanski AK** 1989 Pediatric case of the day. Radiographics 9:563–564
59. **Hammami A, Trabelsi M, Bennaceur B, Boukhris R** 1989 Association d'une maladie d'Addison, d'une achalasie du cardia et d'une alacrymation. A propos de deux observations. Ann Pediatr (Paris) 36:279–282
60. **Grant DB, Barnes ND, Dumic M, Ginalska-Malinowska M, Milla PJ, von Petrykowski W, Rowlatt RJ, Steendijk R, Wales JHK, Werder E** 1993 Neurological and adrenal dysfunction in the adrenal insufficiency/alacrima/achalasia (3A) syndrome. Arch Dis Child 68:779–782
61. **Gazarian M, Cowell CT, Bonney M, Grigor WG** 1995 The "4A" syndrome: adrenocortical insufficiency associated with achalasia, alacrima, autonomic and other neurological abnormalities. Eur J Pediatr 154:18–23
62. **Várkonyi Á, Jukesz J, Szüts P, Tóth I, Faredin I** 1992 Simultaneous occurrence of selective ACTH insensitivity, achalasia and alacrima accompanied by hyperlipoproteinaemia. Acta Paediatr Hung 32: 31–42
63. **Phillip M, Hershkovitz E, Schulman H** 1996 Adrenal insufficiency after achalasia in the triple A syndrome. Clin Pediatr (Phila) 35: 99–100
64. **Dugardeyn C, Anooshiravani M, Christophe C, Goyens P, Perlmutter N** 1993 Achalasia-alacrima-ACTH insensitivity syndrome (triple A syndrome). J Belge Radiol 76:167–168
65. **Koivukangas T, Similä S, Heikkinen E, Räsänen O, Wasz-Höckert O** 1973 Sjögren's syndrome and achalasia of the cardia in two siblings. Pediatrics 51:934–935
66. **Similä S, Kokkonen J, Kaski M** 1978 Achalasia sicca—juvenile Sjögren's syndrome with achalasia and gastric hyposecretion. Eur J Pediatr 129:175–181
67. **Efrati Y, Mares AJ** 1985 Infantile achalsia associated with deficient tear production. J Clin Gastroenterol 7:413–415
68. **Nussinson E, Hager H, Samara M, Bar-Nathan N, Siplovich L** 1988 Familial achalasia with absent tear production. J Pediatr Gastrenterol Nutr 7:284–287
69. **Haverkamp F, Zerres K, Rosskamp R** 1989 Three sibs with achalasia and alacrimia: a separate entity different from triple-A syndrome. Am J Med Genet 34:289–291
70. **el-Rayyes K, Hegab S, Besisso M** 1991 A syndrome of alacrima, achalasia, and neurological anomalities without adrenocortical insufficiency. J Pediatr Ophthalmol Strabismus 28:35–37
71. **Micetic-Turk D, Tomazic D** 1995 Achalasia with absent tear production. Acta Paediatr 84:835–838
72. **Kasirga E, Özkinay F, Tütüncüoglu S, Aydogdu S, Çolakoglu Z, Musoglu A, Yagci A, Taneli B, Yagci RV** 1996 Four siblings with achalasia, alacrimia and neurological abnormalities in a consanguineous family. Clin Genet 49:296–299
73. **Geffner ME, Lippe BM, Kaplan SA, Berquist WE, Bateman JB, Paterno VI, Seegan R** 1983 Selective ACTH insensitivity, achalasia, and alacrima: a multisystem disorder presenting in childhood. Pediatr Res 17:532–536
74. **Chrzanowska B, Romer TE, Baka-Jakubiak M, Kansy J** 1987 The syndrome of adrenocortical unresponsiveness to ACTH with achalasia. Endokrynol Pol 38:107–115
75. **Grant DB, Dunger DB, Smith I, Hyland K** 1992 Familial glucocorticoid deficiency with achalasia of the cardia, associated with mixed neuropathy, long tract degeneration and mild dementia. Eur J Pediatr 151:85–89
76. **Ambrosino MM, Genieser NB, Bangaru BS, Sklar C, Becker MH** 1986 The syndrome of achalasia of the esophagus, ACTH insensitivity and alacrima. Pediatr Radiol 16:328–329
77. **Stuckey BG, Mastaglia FL, Reed WD, Pullan PT** 1987 Glucocorticoid insufficiency, achalasia, alacrima with autonomic motor neuropathy. Ann Intern Med 106:61–63
78. **Chu ML, Berlin D, Axelrod FB** 1996 Allgrove syndrome: documenting cholinergic dysfunction by autonomic tests. J Pediatr 129: 156–159
79. **Dumic M, Radica A, Juöik A, Stefanovic N, Murko Z** 1987 Selective ACTH insensitivity associated with autonomic nervous system disorders and sensory polyneuropathy. Eur J Pediatr 146:592–594
80. **Fagan JE, McArtur RG, Machida H, Hindle W, Wesenberg R** 1987 Palatopharyngeal incompetence in association with esophageal dysmotility, acquired glucocorticoid deficiency, and deficient tear production. Clin Invest Med 10:345–349
81. **Degli Esposti A, Ambrosioni G, Giardina A, Giovannini G, Laghi MG, Molinari PP, Salvatori P, Zaniboni MG** 1985 Sindrome familiare di ipoglicocorticismo da insensibilatà all'ACTH, acalasia, alacrima, con associata neuromiopatia distale. Minerva Pediatr 37: 353–359
82. **Pombo M, Devesa J, Taborda A, Iglesias M, García-Moreno F, Gaudiero GJ, Martinón JM, Castro-Gago M, Peña J** 1985 Glucocorticoid deficiency with achalasia of the cardia and lack of lacrimation. Clin Endocrinol (Oxf) 23:237–243
83. **Makari G, Hoffman WH, Carroll JE, Savage DR, Van der Zalm T** 1988 Autonomic dysfunction and adrenal unresponsiveness to ACTH. J Child Neurol 3:174–176
84. **Weber A, Wienker TF, Jung M, Easton D, Dean HJ, Heinrichs C, Reis A, Clark AJL** 1996 Linkage of the gene for the triple A syndrome to chromosome 12q13 near the type II keratin gene cluster. Hum Mol Genet 5:2061–2066
85. **Weber A, De Vroede M, Wienker TF, Jansen M** 1997 Clinical variability and molecular genetics in a family with triple A syndrome. Horm Res 48[Suppl 2]:191
86. **Rezvani I, DiGeorge AM, Garibaldi LR, Bourdony CJ** 1983 Familial glucocorticoid deficiency (FGD) with lacrimal and esophageal dysfunction: evidence against an ACTH "receptor defect." Pediatr Res 17:170A
87. **Bartges JW, Nielson DL** 1992 Reversible megaesophagus associated with atypical primary hypoadrenocorticism in a dog. J Am Vet Med Assoc 201:889–891
88. **Auge P** 1985 Addison's disease in littermates. Vet Med (Praha) 80:43–45
89. **Shaker E, Hurvitz AI, Peterson ME** 1988 Hypoadrenocorticism in a family of Standard Poodles. J Am Vet Med Assoc 192:1091–1092
90. **Green M** 1989 Catalog of Mutant Genes and Polymorphic Loci. In: Lyon MF, Searle AG (eds) Genetic Variants and Strains of the Laboratory Mouse, Oxford University Press, Oxford, pp 234–235
91. **de Wied** 1990 Neurotropic effects of ACTH/MSH neuropeptides. Acta Neurobiol Exp (Warsz) 50:353–366
92. **Cripps MM, Bromberg BB, Patchen-Moor K, Welch MH** 1987 Adrenocorticotropic hormone stimulation of lacrimal peroxidase secretion. Exp Eye Res 45:673–682
93. **Salomon Y** 1990 Melanocortin receptors: targets for control by extracellular calcium. Mol Cell Endocrinol 70:139–145
94. **Clark AJL, Weber A** 1994 Molecular insights into inherited ACTH resistant syndromes. Trends Endocrinol Metab 5:209–214
95. **Dallman MF, Engeland WC, McBride MH** 1977 The neural regulation of compensatory adrenal growth. Ann NY Acad Sci 297: 373–392
96. **Coupland RE, Parker TL, Kesse WK, Mohamed AA** 1989 The innervation of the adrenal gland. III. Vagal innervation. J Anat 163:173–181
97. **Holzwarth MA, Cunningham LA, Kleitman N** 1987 The role of adrenal nerves in the regulation of adrenocortical functions. Ann NY Acad Sci 512:449–464
98. **Unsicker K, Groschel-Stewart U** 1977 Distribution of contractile proteins and adrenergic nerves in the adrenal gland of guinea pig, rat, and ox as revealed by immunofluorescence and the glyoxylic acid technique. Experentia 34:102–105
99. **Lowry PJ, Silas L, McLean C, Linton EA, Estivariz FE** 1983 Progamma-melanocyte-stimulating hormone cleavage in adrenal gland undergoing compensatory growth. Nature 306:70–73
100. **Cohen S** 1979 Motor disorders of the esophagus. N Engl J Med 301:184–192
101. **Johnson RH** 1983 Autonomic failure and the eyes. In: Bannister R (ed) Autonomic Failure. A Textbook of Clinical Disorders of the

Autonomous Nervous System. Oxford University Press, Oxford, UK, pp 509–542
102. **Gyapay G, Morissette J, Vignal A, Dib C, Fizames C, Millasseau P, Marc S, Bernardi G, Lathrop M, Weissenbach J** 1994 The 1993–94 Généthon human genetic linkage map. Nat Genet 7:246–339
103. **Bray-Ward P, Menninger J, Lieman J, Desai T, Mokady N, Banks A, Ward DC** 1996 Integration of the cytogenetic, genetic, and physical maps of the human genome by FISH mapping of CEPH YAC clones. Genomics 32:1–14
104. **Kucherlapati R, Craig I, Marynen P** 1994 Report and abstracts on the second international workshop on human chromosome 12 mapping 1994. Cytogenet Cell Genet 67:245–276
105. **Krauter K, Montgomery K, Yoon S-J, LeBlanc-Straceski J, Renault B, Marondel I, Herdman V, Cupelli L, Banks A, Lieman J, Menninger J, Bray-Ward P, Nadkarni P, Weissenbach J, Le Paslier D, Rigault P, Chumakov I, Cohen D, Miller P, Ward D, Kucherlapati R** 1995 A second-generation YAC contig map of human chromosome 12. Nature 377 [Suppl]:321–334
106. **Kucherlapati R, Marynen P, Turc-Carel C** 1997 Report of the fourth international workshop on human chromosome 12 mapping, 1997. Cytogenet Cell Genet 78:82–95
107. **Moll R, Franke WW, Schiller DL, Geiger B, Krepler R** 1982 The catalog of human cytokeratins: patterns of expression in normal epithelia, tumors and cultured cells. Cell 31:11–24
108. **Yoon SJ, LeBlanc-Straceski J, Ward D, Krauter K, Kucherlapati R** 1994 Organisation of the human keratin type II gene cluster at 12q13. Genomics 24:502–508
109. **Compton JG** 1994 Epidermal disease: faulty keratin filaments take their toll. Nat Genet 6:6–7
110. **Kimonis V, DiGiovanna JJ, Yang J-M, Doyle SZ, Bale SJ, Compton JG** 1994 A mutation in the V1 end domain of keratin 1 in non-epidermolytic palmar-plantar keratoderma. J Invest Dermatol 103:764–769
111. **McLean WH, Morley SM, Lane EB, Eady RAJ, Griffiths WA, Paige DG, Harper JI, Higgins C, Leigh IM** 1994 Ichthyosis bullosa of Siemens—a disease involving keratin 2e. J Invest Dermatol 103: 277–281
112. **Rothnagel JA, Traupe H, Wojcik S, Huber M, Hohl D, Pittelkow MR, Saeki H, Ishibashi Y, Roop DR** 1994 Mutations in the rod domain of keratin 2e in patients with ichthyosis bullosa of Siemens. Nat Genet 7:485–490
113. **Lane EB, Rugg EL, Navrasia H, Leigh IM, Heagerty AH, Ishida-Yamamoto A, Eady RA** 1992 A mutation in the conserved helix termination peptide of keratin 5 in hereditary skin blistering. Nature 356:244–246
114. **Bowden PE, Haley JL, Kansky A, Rothnagel JA, Jones DO, Turner RJ** 1995 Mutation of a type II keratin gene (K6a) in paronychia congenita. Nat Genet 10:363–365
115. **Hart TC, Stabholz A, Meyle J, Shapira L, Van Dyke TE, Cutler CW, Soskolne WA** 1997 Genetic studies of syndromes with severe periodontitis and palmoplantar hyperkeratosis. J Periodontal Res 32:81–89
116. **Laass MW, Hennies HC, Preis S, Stevens HP, Jung M, Leigh IM, Wienker TF, Reis A** 1997 Localization of a gene for Papillon-Lefèvre syndrome to chromosome 11q14–q21 by homozygosity mapping. Hum Genet 101:376–382
117. **Burgess DL, Kohrman DC, Galt J, Plummer NW, Jones JM, Spear B, Meisler MH** 1995 Mutation of a new sodium channel gene, Scn8a, in the mouse mutant 'motor endplate disease.' Nat Genet 10:461–465
118. **Kohrman DC, Plummer NW, Schuster T, Jones JM, Jang W, Burgess DL, Galt J, Spear BT, Meisler MH** 1995 Insertional mutation of the motor endplate disease (*med*) locus on mouse chromosome 15. Genomics 26:171–177
119. **Kohrman DC, Harris JB, Meisler MH** 1996 Mutation detection in the *med* and *medJ* alleles of the sodium channel Scn8a. Unusual splicing due to a minor class AT-AC intron. J Biol Chem 271:17576–17581
120. **Kohrman DC, Smith MR, Goldin AL, Harris J, Meisler MH** 1996 A missense mutation in the sodium channel Scn8A is responsible for cerebellar ataxia in the mouse mutant jolting. J Neurosci 16: 5993–5999
121. **Kendall-Taylor P, Lambert A, Mitchell R, Robertson WR** 1988 Antibody that blocks stimulation of cortisol secretion by adrenocorticotropic hormone in Addison's disease. Br Med J 296:1489–1491
122. **Wardle CA, Weetman AP, Mitchell R, Peers N, Robertson WR** 1993 Adrenocorticotropic hormone receptor-blocking immunoglobulins in serum from patients with Addison's disease: a reexamination. J Clin Endocrinol Metab 77:750–753
123. **Mitelman F (ed)** 1995 ISCN: An International System for Human Cytogenetic Nomenclature. S. Karger, Basel, Switzerland
124. **Dib C, Fauré S, Fizames C, Samson D, Drouot N, Vignal A, Millasseau P, Marc S, Hazan J, Seboun E, Lathrop M, Gyapay G, Morissette J, Weissenbach J** 1996 A comprehensive genetic map of the human genome based on 5264 microsatellites. Nature 380:152–154