

Germ Cell Tumors in the Intersex Gonad: Old Paths, New Directions, Moving Frontiers

Martine Cools, Stenvert L. S. Drop, Katja P. Wolffenbuttel, J. Wolter Oosterhuis, and Leendert H. J. Looijenga

Department of Pathology (M.C., J.W.O., L.H.J.L.), Erasmus MC–University Medical Center Rotterdam, Daniel den Hoed Cancer Center, Josephine Nefkens Institute, Rotterdam, The Netherlands; and Departments of Pediatric Endocrinology (M.C., S.L.S.D.) and Pediatric Urology (K.P.W.), Erasmus MC–Sophia Children's Hospital, Rotterdam, The Netherlands

The risk for the development of germ cell tumors is an important factor to deal with in the management of patients with disorders of sex development (DSD). However, this risk is often hard to predict. Recently, major progress has been made in identifying gene-products related to germ cell tumor development (testis-specific protein-Y encoded and octamer binding transcription factor 3/4) and in recognizing early changes of germ cells (maturation delay, preneoplastic lesions, and *in situ* neoplasia). The newly recognized “undifferentiated gonadal tissue” has been identified as a gonadal differentiation pattern bearing a high risk for the development of gonadoblastoma. It is expected that the combination of these findings will allow for estimation of the risk for tumor development in the individual patient (high risk/intermediate

risk/low risk). This article reviews the recent literature regarding the prevalence of germ cell tumors in patients with DSD. Some major limitations regarding this topic, including a confusing terminology referring to the different forms of intersex disorders and unclear criteria for the diagnosis of malignant germ cells at an early age (maturation delay *vs.* early steps in malignant transformation) are discussed. Thereafter, an overview of the recent advances that have been made in our knowledge of germ cell tumor development and the correct diagnosis of early neoplastic lesions in this patient population is provided. A new classification system for patients with DSD is proposed as a tool to refine our insight in the prevalence of germ cell tumors in specific diagnostic groups. (*Endocrine Reviews* 27: 468–484, 2006)

- I. Introduction
- II. Gonadal Tumors in Intersex Patients
- III. The Prevalence of Germ Cell Tumors in Patients with Disorders of Sex Development
 - A. Hypervirilization syndromes
 - B. Undervirilization syndromes
 - C. Gonadal dysgenesis
 - D. Conclusions
- IV. The Use of Immunohistochemical Markers for the Diagnosis of Germ Cell Tumors in Patients with Disorders of Sex Development
 - A. OCT3/4 (POU5F1)
 - B. The testis-specific protein-Y encoded (TSPY)
- V. Maturation Delay *vs.* CIS: Transitional Changes of the Germ Cells
 - A. Maturation delay of germ cells
 - B. Pitfalls in the diagnosis of early germ cell neoplasia
 - C. Progression toward malignancy
- VI. CIS or Gonadoblastoma?

- VII. Proposal for a New Classification of Patients with Disorders of Sex Development according to Their Risk for the Development of Germ Cell Tumors and Future Perspectives

I. Introduction

DISORDERS OF SEX development (DSD) or intersex disorders refer to conditions of incomplete or disordered genital or gonadal development leading to a discordance between genetic sex, gonadal sex, and phenotypic sex (1). Together, DSD form a complex entity of heterogeneous etiology that affect the four different dimensions (genetic sex, gonadal sex, phenotypic sex, and behavioral sex) of sex development. Many classification systems have attempted to offer a comprehensive overview (1, 2). From a clinical as well as a pathological point of view, the distinction between disorders of gonadal dysgenesis (GD), which affect the level of gonadal sex on the one hand, and syndromes of hypervirilization and undervirilization, which affect the level of phenotypic sex on the other, seems to be the most valuable and will therefore be used for the purpose of this article.

Since the rejection of the classic anthropocentric paradigm for the treatment of patients with DSD as it was established by Money and Ehrhardt in the 1950s to 1970s (3), the optimal management for these patients has been a continuous matter of debate (4–15). However, the malignant potential of the dysgenetic gonad (16–22) opposes itself firmly to the recent interest in a more conservative approach regarding gonadectomy. Safe guidelines for a policy of including patients in a “watchful waiting” protocol are highly needed. They must be evidence-based but can also profit from new, promising

First Published Online May 30, 2006

Abbreviations: AIS, Androgen insensitivity syndrome; CAIS, complete AIS; CIS, carcinoma *in situ*; DG, dysgerminoma; DSD, disorders of sex development; EC, embryonal carcinoma; ESC, embryonal stem cell; GB, gonadoblastoma; GD, gonadal dysgenesis; HSD, hydroxysteroid dehydrogenase; ITGNU, intratubular germ cell neoplasia unclassified; OCT3/4, octamer binding transcription factor 3/4 [alternatively referred to as POU5F1 (POU domain class 5 transcription factor 1)]; PAIS, partial AIS; PGC, primordial germ cell; PLAP, placental-like alkaline phosphatase; SC, sex cord(s); TSPY, testis-specific protein-Y encoded; UGT, undifferentiated gonadal tissue.

Endocrine Reviews is published by The Endocrine Society (<http://www.endo-society.org>), the foremost professional society serving the endocrine community.

techniques for the diagnosis of *in situ* neoplastic lesions and even preneoplastic changes of germ cells in gonadal biopsy samples of intersex patients. Therefore, this article provides a detailed and updated overview of the literature regarding the occurrence of germ cell tumors in patients with DSD and outlines the major recent progress that has been made in our understanding of the pathogenesis of germ cell tumors and the early recognition of (pre-)neoplastic changes. Based on this broadened knowledge, a tentative new classification for patients with DSD is proposed that may serve as a tool for estimating the risk for germ cell tumor development in an individual patient.

II. Gonadal Tumors in Intersex Patients

The so-called “type II germ cell tumors of the testis and the dysgenetic gonad” (Table 1) (for a detailed overview of the various types of germ cell tumors and their characteristics, see Ref. 23) are by far the most frequently occurring and feared tumors in patients with DSD. Therefore, this review will exclusively focus on this group of tumors. However, sporadically, other gonadal (benign and malignant) neoplasms are reported in patients with DSD, often in combination with the above-mentioned type II germ cell tumors. These include sex cord (SC)-stromal tumors [juvenile granulosa cell tumor (24), Sertoli-Leydig cell tumor (25), and Sertoli cell nodules (26–28)] and epithelial tumors [Brenner tumor (29), mucinous cystadenoma (24, 29), and Müllerian cyst (26)].

The invasive type II germ cell tumors that are encountered in the intersex gonad are the seminoma (if the gonad is considered a testis)/dysgerminoma (DG) (if the gonad is considered an ovary) and the nonseminoma. The development of these invasive tumors is always preceded by the presence of an *in situ* neoplastic lesion—intratubular germ

cell neoplasia unclassified (ITGNU) or gonadoblastoma (GB) (for a detailed histological description of ITGNU, GB, and invasive tumors, see Ref. 30). The ITGNU lesion is commonly known as carcinoma *in situ* (CIS), and although this latter term, suggesting a neoplasm of epithelial origin, is less accurate, we will use it for the purpose of this review.

Germ cells in intersex gonads may undergo transient benign changes, pointing at a delay in their maturation, which are often hard to distinguish from an *in situ* neoplastic lesion (28, 31). However, this benign condition may, in some cases, predispose to malignancy (see Section V). Because gonadectomies in patients with DSD are often performed prophylactically in early childhood, most of the encountered changes in germ cells are benign or *in situ* malignant lesions.

Although β -human chorionic gonadotropin (choriocarcinoma) and α 1-fetoprotein (yolk sac tumor) are well-established serum tumor markers for the diagnosis and follow-up of specific type II germ cell tumors (32–34), no studies exist at present on the value and applicability of these and other serum markers [placental-like alkaline phosphatase (PLAP), octamer binding transcription factor 3/4 (OCT3/4), testis-specific protein-Y encoded (TSPY)] for screening and early tumor detection in patients with DSD.

III. The Prevalence of Germ Cell Tumors in Patients with Disorders of Sex Development

The prevalence of germ cell tumors is increased in patients with DSD containing Y chromosome material in their karyotype and is probably related to the presence of the *TSPY* gene (see Section IV.B) (35–39). The presence of *SRY* or other sex determining genes is irrelevant in this context. The ectopic position of the (dysgenetic) testis adds to this risk because the prevalence of germ cell tumors in simple cryptorchidism is

TABLE 1. The five types of germ cell tumors (based on Ref. 23)

Type	Anatomical site	Phenotype	Age	Originating cell	Genomic imprinting	Genotype
I	Testis/ovary/sacral region/retroperitoneum/mediastinum/neck/midline brain/other rare sites	(Immature) teratoma/yolk-sac tumor	Neonates and children	Early PGC/gonocyte	Biparental partially erased	Diploid (teratoma), Aneuploid (yolk-sac tumor): gain of 1q, 12(p13), and 20q, loss of 1p, 4 and 6q
II ^a	Testis	Seminoma/nonseminoma	>15 yr (median, 35 and 25 yr)	PGC/gonocyte	Erased	Aneuploid (+/– triploid): gain of X, 7, 8, 12p and 21, loss of Y, 1p, 11, 13 and 18
	Ovary	Dysgerminoma/nonseminoma	>4 yr	PGC/gonocyte	Erased	Aneuploid
	Dysgenetic gonad	Dysgerminoma/nonseminoma	Congenital	PGC/gonocyte	Erased	Diploid/tetraploid
III	Testis	Spermatocytic seminoma	>50 yr	Spermatogonium/spermatocyte	Partially complete paternal	Aneuploid: gain of 9
IV	Ovary	Dermoid cyst	Children/adults	Oogonia/oocyte	Partially complete maternal	(Near) diploid, diploid/tetraploid, peritriploid (gain of X, 7, 12 and 15)
V	Placenta/uterus	Hydatidiform mole	Fertile period	Empty ovum/spermatozoa	Completely paternal	Diploid (XX and XY)

^a Germ cell tumors occurring along the midline of the body (anterior mediastinum, midline of the brain) also belong to the group of type II germ cell tumors.

estimated at four to 10 times the normal prevalence of 6–11 per 100,000 (17, 30, 40, 41).

Traditionally, the prevalence of germ cell tumors in patients with GD is estimated at around 30% (17) and in patients with undervirilization syndromes at 5–10% (42, 43). However, reported prevalence numbers per diagnostic group may vary considerably. In our view, this is at least in part due to two major methodological problems. First, there are no well-established criteria for the diagnosis of early neoplastic changes (CIS) in young children, leading to a different interpretation of results by different research groups (see below) (28, 44). Second, the terminology and classification systems that are used at present are extremely confusing. Several synonyms and eponyms are used in literature. A definition for the terminology used in an

individual article is often lacking. Moreover, the actual classification system is based on phenotypic, genetic, and pathological criteria at the same time and shows several overlaps (for an example of the actual classification of patients with DSD and encountered synonyms in literature, see Table 2). This situation evidently leads to inconsistent classification of patients, which hampers a good insight in the prevalence of malignancy in specific diagnostic groups.

In the following paragraphs, an estimation of the prevalence of germ cell tumors in intersex patients is made, based on combined patient series from a review of the literature. For this purpose, intersex patients were divided into three major groups, based on a common underlying pathophysiological mechanism per group.

TABLE 2. Example of a currently used classification of patients with DSD and encountered synonyms in literature [adapted from Grumbach MM *et al.* (2)]

Syndrome	Major group	Subgroups	Encountered synonyms
Female PHP			Hypervirilized females
	CAH CYP19 aromatase deficiency Exogenous androgens		
Male PHP			Hypovirilized males
	End organ resistance for testosterone action	CAIS	Morris' syndrome, testicular feminization Reifenstein's syndrome
	Disorders in testosterone and dihydrotestosterone biosynthesis	PAIS StAR deficiency 3β-HSDII deficiency CYP17 deficiency 17β-HSD3 deficiency 5α-reductase II deficiency	
	Testicular unresponsiveness to LH and hCG Dysgenetic male PHP ^a **		Leydig cell hypoplasia/agenesis Incomplete GD ^b , partial GD ^b , mixed GD ^c **
		XO/XY mosaicism* Structurally abnormal Y, Xp+, 9p–,10q– Gene mutations (<i>WT1</i> , <i>SOX9</i> , <i>SF1</i> , <i>etc.</i>)	<i>WT1</i> , Denys-Drash, Frasier, WAGR (if <i>WT1</i> deleted), <i>SOX9</i> : campomelic dysplasia Persistent Müllerian duct syndrome
	Defects in synthesis, secretion, or action of AMH Exogenous estrogens/progestagens		
GD			
	47,XXY 45,X 45,X/46,XY and variants (+/– Turner stigmata)* Pure (complete) GD ^d True hermaphroditism ^e Incomplete forms of GD ^b **	complete 46,XY GD complete 46,XX GD	Klinefelter's syndrome Turner's syndrome Turner's syndrome (if Turner stigmata) Swyer's syndrome

CAH, Congenital adrenal hyperplasia; PHP, pseudohermaphroditism; AMH, anti-Müllerian hormone; StAR, steroidogenic acute regulatory protein; WT-1, Wilms' tumor 1 gene; WAGR, Wilms' tumor aniridia genitourinary anomalies and mental retardation; SOX9, SRY-box-related gene 9; SF-1, steroidogenic factor 1; hCG, human chorionic gonadotropin. *Asterisks* represent categories showing partial overlap.

^a (Mostly ambiguous) phenotype resulting from the presence of bilateral dysgenetic testes.

^b (Mostly ambiguous) phenotype resulting from the presence of bilateral dysgenetic testes or one dysgenetic testis on one side and a streak on the other side.

^c (Mostly ambiguous) phenotype resulting from the presence of one dysgenetic testis on one side and a streak on the other side.

^d Normal female phenotype (without Turner stigmata) in the presence of bilateral streak gonads (devoid of germ cells) in a 46,XX or 46,XY individual.

^e (Mostly ambiguous) phenotype resulting from the presence of both testicular tissue consisting of seminiferous tubules and ovarian tissue, containing germ cells that are all enclosed in primordial and eventually growing follicles in the same individual, either in a single gonad or in opposite gonads.

A. Hypervirilization syndromes

These include 46,XX individuals who are exposed to androgens (endogenous due to genetic defects in enzymes involved in adrenal steroid hormone production or of exogenous origin) during fetal life or thereafter (2). The diagnosis is based on clinical and biochemical grounds and is usually made at birth.

Patients with hypervirilization syndromes are not at risk for the development of germ cell tumors. The gonadal tissue always consists of well-differentiated ovaries, and the chromosomal constitution is 46,XX.

B. Undervirilization syndromes

These are caused by errors in testosterone biosynthesis, by testicular unresponsiveness to stimulation from the pituitary, or by defects in androgen-dependent target tissues and result in an ambiguous or female phenotype in a patient with a 46,XY karyotype (2).

For patients with male pseudohermaphroditism (the underlying defect not being further specified in the original articles), combined series reveal a tumor prevalence of 2.3% (3 of 129 patients) (19, 44–46).

The first reported prevalence of germ cell tumors in the androgen insensitivity syndrome (AIS) was 22% (25). Later, this was corrected to 5–10% (42, 43). In combined more recent series of samples mostly obtained after prophylactic gonadectomy, the calculated prevalence is 5.5% (15 of 270 patients) (19, 24, 26–28, 44, 45, 47–50). Although data are limited, the risk seems to be markedly higher in the partial form (PAIS) [12 of 80 patients (15%)] (28, 48, 50) than in the complete variant (CAIS) [1 of 120 patients (0.8%)] (19, 24, 28, 48–50). In our view, this difference is explained by the fact that there is a rapid and total loss of germ cells in CAIS, starting from the age of 1 yr, whereas PAIS patients have maintained their germ cell population at about two thirds of the normal number at puberty (28). However, in this context it is important to note that at present, none of the existing *in vivo* or *in vitro* tests distinguish unambiguously between CAIS and PAIS (51–54).

Tumor prevalence in AIS markedly increases after puberty and reaches 33% at the age of 50 yr (19). However, no data exist on the estimated prevalence in CAIS *vs.* PAIS patients at this age.

For other causes of undervirilization, series are too small to draw conclusions: one tumor is reported in a series of six patients with 17 β -hydroxysteroid dehydrogenase (17 β -HSD) deficiency (17%) (28), no tumors are found in a series of three patients with 5 α -reductase deficiency (49) and of two patients with Leydig cell hypoplasia (28).

With the exception of one case report of a GB, sufficiently supported by published histological findings in a CAIS patient (55), all the reported tumors in the group of patients with undervirilization syndromes are CIS lesions (81%) or seminomas (19%).

The prevalence of preinvasive tumor lesions found in prophylactic biopsy samples (usually performed at a very young age) in PAIS patients (15%) is unexpectedly high compared with the total group of undervirilized patients (2.3%).

Due to the widespread policy of prophylactic gonadectomy, invasive tumors in these patients are rare at present,

but the hypothesis that all CIS lesions will finally result in an invasive tumor (56) explains the higher prevalence in older series. However, in our view, the real prevalence of CIS lesions in gonadectomy samples of young children might be lower than the calculated 5.5%, because the benign condition of maturation delay can easily be misinterpreted as CIS and may cause a significant bias in some of the reported series (48, 49, 57) (see *Section V.B*). The recent tendency to leave the gonads in place, fixed in the scrotum in phenotypic males, and to include them in strict follow-up protocols will allow a better insight in the risk for malignant transformation of the testis in undervirilized patients in the future.

C. Gonadal dysgenesis

Gonadal dysgenesis (GD) is defined as an incomplete or defective formation of the gonads, as a result of a disturbed process of migration of the germ cells and/or their correct organization in the fetal gonadal ridge. Structural or numerical anomalies of the sex chromosomes or mutations in genes involved in the formation of the urogenital ridge and in sex determination of the bipotential gonad mostly underlie these disorders (2, 58–61).

A clear insight in the prevalence of germ cell tumors in patients with GD is hampered by the existing confusion regarding nomenclature, which is most pronounced for this patient category (see Table 2).

Four series report on the prevalence of germ cell tumors in GD (not further specified): A germ cell neoplasia is found in 48 of 228 patients (21%) (18, 19, 44, 62). Most frequent are isolated GBs [26 of 48 (54%)] and DGs [11 of 48 (23%)]. Five (10%) consist of a combined GB and DG, two GB (4%) are associated with a nonseminoma, one is a combined GB and CIS lesion (2%), and three (6%) isolated CIS are reported.

In two series of patients with 46,XY GD, the tumor prevalence is 30–33% (17, 63). However, one series of 11 patients with 46,XY dysgenetic male pseudohermaphroditism reports CIS in 100% of cases (64). In our view, most of the germ cell lesions described in this series reflect a state of maturation delay of the germ cells (see *Section V.B*). Therefore, this study will not be included in further calculations.

In series of patients with mixed GD, or asymmetrical gonadal differentiation, the overall prevalence of germ cell tumors is 18 of 119 patients (15%) (19, 20, 24, 45, 46, 65), which is considerably lower than the previously reported prevalence of 33% (19). The practice of performing an early prophylactic gonadectomy probably explains at least in part this difference. A total of 38.5% of the tumors are GB, 23% are composed of GB and DG, 38.5% are isolated DG, and no CIS lesions are found in these patient series. The findings correspond to older studies (19). However, in contrast with these data, one study describes 13 patients with mixed GD in which the prevalence of malignant lesions is 77% (10 of 13), all of them being CIS lesions, and 11 patients with partial GD, in which the tumor prevalence is 91% (10 of 11), all CIS, in seven cases associated with GB (66). According to us, again, the CIS lesions described here correspond to a state of maturation delay of the germ cells (see *Section V.B*), and the data will not be used for further calculations.

In selected series of patients with true hermaphroditism,

the prevalence of tumors is considerably lower. In three studies, 426 patients are described (29, 44, 46). In these patients, 11 tumors occurred (2.6%), and the subtypes are two of 11 (18%) GB, one of 11 (9%) CIS, six of 11 (55%) DG, and two of 11 (18%) embryonal carcinoma (EC).

According to the older literature, germ cell tumors occur in 15–20% of patients with proven mosaicism 45,X/46,XY and variants. Recent data may suggest a higher prevalence: independent series describe 17 patients in whom seven germ cell tumors occur (41%) (63, 67, 68): four of seven tumors (57%) are GB, one of seven (14%) is a GB associated with a DG, and two of seven (28%) are DG. However, a bias due to selective reporting of positive gonadectomy samples cannot be excluded. In one series of four patients, CIS is found in all cases (100%) (69), but again, the criteria used for the diagnosis of what the authors call “an infantile CIS pattern” overlap with the characteristics of germ cells delayed in their maturation (see *Section V.B*). This study will not be used for further calculations.

Molecular genetic techniques (mainly PCR) allow a more reliable detection of a second (Y containing) cell line than classic karyotyping. Therefore, some studies examine the usefulness of routine PCR screening of all patients with Turner syndrome for the presence of Y chromosome material. We performed a meta-analysis of 11 studies dealing with this topic (70–80). It reveals that in 541 Turner syndrome patients without Y chromosome material on cytogenetic screening, 27 patients turned out to be mosaic for a Y-containing cell line (5%). If a marker chromosome (mar+) was present in the original karyotype, the chance of detecting Y chromosomal derivatives approximates 100%. A total of 557 patients were examined in these studies (in 16 patients Y chromosome derivatives were already detected on cytogenetic screening). Thus, the total number of patients bearing a Y chromosomal cell line was 43 of 557. In all of them, a gonadectomy was performed, and GB was present in five of them (11.6%). From these data it can be concluded that routine PCR examination of Turner syndrome patients to detect high-risk individuals for the development of GB is not indicated (the prevalence of GB in the total group being five of 557 or 0.9%). In contrast, if a marker chromosome is found on cytogenetic karyotyping, the presence of Y chromosome material (and an elevated risk for the development of GB) must be suspected, and further examination by molecular genetic techniques is warranted.

In a review of 15 cases of Frasier syndrome, the prevalence of germ cell tumors is as high as 60% (88% GB, 12% DG) (81). From these data, it is unclear whether this series reflects a reliable estimation of the tumor risk in Frasier syndrome or if an overrepresentation of positive cases has induced a selection bias. In other syndromes caused by *WT-1* mutations (Denys-Drash, Wilms' tumor aniridia genitourinary anomalies and mental retardation), the prevalence of germ cell tumors may be equally high. Gonadal pathology is studied in one series of 10 patients with Denys-Drash syndrome: GB was found in two of five 46,XY patients (40%), whereas none of the four 46,XX patients developed gonadal tumors (in one additional patient without GB, the karyotype was not determined) (82). No data are available concerning the prevalence of germ cell tumors in cases of GD due to mutations

in other newly discovered genes that are important for gonadal development (*e.g.*, *SF-1*, *SOX9*, *DAX1*).

D. Conclusions

Combining of these data allows some important conclusions:

1. The overall prevalence of germ cell tumors in the various patient series with GD is estimated at 97 of 817 (12%).

2. In undervirilization syndromes, the overall prevalence of germ cell tumors approximates 2.3%. However, because this estimation is mainly based on prophylactically removed gonadectomy samples, the prevalence in untreated patient series is probably higher.

3. Within the group of undervirilization syndromes, germ cell tumors are extremely rare in CAIS and more frequent than expected in PAIS.

4. In contrast to patients with undervirilization syndromes, germ cell tumors in patients with GD are frequently found at a very young age [*e.g.*, in the first year of life (20, 21, 62, 83)] or may even be present at birth (65).

5. CIS, arising in well-differentiated testicular tissue is virtually the only precursor lesion found in patients with undervirilization syndromes. In contrast, nearly all the *in situ* neoplastic lesions in patients with GD are GBs, whether or not (partially) overgrown by seminoma/DG [56 of 61 (92%)]. The CIS lesion accounts for only 8% (5 of 61) of precursor lesions in patients with GD and is probably only encountered in the presence of testicular tissue (our personal observations).

6. The presence of the Y chromosome (and of the TSPY gene) was not an inclusion criteria in the large majority of the studies. Studies on patient series in which the presence of the TSPY gene or protein in the gonadectomy samples or at least in the patients' karyotype is confirmed are highly needed to get a better insight in the real malignant potential of the dysgenetic gonad in selected series of high-risk patients.

7. The use of an unambiguous classification system of clinical diagnoses and a clear definition of the used terminology is indispensable for a correct interpretation of data and for a better estimation of tumor risk in specific patient series (*e.g.*, 17β -HSD deficiency, Leydig cell hypoplasia).

8. The routine search for mutations in genes involved in gonadal differentiation (*e.g.*, *WT1*, *SF1*, *DAX1*, *SOX9*) in 46,XY individuals with GD is essential to determine the tumor risk in specific patient series.

A summary of the estimated tumor prevalences and the type of precursor lesion is given in Table 3.

IV. The Use of Immunohistochemical Markers for the Diagnosis of Germ Cell Tumors in Patients with Disorders of Sex Development

The development of germ cell tumors in general is related to events during fetal gonadogenesis, the malignant germ cell being the neoplastic counterpart of a primordial germ cell (PGC) or gonocyte (23). Therefore, immunohistochemical markers that are expressed by normal PGCs can be used for the diagnosis of malignant germ cell tumors. However, it is important to note that none of these markers is able to dis-

TABLE 3. Summary of the estimated germ cell tumor prevalence in patients with DSD and type of precursor lesion

	Estimated tumor prevalence	Type of precursor lesion	
		CIS	GB
Undervirilization	2.3% (probably higher if untreated)	~100%	~0%
AIS	5.5% (20–30% if untreated)		
CAIS	0.8%		
PAIS	15%		
GD	12% (probably >30% if untreated and/or selected for the presence of the Y chromosome)	8%	92%
45,X/46,XY and variants	15–40%		
46,XY GD	30%		
Mixed GD/asymmetrical gonadal differentiation	15% (>30% if untreated and/or selected for the presence of the Y chromosome)		
True hermaphroditism	2.6%		
Frasier syndrome	60% (limited data)		
Denys-Drash syndrome with 46,XY karyotype	40% (limited data)		

tinguish unambiguously between maturation delay of germ cells (a benign condition, see *Section V.A*) and an *in situ* neoplasm. Because such a discriminative marker is not to be expected in the near future, additional criteria are indispensable to diagnose CIS in young children.

A set of relevant immunohistochemical markers (OCT3/4, PLAP, c-KIT, TSPY, VASA) was specifically examined in large series of gonads from intersex patients by our group (for results and references, see Table 4). The markers OCT3/4, c-KIT, and PLAP show overlapping expression patterns, but the use of the newer (both monoclonal and polyclonal forms of) OCT3/4 results in a well-circumscribed and intense nuclear staining, is easiest for interpretation, and is very robust, even if different methods of pretreatment and tissue storage are applied (84). Therefore, it is largely preferred to the other two markers.

The *in situ* neoplastic lesions of the intersex gonad—GB and CIS—are unambiguously characterized by a consistent expression of OCT3/4 and an abundant expression of TSPY (28, 62, 85). A careful analysis of the staining results summarized in Table 4 reveals that they can only arise from abnormal (developmentally delayed and/or dysgenetic) testicular tissue or from undifferentiated gonadal tissue (UGT) (see *Section VI*), but not from normal testes or ovaries. The possible roles of OCT3/4 and TSPY in the development of germ cell tumors are discussed in *Section IV.A* and *IV.B*.

A. OCT3/4 (*POU5F1*)

OCT3/4 is consistently and specifically expressed in all germ cell tumors with pluripotent potential and is therefore used as a reliable marker for the diagnosis of CIS, GB, seminoma/DG, and EC (84, 86). The diagnostic value of OCT3/4 has been confirmed in a series of independent studies (31, 87–92). The expression of the recently proposed immuno-

histochemical marker activator protein 2-γ (93) is similar to OCT3/4 expression but offers no additional information.

The octamer binding transcription factor OCT3/4 is a member of the family of POU (pit-1, oct-1, *Caenorhabditis elegans* unc-86) transcription factors, genes that regulate the expression of other target genes during mammalian development (94). It is highly expressed during the earliest stages of embryogenesis and in embryonic stem cells (ESC) (87, 95), and is essential for the maintenance of pluripotency of these cells. Up- or down-regulation of OCT3/4 in ESC as well as in EC cell lines induces differentiation (95, 96). In the early embryo, OCT3/4 is quickly repressed and soon becomes exclusively confined to the germ cell lineage. However, loss of OCT3/4 expression in PGCs does not lead to differentiation of these cells but to apoptosis (97). Thus OCT3/4 is required for the survival of PGCs. In female gonadal development, OCT3/4 is expressed in oogonia and early oocytes, but never in germ cells included in follicles (31, 98), and, in accordance with this observation, it was suggested that down-regulation of OCT3/4 is related to the entry of female germ cells into meiosis (94). As a result, in the female gonad, expression of OCT3/4 is high until 25 wk gestational age, but decreases sharply thereafter. At birth, hardly any positive germ cell is detectable (98). In human male embryonic development, OCT3/4 expression is confined to gonocytes, which are positioned in the center of the tubule. During gonadal development, gonocytes migrate toward the periphery, and once they make contact with the basal lamina (they are now referred to as prospermatogonia), they lose OCT3/4 expression (in contrast to normal adult OCT3/4 expression in murine spermatogonia; see Ref. 94). This results in a high expression pattern of OCT3/4 early in the second trimester and a constant decrease thereafter. In the perinatal period, few tubules display a single, centrally located positive germ

TABLE 4. Immunohistochemical markers in germ cells and germ cell tumors

	Testis			UGT	Ovary	CIS	GB	Seminoma	Nonseminoma	Refs
	Normal	Delay	Dysgenetic							
OCT3/4	–	+	+	+	–	+	+	+	EC	28, 62, 84–86, 92, 98–100, 120
PLAP	–	+	+	+	–	+	+	+	EC	28, 62, 98–100, 121
c-KIT	–	+	+	+	+	+	+	+/–	–	28, 62, 98–100, 122, 123
TSPY	+	2+	2++	2++	–	2++	2++	+/–	–	28, 35, 62, 85, 99–101
VASA	+	+	+	+	+	+/–	+/–	+/–	–	28, 62, 98–100, 124

cell (99, 100). Subsequently, it was shown that the expression of OCT3/4 is abnormally prolonged in situations where germ cells are delayed in their development (see *Section V.A*) (28, 31, 62, 100).

In ESC-derived tumors in mice, the level of expression of OCT3/4 was highly correlated with the formation and aggressive properties of the tumors (absent or low levels of OCT3/4 expression hampered tumor formation or resulted in poorly aggressive, well-differentiated tumors, whereas high levels of OCT3/4 led to frequent and highly aggressive tumors, down-regulation of OCT3/4 in these tumors resulted in their regression). Extrapolation of these data to the noticed OCT3/4 expression in germ cell tumors led to the suggestion that aberrant OCT3/4 expression might be of pathogenetic relevance in the development of these tumors and might determine their oncogenic potential (87).

B. The testis-specific protein-Y encoded (TSPY)

It was observed for many years that a GB almost exclusively arises in the dysgenetic gonads of intersex patients with a Y chromosome. Rare case reports of GB arising in Y-negative patients date from an era before the use of molecular genetic techniques to exclude the presence of Y chromosome material (16–19, 21). This led Page (39) in 1987 to postulate the hypothesis that a gene on the Y chromosome with a physiological function related to spermatogenesis in normal males may act as an oncogene in the context of a dysgenetic gonad. He referred to this hypothetical gene as *GBY* (gonadoblastoma locus on the Y chromosome) (39). By comparing the karyotypes of patients with GB and partially deleted Y chromosome material, the *GBY* susceptibility region was further sublocalized to a small region on the short arm (deletion interval 3E-3G and 4B) (38) or long arm (deletion interval 5E) of the Y chromosome (37), both close to the Y centromere (Fig. 1). The main candidate for *GBY* among the seven known genes of the interval on Yp is *TSPY*, which also has functional copies in the defined interval on Yq. In accordance with the original hypothesis of Page, the *TSPY* protein is normally expressed in spermatogonia of the adult male, and although its function is not fully understood, it is thought to be related to their mitotic proliferation (36, 101). Variations in the level of *TSPY* expression, resulting in fluctuations in the staining intensity in immunohistochemical experiments have been reported by different observers (28, 36, 62, 100, 101). In the fetal gonad, *TSPY* is expressed at a constant level throughout pregnancy (99). However, *TSPY* staining is more intense in fetal germ cells of trisomy 21 patients, which are delayed in their maturation (100), and becomes abundant in germ cells of intersex patients (undervirilization syndromes as well as GD) (28, 62). Furthermore, the intensity of the *TSPY* staining is also abundant in CIS (whether or not arising in intersex patients) (28, 101), GB (35, 62, 85), seminoma (35), and possibly in prostate cancer (102) and hepatocellular carcinoma (103). Whether or not the observed increase in staining intensity results from an up-regulation of transcribed and translated *TSPY* copies has not been examined so far.

From this section and *Section IV.A*, it can be hypothesized that prolonged expression of OCT3/4 and increased expres-

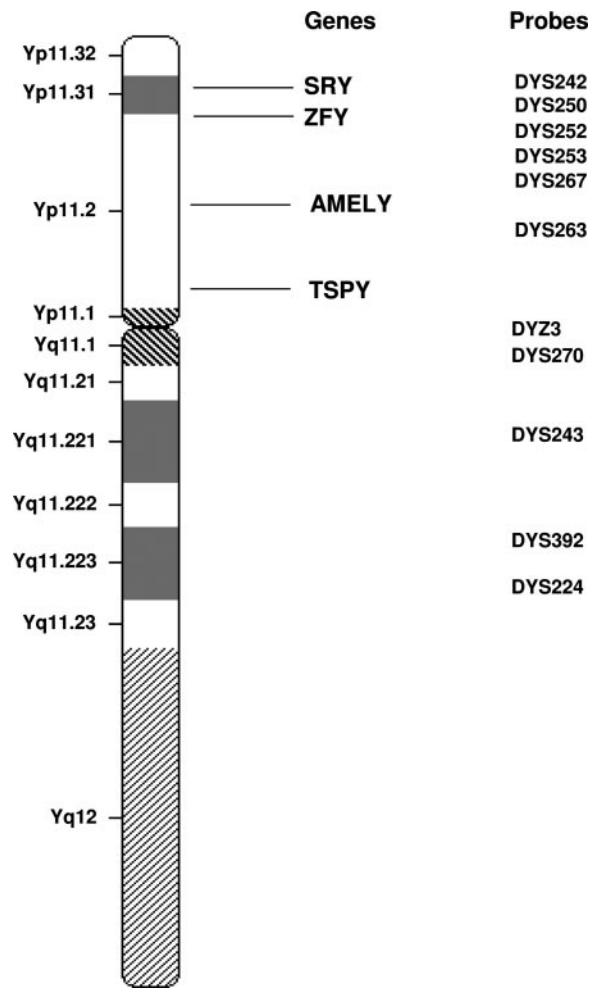


FIG. 1. Location of the *TSPY* gene on Yp. *TSPY* is located in the pericentromeric region on Yp; homologous copies may be present on Yq.

sion of *TSPY* can provide the germ cells residing in an unfavorable environment with additional tools to survive and proliferate.

V. Maturation Delay vs. CIS: Transitional Changes of the Germ Cells

A. Maturation delay of germ cells

According to the testicular dysgenesis syndrome hypothesis that Skakkebaek and co-workers (104, 105) proposed, germ cells that are not optimally nourished by Sertoli cells at the time of fetal gonadogenesis undergo a delay in their maturation, resulting in an increased risk for subfertility and germ cell tumor formation. This model suggests that developmental delay of germ cells is the common underlying mechanism in various apparently unrelated conditions, such as exposure to xenoestrogens and antiandrogens (the so-called “endocrine disruptors”) of the male fetus, certain conditions caused by chromosomal aberrations (*e.g.*, trisomy 21), and DSD.

To test this hypothesis, we quantitatively and qualitatively examined the expression of germ cell markers in male and

TABLE 5. Additional criteria for the diagnosis of maturation delay and CIS in XY individuals with undervirilization syndromes

	Maturation delay	Transition	CIS
Patient age	<1 yr	Prepubertal	>1 yr
Position of OCT3/4-positive cells within the seminiferous tubule	Luminally	Luminally and on the basal lamina	On the basal lamina
Position of OCT3/4-positive cells throughout the gonad	Widespread	Confined to a specific region; rest of the gonad is free of positive cells or displays characteristics of maturation delay	Confined to a specific region; rest of the gonad is free of positive cells or displays characteristics of maturation delay

female fetuses throughout pregnancy (98, 99) and compared the expression patterns to those obtained in trisomy 21 fetuses, undervirilization syndromes, and GD (28, 62, 100). We found that in all these conditions, a subpopulation of germ cells is indeed affected by maturation delay. In the testes of males with trisomy 21 and of patients with undervirilization syndromes and GD, the normal migration of these early germ cells toward the basal lamina and their subsequent differentiation into prespermatogonia is disrupted. This becomes apparent by their morphological similarity with the primitive gonocyte, by their increased and prolonged expression of the tumor markers OCT3/4, c-KIT, and PLAP, and by increased intensity of immunohistochemical staining for TSPY. The developmental delay present in the gonads of male trisomy 21 patients, who have a moderately elevated risk (estimated at 0.5%) for the development of germ cell tumors is rather mild, whereas a more pronounced maturation delay was demonstrated in the germ cells of patients with undervirilization syndromes and especially in the testicular parts of gonads from patients with GD (28, 62, 100). In UGT, characteristic for patients with GD and at high risk for the development of GB, germ cells, extremely retarded (or blocked) in their maturation reside in a background of supporting and stromal cells that failed themselves to differentiate properly and to organize in structures characteristic for normal male or female gonadal development (*i.e.*, the formation of testes or ovaries) (62).

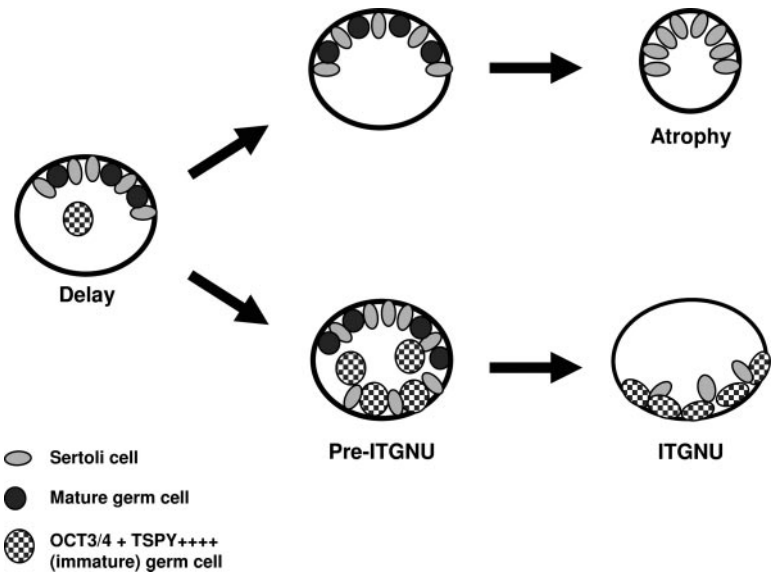
Thus, our data confirm the model that a delay or block in germ cell development is a common underlying mechanism

in various conditions such as trisomy 21 and DSD. To what extent these data can be extrapolated to gonadal development in male fetuses exposed to endocrine disruptors remains to be examined at present.

B. Pitfalls in the diagnosis of early germ cell neoplasia

The prolonged expression of fetal germ cell markers/tumor markers in the gonads of young patients with DSD has led to a significant overdiagnosis of CIS in this patient population, because the mere presence of a tumor marker in a germ cell with aberrant morphology (the morphology of a CIS cell also closely resembles that of a primitive gonocyte) was considered as a hallmark for its malignant transformation and was thought to represent a “prepubertal CIS lesion” (48, 49, 64, 66, 106). Therefore, we have proposed three additional criteria—patient age, position of OCT3/4-positive cells within the seminiferous tubule, and distribution of OCT3/4-positive cells throughout the gonad—that allow distinguishing between maturation delay and CIS in the gonads of patients with undervirilization syndromes (28) (Table 5). These criteria have recently been validated in an independently performed study (107). The last two criteria are also applicable on the dysgenetic testes of patients with GD; however, the age criterion cannot be used in this population because the process of maturation delay is more pronounced in this condition and was found up to the age of 10 yr (our personal observations).

FIG. 2. Development of CIS in the testis of patients with DSD. Germ cells that are delayed in their maturation are characterized by prolonged OCT3/4 and increased TSPY expression. Due to the unfavorable environment, most of these germ cells will die, leading to tubular atrophy. However, surviving germ cells are prone to clonal expansion and the formation of an *in situ* neoplasia.



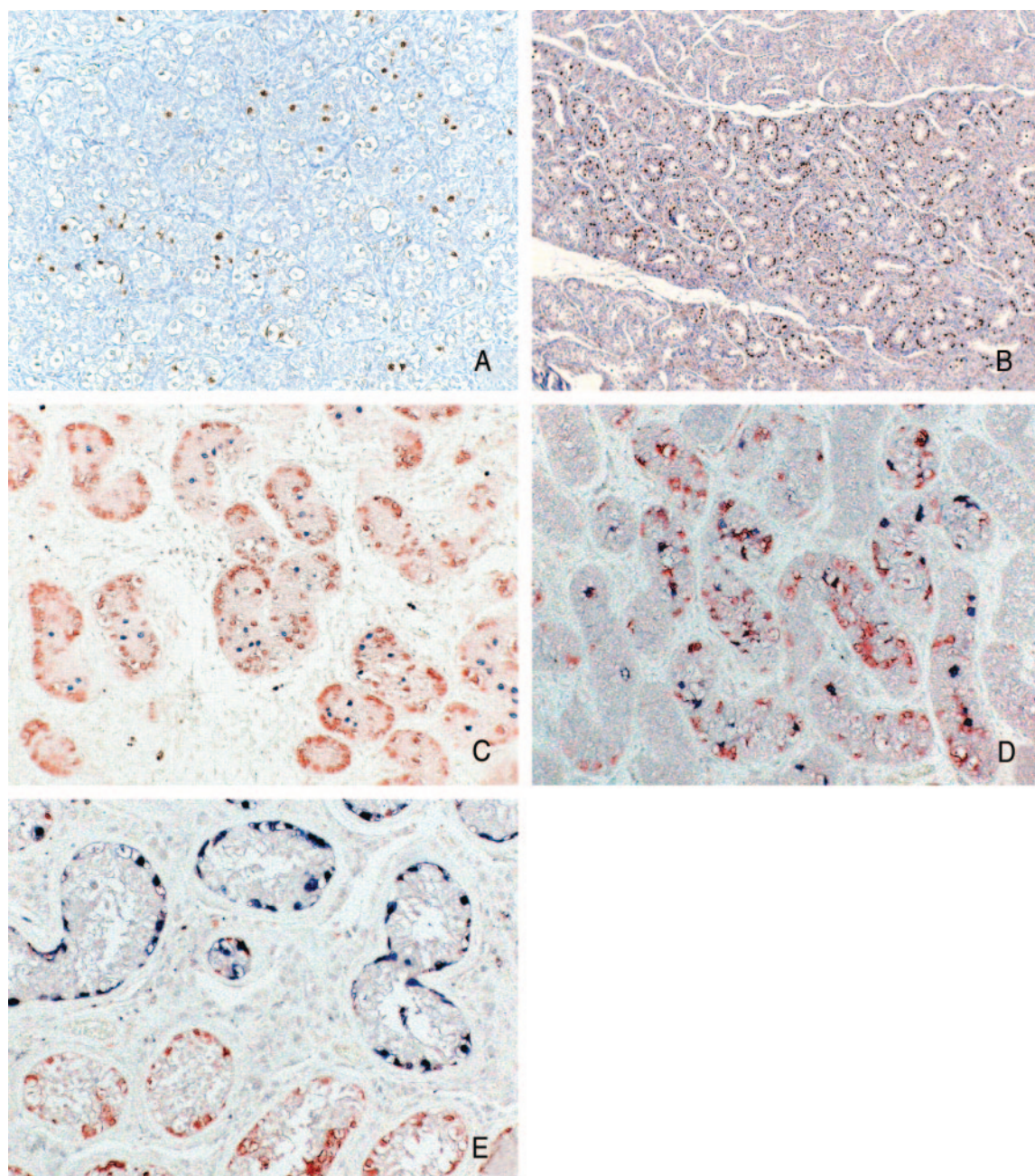


FIG. 3. Maturation delay *vs.* CIS in the testes of patients with undervirilization syndromes. A, Maturation delay: OCT3/4-positive tubules are scattered throughout the gonad in a 6-month-old patient with 17β -HSD deficiency. Note the central position of the OCT3/4-positive cells within the tubules (OCT3/4 staining; magnification, $\times 100$). B, CIS: OCT3/4-positive tubules in a 13-yr-old PAIS patient. The OCT3/4-positive tubules are confined to one limited area of the gonad, separated from the OCT3/4-negative areas by fibrous septa (OCT3/4 staining; $\times 100$). C, Maturation delay: OCT3/4 (blue)-VASA (red) double staining ($\times 200$) in a 1-month-old CAIS patient. OCT3/4-positive cells are located in the center of the tubule and are separated from the basal lamina by at least one layer of Sertoli cells; VASA-positive cells, staining as maturing germ cells, are mainly found on the basal lamina. D, Preneoplastic lesion: OCT3/4 (blue)-VASA (red) double staining ($\times 200$) in a 4-yr-old 17β -HSD deficiency patient. OCT3/4-positive cells are found centrally in the tubule and along the basal lamina. Normally maturing germ cells (characterized by the red VASA staining) are equally present in the affected tubules. E, CIS: OCT3/4 (blue)-VASA (red) double staining ($\times 200$) in a 13-yr-old PAIS patient. OCT3/4-positive cells are found almost exclusively along the basal lamina. Affected tubules do not contain normally maturing germ cells anymore (characterized by the red VASA staining).

C. Progression toward malignancy

From the previous sections, it can be concluded that maturation delay of germ cells may indeed result in an increased risk for neoplastic transformation, which is related to the prolonged expression of OCT3/4 and increased TSPY ex-

pression, which provides the cell with equipment to survive and proliferate. However, in most cases this is only a transient condition; despite their initial developmental delay, immature germ cells lose OCT3/4 expression and differentiate into a more mature cell type, or alternatively they die,

due to the inappropriateness of their environment. However, in the testes of patients with undervirilization syndromes and GD, it was occasionally observed that OCT3/4-positive PGCs/gonocytes manage to make contact with the basal lamina and seem to definitively escape down-regulation of OCT3/4 and further differentiation along the spermatogenic pathway. These OCT3/4-positive and TSPY-positive germ cells in contact with the basal lamina can now undergo mitotic proliferation and are prone to clonal expansion. On immunohistochemical staining, this preneoplastic lesion is characterized by the combined presence of OCT3/4-positive and OCT3/4-negative germ cells on the basal lamina of the seminiferous tubule. Luminally positioned OCT3/4-positive cells may also be present (Table 5 and Figs. 2 and 3). This pattern was hitherto seen only in prepubertal patients (28, 62). Thus, histologically, a continuum can be identified, from maturation delay toward preneoplastic changes of the germ cells and final organization into a typical CIS pattern.

Maturation arrest of tissue-determined stem cells has been proposed previously as a common underlying mechanism in all epithelial-derived tumors as well as in tumors of hematopoietic origin (108). In this context, the recent observation that global loss of genomic imprinting in mouse ESCs predisposes these cells to malignancy by rendering them immortal is of interest (109). Indeed, type II germ cell tumors of the testis have been found to consistently show biallelic expression of imprinted genes, *i.e.*, they lack a somatic pattern of genomic imprinting (110). Despite the fact that it possibly concerns an intrinsic characteristic of the cell of origin (a PGC/gonocyte), this loss of genomic imprinting might in fact represent a step in the pathogenetic process of malignant transformation. Extrapolation of these data to patients with DSD creates a model in which PGCs, insufficiently nourished by an inappropriate environment, undergo a severe delay or arrest in their development, which is most pronounced in those tissues with the lowest degree of differentiation, thereby maintaining (or inducing) a status of erased genomic imprinting and prolonged OCT3/4 expression of the germ cells (immortalization). Increased TSPY expression may rapidly lead to expansive proliferation of this immortal cell type (Fig. 4).

FIG. 4. Overview of the pathogenetic mechanisms leading to clonal expansion of germ cells in patients with DSD. The original biparental pattern of genomic imprinting present in the zygote has to be erased during PGC development to install a uniparental pattern of maternal genomic imprinting in the oocyte and paternal genomic imprinting in the spermatozoa. Loss of genomic imprinting (or biallelic expression of imprinted genes, as is seen in the PGC/gonocyte) may lead to immortalization. In DSD, due to the unsupportive environment, the normal maturation of germ cells is interrupted. Maturation delay/arrest of the germ cells, characterized by prolonged OCT3/4 expression (increased survival of the PGC) and a maintained or induced status of erased genomic imprinting, may lead to immortalization of the cell. Increased TSPY expression may cause proliferation of this immortalized cell type.

VI. CIS or Gonadoblastoma?

Why do some patients with DSD develop a CIS and others a GB as an *in situ* neoplastic lesion? From Table 3 it becomes apparent that CIS is the almost exclusive precursor lesion in undervirilized patients, whereas GB is predominant in patients with GD. In the various undervirilization syndromes and the (more frequently occurring) CIS lesion of the normal adult male, it is clear that the gonadal tissue in which these lesions originate always consists of well-differentiated testicular tissue. The detailed nature of the gonad in which a GB can arise has been unclear so far. It was examined in some patient series (16, 20, 64, 65, 67, 83). The combination of these data reveals that the gonad of origin is considered as a dysgenetic testis in 20% of cases and a streak in 26%, and that it could not be determined in 54% of cases. Recently, we hypothesized that GBs probably arise from surviving germ cells residing in UGT and primitive SC (62), structures that are only encountered in the context of GD and that remained unrecognized so far.

The normal development of human fetal gonads is described by Gondos (111) and is largely analogous to the gonadal development and differentiation process analyzed in detail in mice (112–114). At their arrival in the genital ridge around the 5 wk gestational age, the germ cells and pre-Sertoli/granulosa cells reside in the bipotential gonad without specific organization. The first sign of sexual differentiation, the formation of primitive SC, coincides with the expression of *SRY*, around wk 6. Subsequent development of the SC into seminiferous tubules depends on adequate gene expression downstream of *SRY*. In the absence of *SRY* expression, no changes occur in the undifferentiated gonad until the 12th wk, when the germ cells enter meiosis. It was hypothesized that the UGT found in patients with GD represents this undifferentiated state of the gonad, where no accurate *SRY* expression has taken place, but where, under the influence of unknown male characteristics, meiosis and progression along the default pathway are inhibited (Fig. 4).

Surviving PGCs in UGT and SC of the dysgenetic gonad abundantly express TSPY, and a subpopulation of them also expresses OCT3/4 (Table 4). We hypothesized that down-

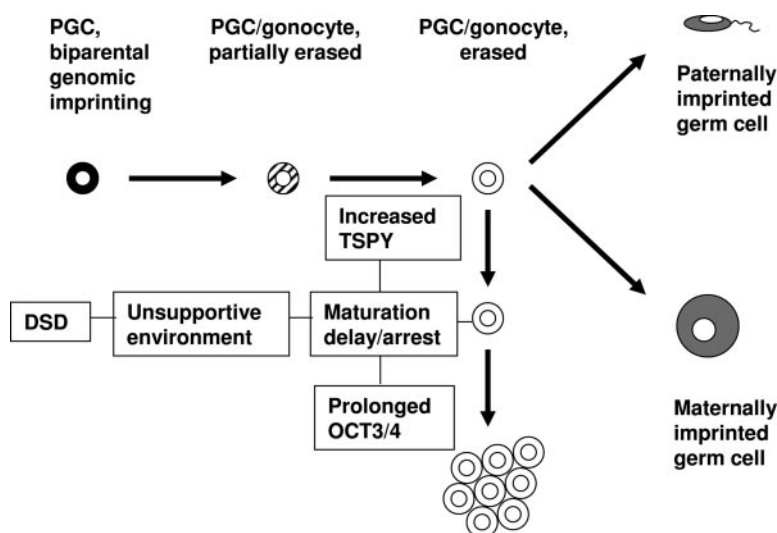
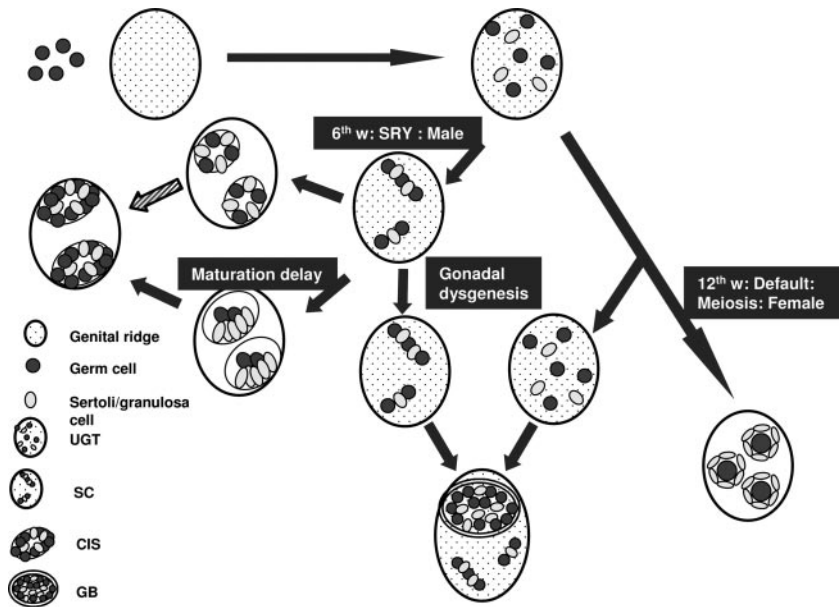


FIG. 5. Model for the development of UGT, GB, and CIS within the dysgenetic gonad. *Top*, In the developing embryo, germ cells migrate from the yolk sac into the bipotential gonad and intermingle with pre-Sertoli/granulosa cells. *Middle, from right to left*, In the male, *SRY* expression in the sixth week after conception induces organization of pre-Sertoli cells and germ cells in primitive SC. Under the influence of other male sex-determining genes downstream of *SRY*, these SC differentiate into seminiferous tubules. Pathological conditions can cause a block or delay in the normal germ cell development, thereby increasing the risk for CIS formation. *Bottom*, In GD, inaccurate or absent *SRY* expression or a disturbed expression of other male-determining genes prohibits SC formation or further differentiation of SC, whereas progression along the meiosis-default pathway is also blocked (*bottom right*). Surviving germ cells residing in UGT (including immature SC) contain a high risk for the development of GB (*bottom, middle*).



regulation of OCT3/4 in these PGCs results in apoptosis, finally leading to the formation of a streak. However, the risk of clonal expansion in these OCT3/4-positive, TSPY-positive germ cells residing in UGT and SC is high and frequently

leads to the development of a GB (Figs. 5 and 6). If this evolution takes place more rapidly than the progression toward CIS, this would explain the more frequent finding of a GB rather than a CIS lesion in dysgenetic gonads containing

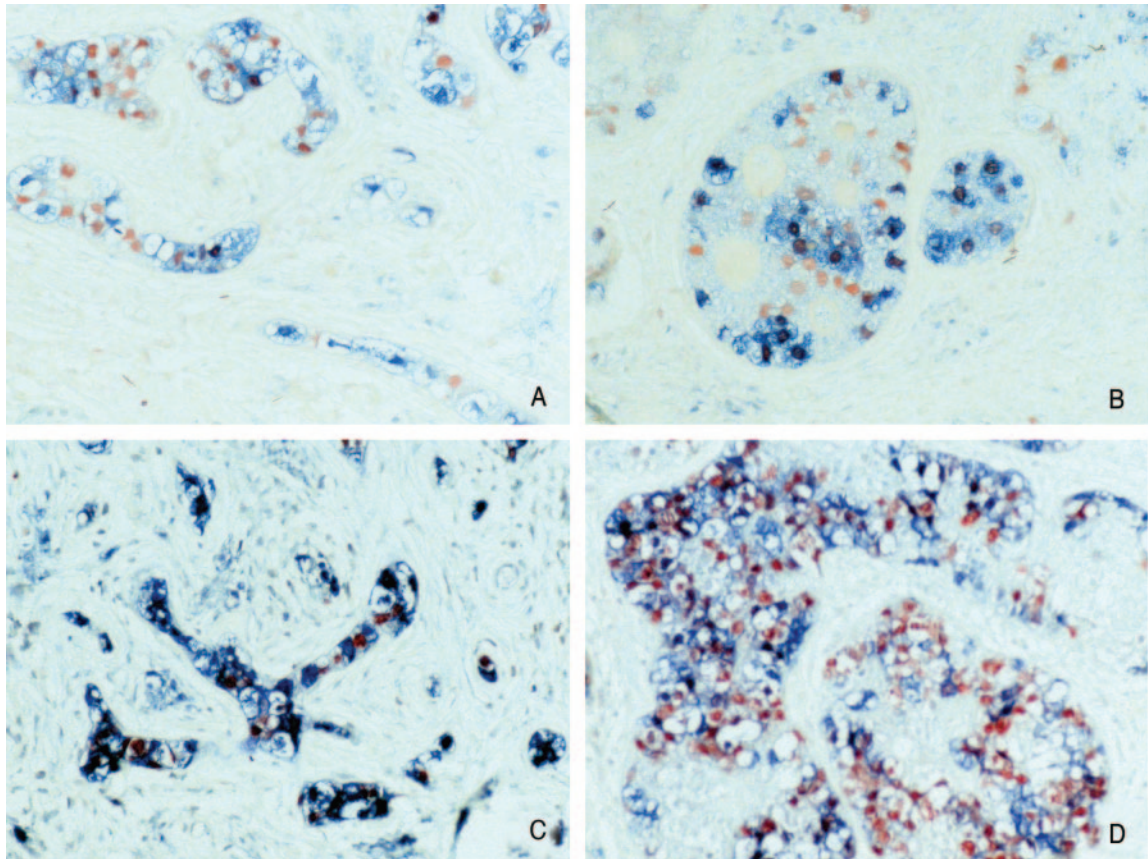


FIG. 6. OCT3/4 and TSPY staining results in UGT and adjacent GB lesions. OCT3/4 (red)-TSPY (blue) double staining (magnification, $\times 200$) in a 19-yr-old 46,XY patient with GD and bilateral GB. A subpopulation of germ cells (characterized by their positive TSPY staining) within the UGT (A, left gonad; C, right gonad) adjacent to GB expresses OCT3/4. Most germ cells within the GB lesion express OCT3/4 and TSPY (B, left gonad; D, right gonad).

both SC or UGT and testicular tissue. Alternatively, it is conceivable that immature germ cells, blocked in their maturation but residing in SC or UGT, which is their natural environment during early embryonic life, have increased survival and proliferation chances compared with immature germ cells residing in well-differentiated testicular tissue (62). These findings are partially in line with a recently published study (115) in which the authors state that GBs originate from germ cells developing along the female pathway but failing to complete the meiotic prophase and to organize in primordial follicles. However, in contrast to our data, primitive SC, blocked in their further progression toward seminiferous tubules, were not identified as containing a high risk for the development of GB by these authors.

VII. Proposal for a New Classification of Patients with Disorders of Sex Development according to Their Risk for the Development of Germ Cell Tumors (Fig. 7 and Table 6) and Future Perspectives

A review of the literature, as outlined in *Section III*, actually reveals that a correct insight in the risk for germ cell tumor development in patients with DSD cannot be achieved for the reasons stated in *Section III*. Therefore, we propose a new classification for patients with DSD, based on the differentiation type of the gonad, which is directly related to the risk for tumor development (Fig. 7), and using a more homogeneous terminology that avoids synonyms and overlapping categories (Table 6). This classification system is partly in line with the classification of patients with DSD as it was recently proposed by the consensus conference on the management of patients with DSD (Chicago, IL, October 2005), the results of which are presented in Ref. 116. However, there are some important modifications, and the classification system is extended based on additional information (Table 6). First, the table is built vertically instead of horizontally, as is the case in Ref. 116, thereby underscoring the various levels at which sex development can be affected (level of chromosomal sex *vs.* gonadal sex and phenotypic sex). Second, more attention is paid to the different gonadal differentiation patterns en-

countered in a specific category of DSD, including the recently described UGT pattern (not available at the time of the consensus meeting), which is likely to be at the base of GB formation. Third, the presence or absence of the TSPY gene in the patients' (gonadal) karyotype is specified. Taken together, the proposed classification system allows an immediate estimation of the patient's individual risk for germ cell tumor development once he or she is placed in a specific category.

A major disadvantage of this classification system is that obtaining representative gonadal tissue (at least a bilateral gonadal biopsy is needed) becomes essential for classifying the patient, which makes a surgically restrictive patient care impossible at once. Therefore, we would like to consider it as a temporary tool to reclassify detailed patient series from the literature and, additionally, newly diagnosed patients, in whom a bilateral gonadectomy is, as a rule, performed at present.

Important questions and remarks are:

- To what degree is a gonadal biopsy representative for the whole gonad in patients with undervirilization syndromes and GD? How many biopsies (at the same time and/or with a given time interval) are necessary to generalize data on the presence or absence of germ cells or their malignant transformation in a biopsy specimen? How do we exclude the (eventually microscopical) presence of testicular or UGT in patients with GD and predominant ovarian differentiation based on limited biopsy material?
- The prevalence of germ cell tumors in CAIS is estimated at 0.8%, compared with 15% in PAIS (Table 3). Prevalence rates rise significantly after puberty. Based on our results regarding germ cell loss in CAIS patients (28), we hypothesize that even small amounts of testosterone are sufficient to prevent germ cells from undergoing apoptosis, most likely via indirect mechanisms mediated by the surrounding Sertoli cells (germ cells themselves do not have androgen receptors). In this context, the following considerations are relevant: Are patients with the CAIS (provided that the diagnosis of CAIS is made on very strict




FIG. 7. Classification of patients with DSD. The risk for tumor development is related to the pattern and degree of gonadal differentiation.

* No risk in the absence of germ cells or in the absence of the TSPY gene (in peripheral blood and/or gonadal tissue)

TABLE 6. New classification system for patients with DSD

Affected level	Relation to karyotype	Underlying defect	Gonadal differentiation pattern	Testis	UGT	Ovary	Streak	Presence of Y/TSPY ^a
Gonadal sex: Chromosomal sex (Sex chromosome DSD)	45,X (Turner syndrome)	Sex chromosome: numerical	Complete GD (or ovaries) ^b	–	–	+/–	+/–	–
	47,XXY (Klinefelter syndrome)	Sex chromosome: numerical	Testes	+	–	–	–	+
	45,X/46,XY and variants	Sex chromosome: numerical	Complete GD	–	–	–	+	+/–
			Testicular dysgenesis ^c	+	–	–	+/–	+/–
			Ovotesticular dysgenesis ^d	+	–	+	–	+/–
			Undifferentiated GD ^e	+/–	+	+/–	+/–	+/–
	46,XX/46,XY and variants	Sex chromosome: numerical	Complete GD	–	–	–	+	+/–
			Testicular dysgenesis	+	–	–	+/–	+/–
			Ovotesticular dysgenesis	+	–	+	–	+/–
			Undifferentiated GD	+/–	+	+/–	+/–	+/–
Gonadal sex: Mutation in sex-determining gene	46,XY GD	Mutation in sex-determining gene	Complete GD	–	–	–	+	+
			Testicular dysgenesis	+	–	–	+/–	+
			Ovotesticular dysgenesis	+	–	+	–	+
			Undifferentiated GD	+/–	+	+/–	+/–	+
			Gonadal regression	–	–	–	–	+
	46,XX GD	Mutation in sex-determining gene	Complete GD	–	–	–	+	+/–
			Testicular dysgenesis	+	–	–	+/–	+/–
			Ovotesticular dysgenesis	+	–	+	–	+/–
			Undifferentiated GD	+/–	+	+/–	+/–	+/–
Phenotypic sex	46,XY (Undervirilization)	Disorders in T and DHT biosynthesis ^f	Testes	+	–	–	–	+
		End organ resistance for T action ^g	Testes	+	–	–	–	+
		Testicular unresponsiveness to LH and hCG	Testes	+	–	–	–	+
		Disorders of AMH and AMH receptor	Testes	+	–	–	–	+
	46,XX (Hypervirilization)	Fetal: Disorders in adrenal steroid biosynthesis	Ovaries	–	–	+	–	–
		Fetoplacental: aromatase deficiency	Ovaries	–	–	+	–	–
		Maternal androgens	Ovaries	–	–	+	–	–
		Mutations in genes related to ovarian differentiation	Complete GD or ovaries	–	–	+/–	+/–	–
Other	46,XY	Severe hypospadias, cloacal extrophy	Testes	+	–	–	–	+
	46,XX	Cloacal extrophy, vaginal atresia	Ovaries	–	–	+	–	–

The combined presence of testicular tissue or UGT and the TSPY gene contains an increased risk for the development of germ cell tumors. hCG, Human chorionic gonadotropin; DHT, dihydrotestosterone; T, testosterone; AMH, anti-Müllerian hormone.

^a The presence of Y/TSPY must be excluded first in the peripheral blood karyotype. If negative in the presence of testicular or UGT, it must be excluded in gonadal tissue by fluorescence *in situ* hybridization or PCR.

^b Normal female phenotype in the presence of bilateral streak gonads (devoid of germ cells) in a 46,XX or 46,XY individual.

^c (Mostly ambiguous) phenotype resulting from the presence of one (dysgenetic) testis on one side and a streak on the other side, or of two dysgenetic testes.

^d (Mostly ambiguous) phenotype resulting from the presence of both testicular tissue consisting of seminiferous tubules, and ovarian tissue, containing germ cells that are all enclosed in primordial and eventually growing follicles in the same individual, either in a single gonad or in opposite gonads.

^e (Mostly ambiguous) phenotype resulting from the presence of undifferentiated gonadal tissue or SC, whether or not in combination with testicular or ovarian tissue or a streak.

^f Patients with 5 α -reductase II deficiency should be considered separately within this group since this defect, in contrast to the other enzyme defects, only affects the development of the male external genitalia.

^g A strict subclassification of patients in groups CAIS *vs.* severe AIS and PAIS, based on the combination of clinical data, histology of Wolffian duct derivatives, sequencing of the androgen receptor and androgen receptor binding studies, is essential to demonstrate the expected major difference in tumor risk between these groups.

criteria) at risk for germ cell tumor development at all? If the answer is negative, it is preferable to leave their gonads in place to allow these patients to profit from their en-

dogenous hormone production. Thus, the suggestion of some authors (54, 117) to reclassify AIS patients into PAIS, severe AIS, and CAIS is of relevance—the true CAIS pa-

Downloaded from https://academic.oup.com/edrv/article/27/5/468/2355191 by guest on 10 April 2024

TABLE 7. Summary of the risk of germ cell malignancy in the various forms of DSD, subdivided into high, intermediate, low, and possibly no risk

Risk group	Disorder	Risk (%)	Action needed	No. of studies	No. of patients
High	GD ^a (+Y) ^b intra-abd	15–35	Gonadectomy ^c	12	>350
	PAIS nonscrotal	15	Gonadectomy ^c	3	80
	Frasier	60	Gonadectomy ^c	1	15
	Denys-Drash (+Y)	40	Gonadectomy ^c	1	5
Intermediate	Turner (+Y)	12	Gonadectomy ^c	11	43
	17β-HSD	28	Watchful waiting and possible biopsy	2	7
Low	CAIS	0.8	Biopsy ^d and possible irrad/gonadectomy	3	120
	Ovotest. DSD	3	Testicular tissue removal in case of ♀ rearing?	3	426
	Turner (–Y ^e)	1	None	11	557
Unknown ^f	5α-Reductase	0	Unresolved	1	3
	Leydig cell hypoplasia	0	Unresolved	1	2
	GD (+Y) ^b scrotal	Unknown	Biopsy ^d and irrad?	0	0
	PAIS scrotal gonad	Unknown	Biopsy ^d and irrad?	0	0

Recommended actions are indicated, as well as the number of studies and patients included in the survey. In case of PAIS, 17β-HSD, and ovotestis, the decision regarding gonadectomy is largely determined by sex of rearing. Relevant data from the recently published study by Hannema *et al.* (107) are not included in this table because it is at present unclear to us to what extent patient series from this study show overlap with patient series from a previously published study by the same group (117). Intra-abd, Intraabdominal located gonad; nonscrotal, nonscrotally located gonad; scrotal, scrotally located gonad; irrad, local irradiation with 18 Gy; ovotest. DSD, formally ovotestis (true hermaphrodite).

^a GD (including not further specified, 46XY, 46X/46XY, mixed, partial, complete).

^b GBY region positive, including the TSPY gene.

^c At time of diagnosis.

^d At puberty, allowing investigation of at least 30 seminiferous tubules, preferential diagnosis based on OCT3/4 immunohistochemistry.

^e PCR detection of Y-chromosomal sequences (in particular the GBY region) is implicated if a marker is identified by karyotyping.

^f Based on current knowledge (single study including limited number of patients, or no studies reported at all).

tients, without pubic hair growth at puberty and without Wolffian duct derivatives, being the only category in which such a policy would be defensible at present. A fourth category could include AIS phenotypic males with infertility, in whom the prevalence of germ cell tumors is not specifically determined at present. However, precise information regarding the development of secondary sexual characteristics (hair growth) and the presence or absence of Wolffian duct derivatives is often lacking in published patient series and case record files. Moreover, unless the androgen receptor mutation induces the formation of a stop codon, no *in vivo* or *in vitro* test is presently able to differentiate between these different categories. Further research is mandatory to answer these questions.

- Very limited or no data at all exist at present regarding the prevalence and age of occurrence of germ cell tumors in patients with PAIS, 17β-HSD deficiency, Leydig cell hypoplasia, and *WT-1* and other gene mutations. However, answering this question is of major importance because these patients more and more will be reared as males, preferably with their gonads preserved and fixed in the scrotum. The establishment of safe follow-up protocols for this patient population by noninvasive techniques (*e.g.*, ultrasound) is mandatory. In adult males diagnosed with CIS, it was shown that local low-dose irradiation prevents progression toward invasiveness and allows the preservation of hormonal function in most patients (118). To what extent these data also apply to CIS lesions in the testes of young patients with DSD remains to be examined but is of high relevance because it possibly offers to them an alternative to gonadectomy.
- Is the prevalence of germ cell tumors in patients with true hermaphroditism as low as it appears to be? A low prevalence would indeed be expected, because their gonads

consist mainly of well-differentiated ovarian tissue, with no risk for neoplasms, and of well-differentiated testicular tissue, eventually displaying maturation delay. Moreover, 60% of true hermaphrodites have a 46,XX karyotype (119). However, to what extent the peripheral blood karyotype in these patients corresponds to their gonadal karyotype is actually unknown.

- In light of its suspected role in the development of germ cell tumors, the gonadal presence of the TSPY gene and/or protein should always be ruled out in the presence of dysgenetic testes, SC, or true hermaphroditism, even if the karyotype does not reveal a Y-bearing cell line.
- The diagnosis of pure GD should only be made on very strict criteria, because the total absence of germ cells rules out the possibility of germ cell tumors. The presence of rare isolated germ cells in otherwise ovarian-type fibrous stroma should always be designated as UGT and contains a high risk for GB formation.

In view of the limited patient numbers, an intense and multicenter collaboration is needed to answer these questions in a restricted time period. A first step to achieve this goal was recently made during an international consensus meeting (Chicago, IL, October 2005), where the implementation of the data presented in this article led to the proposal of new recommendations for the management of patients with DSD with regard to gonadectomy (Table 7) (116). In the future, the conclusions drawn from these guidelines may serve as a starting point for the establishment of safe, evidence-based protocols for a definitively revised management of patients with DSD, in accordance with the possibilities offered by modern diagnostic and surgical techniques and with the aspirations of patient advocacy groups all over the world.

Acknowledgments

The authors thank all the collaborators and laboratory staff involved in our own studies who that referred to in this review.

Address all correspondence and requests for reprints to: L. H. J. Looijenga, Department of Pathology, Erasmus MC-University Medical Center Rotterdam, Josephine Nefkens Institute, Room 430b, P.O. Box 1738, 3000 DR Rotterdam, The Netherlands. E-mail: l.looienga@erasmusmc.nl

The authors are financially supported by the European Society for Paediatric Endocrinology Research Fellowship, sponsored by Novo Nordisk A/S (to M.C.), by the Belgian Study Group for Pediatric Endocrinology (to M.C.), and by the Dutch Cancer Society (to L.H.J.L. and K.P.W.).

M.C., K.P.W., J.W.O., and L.H.J.L. have nothing to declare. S.L.S.D. received consulting fees from Eli Lilly.

References

- Houk CP, Lee PA 2005 Intersexed states: diagnosis and management. *Endocrinol Metab Clin North Am* 34:791–810, xi
- Grumbach MM, Hughes IA, Conte FA 2003 Disorders of sex differentiation. In: Larsen PR, Kronenberg HM, Melmed S, Polonsky KM, eds. *Williams textbook of endocrinology*. 10th ed. Philadelphia: W.B. Saunders (Elsevier); 842–1002
- Money J, Ehrhardt AA 1972 Man and woman, boy and girl. Baltimore: Johns Hopkins University Press
- Reiner WG, Gearhart JP 2004 Discordant sexual identity in some genetic males with cloacal exstrophy assigned to female sex at birth. *N Engl J Med* 350:333–341
- Reiner WG 1999 Assignment of sex in neonates with ambiguous genitalia. *Curr Opin Pediatr* 11:363–365
- Creighton SM, Minto CL, Liao LM, Alderson J, Simmonds M 2004 Meeting between experts: evaluation of the first UK forum for lay and professional experts in intersex. *Patient Educ Couns* 54:153–157
- Crone J, Amann G, Gheradini R, Kirchlechner V, Fekete CN 2002 Management of 46, XY partial gonadal dysgenesis—revisited. *Wien Klin Wochenschr* 114:462–467
- Official web site of the Intersex Society of North America. <http://www.isna.org>
- Creighton S, Minto C 2001 Managing intersex. *BMJ* 323:1264–1265
- Wilson JD 1999 The role of androgens in male gender role behavior. *Endocr Rev* 20:726–737
- Reiner WG, Kropp BP 2004 A 7-year experience of genetic males with severe phallic inadequacy assigned female. *J Urol* 172:2395–2398
- Slijper FM, Drop SL, Molenaar JC, de Muinck Keizer-Schrama SM 1998 Long-term psychological evaluation of intersex children. *Arch Sex Behav* 27:125–144
- Meyer-Bahlburg HF 1999 Gender assignment and reassignment in 46,XY pseudohermaphroditism and related conditions. *J Clin Endocrinol Metab* 84:3455–3458
- Nihoul-Fekete C, Thibaud E, Lortat-Jacob S, Josso N 2006 Long-term surgical results and patient satisfaction with male pseudohermaphroditism or true hermaphroditism: a cohort of 63 patients. *J Urol* 175:1878–1884
- Nihoul-Fekete C 2005 Does surgical genitoplasty affect gender identity in the intersex infant? *Horm Res* 64(Suppl 2):23–26
- Scully RE 1970 Gonadoblastoma. A review of 74 cases. *Cancer* 25:1340–1356
- Verp MS, Simpson JL 1987 Abnormal sexual differentiation and neoplasia. *Cancer Genet Cytogenet* 25:191–218
- Schellhas HF 1974 Malignant potential of the dysgenetic gonad. Part 1. *Obstet Gynecol* 44:289–309
- Manuel M, Katayama PK, Jones Jr HW 1976 The age of occurrence of gonadal tumors in intersex patients with a Y chromosome. *Am J Obstet Gynecol* 124:293–300
- Robboy SJ, Miller T, Donahoe PK, Jahre C, Welch WR, Haseltine FP, Miller WA, Atkins L, Crawford JD 1982 Dysgenesis of testicular and streak gonads in the syndrome of mixed gonadal dysgenesis: perspective derived from a clinicopathologic analysis of twenty-one cases. *Hum Pathol* 13:700–716
- Troche V, Hernandez E 1986 Neoplasia arising in dysgenetic gonads. *Obstet Gynecol Surv* 41:74–79
- Savage MO, Lowe DG 1990 Gonadal neoplasia and abnormal sexual differentiation. *Clin Endocrinol (Oxf)* 32:519–533
- Oosterhuis JW, Looijenga LH 2005 Testicular germ-cell tumours in a broader perspective. *Nat Rev Cancer* 5:210–222
- Gourlay WA, Johnson HW, Pantzar JT, McGillivray B, Crawford R, Nielsen WR 1994 Gonadal tumors in disorders of sexual differentiation. *Urology* 43:537–540
- Morris JM, Mahesh VB 1963 Further observations on the syndrome, “Testicular Feminization”. *Am J Obstet Gynecol* 87:731–748
- Bangsboll S, Qvist I, Lebech PE, Lewinsky M 1992 Testicular feminization syndrome and associated gonadal tumors in Denmark. *Acta Obstet Gynecol Scand* 71:63–66
- Regadera J, Martinez-Garcia F, Paniagua R, Nistal M 1999 Androgen insensitivity syndrome: an immunohistochemical, ultrastructural, and morphometric study. *Arch Pathol Lab Med* 123:225–234
- Cools M, van Aerde K, Kersemaekers AMF, Boter M, Drop SL, Wolffenbuttel KP, Steyerberg EW, Oosterhuis JW, Looijenga LH 2005 Morphological and immunohistochemical differences between gonadal maturation delay and early germ cell neoplasia in patients with undervirilization syndromes. *J Clin Endocrinol Metab* 90:5295–5303
- van Niekerk WA, Retief AE 1981 The gonads of human true hermaphrodites. *Hum Genet* 58:117–122
- Ulbricht TM 1997 Neoplasms of the testis. In: Bostwick DG, Eble JN, eds. *Urologic surgical pathology*. 1st ed. St. Louis, MO: Mosby
- Rajpert-De Meyts E, Hanstein R, Jorgensen N, Graem N, Vogt PH, Skakkebaek NE 2004 Developmental expression of POU5F1 (OCT-3/4) in normal and dysgenetic human gonads. *Hum Reprod* 19:1338–1344
- Gobel U, Schneider DT, Calaminus G, Haas RJ, Schmidt P, Harms D 2000 Germ-cell tumors in childhood and adolescence. GPOH MAKEI and the MAHO study groups. *Ann Oncol* 11:263–271
- Hussain A 2005 Germ cell tumors. *Curr Opin Oncol* 17:268–274
- Gornall P 1997 Paediatric surgical oncology. 7—germ cell tumours. *Eur J Surg Oncol* 23:68–72
- Lau Y, Chou P, Iezzoni J, Alonzo J, Komuves L 2000 Expression of a candidate gene for the gonadoblastoma locus in gonadoblastoma and testicular seminoma. *Cytogenet Cell Genet* 91:160–164
- Lau YF 1999 Gonadoblastoma, testicular and prostate cancers, and the TSPY gene. *Am J Hum Genet* 64:921–927
- Salo P, Kaariainen H, Petrovic V, Peltomaki P, Page DC, de la Chapelle A 1995 Molecular mapping of the putative gonadoblastoma locus on the Y chromosome. *Genes Chromosomes Cancer* 14:210–214
- Tsuchiya K, Reijo R, Page DC, Distech CM 1995 Gonadoblastoma: molecular definition of the susceptibility region on the Y chromosome. *Am J Hum Genet* 57:1400–1407
- Page DC 1987 Hypothesis: a Y-chromosomal gene causes gonadoblastoma in dysgenetic gonads. *Development* 101(Suppl):151–155
- Pinczowski D, McLaughlin JK, Lackgren G, Adami HO, Persson I 1991 Occurrence of testicular cancer in patients operated on for cryptorchidism and inguinal hernia. *J Urol* 146:1291–1294
- Looijenga LH, Oosterhuis JW 2002 Pathobiology of testicular germ cell tumors: views and news. *Anal Quant Cytol Histol* 24:263–279
- Rutgers JL, Scully RE 1987 Pathology of the testis in intersex syndromes. *Semin Diagn Pathol* 4:275–291
- Rutgers JL, Scully RE 1991 The androgen insensitivity syndrome (testicular feminization): a clinicopathologic study of 43 cases. *Int J Gynecol Pathol* 10:126–144
- Ramani P, Yeung CK, Habeebu SS 1993 Testicular intratubular germ cell neoplasia in children and adolescents with intersex. *Am J Surg Pathol* 17:1124–1133
- Salle B, Hedinger C 1970 Gonadal histology in children with male pseudohermaphroditism and mixed gonadal dysgenesis. *Acta Endocrinol (Copenh)* 64:211–227
- Beheshti M, Hardy BE, Mancor K, McLorie G, Churchill BM 1987

- Neoplastic potential in patients with disorders of sexual differentiation. *Urology* 29:404–407
47. **Armstrong GR, Buckley CH, Kelsey AM** 1991 Germ cell expression of placental alkaline phosphatase in male pseudohermaphroditism. *Histopathology* 18:541–547
 48. **Muller J** 1984 Morphometry and histology of gonads from twelve children and adolescents with the androgen insensitivity (testicular feminization) syndrome. *J Clin Endocrinol Metab* 59:785–789
 49. **Cassio A, Cacciari E, D'Errico A, Balsamo A, Grigioni FW, Pascucci MG, Bacci F, Tacconi M, Mancini AM** 1990 Incidence of intratubular germ cell neoplasia in androgen insensitivity syndrome. *Acta Endocrinol (Copenh)* 123:416–422
 50. **Ahmed SF, Cheng A, Dovey L, Hawkins JR, Martin H, Rowland J, Shimura N, Tait AD, Hughes IA** 2000 Phenotypic features, androgen receptor binding, and mutational analysis in 278 clinical cases reported as androgen insensitivity syndrome. *J Clin Endocrinol Metab* 85:658–665
 51. **Sinnecker GH, Hiort O, Nitsche EM, Holterhus PM, Kruse K** 1997 Functional assessment and clinical classification of androgen sensitivity in patients with mutations of the androgen receptor gene. German Collaborative Intersex Study Group. *Eur J Pediatr* 156:7–14
 52. **McPhaul MJ, Marcelli M, Zoppi S, Griffin JE, Wilson JD** 1993 Genetic basis of endocrine disease. 4. The spectrum of mutations in the androgen receptor gene that causes androgen resistance. *J Clin Endocrinol Metab* 76:17–23
 53. **Boehmer AL, Brinkmann O, Bruggenwirth H, van Assendelft C, Otten BJ, Verleun-Mooijman MC, Niermeijer MF, Brunner HG, Rouwe CW, Waelkens JJ, Oostdijk W, Kleijer WJ, van der Kwast TH, de Vroede MA, Drop SL** 2001 Genotype versus phenotype in families with androgen insensitivity syndrome. *J Clin Endocrinol Metab* 86:4151–4160
 54. **Quigley CA, De Bellis A, Marschke KB, el-Awady MK, Wilson EM, French FS** 1995 Androgen receptor defects: historical, clinical, and molecular perspectives. *Endocr Rev* 16:271–321
 55. **Chen CP, Chern SR, Wang TY, Wang W, Wang KL, Jeng CJ** 1999 Androgen receptor gene mutations in 46,XY females with germ cell tumours. *Hum Reprod* 14:664–670
 56. **Giwerzman A, Muller J, Skakkebaek NE** 1991 Prevalence of carcinoma in situ and other histopathological abnormalities in testes from 399 men who died suddenly and unexpectedly. *J Urol* 145:77–80
 57. **Muller J, Skakkebaek NE** 1984 Testicular carcinoma in situ in children with the androgen insensitivity (testicular feminisation) syndrome. *Br Med J (Clin Res Ed)* 288:1419–1420
 58. **MacLaughlin DT, Donahoe PK** 2004 Sex determination and differentiation. *N Engl J Med* 350:367–378
 59. **Fleming A, Vilain E** 2005 The endless quest for sex determination genes. *Clin Genet* 67:15–25
 60. **Veitia RA, Salas-Cortes L, Ottolenghi C, Pailhoux E, Cotinot C, Fellous M** 2001 Testis determination in mammals: more questions than answers. *Mol Cell Endocrinol* 179:3–16
 61. **Ahmed SF, Hughes IA** 2002 The genetics of male undermasculinization. *Clin Endocrinol (Oxf)* 56:1–18
 62. **Cools M, Stoop H, Kersemaekers AMF, Drop SLS, Wolffebuttel KP, Bourguignon J-P, Slowikowska-Hilczek J, Kula K, Faratz S, Oosterhuis JW, Looijenga LHJ** 2006 Gonadoblastoma arising in undifferentiated gonadal tissue within dysgenetic gonads. *J Clin Endocrinol Metab* 91:2404–2413
 63. **Trobs RB, Hoepffner W, Buhligen U, Limbach A, Keller E, Schutz A, Horn LC, Kiess W, Bennek J** 2004 Video-assisted gonadectomy in children with Ullrich Turner syndrome or 46,XY gonadal dysgenesis. *Eur J Pediatr Surg* 14:179–184
 64. **Slowikowska-Hilczek J, Szarras-Czapnik M, Kula K** 2001 Testicular pathology in 46,XY dysgenetic male pseudohermaphroditism: an approach to pathogenesis of testis cancer. *J Androl* 22:781–792
 65. **Donahoe PK, Crawford JD, Hendren WH** 1979 Mixed gonadal dysgenesis, pathogenesis, and management. *J Pediatr Surg* 14:287–300
 66. **Slowikowska-Hilczek J, Romer TE, Kula K** 2003 Neoplastic potential of germ cells in relation to disturbances of gonadal organogenesis and changes in karyotype. *J Androl* 24:270–278
 67. **Krasna IH, Lee ML, Smilow P, Sciorra L, Eierman L** 1992 Risk of malignancy in bilateral streak gonads: the role of the Y chromosome. *J Pediatr Surg* 27:1376–1380
 68. **Horn LC, Limbach A, Hoepffner W, Trobs RB, Keller E, Froster UG, Richter CE, Jakubiczka S** 2005 Histologic analysis of gonadal tissue in patients with Ullrich-Turner syndrome and derivative Y chromosomes. *Pediatr Dev Pathol* 8:197–203
 69. **Muller J, Skakkebaek NE, Ritzen M, Ploen L, Petersen KE** 1985 Carcinoma in situ of the testis in children with 45,X/46,XY gonadal dysgenesis. *J Pediatr* 106:431–436
 70. **Medlej R, Lobaccaro JM, Berta P, Belon C, Leheup B, Toubanc JE, Weill J, Chevalier C, Dumas R, Sultan C** 1992 Screening for Y-derived sex determining gene SRY in 40 patients with Turner syndrome. *J Clin Endocrinol Metab* 75:1289–1292
 71. **Kocova M, Siegel SF, Wenger SL, Lee PA, Trucco M** 1993 Detection of Y chromosome sequences in Turner's syndrome by Southern blot analysis of amplified DNA. *Lancet* 342:140–143
 72. **Coto E, Toral JF, Menendez MJ, Hernando I, Plasencia A, Benavides A, Lopez-Larrea C** 1995 PCR-based study of the presence of Y-chromosome sequences in patients with Ullrich-Turner syndrome. *Am J Med Genet* 57:393–396
 73. **Binder G, Koch A, Wajs E, Ranke MB** 1995 Nested polymerase chain reaction study of 53 cases with Turner's syndrome: is cytogenetically undetected Y mosaicism common? *J Clin Endocrinol Metab* 80:3532–3536
 74. **Lopez M, Canto P, Aguinaga M, Torres L, Cervantes A, Alfaro G, Mendez JP, Kofman-Alfaro S** 1998 Frequency of Y chromosomal material in Mexican patients with Ullrich-Turner syndrome. *Am J Med Genet* 76:120–124
 75. **Osipova GR, Karmanov ME, Kozlova SI, Evgrafov OV** 1998 PCR detection of Y-specific sequences in patients with Ullrich-Turner syndrome: clinical implications and limitations. *Am J Med Genet* 76:283–287
 76. **Mendes JR, Strufaldi MW, Delcelo R, Moises RC, Vieira JG, Kasamatsu TS, Galera MF, Andrade JA, Verreschi IT** 1999 Y-chromosome identification by PCR and gonadal histopathology in Turner's syndrome without overt Y-mosaicism. *Clin Endocrinol (Oxf)* 50:19–26
 77. **Gravholt CH, Fedder J, Naeraa RW, Muller J** 2000 Occurrence of gonadoblastoma in females with Turner syndrome and Y chromosome material: a population study. *J Clin Endocrinol Metab* 85:3199–3202
 78. **Fernandez-Garcia R, Garcia-Doval S, Costoya S, Pasaro E** 2000 Analysis of sex chromosome aneuploidy in 41 patients with Turner syndrome: a study of 'hidden' mosaicism. *Clin Genet* 58:201–208
 79. **Nishi MY, Domenice S, Medeiros MA, Mendonca BB, Billerbeck AE** 2002 Detection of Y-specific sequences in 122 patients with Turner syndrome: nested PCR is not a reliable method. *Am J Med Genet* 107:299–305
 80. **Alvarez-Nava F, Soto M, Sanchez MA, Fernandez E, Lanes R** 2003 Molecular analysis in Turner syndrome. *J Pediatr* 142:336–340
 81. **Joki-Erkila MM, Karikoski R, Rantala I, Lenko HL, Visakorpi T, Heinonen PK** 2002 Gonadoblastoma and dysgerminoma associated with XY gonadal dysgenesis in an adolescent with chronic renal failure: a case of Frasier syndrome. *J Pediatr Adolesc Gynecol* 15:145–149
 82. **Pelletier J, Bruening W, Kashtan CE, Mauer SM, Manivel JC, Striegel JE, Houghton DC, Junien C, Habib R, Fouser L, Fine RN, Silverman BL, Haber DA, Housman D** 1991 Germline mutations in the Wilms' tumor suppressor gene are associated with abnormal urogenital development in Denys-Drash syndrome. *Cell* 67:437–447
 83. **Pena-Alonso R, Nieto K, Alvarez R, Palma I, Najera N, Erana L, Dorantes LM, Kofman-Alfaro S, Queipo G** 2005 Distribution of Y-chromosome-bearing cells in gonadoblastoma and dysgenetic testis in 45,X/46,XY infants. *Mod Pathol* 18:439–445
 84. **de Jong J, Stoop H, Dohle GR, Bangma CH, Kliffen M, van Esser JW, van den Bent M, Kros JM, Oosterhuis JW, Looijenga LH** 2005 Diagnostic value of OCT3/4 for pre-invasive and invasive testicular germ cell tumours. *J Pathol* 206:242–249
 85. **Kersemaekers AM, Honecker F, Stoop H, Cools M, Molier M, Wolffebuttel K, Bokemeyer C, Li Y, Lau YF, Oosterhuis JW, Looijenga LH** 2005 Identification of germ cells at risk for neoplastic transformation in gonadoblastoma: an immunohistochemical study for OCT3/4 and TSPY. *Hum Pathol* 36:512–521
 86. **Looijenga LH, Stoop H, de Leeuw HP, de Gouveia Brazao CA,**

- Gillis AJ, van Roozendaal KE, van Zoelen EJ, Weber RF, Wolffenbutter KP, van Dekken H, Honecker F, Bokemeyer C, Perlman EJ, Schneider DT, Kononen J, Sauter G, Oosterhuis JW 2003 POU5F1 (OCT3/4) identifies cells with pluripotent potential in human germ cell tumors. *Cancer Res* 63:2244–2250
87. Gidekel S, Pizov G, Bergman Y, Pikarsky E 2003 Oct-3/4 is a dose-dependent oncogenic fate determinant. *Cancer Cell* 4:361–370
 88. Jones TD, Ulbright TM, Eble JN, Cheng L 2004 OCT4: a sensitive and specific biomarker for intratubular germ cell neoplasia of the testis. *Clin Cancer Res* 10:8544–8547
 89. Jones TD, Ulbright TM, Eble JN, Baldrige LA, Cheng L 2004 OCT4 staining in testicular tumors: a sensitive and specific marker for seminoma and embryonal carcinoma. *Am J Surg Pathol* 28: 935–940
 90. Cheng L, Thomas A, Roth LM, Zheng W, Michael H, Karim FW 2004 OCT4: a novel biomarker for dysgerminoma of the ovary. *Am J Surg Pathol* 28:1341–1346
 91. Cheng L 2004 Establishing a germ cell origin for metastatic tumors using OCT4 immunohistochemistry. *Cancer* 101:2006–2010
 92. Ezech UI, Turek PJ, Reijo RA, Clark AT 2005 Human embryonic stem cell genes OCT4, NANOG, STELLAR, and GDF3 are expressed in both seminoma and breast carcinoma. *Cancer* 104:2255–2265
 93. Hoei-Hansen CE, Nielsen JE, Almstrup K, Sonne SB, Graem N, Skakkebaek NE, Leffers H, Rajpert-De Meyts E 2004 Transcription factor AP-2 γ is a developmentally regulated marker of testicular carcinoma in situ and germ cell tumors. *Clin Cancer Res* 10:8521–8530
 94. Pesce M, Wang X, Wolgemuth DJ, Scholer H 1998 Differential expression of the Oct-4 transcription factor during mouse germ cell differentiation. *Mech Dev* 71:89–98
 95. Niwa H, Miyazaki J, Smith AG 2000 Quantitative expression of Oct-3/4 defines differentiation, dedifferentiation or self-renewal of ES cells. *Nat Genet* 24:372–376
 96. Matin MM, Walsh JR, Gokhale PJ, Draper JS, Bahrami AR, Morton I, Moore HD, Andrews PW 2004 Specific knockdown of Oct4 and β 2-microglobulin expression by RNA interference in human embryonic stem cells and embryonic carcinoma cells. *Stem Cells* 22:659–668
 97. Kehler J, Tolkunova E, Koschorz B, Pesce M, Gentile L, Boiani M, Lomeli H, Nagy A, McLaughlin KJ, Scholer HR, Tomilin A 2004 Oct4 is required for primordial germ cell survival. *EMBO Rep* 5:1078–1083
 98. Stoop H, Honecker F, Cools M, de Krijger R, Bokemeyer C, Looijenga LH 2005 Differentiation and development of human female germ cells during prenatal gonadogenesis: an immunohistochemical study. *Hum Reprod* 20:1466–1476
 99. Honecker F, Stoop H, de Krijger RR, Chris Lau YF, Bokemeyer C, Looijenga LH 2004 Pathobiological implications of the expression of markers of testicular carcinoma in situ by fetal germ cells. *J Pathol* 203:849–857
 100. Cools M, Honecker F, Stoop H, Veltman JD, de Krijger RR, Steyerberg E, Wolffenbutter KP, Bokemeyer C, Lau YF, Drop SL, Looijenga LH 2006 Maturation delay of germ cells in trisomy 21 fetuses results in increased risk for the development of testicular germ cell tumors. *Hum Pathol* 37:101–111
 101. Schnieders F, Dork T, Arnemann J, Vogel T, Werner M, Schmidtke J 1996 Testis-specific protein, Y-encoded (TSPY) expression in testicular tissues. *Hum Mol Genet* 5:1801–1807
 102. Lau YF, Lau HW, Komuves LG 2003 Expression pattern of a gonadoblastoma candidate gene suggests a role of the Y chromosome in prostate cancer. *Cytogenet Genome Res* 101:250–260
 103. Yin YH, Li YY, Qiao H, Wang HC, Yang XA, Zhang HG, Pang XW, Zhang Y, Chen WF 2005 TSPY is a cancer testis antigen expressed in human hepatocellular carcinoma. *Br J Cancer* 93:458–463
 104. Skakkebaek NE, Rajpert-De Meyts E, Main KM 2001 Testicular dysgenesis syndrome: an increasingly common developmental disorder with environmental aspects. *Hum Reprod* 16:972–978
 105. Skakkebaek NE 2004 Testicular dysgenesis syndrome: new epidemiological evidence. *Int J Androl* 27:189–191
 106. Jacobsen GK, Henriques UV 1992 A fetal testis with intratubular germ cell neoplasia (ITGCN). *Mod Pathol* 5:547–549
 107. Hannema S, Scott I, Rajpert-De Meyts E, Skakkebaek N, Coleman N, Hughes I 2006 Testicular development in the complete androgen insensitivity syndrome. *J Pathol* 208:518–527
 108. Sell S, Pierce GB 1994 Maturation arrest of stem cell differentiation is a common pathway for the cellular origin of teratocarcinomas and epithelial cancers. *Lab Invest* 70:6–22
 109. Holm TM, Jackson-Grusby L, Brambrink T, Yamada Y, Rideout 3rd WM, Jaenisch R 2005 Global loss of imprinting leads to widespread tumorigenesis in adult mice. *Cancer Cell* 8:275–285
 110. van Gurp RJ, Oosterhuis JW, Kalscheuer V, Mariman EC, Looijenga LH 1994 Biallelic expression of the H19 and IGF2 genes in human testicular germ cell tumors. *J Natl Cancer Inst* 86:1070–1075
 111. Gondos B 1985 Development of the reproductive organs. *Ann Clin Lab Sci* 15:363–373
 112. McLaren A, Southee D 1997 Entry of mouse embryonic germ cells into meiosis. *Dev Biol* 187:107–113
 113. McLaren A 2000 Germ and somatic cell lineages in the developing gonad. *Mol Cell Endocrinol* 163:3–9
 114. McLaren A 2003 Primordial germ cells in the mouse. *Dev Biol* 262:1–15
 115. Pauls K, Franke FE, Buttner R, Zhou H 2005 Gonadoblastoma: evidence for a stepwise progression to dysgerminoma in a dysgenetic ovary. *Virchows Arch* 447:603–609
 116. Hughes IA, Houk C, Ahmed SF, Lee PA; LWPES Consensus Group; ESPE Consensus Group 2006 Consensus statement on management of intersex disorders. *Arch Dis Child* 91:554–563
 117. Hannema SE, Scott IS, Hodapp J, Martin H, Coleman N, Schwabe JW, Hughes IA 2004 Residual activity of mutant androgen receptors explains wolffian duct development in the complete androgen insensitivity syndrome. *J Clin Endocrinol Metab* 89:5815–5822
 118. Rorth M, Rajpert-De Meyts E, Andersson L, Dieckmann KP, Fossa SD, Grigor KM, Hendry WF, Herr HW, Looijenga LH, Oosterhuis JW, Skakkebaek NE 2000 Carcinoma in situ in the testis. *Scand J Urol Nephrol Suppl*:166–186
 119. Queipo G, Zenteno JC, Pena R, Nieto K, Radillo A, Dorantes LM, Erana L, Lieberman E, Soderlund D, Jimenez AL, Ramon G, Kofman-Alfaro S 2002 Molecular analysis in true hermaphroditism: demonstration of low-level hidden mosaicism for Y-derived sequences in 46,XX cases. *Hum Genet* 111:278–283
 120. Hart AH, Hartley L, Parker K, Ibrahim M, Looijenga LH, Pauchnik M, Chow CW, Robb L 2005 The pluripotency homeobox gene NANOG is expressed in human germ cell tumors. *Cancer* 104: 2092–2098
 121. Hustin J, Collette J, Franchimont P 1987 Immunohistochemical demonstration of placental alkaline phosphatase in various states of testicular development and in germ cell tumours. *Int J Androl* 10:29–35
 122. Strohmeyer T, Reese D, Press M, Ackermann R, Hartmann M, Slamon D 1995 Expression of the c-kit proto-oncogene and its ligand stem cell factor (SCF) in normal and malignant human testicular tissue. *J Urol* 153:511–515
 123. Rajpert-De Meyts E, Skakkebaek NE 1994 Expression of the c-kit protein product in carcinoma-in-situ and invasive testicular germ cell tumours. *Int J Androl* 17:85–92
 124. Castrillon DH, Quade BJ, Wang TY, Quigley C, Crum CP 2000 The human VASA gene is specifically expressed in the germ cell lineage. *Proc Natl Acad Sci USA* 97:9585–9590