

Assessment of subclinical atherosclerosis using contrast-enhanced ultrasound

Stijn C.H. van den Oord^{1,2}, Gerrit L. ten Kate³, Zeynettin Akkus², Guillaume Renaud², Eric J.G. Sijbrands³, Folkert J. ten Cate¹, Aad van der Lugt⁴, Johan G. Bosch², Nico de Jong², Antonius F.W. van der Steen², and Arend F.L. Schinkel^{1,3*}

¹Department of Cardiology, Thoraxcenter Room Ba 304, Erasmus Medical Center, 's-Gravendijkwal 230, 3015 CE Rotterdam, The Netherlands; ²Department of Biomedical Engineering, Thoraxcenter, Erasmus Medical Center, Rotterdam, The Netherlands; ³Division of Pharmacology, Vascular and Metabolic Diseases, Department of Internal Medicine, Erasmus Medical Center, Rotterdam, The Netherlands; and ⁴Department of Radiology, Erasmus Medical Center, Rotterdam, The Netherlands

Received 14 March 2012; accepted after revision 2 May 2012; online publish-ahead-of-print 29 May 2012

Aims

The sensitivity of standard carotid ultrasound and colour Doppler for the detection of subclinical atherosclerotic plaques is suboptimal. The aim of this study is to assess whether contrast-enhanced ultrasound (CEUS) added to standard carotid ultrasound improves the detection of subclinical atherosclerosis.

Methods and results

Carotid intima–media thickness (CIMT) measurement, standard carotid ultrasound including colour Doppler imaging, and CEUS were performed in 100 asymptomatic patients with one or more risk factors for atherosclerosis. CEUS was performed using intravenous administration of SonoVue™ contrast agent (Bracco S.p.A., Milan, Italy). CIMT, standard ultrasound, colour Doppler, and CEUS were reviewed by two independent observers. Standard ultrasound, colour Doppler, and CEUS were scored for the presence of atherosclerotic plaques. Subclinical atherosclerosis was diagnosed if patients had a CIMT above their age-corrected threshold value or if atherosclerotic plaques were present on standard carotid ultrasound clips or CEUS clips. McNemar's test was performed to compare between groups. Twenty-one patients (21%) had a thickened CIMT value and were considered to have subclinical atherosclerosis. Standard carotid ultrasound including colour Doppler demonstrated atherosclerotic plaques in 77 patients (77%). The addition of CEUS to the standard ultrasound protocol demonstrated atherosclerotic plaques in 88 patients (88%). The incorporation of CEUS into the standard carotid ultrasound protocol resulted in a significantly improved detection of patients with subclinical atherosclerosis ($P < 0.01$).

Conclusion

CEUS has an incremental value for the detection of subclinical atherosclerosis in the carotid arteries. Atherosclerotic plaques which were only detected with CEUS and not with standard carotid ultrasound and colour Doppler imaging were predominantly hypoechoic.

Keywords

Atherosclerosis • Carotid ultrasound • Contrast-enhanced ultrasound • Intima–media thickness

Introduction

Atherosclerosis is the leading cause of morbidity and mortality in western countries.¹ It is by far the most frequent underlying cause of coronary artery disease, carotid artery disease, and peripheral arterial disease. Generally, the development of atherosclerosis starts at young age and progresses asymptotically through adult life. The progression of atherosclerosis may result in atherosclerotic plaques prone to rupture. The rupture of these atherosclerotic plaques may cause acute thrombosis leading to clinical

events.² The detection of atherosclerosis before it leads to clinical events may improve risk-reducing strategies.

Carotid ultrasound is a widely available and relatively inexpensive technique to detect subclinical atherosclerosis. Carotid intima–media thickness (CIMT), as measured by B-mode ultrasound, has frequently been used as a surrogate marker for atherosclerosis.^{3,4} CIMT measurement is accurate, reproducible, and significantly related with clinical outcome. Still, there are indications that a systematic examination of the extracranial carotid arteries, including screening for the presence of plaques, may

* Corresponding author. Tel: +31 10 7033986; fax: +31 10 7035498, Email: a.schinkel@erasmusmc.nl

Published on behalf of the European Society of Cardiology. All rights reserved. © The Author 2012. For permissions please email: journals.permissions@oup.com

increase the sensitivity of ultrasound for identifying subclinical atherosclerosis. A recent meta-analysis demonstrated that the presence of plaques is a better predictor of clinical events when compared with CIMT measurement.⁵ Nevertheless, the sensitivity of standard carotid ultrasound of the carotid arteries to detect atherosclerotic plaques is suboptimal.⁶

Contrast-enhanced ultrasound (CEUS) provides a better delineation of the carotid arterial lumen than standard carotid ultrasound.^{7,8} However, the incremental value of CEUS for the detection of subclinical atherosclerosis in the carotid arteries has not been tested. The purpose of the present study is to assess whether CEUS added to standard carotid ultrasound improves the detection of subclinical atherosclerosis.

Methods

Patient population and study protocol

The study protocol was approved by the local Ethics Committee and all study participants provided informed consent prior to the ultrasound examination. Between April 2010 and February 2011, 100 consecutive patients (45 females) from the outpatient clinics of vascular medicine and cardiology were included in this prospective study. All patients had no known atherosclerosis but had an increased cardiovascular risk profile. Inclusion criteria were: one or more clinical risk factors for atherosclerosis and age ≥ 18 years. Risk factors were dyslipidaemia, hypertension, diabetes mellitus, smoking, and a familial history of cardiovascular disease. Exclusion criteria were contraindications for the use of ultrasound contrast agent, such as unstable angina, acute cardiac failure, acute endocarditis, known right-to-left shunts, and known allergy for microbubble contrast agents. Patient characteristics were registered, and a structured clinical interview and physical examination were performed. All patients underwent CIMT measurement and a standard carotid ultrasound examination in conjunction with CEUS.

Carotid ultrasound acquisition

Standard carotid ultrasound including colour Doppler, and CEUS were performed with a Philips iU-22 ultrasound system (Philips Medical Systems, Bothell, WA, USA), equipped with an L9-3 transducer. Image acquisition was performed by a trained sonography technician using a standard scanning protocol according to the American Society of Echocardiography consensus statement.⁹ In short, both left and right carotid arteries were examined with the patient in a supine position with the head supported at a 45° angle turned to the contralateral side. The left and the right common carotid artery (CCA), carotid bifurcation, internal carotid artery (ICA), external carotid artery (ECA), and vertebral arteries were imaged by B-mode ultrasound, colour Doppler, and pulse-wave Doppler. All anatomical sites were examined from different angles of view. Gain and imaging depth were adjusted per patient to obtain optimal ultrasound images. Each side was extensively evaluated for the presence of carotid plaques (Figure 1A). The degree of stenosis of the CCA, ICA, and ECA was assessed according to the current guidelines on the basis of spectral Doppler velocities.¹⁰

After standard carotid ultrasound, CEUS was performed using intravenous administration of SonoVue™ contrast agent (Bracco S.p.A., Milan, Italy). The contrast mode of the ultrasound system, using amplitude modulation and a mechanical index of 0.06–0.08, was used to optimize the CEUS examination. CEUS clips were recorded with a dual display mode for simultaneous standard B-mode ultrasound and

CEUS view (Figure 1B). Before injection of the ultrasound contrast agent, the intravenous access was flushed with a 5.0 mL NaCl 0.9% solution bolus injection. The ultrasound contrast agent was injected in boluses of 0.5 mL. Each contrast agent bolus was followed by a saline flush using 2.0 mL NaCl 0.9% solution. After administration of contrast agent, high-quality contrast images could be obtained for ~ 1 min. Contrast administration was repeated when required up to a maximum total dose of 10.0 mL. Both carotid arteries were examined using a standard acquisition protocol. Still frames and cineclips were digitally stored for offline analysis.

Carotid ultrasound analysis

Standard ultrasound and CEUS were reviewed offline by two independent observers unaware of the clinical data. For each patient, the same analysis protocol was followed. First, CIMT was measured in the left CCA, followed by screening for the presence of atherosclerotic plaques in the left carotid artery using the standard ultrasound clips. This analysis was repeated for the right carotid artery. Finally, CEUS clips were analysed; first, the left carotid artery was screened for the presence of atherosclerotic plaques. This analysis was repeated for the right carotid artery. In accordance with previously published studies, the CIMT was measured in the far wall of the distal 1 cm of the CCA.¹¹ Semi-automated CIMT measurement was performed using Qlab quantification software (Philips Healthcare, Best, The Netherlands). For each side, the CIMT measurement was performed three times on selected still frames on different R-peaks of the ECG signal. The mean value of three measurements was used in further statistical analysis. The threshold for a high CIMT value was calculated for each patient individually according to the formula reported by Jäger and Staub¹² (threshold value in mm = decade of life/10 + 0.2 mm). Patients were considered to have subclinical atherosclerosis if their mean CIMT was above this threshold value.

Carotid plaque screening was performed using the standard carotid ultrasound images and colour Doppler clips. Atherosclerotic plaque was defined as a focal structure encroaching into the lumen of at least 0.5 mm or 50% of the surrounding CIMT or demonstrates a thickness of >1.5 mm as measured from the media–adventitia interface to the intima–lumen interface.¹³ The presence of plaques was recorded for each side.

Subsequently, carotid plaque screening was performed using the CEUS images. In the CEUS images, the carotid lumen is enhanced by the presence of contrast agent, resulting in enhanced visualization of plaque and luminal morphology. Typically, the lumen appears hyperechoic, plaques and intima–media complex are hypoechoic, and the adventitial layer is hyperechoic. The definition of atherosclerotic plaques was identical to that used for standard ultrasound.¹³ The presence of plaques was recorded for each side.

If a new atherosclerotic plaque was found on CEUS, both standard carotid ultrasound and CEUS clips were reviewed in order to investigate why this plaque had been initially missed on standard carotid ultrasound alone. A systematic analysis of the standard carotid ultrasound clips of the region of the missed plaque was performed using the dual-display mode with simultaneous standard carotid ultrasound and CEUS. First, the image quality of the region of interest was scored based on a three-point scale as good-, moderate-, or poor-quality depending on artefacts or ultrasound shadowing. Secondly, echolucency was determined in the region of the missed plaque using the Gray-Weale score¹⁴ as follows: 1, predominantly echolucent plaque; 2, substantially echolucent lesions with small areas of echogenicity; 3, predominantly echogenic lesions with small areas of echolucency; and 4, uniformly echogenic lesions.

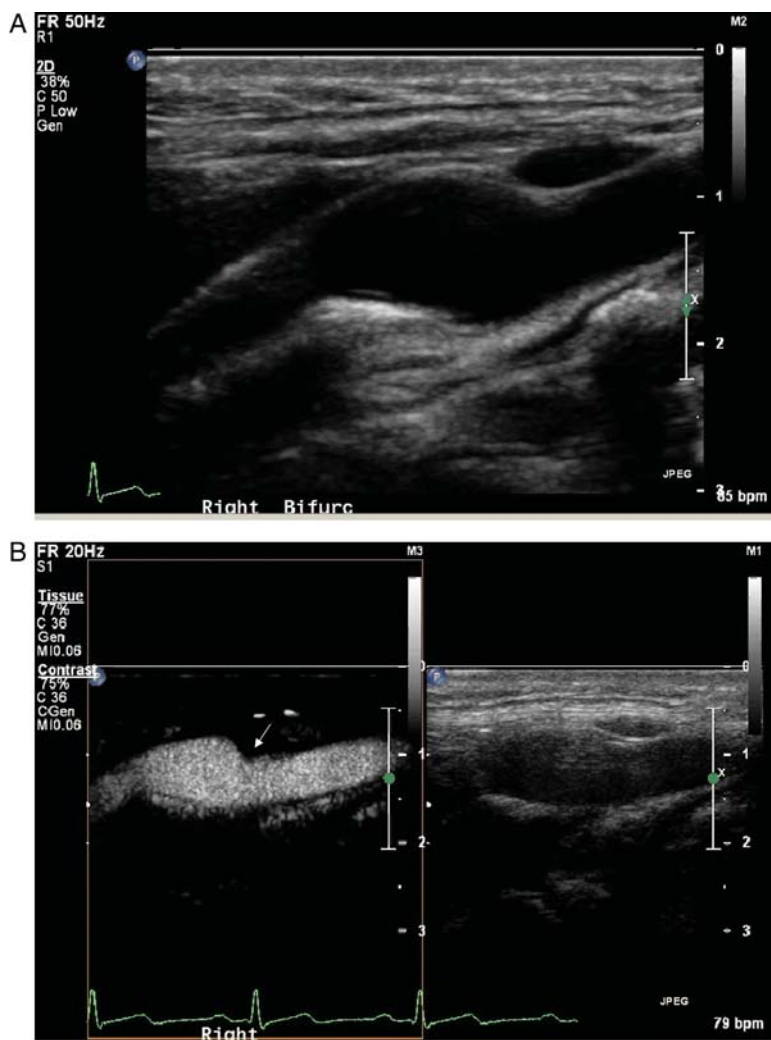

Figure 1 Assessment of subclinical atherosclerosis using standard carotid ultrasound and CEUS. (A) B-mode still frame of the right carotid artery. On the image, the distal CCA, bifurcation, and proximal ICA are visible (from right to left). No atherosclerotic plaques were detected. (B) Corresponding combined B-mode and CEUS still frame. An atherosclerotic plaque is visible on the contrast-enhanced still frame. It is located in the distal CCA and bifurcation (white arrow).

Statistical analyses

Statistical analysis was performed using SPSS PASW software for Windows (Version 17.0.2, SPSS Inc., Chicago, IL, USA). Continuous data were expressed as mean ± standard deviation, and categorical variables were expressed as counts and percentages and/or median value. McNemar’s test was used to compare between groups. Intra- and inter-observer reproducibility for the assessment of CIMT and atherosclerotic plaque was calculated using Pearson’s correlation and κ -statistics. A value of $P < 0.05$ was considered statistically significant.

Results

Patient characteristics

Clinical characteristics of the 100 patients (mean age 56 ± 9 years, 45% females) are summarized in Table 1. A total of 27 patients had one clinical risk factor for atherosclerosis, 34 patients had two

clinical risk factors, 33 patients had three clinical risk factors, and 6 patients had four clinical risk factors. The standard carotid ultrasound and CEUS examinations were performed without adverse reactions in all patients.

Analysis of carotid arteries

A total of 200 carotid arteries were evaluated. The mean CIMT was 0.69 ± 0.16 mm. The standard ultrasound examination, including colour Doppler, revealed atherosclerotic plaques in 129 carotid arteries (65%), and in the remaining 71 carotid arteries (36%), no atherosclerotic plaques were detected. There were no haemodynamically significant carotid stenoses detected. The addition of CEUS to the standard ultrasound protocol demonstrated atherosclerotic plaques in 155 carotid arteries (78%). In 26 carotid arteries (13%), standard ultrasound demonstrated no atherosclerosis, whereas CEUS demonstrated atherosclerotic

plaques (Figures 1 and 2). In another 26 carotid arteries (13%), atherosclerotic plaques were detected on standard carotid ultrasound, and additional atherosclerotic plaques were detected using CEUS. The incorporation of CEUS into the standard carotid ultrasound protocol resulted in a significantly improved detection of subclinical atherosclerotic plaques ($P < 0.001$).

The atherosclerotic plaques which were only detected with CEUS and had been missed using the standard carotid ultrasound examination including colour Doppler were predominantly hypoechoic, with a median Gray-Weale score of 1. A total of 39 plaque regions (70%) had Gray-Weale score 1; 13 plaque regions (23%) had Gray-Weale score 2; 4 plaque regions (7%) had Gray-Weale score 3; and 0 plaque region (0%) had Gray-Weale score 4. The image quality of standard carotid ultrasound in the regions with

plaques that were detected using CEUS but missed using standard carotid ultrasound only was good in 32 regions (57%), moderate in 17 regions (30%), and poor in 7 regions (13%).

Analysis of patients

A total of 21 patients (21%) had a CIMT value above their age-corrected threshold and were considered to have subclinical atherosclerosis. Standard carotid ultrasound demonstrated atherosclerotic plaques in a total of 77 patients (77%). All 21 patients with a CIMT value above their age-corrected threshold had atherosclerotic plaques on standard carotid ultrasound. Using standard carotid ultrasound, no atherosclerotic plaques were detected in the remaining 23 patients (23%). The addition of CEUS to the standard ultrasound protocol demonstrated atherosclerotic plaques in 88 patients (88%). In 11 patients (11%), standard carotid ultrasound demonstrated no atherosclerosis, but CEUS revealed atherosclerotic plaques. In 43 patients (43%), standard carotid ultrasound demonstrated atherosclerotic plaques and additional atherosclerotic plaques were detected using CEUS. The incorporation of CEUS into the standard carotid ultrasound protocol resulted in a significantly improved detection of patients with subclinical atherosclerosis ($P < 0.01$; Figure 3).

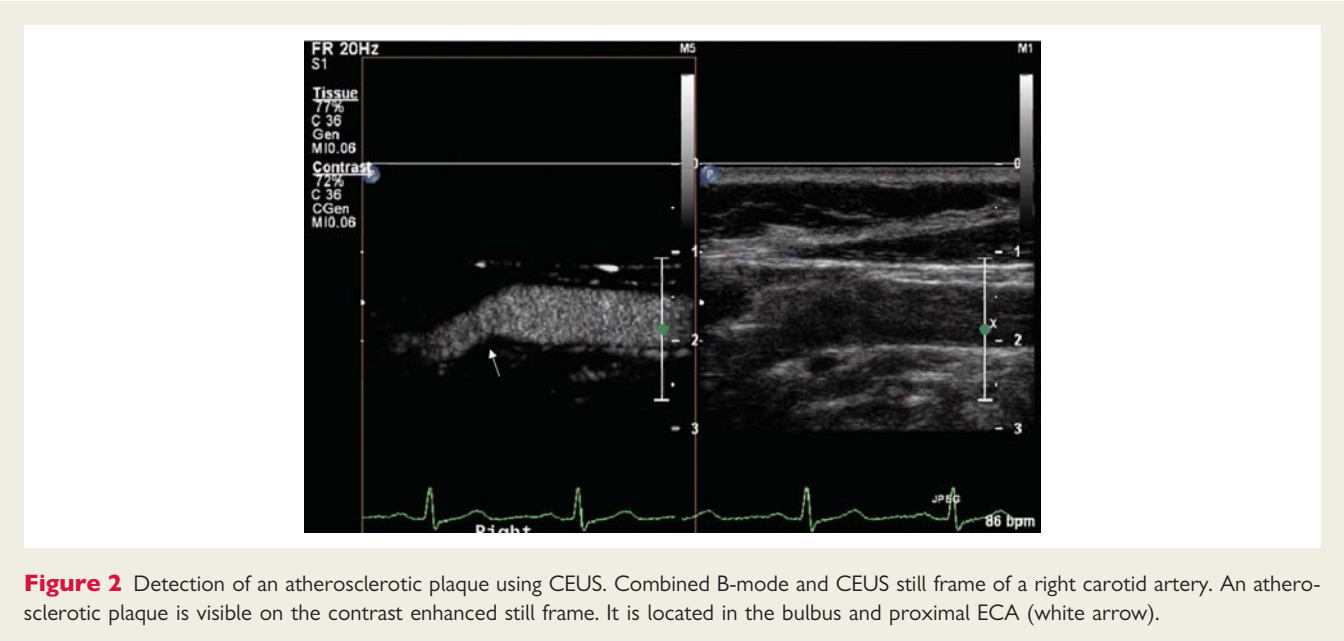
Reproducibility

Reproducibility of ultrasound-clip analysis was assessed using the complete ultrasound examinations of all 100 patients. The mean difference between inter-observer measurements of the CIMT was 0.02 ± 0.03 mm. The correlation coefficient for inter-observer measurements of the CIMT was good ($r = 0.97$). The κ -statistics for the inter-observer agreement of atherosclerotic plaque detection with standard carotid ultrasound was 0.68. For combined standard carotid ultrasound and CEUS, the κ -statistics for inter-observer agreement of atherosclerotic plaque detection was 0.65, which suggests a substantial agreement.

Table 1 Clinical characteristics of the study population (N = 100)

Characteristic	Data
Age (years)	56 ± 9
Female gender	45 (45)
Height (cm)	174 ± 10
Weight (kg)	83 ± 17
BMI (kg/m ²)	27 ± 5
Cardiovascular risk factors	
Diabetes	22 (22)
Dyslipidaemia	88 (88)
Familial history of CVD	51 (51)
Hypertension	33 (33)
Smoker (current)	24 (24)
Smoker (former)	23 (23)

BMI, body mass index; CVD, cardiovascular disease. Data are presented as the numbers of patients (percentages) or as mean ± standard deviation.



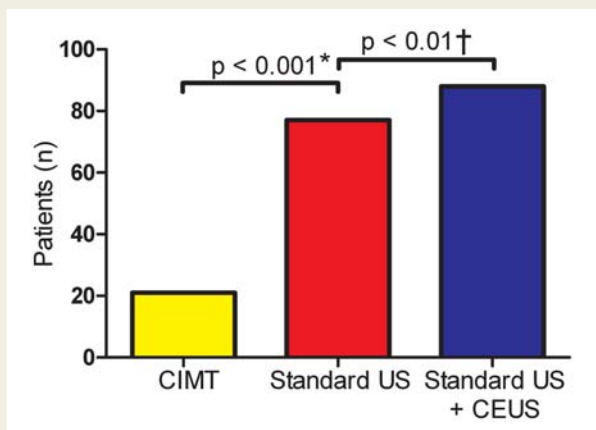


Figure 3 Identification of subclinical atherosclerosis by different imaging strategies. CMT, carotid intima-media thickness measurement; standard US, standard carotid ultrasound; CEUS, contrast-enhanced ultrasound. *Standard ultrasound identified significantly more patients with subclinical atherosclerosis when compared with CMT measurement. †When standard carotid ultrasound was combined with CEUS, significantly more patients with subclinical atherosclerosis were detected than with standard carotid ultrasound only.

Discussion

The main finding of the current study is that CEUS has incremental value for the detection of subclinical atherosclerosis. According to a previously suggested age-specific threshold formula for CMT,¹² 21% of the patients had subclinical atherosclerosis. Standard carotid ultrasound including colour Doppler images demonstrated atherosclerotic plaques in 77% of the patients. The addition of CEUS to the standard ultrasound protocol demonstrated atherosclerotic plaques in 88% of the study population. In 11% of the patients, atherosclerotic plaques were only detected by CEUS and not with standard ultrasound. These plaques were predominantly hypoechoic. The combination of standard carotid ultrasound and CEUS may thus be the preferred strategy for evaluation of subclinical atherosclerosis.

These results are in line with previous experimental studies. Sirlin *et al.*⁸ reported that CEUS provides more accurate delineation of the arterial lumen than standard ultrasound. In an *ex vivo* human carotid artery model and an *in vivo* rabbit aorta model, CEUS enabled an improved depiction of wall abnormalities, while this study was performed without contrast-specific imaging settings. Kono *et al.*⁷ demonstrated that phase-inversion harmonic imaging further increases the sensitivity of ultrasound to contrast agent, leading to an improved visualization of the vascular lumen and tissues. To the best of our knowledge, the current study is the first to demonstrate that CEUS has an additional value for the detection of subclinical atherosclerosis.

The atherosclerotic plaques that were only detected using CEUS and not with the standard carotid ultrasound examination were predominantly hypoechoic. A number of studies have demonstrated that hypoechoic plaques contain a large lipid pool,

are related with intraplaque haemorrhage, and an increased incidence of cardiovascular events.^{15–17} Large lipid pool and intraplaque haemorrhage are histopathological features of the vulnerable atherosclerotic plaque, which is at risk to rupture and may cause cardiovascular events.² The hypoechoic atherosclerotic plaques detected with CEUS may be of the vulnerable plaque type. A follow-up study is required to investigate whether the newly found hypoechoic atherosclerotic plaques are associated with an increased incidence of cardiovascular events.

The present study demonstrates that CEUS provides an incremental value for the detection of subclinical atherosclerosis, irrespective of the image quality of the standard carotid ultrasound images. The image quality of standard carotid ultrasound in the regions with plaques that were detected by CEUS but missed using standard ultrasound was good in 57% and impaired (moderate-or-poor image quality) in 43%.

The current findings may have implications for cardiovascular risk assessment. Carotid ultrasound has been extensively used for the non-invasive detection of subclinical atherosclerosis. Large prospective studies have demonstrated that an increased CMT is associated with clinical events, including myocardial infarction and stroke.^{18–20} CMT measurement is an excellent research tool and numerous clinical trials have studied the effect of medical therapy on CMT instead of hard cardiovascular endpoints. Still, an increased CMT is associated with but not necessarily synonymous with atherosclerosis. Moreover, individual risk prediction using CMT is challenging because well-established threshold values for CMT do not exist. Carotid plaque screening has therefore been suggested as a better surrogate outcome for coronary artery disease.²¹ Systematic examination of the extracranial carotid arteries, including screening for the presence of plaques, may increase the sensitivity of ultrasound for identifying subclinical atherosclerosis and improve cardiovascular risk stratification.^{5,22,23} A recent meta-analysis demonstrated that carotid ultrasound screening for the presence of plaques is a better predictor of hard cardiovascular events when compared with CMT measurement.⁵

A limitation of this study is that well-established threshold values for CMT do not exist. The formula used to calculate the threshold for abnormal CMT only adjusts for age.¹² Previous studies have demonstrated that multiple factors including gender and ethnicity may influence CMT. Therefore, in this study, CMT measurement may have over- or underestimated the presence of subclinical atherosclerosis. Furthermore, the predictive value of the newly detected atherosclerotic plaques for cardiovascular risk assessment has not been investigated yet. Follow-up studies are required to determine the additional predictive value of the absence or presence of subclinical atherosclerosis detected with CEUS.

In conclusion, CEUS has an additional value for the detection of subclinical atherosclerosis in the carotid arteries. The atherosclerotic plaques that were detected by CEUS but missed using standard carotid ultrasound including colour Doppler were predominantly hypoechoic. These results suggest that the combination of standard carotid ultrasound and CEUS may thus be the preferred strategy for the evaluation of subclinical atherosclerosis.

Acknowledgements

The authors thank Lourus van Haveren and Wim Vletter for their valuable contributions to the study.

Conflict of interest: none declared.

Funding

This research was supported by the Center for Translational Molecular Medicine and the Netherlands Heart Foundation (PARISK). There are no relationships with industry.

References

- Viles-Gonzalez JF, Fuster V, Badimon JJ. Atherothrombosis: a widespread disease with unpredictable and life-threatening consequences. *Eur Heart J* 2004;**25**: 1197–207.
- Schaar JA, Muller JE, Falk E, Virmani R, Fuster V, Serruys PW et al. Terminology for high-risk and vulnerable coronary artery plaques. Report of a meeting on the vulnerable plaque, June 17 and 18, 2003, Santorini, Greece. *Eur Heart J* 2004;**25**: 1077–82.
- O'Leary DH, Bots ML. Imaging of atherosclerosis: carotid intima-media thickness. *Eur Heart J* 2010;**31**:1682–9.
- de Groot E, Jukema JW, Montauban van Swijndregt AD, Zwinderman AH, Akerstaff RG, van der Steen AF et al. B-mode ultrasound assessment of pravastatin treatment effect on carotid and femoral artery walls and its correlations with coronary arteriographic findings: a report of the Regression Growth Evaluation Statin Study (REGRESS). *J Am Coll Cardiol* 1998;**31**:1561–7.
- Inaba Y, Chen JA, Bergmann SR. Carotid plaque, compared with carotid intima-media thickness, more accurately predicts coronary artery disease events: a meta-analysis. *Atherosclerosis* 2012;**220**:128–33.
- Ray A, Tamsma JT, Hovens MMC, op 't Roodt J, Huisman MV. Accuracy of carotid plaque detection and intima-media thickness measurement with ultrasonography in routine clinical practice. *Eur J Intern Med* 2010;**21**:35–9.
- Kono Y, Pinnell SP, Sirlin CB, Sparks SR, Georgy B, Wong W et al. Carotid arteries: contrast-enhanced US angiography—preliminary clinical experience. *Radiology* 2004;**230**:561–8.
- Sirlin CB, Lee YZ, Girard MS, Peterson TM, Steinbach GC, Baker KG et al. Contrast-enhanced B-mode US angiography in the assessment of experimental in vivo and in vitro atherosclerotic disease. *Acad Radiol* 2001;**8**:162–72.
- Stein JH, Korcarz CE, Hurst RT, Lonn E, Kendall CB, Mohler ER et al. Use of carotid ultrasound to identify subclinical vascular disease and evaluate cardiovascular disease risk: a consensus statement from the American Society of Echocardiography Carotid Intima-Media Thickness Task Force. Endorsed by the Society for Vascular Medicine. *J Am Soc Echocardiogr* 2008;**21**:93–111.
- Grant EG, Benson CB, Moneta GL, Alexandrov AV, Baker JD, Bluth EI et al. Carotid artery stenosis: gray-scale and Doppler US diagnosis—Society of Radiologists in Ultrasound Consensus Conference. *Radiology* 2003;**229**:340–6.
- Montauban van Swijndregt AD, The SH, Gussenhoven EJ, Lancée CT, Rijsterborgh H, de Groot E et al. An in vitro evaluation of the line pattern of the near and far walls of carotid arteries using B-mode ultrasound. *Ultrasound Med Biol* 1996;**22**:1007–15.
- Jäger KA, Staub D. Did you measure the intima-media thickness? *Ultraschall Med* 2009;**30**:434–7.
- Touboul P-J, Hennerici MG, Meairs S, Adams H, Amarenco P, Bornstein N et al. Mannheim carotid intima-media thickness consensus (2004–2006). An update on behalf of the Advisory Board of the 3rd and 4th Watching the Risk Symposium, 13th and 15th European Stroke Conferences, Mannheim, Germany, 2004, and Brussels, Belgium, 2006. *Cerebrovasc Dis* 2007;**23**:75–80.
- Gray-Weale AC, Graham JC, Burnett JR, Byrne K, Lusby RJ. Carotid artery atheroma: comparison of preoperative B-mode ultrasound appearance with carotid endarterectomy specimen pathology. *J Cardiovasc Surg* 1988;**29**:676–81.
- Grønholdt ML, Wiebe BM, Laursen H, Nielsen TG, Schroeder TV, Sillesen H. Lipid-rich carotid artery plaques appear echolucent on ultrasound B-mode images and may be associated with intraplaque haemorrhage. *Eur J Vasc Endovasc Surg* 1997;**14**:439–45.
- Polak JF, Shemanski L, O'Leary DH, Lefkowitz D, Price TR, Savage PJ et al. Hypoechoic plaque at US of the carotid artery: an independent risk factor for incident stroke in adults aged 65 years or older. Cardiovascular Health Study. *Radiology* 1998;**208**:649–54.
- Tegos TJ, Sabetai MM, Nicolaidis AN, Robless P, Kalodiki E, Elatrozy TS et al. Correlates of embolic events detected by means of transcranial Doppler in patients with carotid atheroma. *J Vasc Surg* 2001;**33**:131–8.
- Chambless LE, Heiss G, Folsom AR, Rosamond W, Szklo M, Sharrett AR et al. Association of coronary heart disease incidence with carotid arterial wall thickness and major risk factors: the Atherosclerosis Risk in Communities (ARIC) Study, 1987–1993. *Am J Epidemiol* 1997;**146**:483–94.
- Bots ML, Hoes AW, Koudstaal PJ, Hofman A, Grobbee DE. Common carotid intima-media thickness and risk of stroke and myocardial infarction: the Rotterdam Study. *Circulation* 1997;**96**:1432–7.
- O'Leary DH, Polak JF, Kronmal RA, Manolio TA, Burke GL, Wolfson SK. Carotid-artery intima and media thickness as a risk factor for myocardial infarction and stroke in older adults. Cardiovascular Health Study Collaborative Research Group. *N Engl J Med* 1999;**340**:14–22.
- Spence JD. Ultrasound measurement of carotid plaque as a surrogate outcome for coronary artery disease. *Am J Cardiol* 2002;**89**:10–5B.
- Salonen JT, Salonen R. Ultrasonographically assessed carotid morphology and the risk of coronary heart disease. *Arterioscler Thromb* 1991;**11**:1245–9.
- Novo S, Visconti CL, Amoroso GR, Corrado E, Fazio G, Muratori I et al. Asymptomatic carotid lesions add to cardiovascular risk prediction. *Eur J Cardiovasc Prev Rehabil* 2010;**17**:514–8.