P1245

Huge left atrial myxoma masks mitral regurgitation

Toki M.[1]; Hayashida A.[2]; Sakaguchi T.[3]; Aritaka S.[1]; Yoshida K.[2]

[1]The Sakakibara Heart Institute of Okayama, Department of Clinical Laboratory, Okayama, Japan
[2]The Sakakibara Heart Institute of Okayama, Department Of Cardiology, Okayama, Japan
[3]The Sakakibara Heart Institute of Okayama, Department of Cardiovascular Surgery, Okayama, Japan

A 61-year-old gentleman, he had shortness of breath while few weeks and getting worse, was presented to our hospital. His oxygen saturation was 94 %(O2 5L) and no crackles or rales were heard. His electrocardiogram was sinus tachycardia, and chest X-ray showed cardiomegaly and BNP level was elevated (260.3pg/mL). Transthoracic echocardiography (TTE) revealed huge mass(57 × 39mm) occupying left atrium (LA), the mass was flexible in cardiac cycle and prolapsing from LA to left ventricle, it seems like cardiac myxoma. We suspected mitral stenosis (MS) caused by the mass (peak trans mitral flow velocity 3.1m/s), mitral regurgitation(MR) was not significant, and moderate tricuspid regurgitation with pulmonary hypertension (peak systolic pressure 61 mmHg). We performed transesophageal echocardiography(TEE) and CT angiography revealed the mass at fossa ovalis, we decided surgery of removing the mass considering the risk of mitral annulus obstruction and embolism. Intraoperative findings, after taken off the mass, TEE showed moderate to severe MR not detected preoperative TEE. Additionally, it revealed the mitral annulus enlargement(42 × 38mm by 2D TEE) and may gradually induced by prolapsing the mass. Finally, surgery for mitral valve was performed and postoperative TTE showed no MR. The mass was diagnosed cardiac myxoma by pathology.

MS is relatively common in patients with prolapsing LA myxoma , and it improves after removing the mass. In this case, mitral valve was no degeneration but enlarged mitral annulus and significantly MR had revealed after removing the mass. Keep in mind that there is possibility to underestimate of MR associated with LA myxoma. To take care of mitral valve complex sufficiently in such case, and to detect these findings at preoperative echocardiography, then more useful assessment for surgery.

Abstract P1245 Figure. Huge Left Atrial Myxoma Masks MR

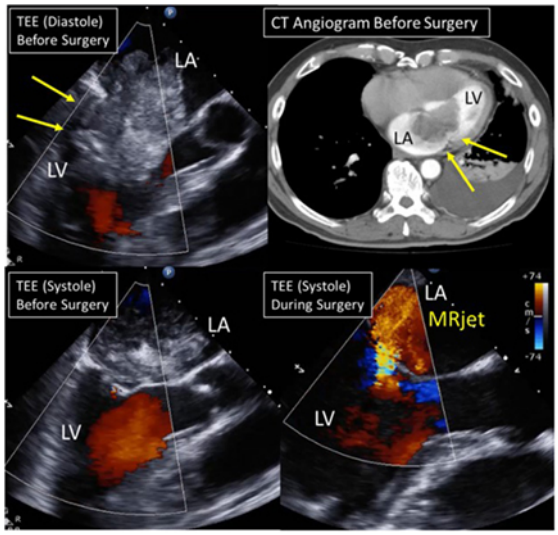

Downloaded from https://academic.oup.com/ehjcimaging/article/21/Supplement_1/jez319.699/5708297 by guest on 17 April 2024