

# A pilot with a helicopter in the left atrium: a case report of an embolized Watchman device

Jonathan Halim \*, Rene Tavernier , Luc Missault, and Philippe Debonnaire 

Department of Cardiology, Sint-Jan Hospital Bruges, Ruddershove 10, 8000 Bruges, Belgium

Received 10 January 2020; first decision 23 February 2020; accepted 19 May 2020; online publish-ahead-of-print 9 July 2020

## Background

Embolization of a Watchman device in patients undergoing percutaneous left atrial appendage (LAA) closure is a rare complication. Retrieval of the device can be achieved percutaneously with a snaring technique or a biptome.

## Case summary

We present an illustrative case of Watchman closure device embolization during an LAA closure attempt in a 77-year-old man. The complication was caused by anatomical restraints of the LAA, in particular limited depth resulting in poor stability of the closure device after implantation. By the use of a double snaring technique, however, we managed to retrieve the device percutaneously. By applying such strategy, a more invasive surgical approach can be prevented.

## Discussion

Prompt response is needed when embolization of a Watchman device occurs. A snaring technique can be used in most cases to attempt device retrieval. A double snaring technique is in this case associated with higher retrieval success than a single snaring technique.

## Keywords

Left atrial appendage closure • Watchman device • Embolisation • Snare technique • Case report

## Learning points

- Detailed assessment of the anatomy of the left atrial appendage (LAA) is essential to minimize the risk of device embolization.
- A double snaring technique can be efficacious in retrieving an embolized Watchman device and is associated with a higher success rate than a single snaring technique.
- The indication for percutaneous LAA closure should be looked at in a comprehensive manner.

## Introduction

Percutaneous left atrial appendage (LAA) closure by a Watchman device has been shown to be a safe, effective, and durable alternative to oral anticoagulation in patients with paroxysmal non-valvular atrial fibrillation at moderate cardioembolic risk.<sup>1</sup> Device thrombosis,

pericardial tamponade, and embolization of the closure device comprise the vast majority of complications, if any.<sup>2,3</sup> Device embolization mandates prompt response in order to retrieve the closure device surgically or percutaneously.<sup>3</sup> We present an illustrative case of LAA closure device embolization into the left atrium, successfully treated by percutaneous retrieval using a double snaring technique.

\* Corresponding author. Tel: +32 50 45 26 82, Email: [jonathan.halim@azsintjan.be](mailto:jonathan.halim@azsintjan.be)

Handling Editor: Harun Kundi

Peer-reviewers: Bogdan Enache and George K. Andrikopoulos

Compliance Editor: Christian Fielder Camm

Supplementary Material Editor: Peysh A. Patel

© The Author(s) 2020. Published by Oxford University Press on behalf of the European Society of Cardiology.

This is an Open Access article distributed under the terms of the Creative Commons Attribution Non-Commercial License (<http://creativecommons.org/licenses/by-nc/4.0/>), which permits non-commercial re-use, distribution, and reproduction in any medium, provided the original work is properly cited. For commercial re-use, please contact [journals.permissions@oup.com](mailto:journals.permissions@oup.com)

## Timeline

Time	Event
0 min	Start of the procedure
45 min	Embolization of the device
48 min	Initiation of a single snaring technique
100 min	Initiation of a double snaring technique
125 min	Retrieval of the device
24 h	Patient discharge

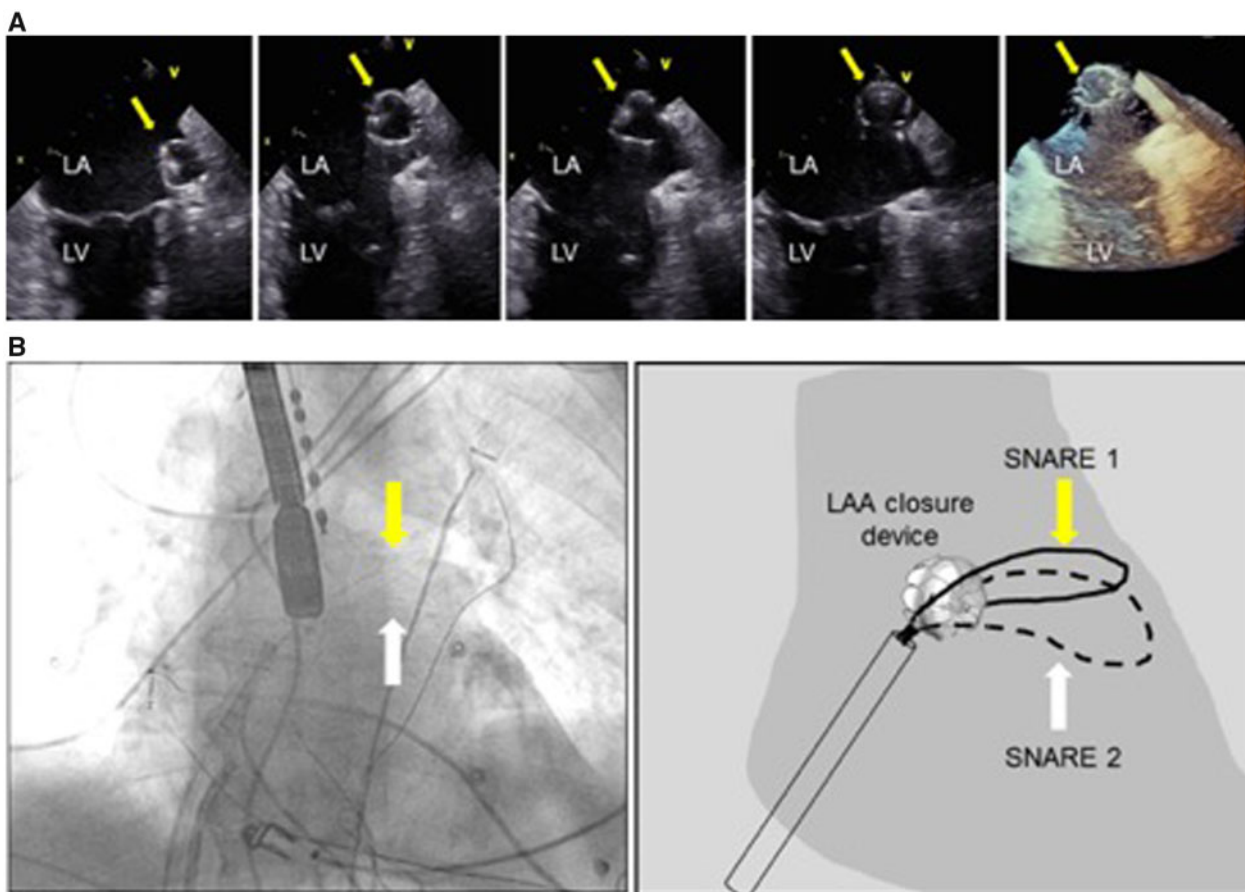
## Case presentation

Until recently, Belgian helicopter pilots lost their license to fly if they were treated with oral anticoagulation. In order to continue his

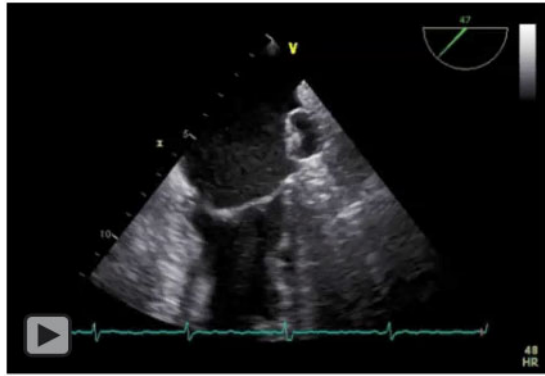
hobby, a 77-year-old man with diabetes, arterial hypertension, and paroxysmal atrial fibrillation, treated with rivaroxaban 20 mg and amiodarone 200 mg daily, requested percutaneous LAA closure. He consented to this off-label indication.

During physical examination, cardiac murmurs were absent and there were no clinical signs of heart failure present. Echocardiogram showed a preserved left ventricular ejection fraction of 60% and did not reveal any structural abnormalities, apart from a dilated left atrium. The CHA<sub>2</sub>DS<sub>2</sub>-VASc score and HAS-BLED score were 4 and 1, respectively.

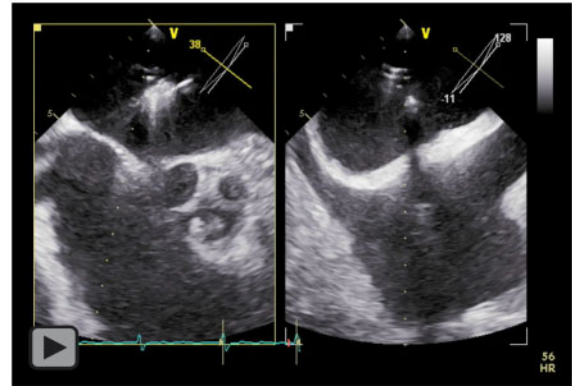
After an uncomplicated pulmonary vein isolation, a percutaneous LAA closure was attempted during the same session. The patient was in sinus rhythm during the entire procedure. A depth of the LAA of 21 mm and a landing zone width of 18 mm were measured on transoesophageal echocardiography. The smallest Watchman closure device of 21 mm was selected because of the limited depth. Although the device protruded slightly outside of the LAA, a tug test and compression test were reassuring and the device was released. While monitoring the device position with transoesophageal



**Figure 1** (A) Transoesophageal view: left atrial appendage closure device (arrow) positioned in the left atrial appendage with outside protrusion into the left atrium and chronologic views of acute embolization, including three-dimensional view in the last panel. (B) Attempt to capture the closure device with a double snaring technique percutaneously. (Left panel) Fluoroscopic view and (right panel) schematic view. LA, left atrium; LAA, left atrial appendage; LV, left ventricle.



**Video 1** Transoesophageal echocardiogram: left atrial appendage closure device embolization.



**Video 2** Fluoroscopy: attempt to recapture the left atrial appendage closure device with a double snaring technique.

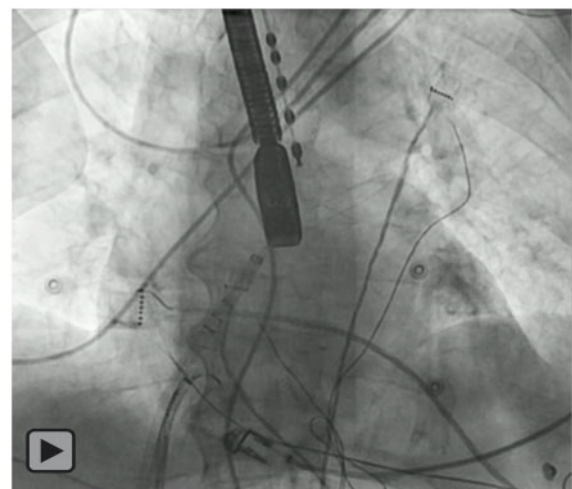
echocardiography, the Watchman device suddenly turned sideways, embolized and started bouncing around in the left atrium (*Figure 1A*, *Video 1*).

The circular mapping catheter used to assess pulmonary vein isolation was positioned at the orifice of the mitral valve to prevent distal embolization of the device. Then we made a self-made snare from a long coronary guidewire, by which we connected the two ends of the wire to create a big 'loop' in the mid part of the wire. The reason we used a self-made snare instead of an available snaring device was that due to the size of the device we believed we needed a bigger loop to recapture the device. Hereafter, we successfully lassoed the device but we were unable to retract it into a steerable 14-Fr transseptal sheath because the LAA closure device refused to collapse. In a second step, two long coronary guidewires were used to create a 'double snare basket' (*Figure 1B*, *Video 2*). After recapturing the device again with one of the snares, we were finally able to collapse it with the second snare and retract it into the 14-Fr transseptal sheath (*Video 3*). Device and transseptal sheath could be redrawn without further complications. At 1-month follow-up, the patient was asymptomatic and he was still in sinus rhythm.

## Discussion

Randomized controlled trials have proven non-inferiority of percutaneous LAA closure vs. anticoagulant treatment in patients at moderate stroke risk.<sup>4,5</sup> Therefore, LAA closure may be considered in patients with atrial fibrillation and contra-indications for long-term anticoagulation treatment.<sup>6</sup> Despite the fact that the patient tolerated oral anticoagulation, he, however, refused further intake in order to maintain his helicopter flight license. Being at considerable stroke risk based on his CHA<sub>2</sub>DS<sub>2</sub>-VASc score of 4, he consented to the off-label indication for percutaneous LAA closure.

Embolization of a percutaneous LAA closure device is a rare complication, occurring during the periprocedural period in the vast majority of cases. Late embolization is a much rarer phenomenon.<sup>3</sup> Besides embolization into the left atrium, migration into the left ventricle and aorta has been described as well.<sup>7</sup> Whereas percutaneous



**Video 3** Transoesophageal echocardiogram: left atrial appendage closure device recapture.

retrieval is the most feasible option when embolization to the left atrium and aorta occurs, embolization to the left ventricle is a more serious complication, usually requiring surgical intervention.<sup>8,9</sup>

Confirming adequate device Position, Anchor, Seal and Size compression (PASS test) before release is essential, in order to prevent the device from embolization. In this case, embolization was due to the limited depth of the LAA, preventing a stable landing zone for the closure device inside the LAA after deployment.

When percutaneous retrieval is attempted, a snaring technique is most frequently applied. Previous studies have shown the effectiveness of the double snaring technique when retrieval of embolized devices is needed.<sup>7,10</sup> Compared to a single snaring technique, a double snaring technique is associated with shorter retrieval time and higher success rate. Due to the size of the device snaring with two wires can lead to collapse of the device. Consequently, this can

facilitate easier retrieval in the sheath. An alternative is to use a biopptome to grasp the device and pull it back into the delivery sheath.<sup>11</sup>

## Conclusion

Prompt response to LAA closure device embolization is key: a double snaring technique may offer a percutaneous solution, avoiding unnecessary vascular or cardiac rescue surgery.

## Lead author biography



Dr Jonathan Halim graduated from the VU University in Amsterdam. After this, he completed his cardiology residency program in the OLVG hospital in Amsterdam. He is now doing a fellowship Interventional Cardiology in the AZ Sint Jan hospital in Bruges, Belgium.

## Supplementary material

Supplementary material is available at *European Heart Journal - Case Reports* online.

**Slide sets:** A fully edited slide set detailing this case and suitable for local presentation is available online as [Supplementary data](#).

**Consent:** The author/s confirm that written consent for submission and publication of this case report including image(s) and

associated text has been obtained from the patient in line with COPE guidance.

**Conflict of interest:** none declared.

## References

- Reddy VY, Doshi SK, Kar S, Gibson DN, Price MJ, Huber K et al. 5-year outcomes after left atrial appendage closure: from the PREVAIL and PROTECT AF trials. *J Am Coll Cardiol* 2017;**70**:2964–2975.
- Reddy VY, Holmes D, Doshi SK, Neuzil P, Kar S. Safety of percutaneous left atrial appendage closure: results from the Watchman Left Atrial Appendage System for Embolic Protection in Patients with AF (PROTECT AF) clinical trial and the Continued Access Registry. *Circulation* 2011;**123**: 417–424.
- Aminian A, Lalmand J, Tzikas A, Budts W, Benit E, Kefer J. Embolization of left atrial appendage closure devices: a systematic review of cases reported with the watchman device and the amplatzer cardiac plug. *Catheter Cardiovasc Interv* 2015; **86**:128–135.
- Holmes DR, Jr, Kar S, Price MJ, Whisenant B, Sievert H, Doshi SK et al. Prospective randomized evaluation of the Watchman Left Atrial Appendage Closure device in patients with atrial fibrillation versus long-term warfarin therapy: the PREVAIL trial. *J Am Coll Cardiol* 2014;**64**:1–12.
- Holmes DR, Reddy VY, Turi ZG, Doshi SK, Sievert H, Buchbinder M et al. Percutaneous closure of the left atrial appendage versus warfarin therapy for prevention of stroke in patients with atrial fibrillation: a randomised non-inferiority trial. *Lancet* 2009;**374**:534–542.
- Kirchhof P, Benussi S, Kotecha D, Ahlsson A, Atar D, Casadei B et al; ESC Scientific Document Group. 2016 ESC Guidelines for the management of atrial fibrillation developed in collaboration with EACTS. *Eur Heart J* 2016;**37**: 2893–2962.
- Alkhouli M, Aljohani S, Kucera R, Moiduddin N, Hull R. A double snare technique for safe retrieval of embolized left atrial appendage occluders. *JACC Cardiovasc Interv* 2017;**10**:e55–e56.
- Gupta P, Szczeklik M, Selvaraj A, Lall K. Emergency surgical retrieval of a migrated left atrial appendage occlusion device. *J Card Surg* 2013;**28**: 26–28.
- Aminian A, Chouchane I, Compagnie M, Decubber M, Lalmand J. Delayed and fatal embolization of a left atrial appendage closure device. *Circ Cardiovasc Interv* 2014;**7**:628–630.
- Ha K, Choi J, Jung S, Kim J, Byun K, Akagi T et al. A novel double snare technique to retrieve embolized septal and left atrial appendage occluders. *J Interv Cardiol* 2018;**31**:685–692.
- Li H, Wu X, Xiao F, Zhou X, Chen Y, Huang WJ. Successful percutaneous retrieval of a 33-mm Watchman left atrial appendage occlusion device from the left atrium. *JACC Cardiovasc Interv* 2018;**11**:e65–e67.