

Cite this article as: De Luca A, Vignaroli W, Bianchini R, Melina G. Severe mitral valve stenosis due to leaflet fusion requiring surgery following MitraClip procedure. Eur J Cardiothorac Surg 2022;61:1449.

Severe mitral valve stenosis due to leaflet fusion requiring surgery following MitraClip procedure

Angelo De Luca , Walter Vignaroli , Roberto Bianchini and Giovanni Melina

Department of Clinical and Molecular Medicine, Cardiac Surgery Unit, Sapienza University of Rome, Sant'Andrea Hospital, Rome, Italy

* Corresponding author. Cardiac Surgery Unit, Sant'Andrea Hospital, Via di Grottarossa 1035-1039, Rome 00189, Italy. Tel: +39-06-3377-5729; fax: +39-06-3377-6317; e-mail: angelo.deluca@uniroma1.it (A. De Luca).

Received 1 July 2021; accepted 12 August 2021

Keywords: Mitral valve replacement • MitraClip failure • Mitral stenosis

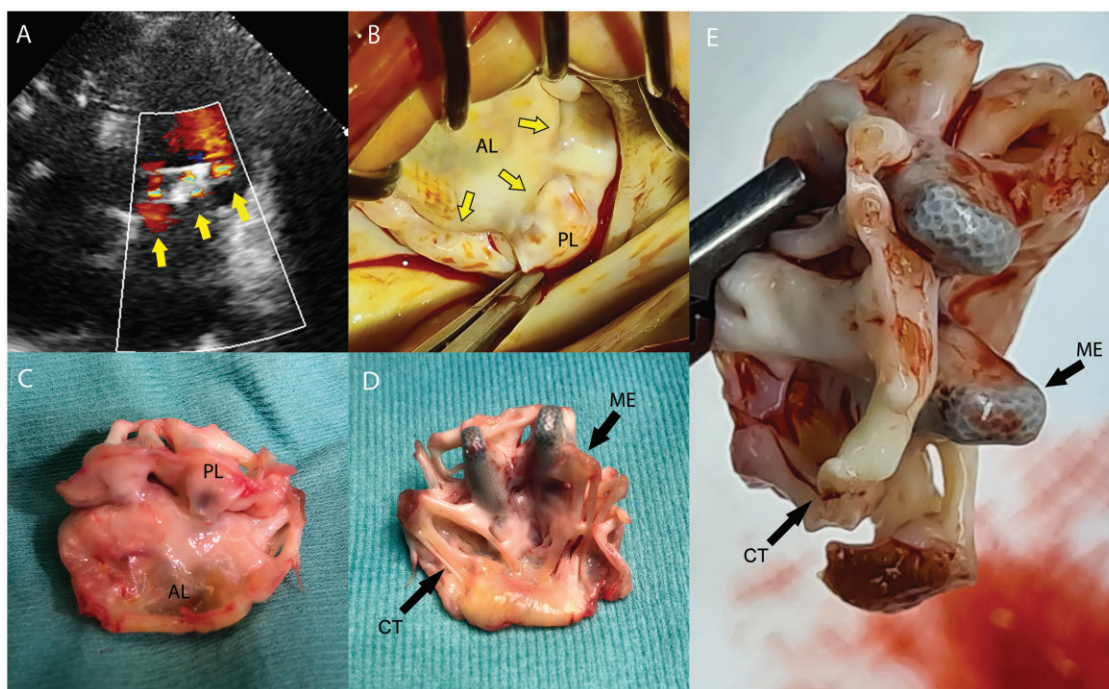


Figure 1: Preoperative echocardiographic 'triple-orifice' mitral valve (A) and intraoperative view from a left atrial approach (B). Surgical sample showing fusion of mitral leaflets (C) with chordae tendineae and MitraClip endothelialization (D and E). AL: anterior leaflet; CT: chordae tendineae; ME: MitraClip endothelialization; PL: posterior leaflet.

Reviewer information

European Journal of Cardio-Thoracic Surgery thanks Mizuki Miura and the other, anonymous reviewer(s) for their contribution to the peer review process of this article.