

Tetralogy of Fallot: what operation, at which age[☆]

Marco Pozzi^{*}, Dipesh B. Trivedi, Denise Kitchiner, Robert A. Arnold

Cardiac Unit, Royal Liverpool Children's Hospital, Alder Hey, Eaton Road, Liverpool L12 2AP, Liverpool, UK

Received 6 September 1999; received in revised form 28 January 2000; accepted 21 February 2000

Abstract

Background: The optimal management of tetralogy of Fallot is still under debate, particularly with respect to surgical approach and the age of operation. In recent times a transatrial-transpulmonary approach and primary repair in younger patients is favoured. The purpose of the present study was to analyze the result of our current surgical management by assessing the perioperative and intermediate term follow up in order to define the optimal strategy and timing of operation for our institution. **Methods:** One hundred and thirty two patients with tetralogy of Fallot who underwent definitive repair between May 1993 and December 1998 were analyzed by reviewing their medical records and follow-up. Median age was 15.5 (2.3–68.6) months and median weight was 8.8 (5–16) kg. Ten (7.57%) patients were under 6 months, 38 (28.78%) were between 6 and 12 months, 36 (27.27%) were between 12 and 18 months, 23 (17.42%) were between 18 and 24 months and 25 (18.93%) were more than 24 months age. During the study period there was a move to earlier surgery and differing methods of repair depending on the anatomy observed. Follow up was conducted by the referring cardiologist. Median follow up was 35.48 (8.07–74.93) months. **Results:** Forty-two (31.8%) patients required a palliative procedure before total correction due to unfavourable anatomy. Subpulmonary infundibular obstruction with a fibrous component increased significantly with age ($P < 0.05$). Operations were entirely transatrial in 14 (10.6%), transatrial and transpulmonary in 69 (52.2%), transatrial and transventricularly in 42 (31.8%) and a homograft conduit was used in seven (5.3%) patients. Younger patients had narrower pulmonary valves and required a transannular patch more frequently. All patients were in sinus rhythm, 28 (21.1%) showing right bundle branch block. Median hospital stay was 8 (5–54) days. No patient required reintervention during follow up and there was no early or late mortality. **Conclusion:** Correction of tetralogy of Fallot at younger age does not increase morbidity or mortality and has potential advantages. A surgical technique adapted to the anatomy of the right ventricular outflow tract, achieves the best results. © 2000 Elsevier Science B.V. All rights reserved.

Keywords: Tetralogy of Fallot; Young age; Surgical approach; Anatomical

1. Introduction

The medical and surgical management of tetralogy of Fallot (TOF) has continued to evolve and many thousands of patients have excellent long-term survival following correction. However, the optimal management is still under debate, particularly with respect to the surgical approach and the age of operation. Documentation of right ventricular dysfunction [1,2], pulmonary insufficiency and ventricular arrhythmias [3] after transventricular repair, has led many centres to adopt to transatrial/transpulmonary approach and excellent results have been demonstrated [4–8].

There has also been a trend from two stage to primary

repair in younger patients including neonates [9–12]. This move to earlier surgery was justified as the operative risk had fallen significantly. Studies of correction in infants have also confirmed the low morbidity and mortality in this age group [9–12]. Many centres, however, continue to favour a staged approach for patients requiring intervention in the neonatal period or infancy [13,14].

We have developed a policy of detailed investigation including cardiac catheterization at the time of presentation so that the management is planned before the development of significant cyanosis or cyanotic spells. Patients with favourable morphology proceed to early primary correction irrespective of the age but those with poorly developed pulmonary arteries or coronary anomalies undergo a staged approach. The purpose of the present study was to analyze the results of our current surgical management by assessing the peri-operative and intermediate period of follow up, in order to define the optimal strategy and timing of operation.

[☆] Presented at the 13th Annual meeting of the European Association for Cardio-thoracic Surgery, Glasgow, Scotland, UK, September 5–8, 1999.

^{*} Corresponding author. Tel.: +44-151-252-5635; fax: +44-151-252-5643.

E-mail address: mpozzi@liverpedcard.u-net.com (M. Pozzi).

Table 1
Nature and level of right ventricular outflow tract obstruction^a

RVOTO	<6 months	6–12 months	12–18 months	18–24 months	>24 months	Total
Infundibular	10 (100)	38 (100)	36 (100)	23 (100)	25 (100)	132 (100)
PV annulus	9 (90)	31 (81.5)	25 (69.4)	15 (65.2)	14 (56)	94 (71.2)
Pulmonary valve	9 (90)	31 (81.5)	25 (69.4)	21 (91.3)	21 (84)	107 (81.1)
MPA	7 (70)	26 (68.4)	30 (83.3)	21 (91.3)	20 (80)	104 (78.7)
LPA	1 (10)	17 (44.7)	13 (36.1)	8 (34.7)	10 (40)	49 (37.1)
RPA	1 (10)	4 (10.5)	6 (16.6)	3 (13.04)	1 (4)	15 (11.3)
Peripheral PA	2 (20)	3 (7.8)	5 (13.8)	2 (8.6)	3 (12)	15 (11.3)

^a Values in parentheses are percentage of patients in that group. RVOTO, right ventricular outflow tract obstruction; PV annulus, pulmonary valve annulus; MPA, main pulmonary artery; LPA, left pulmonary artery; RPA, right pulmonary artery; peripheral PA, peripheral pulmonary artery.

2. Patients and methods

From May 1993 to December 1998, 132 cases of TOF who underwent definitive repair by one surgeon (M.P.) were retrospectively assessed. The medical records were reviewed to obtain information on the pre and postoperative condition.

The inter-atrial septum was intact in 80 (60.6%), patent foramen ovale was present in 37 (28.03%) and atrial septal defect in 15 (11.3%) of patients. Seventy-eight (59.09%) patients had less than 50% aortic override and 54 (40.9%) patients had more than 50% aortic override. Four patients with TOF and an atrioventricular septal defect, and one

patient with absent pulmonary valve syndrome were included. Patients with pulmonary atresia and a ventricular septal defect were excluded. The nature and level of right ventricular outflow tract obstruction are shown in Table 1. Subpulmonary infundibular stenosis was present in all the patients. The fibrous component of the infundibular obstruction increased significantly with age ($P < 0.04$) (Fig. 1).

The median age at the time of repair was 15.3 (2.3–68.6) months. The median weight was 8.81 (5–16) kg and median body surface area was 0.42 (0.26–0.98) m². Ten patients (7.5%) were less than 6 months, 38 (28.78%) were between 6 and 12 months, 36 (27.27%) were between 12 and 18 months, 23 (17.42%) were between 18 and 24 months and

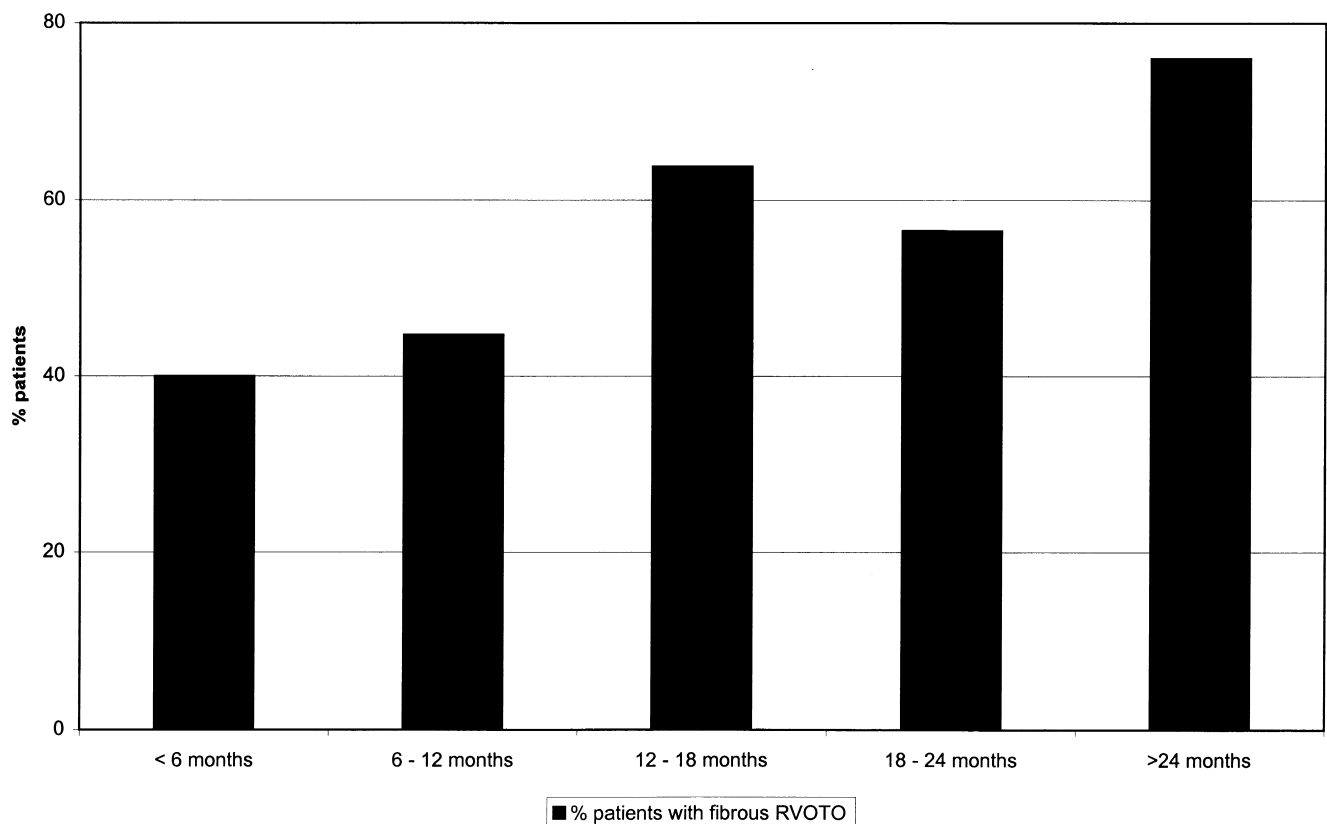


Fig. 1. Incidence of fibrous obstruction in RVOT. Obstruction by age of patient.

25 (18.93%) were more than 24 months of age. The age distribution by year of operation is shown in Fig. 2.

Forty-two patients (31.8%) required a palliative procedure before total correction. Twenty-two patients (16.66%) had right or left modified Blalock–Taussig shunt, 20 patients (15.1%) had balloon dilatation of right ventricular outflow tract and three patients (2.2%) had both shunt and balloon dilatation. Unfavourable anatomy which consisted of either major coronary arteries crossing right ventricular outflow tract, diminutive pulmonary arteries or prematurity with worsening cyanosis were our indications for palliative intervention before total repair. The median age at the time of balloon dilatation of right ventricular outflow tract or pulmonary valve was 6.83 months and complete repair was performed after a median period of 12.13 months. The median age at insertion of systemic to pulmonary artery shunt (right or left modified Blalock–Taussig shunt) was 2.93 months and complete repair was performed after a median period of 20.23 months.

The operative technique was uniform during the study period. Access was obtained through a right atriotomy and the tricuspid valve. The parietal band was excised and dissection was carried upwards as far as possible. Obstructing muscle bands were divided or excised and fibrous tissue was excised. The main pulmonary artery was incised longitudinally and valvotomy was performed through the existing commissures. Further division and excision of muscle

bands was undertaken through the pulmonary valve before assessing the adequacy of the right ventricular outflow tract with Hegar's dilators introduced through the tricuspid valve and the pulmonary valve. Residual narrowing could either be due to a restrictive pulmonary valve or hypoplasia of the right ventricular outflow tract. If the pulmonary valve was stenotic but the infundibular obstruction had been successfully relieved, we incised the annulus without ventriculotomy or by limiting the ventriculotomy to 3–5 mm, just enough to place a patch to effectively enlarge the annulus. In cases where the outflow tract was still obstructed (due to hypoplasia rather than hypertrophy of the outflow tract), we felt that a right ventriculotomy was necessary and should be extended at least a few millimetres beyond the length of the infundibular septum. The left and right pulmonary arteries were also measured and if necessary the incision in the main pulmonary artery was extended into either pulmonary artery. The pulmonary artery and right ventricular outflow tract were reconstructed using untreated autologous pericardium. In the presence of severely hypoplastic peripheral pulmonary arteries, a monocusp homograft patch was used. Fifteen patients (11.3%) had right ventricular outflow tract reconstruction using monocusp homograft patch.

The surgical approach was transatrial in 14 (10.6%) patients, transatrial-transpulmonary in 69 (52.2%) patients and transatrial-transventricular in 42 (31.8%) patients. In seven (5.3%) patients, one with absent pulmonary valve

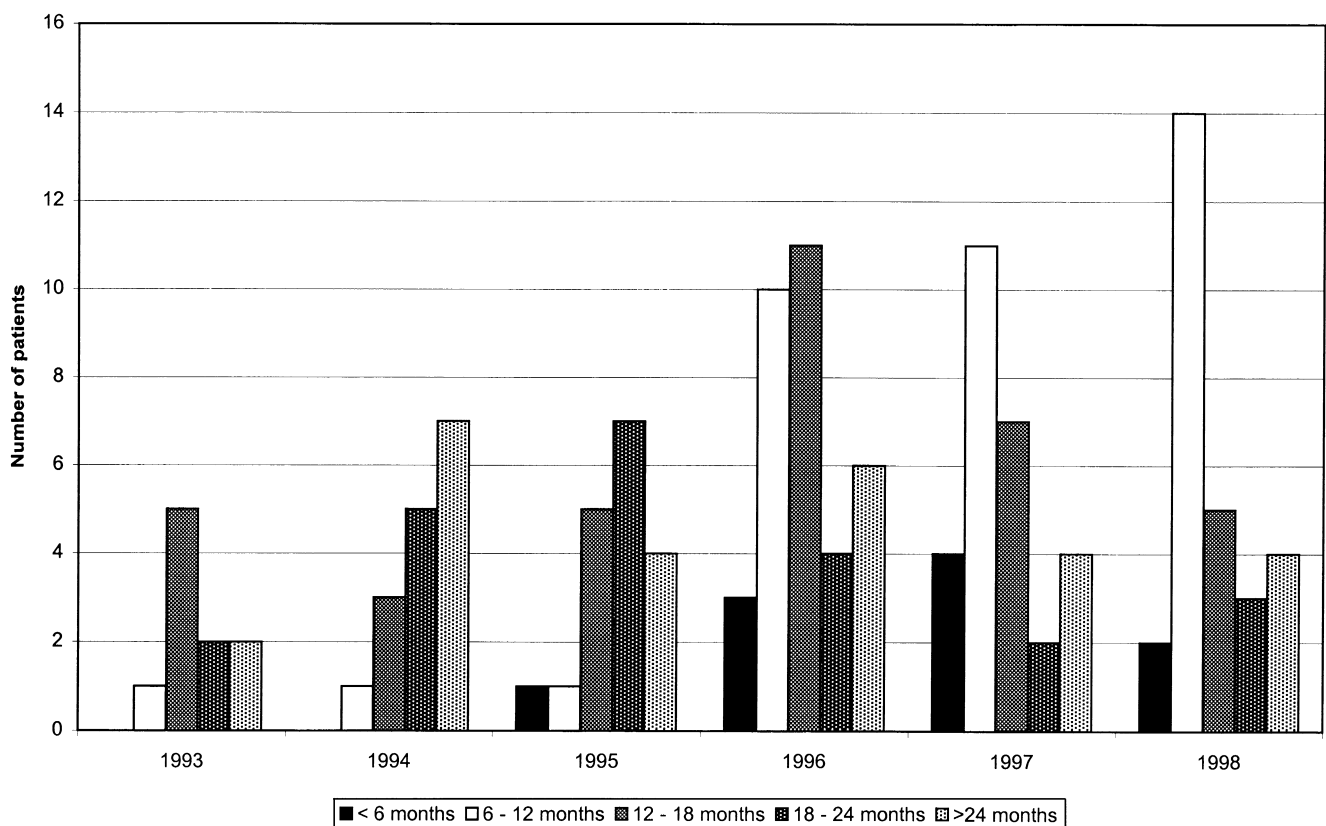


Fig. 2. Age distribution of patients by year of operation.

Table 2
Surgical approach^a

Approach	<6 months	6–12 months	12–18 months	18–24 months	>24 months	Total
TA	0 (0.0)	2 (5.26)	3 (8.33)	5 (21.7)	4 (16)	14 (10.6)
TATP	5 (50)	25 (65.7)	21 (58.3)	8 (34.7)	10 (25)	69 (52.2)
TATV	5 (50)	10 (26.3)	12 (33.3)	9 (39.1)	6 (24)	42 (31.8)
Homograft	0 (0)	1 (2.6)	0 (0)	1 (4.3)	5 (20)	7 (5.3)

^a Values in parentheses are the percentage of patients in that group. TA, transatrial; TATP, transatrial transpulmonary; TATV, transatrial transventricular.

syndrome and six with abnormal coronary arteries crossing the right ventricular outflow, a homograft valve conduit was inserted (Table 2). The ventricular septal defect was closed transatrially. Other additional procedures such as closure of the arterial duct, repair of atrioventricular canal defect were carried out as indicated.

Follow-up by the referring cardiologist included clinical evaluation, electrocardiogram and echocardiography. Median follow up was 35.48 (8.07–74.93) months and was complete to 100%. Data collection was by case-note review.

3. Results

Younger patients had narrower pulmonary annuli and required transannular patch more frequently compared to older patients (Fig. 3). This was not statistically significant

($P = 0.08$). This may be due to uneven number of patients in different age groups. However higher incidence of transannular patch in younger patients did not require larger right ventriculotomy to relieve the obstruction. One hundred and twenty (90.9%) patients required main pulmonary artery reconstruction. Fifty-eight (43.9%) and 16 (12.1%) patients required left pulmonary artery and right pulmonary artery reconstruction, respectively, with no difference between various age groups.

During this study period there was no early or late mortality. Median hospital stay was 8 (5–54) days. Postoperative course was uneventful in 102 (77.27%) of patients. Minor complications in the form of pleural effusion, fever, respiratory infection were present in 20 (15.15%). Amongst the major complications, eight (6.06%) patients required prolonged ventilation for more than 5 days, five (3.7%) patients had ventricular dysfunction which required prolonged inotropic support and later digoxin. Four

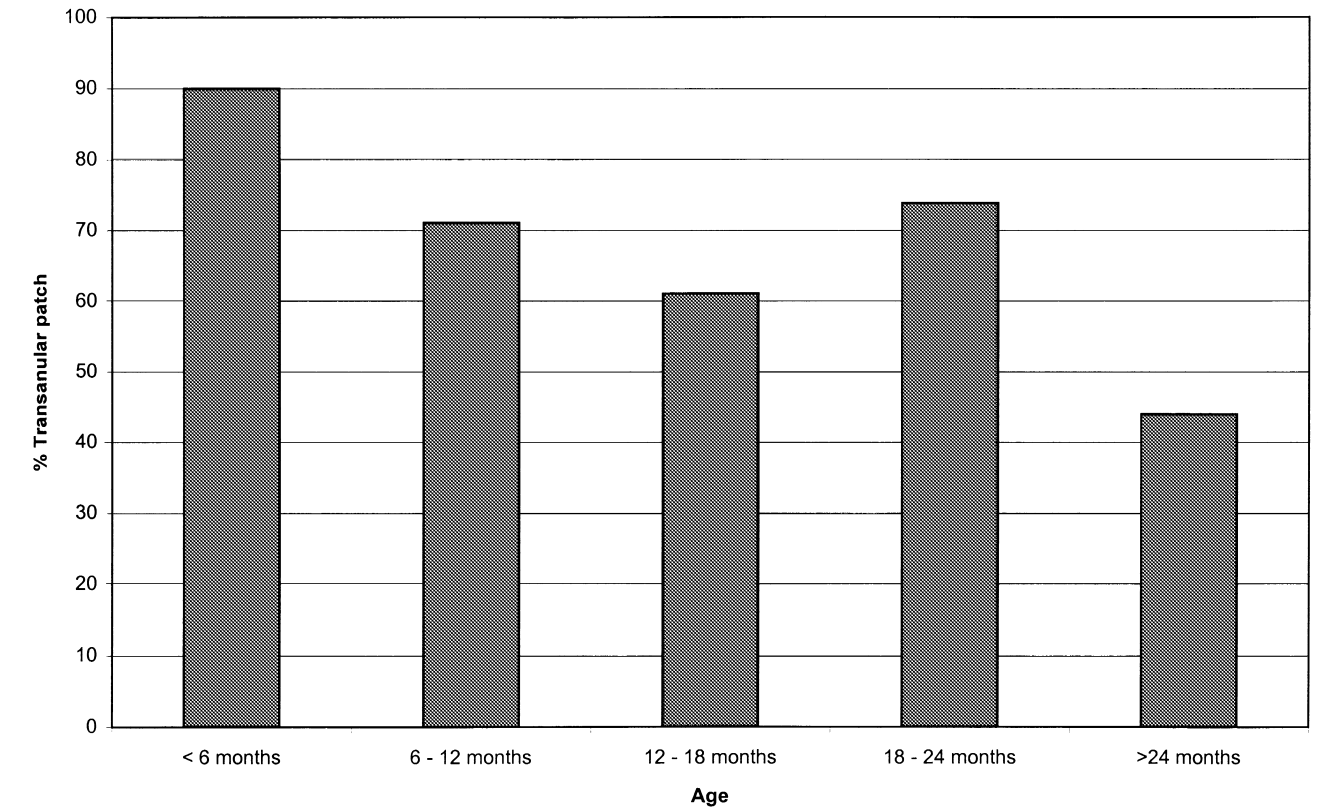


Fig. 3. Incidence of transannular patch by age of patients.

(3.03%) patients had junctional ectopic tachycardia which were treated by systemic cooling to 35°C and overdrive atrial pacing. One patient had disseminated intravascular clotting and recovered from it completely.

At the time of discharge all 132 (100%) patients were in sinus rhythm with 28 (21.2%) showing right bundle branch block, 56 (42.42%) were on digoxin and 90 (68.18%) were on diuretics. There was no difference among different age groups with respect to major or minor complications, inotropic and ventilatory requirement, intensive care or hospital stay.

At the last follow up 128 (96.96%) patients were in NYHA class I and four (3.03%) patients were in NYHA class II. Eighteen (23.67%) patients were on digoxin and 24 (31.68%) patient were on diuretics. Follow up echocardiogram showed good ventricular function in 125 (94.6%) patients. Tricuspid regurgitation was seen in 39 (29.5%) patients with none having severe tricuspid regurgitation. Fifty-one (38.6%) patients had variable degree of pulmonary regurgitation with 28 (21.21%) having moderate pulmonary regurgitation and three (2.27%) patients having severe pulmonary regurgitation. Small residual ventricular septal defect was noted on follow up echocardiogram in eight patients (6.05%). No patient required re-intervention for pulmonary regurgitation, residual right ventricular outflow tract obstruction or residual ventricular septal defect during the follow up period.

4. Discussion and comments

Tetralogy of Fallot is progressive with an unfavourable natural history. Progressive hypoxia, cyanotic spells, cerebral infarction or abscess and endocarditis are major causes of morbidity and mortality [15] and the risk is not entirely removed by palliation. The early and late results of corrective surgery have steadily improved and most centres now report low morbidity and mortality [5,7,11–14,16], as confirmed in this study. Over the years the surgical approach to this condition has changed. There has been a move from a staged approach in favour of a primary repair, a progressive lowering the age at repair and a surgical technique that avoids or reduces the ventriculotomy is preferred.

There is no doubt that primary repair, without prior palliation, is preferable if this can be achieved safely. The immediate consequence of this approach is that patients will need to undergo operation at an earlier age. Several authors have demonstrated that primary repair can be performed in infancy and in the neonatal period without increased mortality or morbidity [5,16–18]. It is a common experience, however, that repair at younger age is associated to a higher incidence of transannular patches. This does not appear to have negative effects at least in the short and medium term. On the other hand early repair has certainly several advantages. It can prevent or reduce the development of severe right ventricular hypertrophy and fibrosis, reduce the risk of

arrhythmias and encourage the development of more normal pulmonary vasculature. Over the period of this study we have achieved a progressive reduction in the age at operation. At present the limiting factor to earlier operation is the timing of presentation or referral. A common attitude is not to intervene in asymptomatic, pink patients. We believe this is wrong and that this is probably the group of patients that could benefit most from an early repair.

We have opted for primary repair whenever possible. However, we still exercise a certain degree of selection. We prefer not to use conduits in neonates and infants and consequently we prefer a shunt in those patients with anomalous coronary arteries. We also opt for a shunt in neonates with multiple, severe, peripheral pulmonary artery stenosis or in the presence of hypoplastic pulmonary arteries. As a consequence of this policy 16.6% of our patients had a modified Blalock–Taussig shunt at a median age of 2.93 months.

This selective approach has allowed us to produce good early and medium term results in all age groups. The remaining question is whether or not these good results will also be maintained in the long term. We are also not in the position to comment on whether or not the same results could be produced with a policy of neonatal or infant correction in patients without any form of selection.

The other important issue is the surgical technique. A transventricular approach has been used for many years and is still in use with good results by some surgeons [16]. However, avoiding a ventriculotomy is very appealing and many authors have proposed a transatrial or transatrial/transpulmonary approach.

We have certainly aimed at avoiding a ventriculotomy but have come to the conclusion that this is not always possible.

Certainly, all the ventricular septal defects can be closed through a right atriotomy. This is our normal practice as we believe that in this way we can minimize the size of ventriculotomy or avoid it altogether.

With regard to the right ventricular outflow tract, we have recognized two distinct situations. In some patients the obstruction is due to hypertrophied muscular bands while in others it is due to an hypoplastic outflow tract. Between these two extremes there is a whole spectrum of intermediate patterns. In the first case we believe that either a right atrial or right atrial/pulmonary artery approach with resection of hypertrophied muscular bands and fibrous tissue can successfully deal with the obstruction without any need for a ventriculotomy. In the second case hypoplasia is the problem and we find very little muscular tissue to remove or divide. In addition these patient have very prominent anterior displacement of the infundibular septum. In our opinion the only way to deal with this type of right ventricular outflow obstruction is to perform a ventriculotomy which should be at least a few millimetres longer than the anteriorly displaced infundibular septum.

Although it is difficult to prove, we believe that an exces-

sively aggressive muscle resection is more damaging than a ventriculotomy. Hence the best way to deal with this obstruction is to adjust the technique to the individual anatomy. To find the balance between muscle resection and ventriculotomy is of paramount importance.

In our series of patients we have described a 31.8% incidence of ventriculotomy, but it is worth emphasizing that ventriculotomy and transannular patch are often used synonymously. Without trying to be semantically too pedantic, we would stress that this is not always the case. There are a number of patients in our series in whom the pulmonary valve ring was stenotic. In these patients the obstruction could be relieved without ventriculotomy, by dividing pulmonary valve ring and enlarging it with a patch without extension of the incision into the outflow tract. As a consequence these patients will have a 'tranannular patch' albeit not a ventriculotomy.

In conclusion, we believe that it is possible to operate on patients with Fallot's tetralogy with very low mortality and morbidity but in order to achieve the best results, it is necessary to adapt the surgical approach to the individual patient. Palliation is sometimes necessary, but primary repair at presentation remains our aim.

References

- [1] Fuster V, McGoon DC, Kennedy MA, Ritter DG, Kirklin JW. Long term evaluation [12–22 years] of open heart surgery for tetralogy of Fallot. *Am J Cardiol* 1980;46:635–642.
- [2] Katz NM, Blackstone EH, Kirklin JW, Pacifico AD, Bargerón Jr LM. Late survival and symptoms after repair of tetralogy of Fallot. *Circulation* 1982;65:403–410.
- [3] Horowitz LN, Vetter VL, Harken AH, Josephson ME. Electrophysiologic characteristics of sustained ventricular tachycardia occurring after repair of tetralogy of Fallot. *Am J Cardiol* 1980;46:446–452.
- [4] Dietl CA, Torres AR, Cazzaniga ME, Favaloro RG. Right atrial approach for surgical correction of tetralogy of Fallot. *Ann Thorac Surg* 1989;47:546–552.
- [5] Karl TR, Sano S, Pornviliwan S, Mee RBB. Tetralogy of Fallot: favourable outcome of nonneonatal transatrial, transpulmonary repair. *Ann Thorac Surg* 1992;54:903–907.
- [6] Kawashima Y, Kitamura S, Nakano S, Yagihara T. Corrective surgery for tetralogy of Fallot without or with minimal right ventriculotomy and with repair of the pulmonary valve. *Circulation* 1981;64(Suppl 2):147–153.
- [7] Touati GD, Vouhe PR, Amodeo A, Pouard P, Mauriat P, Leca F, Neveux JY. Primary repair of tetralogy of Fallot in infancy. *J Thorac Cardiovasc Surg* 1990;99:396–403.
- [8] Pacifico AD, Sand ME, Bargerón LM, Colvin EC. Transatrial – transpulmonary repair of tetralogy of Fallot. *J Thorac Cardiovasc Surg* 1987;93:919–924.
- [9] Walsh EP, Rockenmnhner S, Keane JF, Hougén TJ, Lock JE, Castaneda AR. Late results in patients with tetralogy of Fallot repaired during infancy. *Circulation* 1988;77:1062–1067.
- [10] Martin R, Khaghani A, Radley-Smith R, Yacoub M. Patient status 10 or more years after primary total correction of tetralogy of Fallot under the age of two years. *Br Heart J* 1985;53:666–667.
- [11] Castaneda AR, Freed MD, Williams RG, Norwood WI. Repair of tetralogy of Fallot in infancy: early and late results. *J Thorac Cardiovasc Surg* 1977;74:372–381.
- [12] Gustafson RA, Murray GF, Warden HE, Hill FC, Edward Rozar Jr. G. Early primary repair of tetralogy of Fallot. *Ann Thorac Surg* 1988;45:235–241.
- [13] Starnes VA, Luciani GB, Latter DA, Griffin MC. Current surgical management of tetralogy of Fallot. *Ann Thorac Surg* 1994;58:211–215.
- [14] Barrat-Boyes BG, Neutz JM. Primary repair of tetralogy of Fallot in infancy using profound hypothermia with circulatory arrest and limited cardiopulmonary bypass: a comparison with conventional two stage management. *Ann Surg* 1973;178:406–411.
- [15] Hornereffer PJ, Zahka KG, Rowe SA, Manolio TA, Gott VL, Reitz BA, Gardner TJ. Long term results of total repair of tetralogy of Fallot in childhood. *Ann Thorac Surg* 1990;50:179–185.
- [16] Uva MS, Lacour-Gayet F, Komiya T, Serraf A, Bruniaux J, Touchot A, Roux D, Petit J, Planche C. Surgery for tetralogy of Fallot at less than six months of age. *J Thorac Cardiovasc Surg* 1994;107:1291–1300.
- [17] Caspi J, Zalstein E, Zucker N, Applebaum A, Harrison LH, Munfakh NA, Heck HA, Ferguson TB, Stopa A, White M, Fontenot EE. Surgical management of Tetralogy of Fallot in the first year of life. *Ann Thorac Surg* 1999;68:1344–1349.
- [18] Hennein HA, Mosca RS, Urcelay G, Crowley DC, Bove EL. Intermediate results after complete repair of Tetralogy of Fallot in neonates. *J Thorac Cardiovasc Surg* 1995;109:332–344.