

The left atrial appendage: our most lethal human attachment! Surgical implications[☆]

W. Dudley Johnson^{a,*}, A.K. Ganjoo^b, Christopher D. Stone^c, Ramahalli C. Srivivas^a,
Mary Howard^{a,d}

^aDepartment of Cardiovascular Surgery, St. Francis Hospital, 3300 South 16th Street, Milwaukee, WI 53215, USA

^bSenior Specialist and Chief Cardio-Thoracic Surgery, St. Stephens's Hospital, Tis Hazari, Delhi 110054, India

^cDepartment of Cardio-Thoracic Surgery, Michael E. DeBakey, Heart Institute of Wisconsin, Kenosha, WI 53143, USA

^dW. Dudley Johnson Heart Care Center, 3300 South 16th Street, Milwaukee, WI 53215, USA

Received 20 September 1999; received in revised form 25 February 2000; accepted 29 February 2000

Abstract

Objectives: To prevent death from atrial fibrillation, a cardiac disease which kills by producing emboli. Atrial fibrillation causes about 25% of strokes and increases stroke rate by five times. Over 90% of these embolic strokes are from clots originating in the left atrial appendage. This study addresses the surgical feasibility of removing the appendage to prevent future deaths in two subcategories of patients. (1) Prophylactic removal during open-heart surgery to study its safety. Theoretically, as these patients age and some develop atrial fibrillation, protection from embolic strokes would already be present. (2) Therapeutic removal in chronic atrial fibrillation patients by means of a thorascopic approach. Its technical feasibility is demonstrated. Its actual stroke prevention potential awaits large studies. **Methods:** Appendectomy has been evaluated three ways. (1) Experimentally, thorascopic appendage removal was performed on 20 goats with endoscopic approach. Late studies showed a cleanly healed atrial closure after stapling, and no puckering of tissue as seen with the purse-string approach. (2) Safety of human appendectomy was demonstrated in 437 patients (1995–1997). Routine appendectomy was performed during open-heart surgery. Forty-three appendages were stapled, 391 sutured off. (3) Thorascopic appendectomy in seven patients with chronic atrial fibrillation has been successfully accomplished as an isolated surgical procedure. Stapling or suture closure provides a much cleaner, non-puckered suture line than a purse string. **Results:** In prophylactic removal, no acute bleeding occurred. No late problems have been identified. Endoscopic removal of the appendage has been successful in seven atrial fibrillation patients. **Conclusions:** The left atrial appendage is a lethal source of emboli in atrial fibrillation patients. As patients age and often develop atrial fibrillation, prophylactic appendage removal whenever the chest is open is suggested as a method to prevent future strokes. In chronic atrial fibrillation patients, appendectomy can be done with a mini-thorascopic approach. Further studies are planned to demonstrate the effectiveness of appendectomy in preventing strokes in the chronic fibrillating patients. © 2000 Elsevier Science B.V. All rights reserved.

Keywords: Atrial fibrillation; Atrial appendage; Stroke prevention

1. Introduction

Atrial fibrillation (AF) was once considered a benign, unpleasant rhythm. Studies in the United States and in Europe have now conclusively demonstrated that atrial fibrillation is, in fact, a lethal disease [1]. In the Western World it is a leading cardiac disorder causing death. Recent studies suggest it is the leading arrhythmia causing hospitalization [2]. With over 4 million atrial fibrillation sufferers in Europe and the United States [3,4], the magnitude of the

public health problem of atrial fibrillation certainly approaches epidemic status.

The lethal and devastating effect of this rhythm lies in the large number of arterial emboli that it produces. During atrial fibrillation, no effective atrial contraction occurs. The stagnant blood in the left atrial appendage tends to clot. Studies have indicated that over 90% of atrial clots form in this appendage [5]. The resulting emboli cause about 25% of all strokes [6–9]. Furthermore, these strokes are more lethal and disabling than other strokes [10,11]. With atrial fibrillation, the stroke rate averages about 5% per year, approximately five times the rate for people with normal sinus rhythm [12–14]. The left atrial appendage is our most lethal and disabling attachment!

[☆] Presented at the 13th Annual Meeting of the European Association for Cardio-thoracic Surgery, Glasgow, Scotland, UK, September 5–8, 1999.

* Corresponding author. Tel.: +1-404-643-9880; fax: 1-414-643-9885.

E-mail address: life@johnsonheartcare.com (W.D. Johnson).

In view of these findings, it seems surgical removal of the left atrial appendage might prevent the emboli and reduce strokes. Having received no cardiological support for an open chest operation for ‘appendectomy’, it was elected to try a thoroscopic approach to obliterate the appendage [15,16].

In the initial experimental studies, 20 animals were used (performed at Pewaukee Veterinary Clinic; License no. 35-R-0105, U.S. Department of Agriculture). The initial attempt at appendage obliteration with a loop or purse string was promptly abandoned. The appendage commonly has two, or even three tails. This does not lend itself to a simple loop approach. Perhaps more important, constricting the appendage with one loop tended to cause puckering of the atrial wall. Creating small pockets of atrial wall is exactly the opposite of the desired effect. Commercial endoscopic stapling devices are available and these have proven to be very effective in closing off the appendage with a clean, linear staple line.

In goats that were autopsied many months later, the atrium had healed cleanly and without evidence of clot. These studies demonstrated that clean appendage obliteration can be achieved via thoracoscopy by stapling with a currently available stapling system. A previous study, performed during open-heart surgery, also suggested that the appendage could be more neatly closed without puckering by using a staple machine [17].

In anticipating possible routine removal of the left atrial appendage, long-term function of the appendage was considered. Some surgeons, including the senior author,

have for decades routinely removed the appendage in patients having mitral valve surgery. Adverse results from this approach have not been found in the literature.

Several experimental studies [18–20] and one clinical study [21] all indicate the appendage has certain features. It is more compliant than the atrial wall. Theoretically it could offer some protection from acute elevation in the LA pressure. The appendage also has a higher concentration of the atrial natriuretic peptide. Neither of the functions have been identified as an essential feature in clinical situations. In the clinical study, acute closure of the appendage in patients caused a very small increase in mean LA pressure and an increase in the peak diastolic flow both across the mitral valve and from the pulmonary veins. No changes in pulse rate or blood pressure were observed. The left atrial appendage obviously has very limited function and its removal could potentially have very useful benefits.

2. Methods

Left atrial appendage removal has been performed in two separate studies, prophylactic removal and therapeutic removal, in atrial fibrillation patients. Since emboli from this appendage cause about 25% of strokes (over 125 000 strokes per year in the United States), it seemed reasonable to routinely remove this appendage when the chest was opened. Hopefully our patients would live long enough to develop the usual incidence of atrial fibrillation, and when that happened, the lethal aspect of atrial fibrillation would

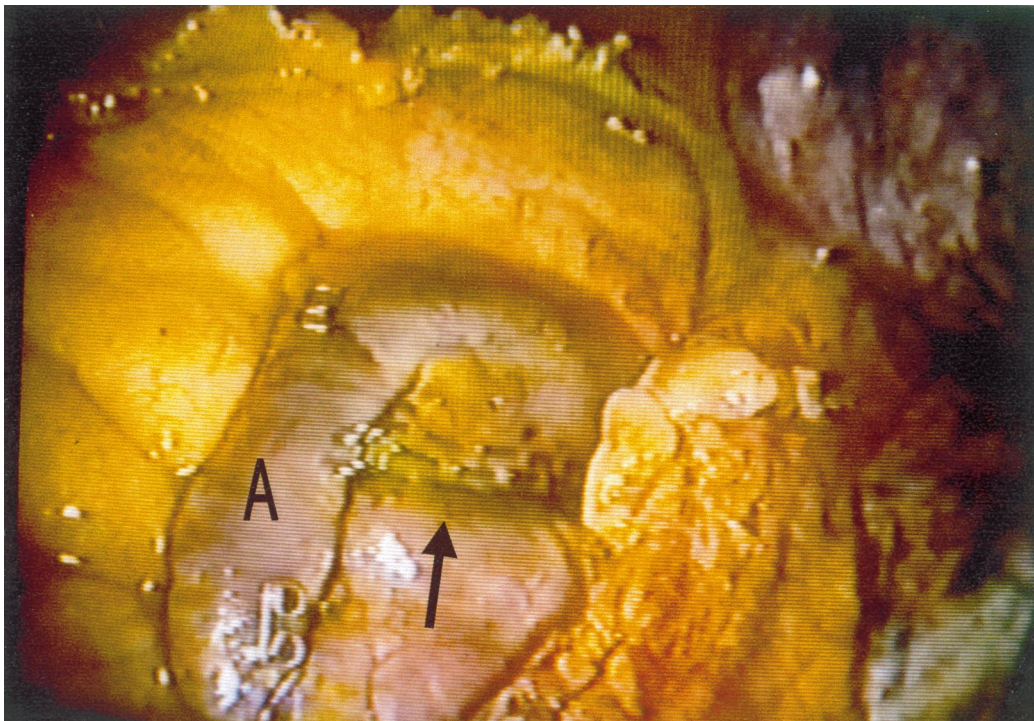


Fig. 1. Thoroscopic picture of the left atrial appendage (A). A clean staple line (arrow) is present which shuts off the appendage with no puckering of the tissue.

have been largely removed. This policy was initiated in late 1995. Two thoroscopic stapling devices were tested with the chest open, one mechanically powered and the other a CO₂ powered stapler (by U.S. Surgical) that closes the staple with a simple touch of the release button.

From late 1995 through 1997, the appendage was

removed in 437 patients undergoing other open-heart operations. In a few patients, no appendectomy was performed. (These few patients were nearly all reoperations, where the hazard of dividing dense adhesions seemed greater than the benefits of appendectomy.) Of the 437 patients, 43 appendages were stapled and 391 were sewn off. If too much

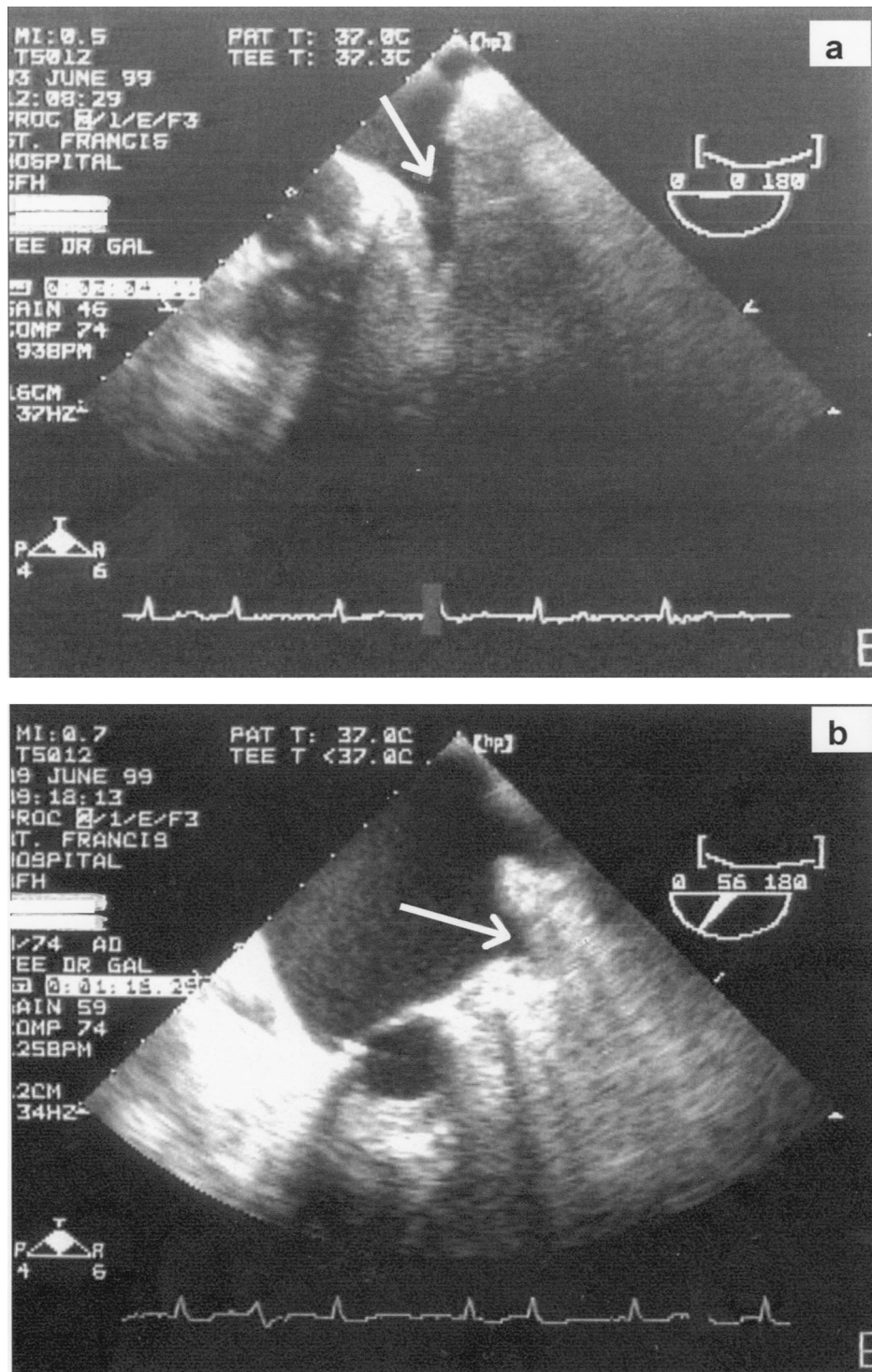


Fig. 2. (a) Pre-operative transesophageal echo visualization of an open appendage without clot. (b) Postoperative transesophageal echo showing obliteration of appendage after stapling.

tension was applied to the appendage and the staples were placed too deep, excess tension was placed on the staple line and small tears and bleeding occurred. In three such patients, additional sutures were required. When applied without tension on the atrium, the staples were very effective in creating a clean, non-puckered closure.

In patients with chronic atrial fibrillation, seven patients were selected to have left atrial appendectomy using the thorascopic approach as depicted in Fig. 1 (consent FDA IDE# G970116). To be eligible for this procedure the protocol required several features:

1. Medical failure or contraindication for warfarin sodium crystalline (Coumadin by Dupont).
2. One or more additional risk factors such as hypertension, prior embolic episode, diabetes, or recent congestive failure.
3. Transesophageal echocardiography within 24 h showing no atrial clot.
4. Negative coronary screening.

In surgery a right lateral decubitus position was used with double lung intubation. Four ports were used, one port for scope, and two for surgical instruments. These ports were spaced near the anterior axillary line. The port for the stapler was placed in the mid-axillary line at the xiphoid level. Effective stapling was accomplished from this position.

3. Results

In the prophylactic series of 437 patients, atrial fibrillation was present in 17 patients preoperatively. Early postoperative atrial fibrillation occurred in 127 patients and 22 patients were discharged with atrial fibrillation. Appendectomy, obviously, does not influence the occurrence of transient postoperative atrial fibrillation. In patients returned to surgery for bleeding, none were bleeding from the appendage area. During this time, 21 patients had perioperative cerebrovascular accident of variable severity. No patients were identified by transesophageal echocardiography to have intra-atrial clots. Seven patients developed a cerebrovascular accident after surgery and four of these had atrial fibrillation. No atrial clots could be found. No late strokes were attributed to atrial fibrillation. In addition, in succeeding years, no patients have been found on transesophageal echocardiographic examination to have atrial clots. In the seven chronic atrial fibrillation patients selected, all had successful appendage closure confirmed by transesophageal echocardiography (Fig. 2). One patient had a stroke several weeks after surgery. This patient had diffuse vascular disease. Echocardiographic studies showed no evidence of thrombus in the atrium. The other patients have remained free of stroke while off Coumadin.

4. Discussion

Routine appendage removal is safe. Furthermore, because cardiac disease is a risk factor for atrial fibrillation, appendectomy should be considered in most patients undergoing heart surgery. Hopefully these patients will live for years. Because they already have a heart problem, their anticipated incidence for developing atrial fibrillation will be above average. If and when atrial fibrillation occurs, these patients will be largely protected from emboli. Use of staples or sutures effectively closes the appendage. Appendage closure is safe and has never been shown to be harmful [5].

The major lethality of chronic atrial fibrillation is embolic episodes. Studies have shown that these usually arise from the appendage. Removal of the appendage theoretically should drastically reduce the lethality of this disease. Technically, endoscopic appendectomy is possible. A large series of patients will need to be followed after appendage removal to demonstrate the efficacy of appendectomy in stroke prevention.

Studies suggest that the left atrial appendage has minimal useful function. It is the source of most emboli in patients with atrial fibrillation and these emboli cause hundreds of thousands of strokes each year. It is clearly our most lethal appendage. Routine appendage removal during cardiac surgery is safe and should be considered. Ongoing studies will be done to evaluate the stroke-preventing role of appendectomy in patients with atrial fibrillation.

References

- [1] Kannel WB, Wolf PA. Epidemiology of atrial fibrillation: AF mechanisms and management. New York: Raven Press, 1992.
- [2] Bially D, Lehmann M, Schumacher D, Steinman R, Meissner M, Harper Hospital/Wayne State University, Detroit, MI and the Commission on Professional and Hospital Activity (CPHA), Ann Arbor, MI. Hospitalization for arrhythmias in the United States: importance of atrial fibrillation. *J Am Coll Cardiol* 1992;19:41A.
- [3] Kannel WD, Abbott RD, Savage DD, McNamara PM. Epidemiologic features of atrial fibrillation; the Framingham study. *N Engl J Med* 1982;306:1018–1022.
- [4] European Atrial Fibrillation Trial Study Group (EAFT). Secondary prevention in non-rheumatic atrial fibrillation after transient ischemic attack or minor stroke. *Lancet* 1993;342:1258–1262.
- [5] Blackshear JL, Odell JA. Appendage obliteration to reduce stroke in cardiac surgical patients with atrial fibrillation. *Ann Thorac Surg* 1996;61:755–759.
- [6] The European Community Stroke Project, Florence Unit. Ischemic stroke associated with atrial fibrillation: The demographic and clinical characteristics and 30 day mortality in a hospital stroke registry. *Ann Ital Med Interna* 1996;11(1):20–26.
- [7] Vemmos KN, Bots ML, Tsibouris PK, Zis VP, Grobbee DE, Georgios GS, Stamatelopoulos SS. Stroke incidence and case fatality in southern Greece: the Arcardia Stroke Registry. *Stroke* 1999;30(2):363–370.
- [8] Petersen P, Godtfredsen J. Risk factors for stroke in chronic atrial fibrillation. *Eur Heart J* 1988;9:291–294.
- [9] Wolf PA, Dawber TR, Thomas HE, Kannel WB. Epidemiologic assessment of chronic atrial fibrillation and a risk of stroke. The Framingham study. *Neurology* 1978;28:973–977.

- [10] Fisher CM. Reducing risk of cerebral embolism. *Geriatrics* 1979;34:59–66.
- [11] Yamanouchi H, Tomonago M, Shimada H, Matsushita S, Kuramoto K, Toyokura Y. Non-valvular atrial fibrillation as a cause of fatal massive cerebral infarction in the elderly. *Stroke* 1989;20:1653–1656.
- [12] Fiore LD. Anticoagulation: risks and benefits in atrial fibrillation. *Geriatrics* 1996;51(6):71–83.
- [13] Cerebral Embolism Task Force. Cardogenic brain embolism (2nd report), 1989. *Arch Neurol* 1989;46:727–743.
- [14] Sherman DG, Hart RG, Easton JD. The secondary prevention of stroke in patients with atrial fibrillation. *Arch Neurol* 1986;43:68–70.
- [15] Johnson WD. Method for closing an atrial appendage. US Patent #5306234. Filing date: March 23, 1993. Issue date: April 26, 1994.
- [16] Odell JA, Bleackshear JL, Davis E, Byrne WJ, Kollmorgen CF, Edwards WD, Orszulak TA. Thorascopic obliteration of the left atrial appendage – potential for stroke reduction? *Ann Thorac Surg* 1996;61:565–659.
- [17] Disesa VJ, Tam S, Cohn LH. Ligation of the left atrial appendage using an automatic surgical stapler. *Ann Thorac Surg* 1988;46:652–653.
- [18] Davis III CA, Rembert JC, Greenfield Jr JC. Compliance of left atrium with and without left atrial appendage. *Am J Physiol* 1990;72(1):1006–1008.
- [19] Holt BD, Shao Y, Tsai L-M, Patel R, Gabel M, Walsh RA. Altered left atrial compliance after atrial appendectomy: influence on left atrial and ventricular filling. *Circ Res* 1993;72(1):167–175.
- [20] Hondo T, Okamoto M, Yamazen T, Kawaguchi T, Karakawa S, Yamagata T, Matsuura H, Kajiyama G. The role of left atrial appendage: a volume loading study in open-chest dogs. *Jpn Heart J* 1995;36:225–234.
- [21] Tabota T, Oki T, Yamada H, Iuchi A, Ito S, Hori T, Kitagawa T, Kato I, Kitahata H, Oshita S. Role of left atrial appendage in left atrial reservoir function as evaluated by left atrial appendage clamping during cardiac surgery. *Am J Cardiol* 1998;81:327–332.

Appendix A. Conference discussion

Dr L. Eijssman (Amsterdam, The Netherlands): I have two questions. Since, as you already pointed out, we know that over 90% of emboli originate in the left atrial appendage, do you consider it necessary after surgical closure to put those patients who can tolerate Coumadin back on Coumadin, or do you think that it is safe enough to leave them without Coumadin? And if your answer is yes, do you think that platelet inhibitors or other drugs should be used?

The second question is a technical question. Since we are aware of the fact that with increasing age the incidence of atrial fibrillation becomes higher, most patients will be of a high age and will have fragile tissue. Would you consider putting something like pericardium or PTFE between the stapler's feet in order to prevent bleeding from the atrial appendage?

Dr Johnson: The patients we have done so far are not on Coumadin for various reasons, and we certainly have not put them back on Coumadin after surgery. We anticipate following these people, and if their stroke reduction is very marked, I would not anticipate trying to place them on Coumadin long term. There are plenty of epidemiological studies demonstrating the high stroke rate in these people. When we do this on larger volumes of people, I anticipate not placing them on Coumadin, leaving them on aspirin, however, which is safer and simpler, and we will then find out whether we can effectively reduce strokes with appendage ligation. To do this operation and put them on Coumadin would appear to be somewhat redundant. Certainly, Coumadin has been well demonstrated to mark-

edly lower the stroke incidence, but there are obviously lots of patients who can't take it for many different reasons.

In terms of reinforcing the suture line, we have used the Gore-Tex sheath over the stapler in the open chest. It works fine to reinforce the suture line in these patients who are on heparin. Staple line bleeding has been no problem with endoscopic patients. There are various things, and certainly lots of glues available at this meeting today, that could be injected around the staple line to slow down the bleeding. In two patients with an open chest who were on chronic steroids, we had a little trouble with the atrium coming apart, and certainly in somebody on steroids I would be inclined to use some type of reinforcing system.

Dr S. Benussi (Milan, Italy): We think that the left atrial appendage should be closed in every patient undergoing an open-heart procedure in atrial fibrillation whether you treat the arrhythmia or not. My question is, do you have any clinical evidence of the impact of primary auricle exclusion on the incidence of thromboembolic events, as assessed by a comparative study?

Dr Johnson: I assume you are referring to the routine appendage removal whenever the chest is open. We don't know the incidence of late-onset AF after any heart operation, but since some heart disease is a risk factor for AF all postoperative patients must have a normal or above-normal chance of developing AF years later. Since the atrial appendage is the source of enormous morbidity and mortality as we get older, it just makes sense to get rid of it.

How long before we can prove the differences, I can't answer. In patients with chronic atrial fibrillation, the statistics are all worked out. We will need to do so many patients and follow them for so long without Coumadin to demonstrate how effectively we can reduce the stroke rate. But it will take a period of time. If anybody should be interested in working with us on this and getting combined data, we would be very excited.

Dr Benussi: The incidence of thromboemboli in patients with atrial fibrillation after mitral valve replacement has been shown to be higher despite the use of anticoagulants. My concern is about these patients with atrial fibrillation on oral anticoagulants after operation. Did you prove any clinical benefit in this setting when the auricle was sutured?

Dr Johnson: I didn't because I routinely have removed the appendage for 25 or 30 years in anybody with mitral valve problems having surgery. The point here is that we think routine removal of the appendage in everybody should be considered during surgery, with or without atrial fibrillation, and with or without valve disease.

Dr S. Schueler (Dresden, Germany): What about those patients in sinus rhythm? I mean, it seems to me that this is the consequence of your statement, that basically everybody has to undergo this procedure who has his chest opened.

Dr Johnson: This is what we are recommending for strong consideration, and we have followed these patients from 1995 to 1997 very carefully. We have contacted them at home, and we have not identified any strokes associated with thrombus in the left atrium. When the chest is open, the 2–3 min required for appendectomy of this lethal and useless appendage may well be worthwhile.

Dr J. Melo (Carnaxide, Portugal): Can you tell us, where do you put your ports and how many ports are you using for this procedure?

Dr Johnson: We have three ports, plus or minus, along the anterior axillary line with the patient obviously in the lateral decubitus position with double intubation. These ports are for surgical and retraction instruments. The stapler port is in the mid-axillary line at the xiphoid level, and it seems to work very well from that position. I should tell you that every patient preoperatively has a TE echo the day before surgery. If that appendage is full of clot, we are not going to go in and smash it with a stapler.