

Indications for surgery in tracheobronchial ruptures[☆]

S. Gabor^{*}, H. Renner, H. Pinter, O. Sankin, A. Maier, F. Tomaselli, F.M. Smolle Jüttner

Department of Thoracic and Hyperbaric Surgery, University Medical School of Graz, Auenbruggerplatz 29, A-8036 Graz, Austria

Received 17 October 2000; received in revised form 8 May 2001; accepted 11 May 2001

Abstract

Objective: Ruptures of the tracheobronchial tree present a life-threatening situation. Nevertheless, therapy is still controversial. Though conservative treatment by antibiotics and intubation with the cuff inflated distal to the tear is favored by some authors, surgical repair is unavoidable in many cases. **Methods:** We present a series of 31 patients (mean age 43.6 years, range 8–72 years) with iatrogenous or post-traumatic tracheobronchial ruptures treated since 1975. Fifteen ruptures were longitudinal tears of the trachea, not extending lower than a distance of 3 cm from the bifurcation, 11 involved the bifurcation and/or the main bronchi. The total length of the longitudinal tears ranged from 2 to 12 cm, five were transverse near complete abruptions of the trachea or main bronchi. Involvement of the full thickness of the wall with free view into the pleural space or to the esophageal wall was present in 29 cases. Twenty-nine out of the 31 patients underwent surgical repair and two were treated conservatively. The length and depth of the lesion, the degree of subcutaneous emphysema, pneumothorax and/or pneumomediastinum as well as clinical signs suggesting incipient mediastinitis were considered when making the decision for surgery. **Results:** Twenty-five out of the 29 patients experienced an uneventful recovery. Four patients died of sepsis unrelated to the tracheobronchial trauma. One of the two patients who underwent conservative therapy also recovered uneventfully. The other one died because of multi-organ failure due to underlying myocardial infarction. **Conclusions:** Conveniently localized short lacerations, especially if they do not involve the whole thickness of the tracheal wall, can be treated with antibiotics and intubation with the cuff inflated distal to the tear, avoiding high intrabronchial pressures also after eventual extubation. In all other cases surgical repair is to be preferred. © 2001 Elsevier Science B.V. All rights reserved.

Keywords: Tracheobronchial rupture; Trauma; Iatrogenous; Surgery; Outcome

1. Introduction

Tracheobronchial rupture is defined as any injury to the trachea or bronchi localized between the level of the cricoid cartilage and the division of the lobar bronchi into their segmental branches. The etiology comprises blunt trauma, explosion injuries, penetrating or gunshot wounds, and iatrogenic injuries.

Ruptures of the tracheobronchial tree often present a dramatic, life-threatening situation. Tension pneumothorax and mediastinal emphysema, as well as prolapse of the esophageal wall into the tracheal lumen, can cause acute asphyxia. In the later course of the injury mediastinitis and sepsis can occur. Nevertheless, some patients, especially those with smaller ruptures run a less eventful course

with only minor signs of penetration of air into the pleural space and into the soft tissues.

This is why therapy is still controversial. Though ‘non-operative’ treatment by antibiotics and intubation with the cuff inflated distal to the tear may be effective in some cases, surgical repair is unavoidable in many others. Up to this time, however, no criteria for the choice of treatment have been established

We present a series of 31 patients with iatrogenous or traumatic tracheobronchial ruptures treated since 1975, trying to define parameters suggesting the need for a surgical intervention.

2. Materials and methods

Since 1975, 31 patients (mean age 43.6 years; range 8–72 years) have been treated because of iatrogenous or traumatic tracheobronchial rupture. The tentative diagnosis of a tracheobronchial rupture made by the clinical features (dyspnea, subcutaneous emphysema, hemoptoe, retrosternal pain) and by the findings from the chest roentgenogram

[☆] Presented at the 14th Annual Meeting of the European Association for Cardio-thoracic Surgery, Frankfurt, Germany, October 7–11, 2000.

^{*} Corresponding author. Tel.: +43-316-385-3302; fax: +43-316-385-4679.

E-mail address: sabine.gabor@kfunigraz.ac.at (S. Gabor).

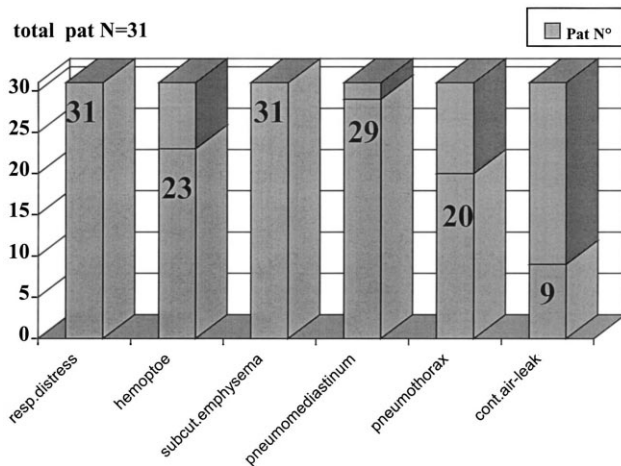


Fig. 1. Symptoms of tracheobronchial rupture found before emergency bronchoscopy.

(pneumothorax, pneumomediastinum) was confirmed by emergency fiberoendoscopy. Ten patients were not diagnosed till after a delay of more than 20 h (5–120). For the clinical and radiological findings see Fig. 1.

Emergency bronchoscopy was done under general anesthesia using a flexible endoscope inserted through an uncuffed endotracheal tube that was repositioned in such a way as to ensure inspection of both the upper and lower rims of the rupture. After the investigation the tube was either fixed in its definitive position for conservative treatment or brought into a position that was adequate for immediate surgical repair (Fig. 2).

Indications for surgical repair were: tension pneumothorax with tracheobronchopleural fistula developing after drainage, rapidly increasing pneumomediastinum and increasing subcutaneous emphysema in spite of conservative treatment attempts, transmural tear with free vision beyond the tracheobronchial wall longer than 2 cm, prolapse of the esophageal wall into the tracheal lumen, and mediastinitis.

Depending on the localization of the rupture, we either used a cervical approach ($N = 3$) or right posterolateral thoracotomy in the fourth intercostal space ($N = 19$) or both a cervical and thoracotomy approach ($N = 7$). Longitudinal tears were closed by continuous running suture, and transverse abruptions by interrupted suture in the cartilaginous and by running suture in the membranous part of the

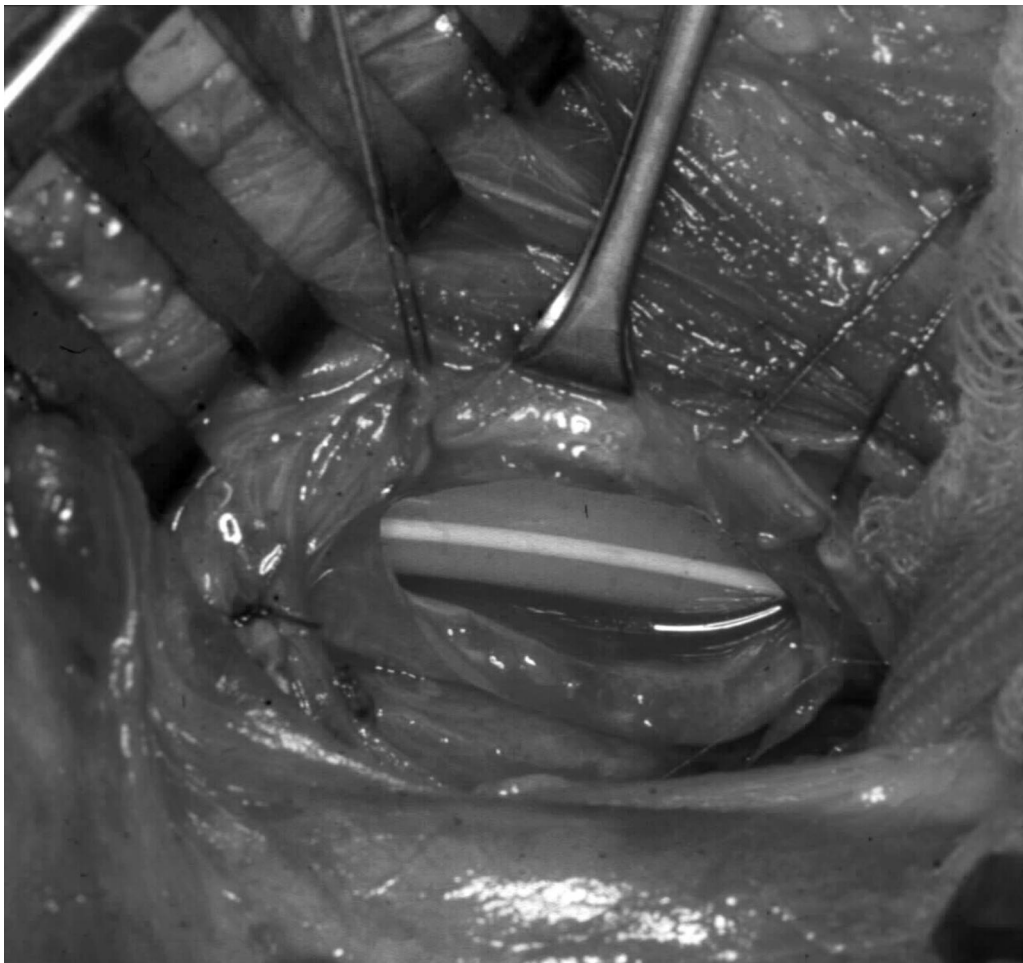


Fig. 2. Longitudinal rupture of the membranous part of the cervical trachea. The endotracheal tube is visible in the tracheal lumen.

organ. Only absorbable sutures (Vicryl R; Ethicon Hamburg-Norderstedt) were used. In patients who had been diagnosed only after considerable delay, clear-cut suturing was not always possible due to mediastinitis and inflammatory changes of the tracheobronchial wall. In these cases a pedicled pectoralis mayor muscle flap was used to cover the suture line and to prevent the formation of an esophagotracheal fistula. In most cases the anesthetic management was demanding: jet-ventilation, frequent bronchoscopically guided, intra-operative repositioning of the tube, intubation over the operated site, and apneic oxygenation were used.

In two small lacerations (<2 cm) localized in the mid-trachea or cervical trachea, respectively, which did not involve the whole thickness of the tracheal wall, the decision for non-operative treatment was made – the patients were intubated with the cuff inflated distal to the tear, a chest tube was inserted in case of pneumothorax, and antibiotic treatment was initiated. For the treatment modalities see Table 1.

The further management for both strategies included vigorous fiberoscopically guided frequent tracheobronchial toilet, broad spectrum antibiotics, and prevention of high

intra-bronchial pressures and by keeping the patients from coughing. Patients who had undergone surgery were extubated as soon as possible, preferably in the operating theater.

3. Results

Twenty-nine out of the 31 patients underwent surgical repair, two were treated non-operatively. In the endoscopic aspect 15 tears were longitudinal involving only the trachea, not extending lower than 3 cm cranial to the bifurcation; 11 further longitudinal tears involved both the distal trachea and the bifurcation and/or the main bronchi. The length of the longitudinal tears ranged from 2 to 12 cm; five tears were transverse, near complete abruptions of the trachea or main bronchi. Rupture of the full thickness of the wall with free view into the pleural space or to the esophageal wall was present in 29 cases (see Fig. 1).

Twenty-five out of the 29 patients who underwent surgical repair experienced an uneventful recovery. Mean stay at the intensive care unit was 5.7 days (2–10 days), mean hospital stay was 12.3 (9–20 days). No post-operative steno-

Table 1
Treatment modalities

Patient no./sex	Cervical approach	Thoracic approach ^a	Cervical+ approach ^a	Suture	Conservative treatment
1/m	Right	4th ICR	Right/4th ICR	Running	
2/f				Interrupted	
3/f	Left	5th ICR		Running	Yes
4/f				Running	
5/m			No		
6/m			Interrupted		
7/f		4th ICR	Running		
8/f		4th ICR	Running		
9/f		4th ICR	Running		
10/f			Right/4th ICR	Running	
11/m			Right/4th ICR	Running	
12/m			5th ICR	Running	
13/f		6th ICR	Running		
14/f		5th ICR	Interrupted		
15/f			No	Yes	
16/f			Right/4th ICR	Running	
17/f		4th ICR		Running	
18/m	Right		Right/4th ICR	Running	
19/f				Running	
20/f		6th ICR		Running	
21/m		6th ICR		Interrupted	
22/f		4th ICR		Running	
23/f		5th ICR		Running	
24/m		4th ICR		Running	
25/m			Right/4th ICR	Running	
26/f		4th ICR		Running	
27/f		5th ICR		Interrupted	
28/m		4th ICR		Running	
29/f			Right/4th ICR	Running	
30/f		5th ICR		Running	
31/f		4th ICR		Running	

^a ICR, intercostal space.

sis developed within the follow-up period between 6 months and 20 years.

Four patients died of sepsis unrelated to the tracheobronchial trauma (two multi-organ failures due to underlying sepsis, one following esophageal resection in a patient with impaired hepatic function, one sepsis and multi-organ failure in the later course of severe thoracoabdominal trauma). In two out of these four patients, adult respiratory distress syndrome (ARDS) developed, necessitating high ventilatory pressures, which eventually caused the suture line to yield after 8 and 10 days, respectively. One patient even developed secondary oesophago-tracheal fistula, which was not amenable to treatment because of the poor general condition.

One out of the two patients, who underwent *non-operative* therapy, also experienced an uneventful recovery. Control endoscopy after 1 week showed a mucosal scar. Follow-up endoscopies after 6 and 12 months showed no evidence of the previous tear. The other patient died of multi-organ failure due to underlying myocardial infarction.

4. Discussion

Respiratory distress and subcutaneous emphysema are the most common clinical findings in tracheobronchial ruptures. Stridor may be present if the larynx or upper trachea are involved. Hemoptysis is also commonly associated with airway injuries at any level, though it may be surprisingly discrete [1]. The degree of subcutaneous emphysema varies according to the location and magnitude of the airway injury. Early radiological signs indicating the possibility of a rupture of the tracheobronchial tree have been described by several authors. Deep cervical emphysema and mediastinal emphysema are commonly found. The obstruction of an air-filled bronchus or the disruption of the tracheal air column has also been mentioned.

A pneumothorax is often present, particularly if the injury communicates freely with the pleural space. The development of a pneumothorax following endotracheal intubation or positive pressure ventilation is another common finding with airway injury. Persistent severe air leak and the failure of the lung to reexpand after chest tube insertion are further evidences of a major airway injury (Fig. 3).

Two-thirds of our patients had both subcutaneous and mediastinal emphysema as well as pneumothorax and intra-luminal bleeding.

The role of a computerized tomography (CT) scan in the diagnosis of tracheobronchial injuries is not clear at this time. Its greatest value is the possibility of detecting mediastinal emphysema not yet visible by routine chest roentgenograms, or of documenting mediastinal hematoma and associated injuries of great vessels. If tracheobronchial trauma is suspected, an inconspicuous CT, however, does not obviate the need for bronchoscopy or further diagnostic measures.

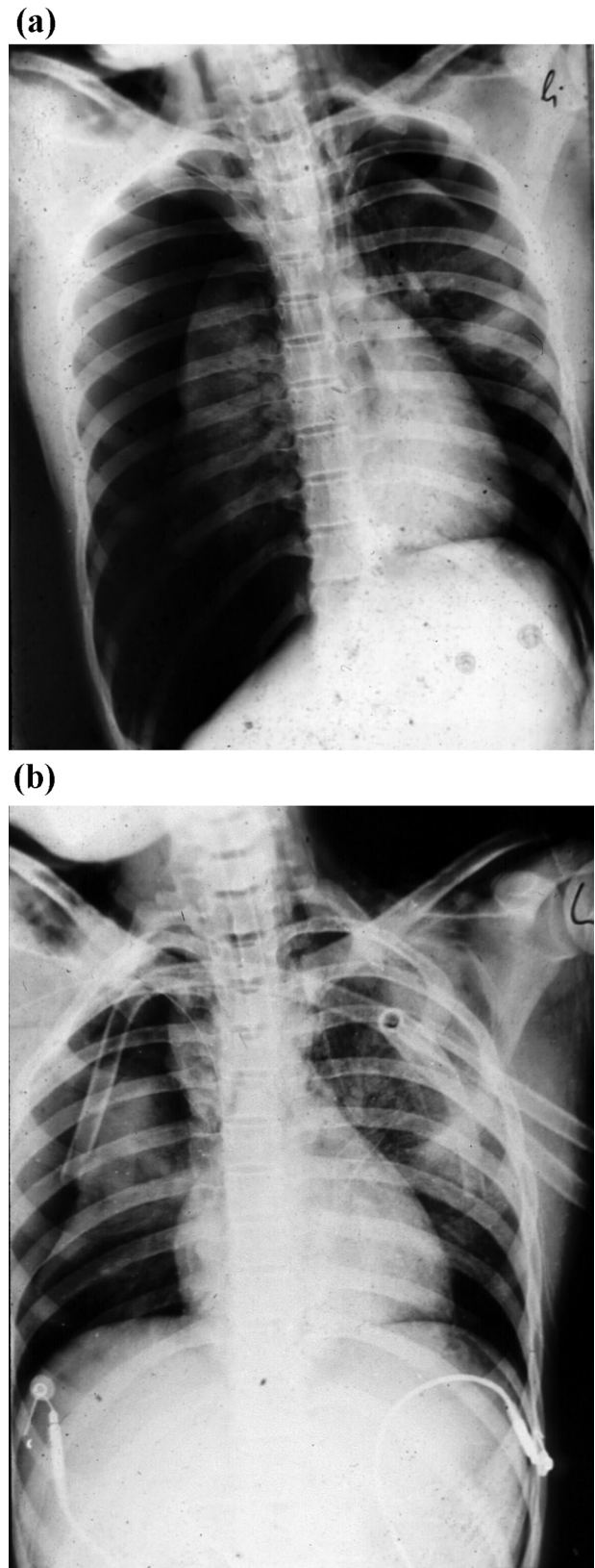


Fig. 3. Pneumothorax and failure of the lung to reexpand after chest tube insertion as an evidence of major airway injury.

Early bronchoscopy is the most effective diagnostic tool in case of suspected airway injury [1–12]. In all our patients the tentative diagnosis was confirmed by emergency bronchoscopy. Moreover, bronchoscopy allows a rather clear determination of the extent and depth of the rupture, establishing a further important parameter for the choice of treatment. For emergency bronchoscopy, which was done under anesthesia, we chose a flexible endoscope inserted through an endotracheal tube, the latter being uncuffed in order not to increase the damage and to be readily repositioned for inspection of the rims of the rupture. This technique enabled sufficient ventilation, a meticulous inspection, and a clear-cut positioning of the endotracheal tube once the investigation was finished, without any need for changing endoscopic devices.

The indications for surgical repair are based upon a synopsis of clinical, radiological, and endoscopic findings. Respiratory distress in the absence of a pneumothorax, rapidly increasing subcutaneous and mediastinal emphysema, and/or pneumothorax showing continuous air leak and no reexpansion of the lung after intercostal suction drainage are strong indicators for the need of surgery. We found these criteria in all patients who during emergency endoscopy had tears involving the full thickness of the organ, longer than approximately 2 cm. Furthermore, transmural ruptures involving the paracarinal region and/or prolapse of the oesophageal wall into the tracheal lumen are indications for surgery (see Fig. 1). In none of our patients was a CT-scan necessary to make the decision for or against surgery.

The choice of the approach for surgical repair depends on the location and the length of the tear. Injuries of the cervical trachea and larynx are best dealt with by a collar incision. A right posterolateral thoracotomy through the fourth or fifth intercostal space gives an excellent exposure of the distal trachea, the bifurcation, and both mainstem bronchi. Only for isolated transverse abruptions of the left mainstem bronchus close to the lobar orifices is a left thoracotomy to be preferred [4,8,9]. Only in three of our patients was the cervical approach alone sufficient; 26 patients had thoracotomies, seven of them both thoracotomy and cervical incision. We do not have experience in transcervical–transtracheal endoluminal repair of membranous tracheal disruptions. Some authors [13,14] discuss a possible reduction of the risk of laryngeal nerve injury or of disconnection of the trachea from its vasculature by avoiding lateral and posterior dissection. This technique, however, is not the method of choice in ruptures of the intra-thoracic trachea or of the bifurcation, which made up the majority of our cases. Moreover, an extensive longitudinal tracheotomy is also a further trauma to the already injured trachea and it may carry the risk of cicatricial stricture.

The principles of surgery for airway injuries include trimming of the borders of the rupture in case of transverse disruptions, mucosa to mucosa repair, and if necessary, the use of protective tissue (muscle, pericard, pleura, mediastinal fat pads) [3] for the anastomosis or suture

line, respectively. Like most authors, we prefer the use of absorbable suture material, applying continuous running sutures whenever possible. As to our experience, an additional ‘protective’ tracheostomy as advocated by some authors [1] is unnecessary and would only mean additional trauma to the trachea.

‘Non-operative’ treatment is reserved for patients in whom the laceration is either small (less than approximately 2 cm) and amenable to adequate cuff positioning, or not involving the whole thickness of the tracheobronchial wall, as well as for patients in a poor general condition with a very high operative risk [4–7,10,11]. Most authors report higher mortality rates for conservatively treated cases, but this may be due to the high proportion of a poor general condition in these very patients. Our own two observations fit into this concept. In general, the indication for a non-operative treatment of tracheobronchial injuries should never be overextended. In case of doubt a second decision for surgery, if possible, should be made quickly.

‘Non-operative’ management includes intubation with the cuff inflated distal to the tear, a chest tube drainage if necessary and adequate antibiotic management. High ventilatory pressures should be avoided at any rate. Furthermore, these patients should be observed carefully for airway obstruction and pulmonary and mediastinal sepsis.

In conclusion, surgical repair of tracheobronchial ruptures ensures a quick relief from a vitally dangerous situation at a tolerable operative risk. The post-operative results are good. The decision for or against surgery must be based upon a synopsis of clinical, radiological, and endoscopic findings. Conservative measures are indicated in well-selected cases, predominantly in those localized in the two upper thirds of the trachea, provided the laceration is small and/or does not involve all tracheal layers.

References

- [1] Wilson RF. Hemoptysis in trauma. *J Trauma* 1987;27:1123–1125.
- [2] Pearson FG, Deslauries J, Ginsberg RJ, Hiebert CA, McKneally M, Urschel HC. Thoracic surgery. Churchill Livingstone 1995 p. 1543–54.
- [3] Berry M, Van Schil P, Van Meerbeeck J, Vanmaele R, Eyskens E. Surgical treatment of iatrogenic tracheal lacerations. *Acta Chir Belg* 1997;97(6):308–310.
- [4] Borasio P, Ardisson F, Chiampo G. Post intubation tracheal rupture. A report on ten cases. *Eur J Cardio-thorac Surg* 1997;12(1):98–100.
- [5] Massard G, Rouge C, Dabbagh A, Kessler R, Hentz JG, Roeslin N, Wihlm JM, Morand G. Tracheobronchial lacerations after intubation and tracheostomy. *Ann Thorac Surg* 1996;61(5):1483–1487.
- [6] Wu MH, Tseng YL, Lin MY, Lai WW. Surgical results of 23 patients with tracheobronchial injuries. *Respirology* 1997;2(2):127–130.
- [7] Ramzy AI, Rodriguez A, Turney SZ. Management of major tracheobronchial ruptures in patients with multiple system trauma. *J Trauma* 1988;28(9):1353–1357.
- [8] Hasegawa T, Endo S, Sohara Y, Kamisawa O, Murayama F, Yamaguchi T, Fuse K. Successful surgical treatment of a complete traumatic tracheal disruption. *Ann Thorac Surg* 1997;63(5):1479–1480.
- [9] Santambrogio L, Nosotti M, Cioffi U, De Simone M, Pavoni G, Testori A. Extended membranous tracheobronchial rupture after tracheal intubation. *Int Surg* 1998;83(2):106–107.

- [10] Velly JF, Martigne C, Moreau JM, Dubrez J, Kerdi S, Couraud L. Post traumatic tracheobronchial lesions. A follow-up study of 47 cases. *Eur J Cardio-thorac Surg* 1991;5(7):352–355.
- [11] Schultz SC, Hammon Jr JW, Turner CS, McGuirt Jr. WF, Nelson JM. Surgical management and follow up of a complex tracheobronchial injury. *Ann Thorac Surg* 1999;67(3):834–836.
- [12] Kaloud H, Smolle-Juettner FM, Prause G, Pinter H, Offner A, Ratzenhofer-Komenda B, List WF. Iatrogenic ruptures of the tracheo-bronchial tree. *Chest* 1997;112:774–778.
- [13] Mussi A, Ambrogi MC, Menconii G, Ribechini A, Angeletti CA. Surgical approaches to membranous tracheal wall lacerations. *J Thorac Cardiovasc Surg* 2000;120(1):115–118.
- [14] Lancelin C, Chapelier AR, Fadel E, Machiarini P, Daetevelle PG. Transcervical–transtracheal endoluminal repair of membranous tracheal disruptions. *Ann Thorac Surg* 2000;70(3):984–986.

Appendix A. Conference discussion

Dr P. Fuentes (Marseille, France): Do you think that patients who are not operated on need always to be intubated?

Dr Gabor: In our two cases, yes.

Dr Fuentes: There are a lot of patients who have a small laceration on the membrane and they do not need to be intubated at all.

Dr Gabor: Of course, but in these specialized two cases it was necessary.

Dr Fuentes: How long?

Dr Gabor: One patient, about 6 days, and one patient, 4 days.

Dr H.-B. Ris (Lausanne, Switzerland): In two patients, the lesions were probably due to an intubation related injury.

Dr Gabor: No.

Dr Ris: How do you treat those lesions using prolonged intubation in order that the cuff will not be situated where you have the lesion of the trachea?

Dr Gabor: Endoscopically.

Dr Ris: Have you observed movements of the tube and cuff during this prolonged time of intubation which could interfere with the lesion?

Dr Gabor: It's controlled endoscopically.

Dr M. Perelman (Moscow, Russia): Our strategy for patients with tracheo-bronchial ruptures must be surgical treatment, surgical treatment in principle only. In selected cases it is possible to treat these patients non-surgically but

under three important conditions: the first, the tear, the rupture must be small; the second condition, it is necessary to have careful observation, careful monitoring of the patient in the hospital; and the third, there must be an experienced surgeon for conservative treatment of such patients.

Dr T. Thorpe (Leeds, UK): I think we have got to also make sure that we have a good anesthetist as well, because we have had about five percutaneous tracheostomies that have perforated the membranous trachea, and out of these, one had to have surgery, so four have been treated conservatively. So I think we ought to tell our anesthetists to be a bit more careful.

Dr K. Al Kattan (Riyadh, Saudi Arabia): What do you do with late presentation of bronchial rupture? We had a couple of cases where they actually had bronchial rupture and they were not managed in a specialized center, that they actually presented to us with complete obstruction of that lung due to old rupture and fibrosis. We tried to attempt to resect and reanastomose again, like a bronchotomy, and it always failed, although the underlying lung is healthy. Do you have experience with late cases of bronchial rupture with fibrosis?

Dr Gabor: In these 31 patients I presented there was no case with such stenosis after rupture. So I have no experience with these things. I have read about it in the literature, but in all of these cases, even in this one who had a delay from about 5 days, there was no stenosis.

Dr V.V. Sokolov (Kiev, Ukraine): Have you ever seen in your practice complete transections of the trachea?

Dr Gabor: Yes.

Dr Sokolov: In our experience we have five patients with complete transection of the trachea. In three patients the transection was due to a penetrating trauma and in two patients the transections were due to blunt trauma. Do you have such cases?

Dr Gabor: Yes. In these cases there were two patients after blunt thoracic trauma with complete disruption of the trachea.

Dr M.C. Ambrogi (Pisa, Italy): What surgical technique did you utilize to repair the membranous tracheal tear?

Dr Gabor: I repaired with a running continuous suture using an absorbable suture.

Dr Ambrogi: Do you make a lateral and posterior tracheal dissection approaching the membranous wall from behind?

Dr Gabor: It depends on the localization of the rupture. I would use a cervical approach or a thoracotomy. In most of the cases we need a thoracotomy through actually the fourth intercostal space and in a few cases also the fifth and the sixth.