

Video-assisted thoracoscopic lobectomy in infants[☆]

Indalecio Cano^{a,*}, Juan L. Antón-Pacheco^a, Araceli García^a, Steve Rothenberg^b

^a Division of Pediatric Surgery and Pediatric Airway Unit, University Hospital "12 de Octubre", Madrid, Spain

^b Division of Pediatric Surgery, Children's Hospital, Denver, CO, USA

Received 3 October 2005; received in revised form 12 December 2005; accepted 14 December 2005

Abstract

Objective: Congenital lung malformations are often discovered on routine prenatal sonography or postnatal imaging. Lesions such as congenital cystic adenomatoid malformation or pulmonary sequestration may be asymptomatic at birth, and their management is controversial. Thoracoscopy in children has been mainly used for lung biopsy and for the treatment of empyema and recurrent pneumothorax. Very few reports of more technically demanding procedures, such as lobectomy, are currently available. This report evaluates the safety and efficacy of video-assisted thoracoscopic (VATS) lobectomy in infants and small children with asymptomatic prenatally diagnosed lung lesions. **Methods:** During 2004, six patients underwent VATS lobectomy without a mini-thoracotomy. Mean age was 10 months (range, 6–19 months). Preoperative diagnosis included congenital cystic adenomatoid malformation ($n = 5$) and an extralobar pulmonary sequestration. All patients were asymptomatic and surgery was performed electively. Three or four 3–5 mm ports were used. Single lung ventilation and controlled low pressure pneumothorax were used in every case. A bipolar sealing device was the preferred mode of vessel ligation and bronchi were closed with interrupted sutures. A chest tube was left in all cases. **Results:** All the procedures were completed thoracoscopically. Operating times ranged from 70 to 215 min (mean, 130 min). There were five lower lobe and one middle lobe resections. There were no intraoperative complications and chest tubes were left in place 1–4 days. Two patients showed postoperative hemothorax that stopped spontaneously. Hospital stay ranged from 4 to 9 days (mean, 7 days). **Conclusions:** VATS lobectomy in small infants is a feasible and safe technique. Decreased postoperative pain, a shorter hospital stay, and a better cosmetic result are definite advantages of this minimally invasive procedure. Long-term morbidity due to a major thoracotomy incision is avoided.

© 2006 Elsevier B.V. All rights reserved.

Keywords: Thoracoscopy; VATS; Lung lobectomy; Congenital cystic adenomatoid malformation; Pulmonary sequestration

1. Introduction

Due to the increasing number of obstetrical ultrasound explorations and the improvement in quality and resolution, congenital lung malformations are being diagnosed more frequently before birth [1,2]. The most common prenatally diagnosed intrathoracic masses in fetuses are congenital cystic adenomatoid malformation (CCAM) and pulmonary sequestration (PS). They appear as hyperechoic, cystic, or mixed lesions within the chest that may displace the fetal heart and mediastinum. The prenatal development of these lesions is quite variable. While some congenital lung malformations may cause complications such as: heart failure, fetal hydrops, polyhydramnios with preterm labor, or even fetal demise, the majority remain stable. These lesions may keep relatively constant in size or they may even regress, so they can be misdiagnosed on subsequent

prenatal ultrasound explorations [3,4]. Most patients remain asymptomatic after birth and frequently chest radiographs appear completely normal [5].

Some authors recommend simple observation of patients with asymptomatic cystic lung lesions [2]. However, most authors favor surgical resection, at least for CCAM [6]. In this malformation, despite the lack of symptoms, patients are prone to pulmonary infections and, if left untreated, these lesions may develop malignant transformation. For these reasons, cystic lung lesions should be resected electively. Pulmonary lobectomy via a posterolateral thoracotomy incision has been the standard surgical procedure. The associated morbidity of this approach in small infants has even questioned the need of resection itself [7]. In the recent years, thoracoscopy (VATS) has become an increasingly important tool in pediatric surgery and, as technology improves, more technically demanding procedures can be performed in small children [6,8–11].

2. Materials and methods

We retrospectively reviewed the clinical charts of six consecutive patients with congenital lung lesions, which

[☆] Presented at the joint 19th Annual Meeting of the European Association for Cardio-thoracic Surgery and the 13th Annual Meeting of the European Society of Thoracic Surgeons, Barcelona, Spain, September 25–28, 2005.

* Corresponding author. Address: c/Avenida de Valladolid 81, esc. Derecha. 2° C, Madrid 28008, Spain. Tel.: +34 91 5477474
E-mail address: indacano@yahoo.es (I. Cano).

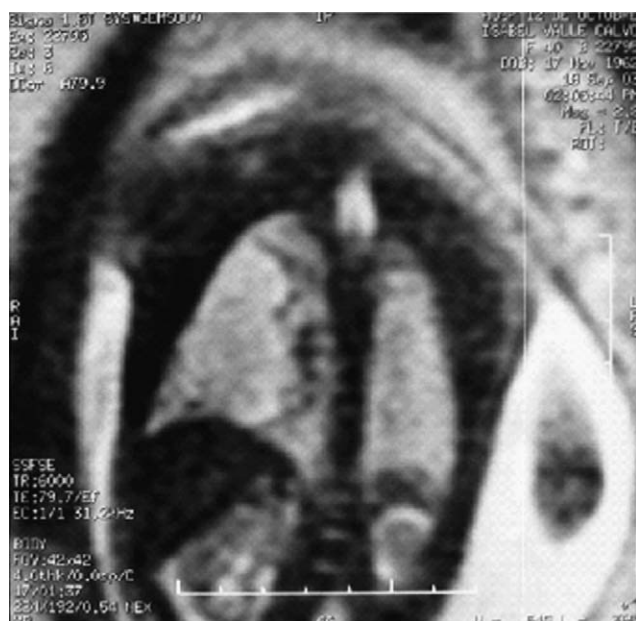


Fig. 1. Fetal nuclear magnetic resonance imaging showing a cystic lesion in the right middle lobe.

underwent VATS resection during 2004 at our institution. All patients were diagnosed prenatally, between week 20 and week 24, by means of ultrasonography and a magnetic resonance imaging was performed in one case (Fig. 1). All children were asymptomatic at birth, without associated anomalies, and were discharged home for follow-up. A thoracic computed tomography (CT) scan was performed soon after birth, showing the prenatally detected lung lesion in all patients. Preoperative diagnosis included five cases of CCAM and one extralobar PS. The thoracoscopic resection was performed at a mean age of 10 months (range, 6–19 months).

2.1. Thoracoscopic technique

The patients were placed in a lateral decubitus position and a single lung ventilation was achieved in all cases by means of contralateral mainstem bronchus intubation. In our room set-up, the surgeon and assistant stood at the child's anterior chest wall facing a single monitor placed in front of the operating surgeon. The first trocar was inserted, with an open technique, in the mid-axillary line through the fifth or sixth intercostal space. This port accommodated the 5-mm, 30° telescope. If complete lung collapse was not achieved by means of selective intubation, induced pneumothorax with a CO₂ flow of 1 l min⁻¹ and a pressure between 4 and 8 mmHg was performed. Two or three additional ports were used, one of which was dedicated to the Ligasure (Valleylab; Boulder, CO, USA), a bipolar sealing device that comes in a 5-mm curved dissector design (Fig. 2). The surgical technique varied depending on the affected lobe and type of malformation. In CCAM patients, the fissure was completed and the lobar vessels were dissected and sealed with the Ligasure device. The bronchus was cut sharply and closed intracorporally with an interrupted suture (Fig. 3). In the only patient with a PS in our series, we used endoclips to secure

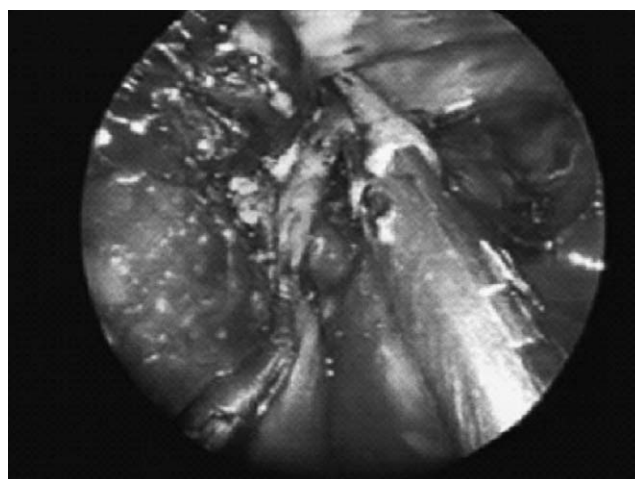


Fig. 2. Vascular control by sealing the lobar vessels with the Ligasure.

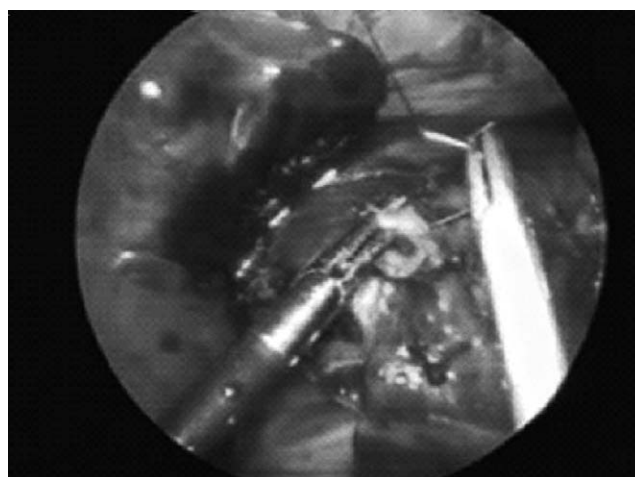


Fig. 3. The bronchus is closed with interrupted sutures.

the systemic arterial aberrant vessel. Once the lobectomy was completed, the upper trocar incision, near the axilla, was lengthened just enough to allow the resected lobe to be withdrawn. No mini-thoracotomy was performed in any case and a chest tube was left in place through a trocar site.

3. Results

There were four boys and two girls. Three lesions were on the left side and three were on the right side. There were five lower lobe and one middle lobe resections. All procedures were completed thoracoscopically. The mean operating time was 130 min (range, 70–215 min). There were no intraoperative complications. Two patients showed significant postoperative chest tube output of blood or blood stained fluid, that stopped spontaneously, and blood transfusion was required in one case. Chest tubes were left in place 1–4 days after the procedure. Postoperative pain was treated with intravenous metamizole for 2 or 3 days. Mean hospital stay

was 7 days (range, 4–9 days). Pathologic examination showed five lobar cystic adenomatoid malformations and one extralobar sequestration. Functional and cosmetic results have been excellent on follow-up (range, 12–18 months).

4. Discussion

The decision to operate on asymptomatic children with congenital lung malformations is controversial. Some authors favor a non-operative attitude considering the risks and eventual complications of a thoracotomy [7], with lung resection, and the possibility of spontaneous resolution in some cases [3,4]. Postnatal imaging studies have shown that regression is rare in the cystic type lesions [5].

Although most patients are asymptomatic at birth, children with CCAM or PS may show symptoms with time because of pulmonary infection or malignant transformation [1]. In our opinion, waiting for infection to occur will only complicate the subsequent surgical procedure and, furthermore, a prolonged period of observation usually results in difficulties to carry out the follow-up. We advocate a short period of survey in the asymptomatic cases, and then a thoracic CT scan should be obtained at 3–6 months of age. If pulmonary lesions are still observed, surgical resection can be recommended as the safest treatment for these patients. At the present time, we perform VATS lobectomy between 6 and 12 months of age in asymptomatic patients, or before if symptoms appear.

The complications and morbidity associated to standard posterolateral thoracotomy are avoided with the thoracoscopic approach [9]. This technique has evolved significantly since the initial descriptions of limited explorations, biopsies, and debridements, made by Rodgers et al. [12] in the 1970s. Current studies in the adult population comparing thoracoscopy and thoracotomy highlight the benefits of VATS in terms of morbidity, pain control, hospital stay, and cosmetic result [13]. The indications of VATS in children are expanding as technology improves, and more technically demanding procedures, such as lobectomies, can now be performed safely and effectively [6,10].

VATS lobectomy in small children poses some unique problems that the surgeon must solve. First, adequate visualization can be achieved with single lung ventilation, the use of valved ports, and creating a low-tension pneumothorax using CO₂ insufflation. Another challenge is controlling the lobe vascular supply. This can be achieved by means of the Ligasure device, which provides a reliable way of sealing the pulmonary vessels in small children [6,10]. Closure of the lobar bronchus did not pose significant problems. Although some authors prefer to clip the bronchi, we favor bronchial closure with interrupted absorbable sutures performed intracorporally. No leaks or broncho-pleural fistulas have developed with this technique.

Despite our limited experience, we think that VATS lobectomy can be a feasible and safe technique in infants and small children. As it happens with other conditions in children, like empyema or recurrent pneumothorax, treated thoracoscopically, reduced postoperative pain, an excellent cosmetic result, and a shorter hospital stay, are definite advantages of VATS. Moreover, the long-term morbidity

(asymmetric chest wall, scoliosis, rib fusion, winged scapula) associated to a formal posterolateral thoracotomy is avoided.

References

- [1] Dell'Agnola C, Tadini B, Mosca F, Colnaghi M, Wesley J. Advantages of prenatal diagnosis and early surgery for congenital cystic disease of the lung. *J Perinat Med* 1996;24:621–31.
- [2] Sauvat F, Michel JL, Benachi A, Emond S, Revillon Y. Management of asymptomatic neonatal cystic adenomatoid malformations. *J Pediatr Surg* 2003;38:548–52.
- [3] MacGillivray TE, Harrison MR, Goldstein RB, Adzick NS. Disappearing fetal lung lesions. *J Pediatr Surg* 1993;28:1321–4.
- [4] Budorick NE, Pretorius DH, Leopold GR, Stamm ER. Spontaneous improvement of intrathoracic masses diagnosed in utero. *J Ultrasound Med* 1992;11:653–62.
- [5] Winters WD, Effmann EL, Nghiem HV, Nyberg DA. Disappearing fetal lung masses: importance of postnatal imaging studies. *Pediatr Radiol* 1997;27:535–9.
- [6] Albanese CT, Sydorak RM, Tsao K, Lee H. Thoracoscopic lobectomy for prenatally diagnosed lung lesions. *J Pediatr Surg* 2003;38:553–5.
- [7] Bal S, Elshershari H, Celiker R, Celiker A. Thoracic sequels after thoracotomies in children with congenital cardiac disease. *Cardiol Young* 2003;13:264–7.
- [8] Rothenberg SS, Chang JHT, Bealer JF. Experience with minimally invasive surgery in infants. *Am J Surg* 1998;176:654–8.
- [9] Rothenberg SS. Thoracoscopic lung resection in children. *J Pediatr Surg* 2000;35:271–5.
- [10] Rothenberg SS. Experience with thoracoscopic lobectomy in infants and children. *J Pediatr Surg* 2003;38:102–4.
- [11] Koontz CS, Oliva V, Gow KW, Wulkan ML. Video assisted thoracoscopic surgical excision of cystic lung disease in children. *J Pediatr Surg* 2005;40:835–7.
- [12] Rodgers BM, Moazaum F, Talbert JL. Thoracoscopy in children. *Ann Surg* 1979;189:176–80.
- [13] Weatherford DA, Stephenson JE, Taylor SM, Blackhurst D. Thoracoscopy versus thoracotomy: indications and advantages. *Am Surg* 1995;61:83–6.

Appendix A. Conference discussion

Dr D. Cohen (Boston, MA, USA): I'm surprised that you handled the bronchus with the suture technique. Were you reluctant to use the stapling device?

And my second question is: why didn't you have an anterior port for access to the artery and vein?

Dr Antón-Pacheco: Well, I'll answer the last question first. We sometimes use a fourth port if we are not comfortable with the three ports. And regarding the other question, we prefer the intracorporeal suture of the bronchus because we don't rely so much on the ligature for bronchus, and the stapling device needs a larger port, more than 5 mm, so we prefer to suture, two stitches, one stitch.

Dr C. Paleru (Bucharest, Romania): Please detail a little bit about the relation of ligature in lung dissection, fissure reconstruction, ligature utilization, when you open the fissure, when you seal the arteries, etc.

Dr Antón-Pacheco: Well, we open the fissure with the Ligasure until we arrive to the lobar vessels. And we go through the fissure and we seal the vessels that go to the affected lobe. So we progress in that direction, and we go, sealing, until we isolate, we dissect the bronchus, and the bronchus is sectioned and sutured.

Dr M. Infante (Milan, Italy): You said you don't do any minithoracotomies. I would like to ask you how you deliver the specimen out?

Dr Antón-Pacheco: Well, we use one of the 5-mm ports. We enlarge a bit the port site and we withdraw the lobe. And we can cut it so that we can withdraw it. It's a benign lesion so there is not any problem.

Dr G. Friedel (Gerlingen, Germany): Could I ask you, you separate the lobe? You draw out the lobe, not completely, the complete lobe?

Dr Antón-Pacheco: The lobe is withdrawn. We try to take it complete through the trocar site, but sometimes we must cut the lobe to extract it completely.

Dr Friedel: With the new ultrasound examination, we see more and more sequestrations in small children. Is sequestration, which is detected by ultrasound that had no symptoms, indication for resection in your opinion?

Dr Antón-Pacheco: Well, that's controversial, and I'm afraid it's not the point of the presentation. But I think with congenital adenomatoid

malformation nearly everybody agree that it's necessary to make the lobectomy because of malignant degeneration or possible infection. With sequestration, well, the risks are probably infection, hemorrhage maybe, not malignant transformation, but in any case we usually operate on them.