

Case report

# Endobronchial ultrasound-guided transbronchial needle aspiration for the treatment of central airway stenosis caused by a mediastinal cyst

Takahiro Nakajima, Kazuhiro Yasufuku<sup>\*</sup>, Kiyoshi Shibuya, Takehiko Fujisawa

*Department of Thoracic Surgery, Graduate School of Medicine, Chiba University, Japan*

Received 23 February 2007; received in revised form 5 June 2007; accepted 11 June 2007; Available online 12 July 2007

## Abstract

Central airway stenosis caused by compression due to mediastinal cyst is rare. Direct real-time endobronchial ultrasound-guided transbronchial needle aspiration (EBUS-TBNA) is a minimally invasive method for tissue sampling of the mediastinum. Using this new therapeutic modality, the mediastinum can be punctured repeatedly and safely under local anesthesia with real-time guidance. Cystic lesions are easily detectable, and the Doppler mode helps to distinguish the cystic lesion from vascular structures. We herein report a rare case of central airway stenosis caused by mediastinal cyst successfully treated by EBUS-TBNA with no regrowth after 1 year. A total of 80 ml of fluid content was aspirated, resulting in patency of the trachea.

© 2007 European Association for Cardio-Thoracic Surgery. Published by Elsevier B.V. All rights reserved.

**Keywords:** Bronchoscopy and interventional techniques; Mediastinal cyst; Central airway stenosis

## 1. Introduction

The management of mediastinal cyst remains controversial. Although most clinicians select thoracotomy or video-assisted thoracic surgery (VATS) to treat mediastinal cyst, these surgical interventions are associated with a risk of various complications. Recent progress with endobronchial ultrasound technology has enabled a better understanding of the mediastinal structure from the internal lumen of the airway. Endobronchial ultrasound-guided transbronchial needle aspiration (EBUS-TBNA) is a new, minimally invasive technique for tissue sampling of the mediastinum using convex-probe EBUS [1–3]. Using this procedure, cystic lesions are easily detectable, and the Doppler mode facilitates differentiation of the cystic lesion from nearby vascular structures. This procedure uses a dedicated 22-gauge needle, which allows peribronchial lesions to be punctured under real-time guidance.

## 2. Case report

A 78-year-old man was referred to our department for work-up of a mediastinal cyst in January 2006. The patient had a surgical history of left thyroid lobectomy for a left

thyroid goiter. Chest computed tomography (CT) showed a low-density mass shadow in the upper mediastinum adjacent to the trachea that extended from the right lobe of the thyroid. EBUS-TBNA with a convex probe equipped with a 7.5-MHz linear probe on its tip (BF-UC260F-OL8; Olympus Ltd., Tokyo, Japan) was performed to diagnose the mass. Serous fluid was aspirated, and cytological examination revealed macrophages without malignant cells, which were suggestive of a bronchogenic cyst.

The patient gradually felt increasing discomfort in his chest and was admitted to our department in June 2006. CT showed a huge mass, 65 mm × 57 mm × 49 mm, compressing the membranous portion of the trachea and causing narrowing of the airway (Fig. 1A). Surgical resection was not performed due to the risk of loss of thyroid and parathyroid function. Cervical aspiration was not possible due to the presence of a large blood vessel next to the cyst. Therefore, EBUS-TBNA was performed to aspirate the fluid inside the cyst and to restore trachea patency. The patient was treated under local anesthesia with mild conscious sedation using 2 mg midazolam. A torose lesion was observed in the membranous portion that caused 80% stenosis of the trachea (Fig. 2A). An EBUS image revealed a homogenous low-echoic mass with multiple septae inside the cyst (Fig. 2B). The convex probe was placed near the torose lesion and EBUS-TBNA was performed to aspirate the fluid from the cyst under real-time guidance. The low-echoic lesion in the first cyst was reduced by aspiration, and eventually collapsed completely (Fig. 2C). After searching for the next cystic lesion, we repeatedly punctured it, which

<sup>\*</sup> Corresponding author. Address: Department of Thoracic Surgery, Graduate School of Medicine, Chiba University, 1-8-1 Inohana, Chuo-ku, Chiba, 260-8670, Japan. Tel.: +81 43 222 7171x5464; fax: +81 43 226 2172.

E-mail address: [kyasufuku@faculty.chiba-u.jp](mailto:kyasufuku@faculty.chiba-u.jp) (K. Yasufuku).

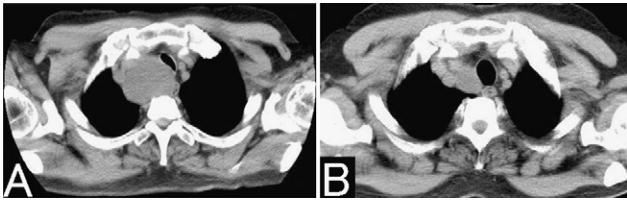


Fig. 1. (A) CT showed a huge mass compressing the trachea in the membranous portion, causing narrowing of the airway. (B) A 1-year follow-up CT showed that following aspiration with EBUS-TBNA, the resulting lesion remained stable, without regrowth of any cystic lesions.

allowed aspiration of 80 ml of serous brown fluid. The patency of the trachea dramatically improved along with immediate relief of dyspnea (Fig. 2D).

The patient has been in a stable condition for 1 year, without any recurrence of cystic lesions on chest CT (Fig. 1B).

### 3. Discussion

Although there have been many reports about the diagnostic utility of EBUS-TBNA [1–3], its use has never been reported in a therapeutic setting. EBUS-TBNA allows visualization of the majority of the mediastinum, comparable to the reach of mediastinoscopy; EBUS-TBNA also has the added benefit of allowing assessment of the middle and posterior mediastinum. In addition, compared to mediastinoscopy, EBUS-TBNA is minimally invasive, can be done quite safely, and can be performed under local anesthesia in an outpatient setting. We have never experienced any complications related to this procedure. In this case, we

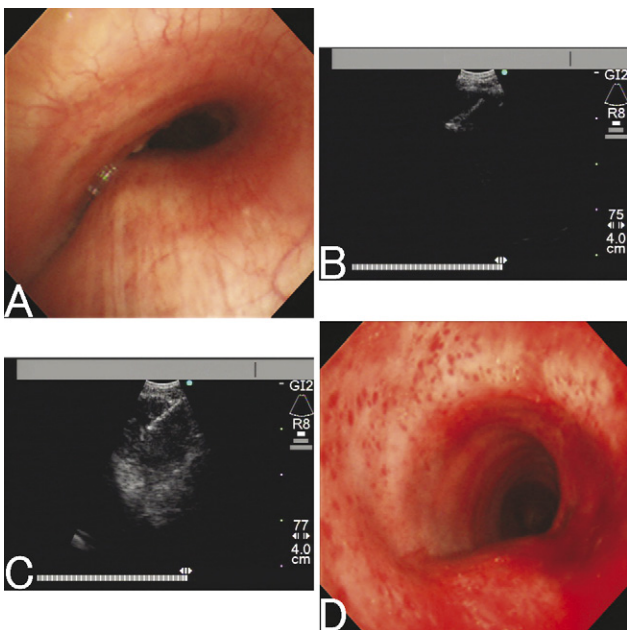


Fig. 2. (A) Bronchoscopic findings showed the torse lesion was observed in the membranous portion, which caused 80% stenosis of the trachea. (B) EBUS image showed a homogenous low-echoic mass. (C) The low-echoic lesion in the first cyst was reduced by aspiration, and ultimately collapsed completely. (D) As a result of aspiration by EBUS-TBNA, the patency of the trachea dramatically improved.

successfully treated a mediastinal cyst by EBUS-TBNA, which resulted in a significant improvement of tracheal stenosis.

Although most mediastinal cysts are asymptomatic, some may induce compression and irritation of adjacent structures thereby causing symptoms, infection, or even malignant degeneration within the cyst [4–5]. Hence, many clinicians emphasize the necessity of early treatment and complete resection by thoracotomy or VATS [4–7]. The recurrence rate is very low following complete resection of a mediastinal cyst, with the most critical step for preventing cyst recurrence being complete resection of the mucosal lining. Thoracotomy or VATS should be the first choice of treatment. However, the complications of surgery and general anesthesia cannot be ignored [8–9], and patients in poor general condition may not be candidates for surgical intervention. Hence, substitute treatments may be considered in some cases of mediastinal cyst. Many successful substitutive treatments, including transbronchial aspiration, transesophageal aspiration, CT-guided or ultrasound-guided percutaneous aspiration, percutaneous aspiration with sclerotherapy, and mediastinoscopic drainage, have been reported for mediastinal cysts. Although these therapies appear to be useful, they have only been used in sporadic case study series with limited follow-up periods ranging from 3 months to 1 year [5]. Further, cyst recurrence may occur following both simple aspiration and incomplete resection [10–11]. Therefore, non-surgical treatments for mediastinal cysts appear to be only palliative [5].

Galluccio et al. recommended endobronchial ultrasonography-guided fine needle aspiration using a radial probe for aspiration of the contents of the cyst [12]. These investigators hypothesized that EBUS enabled deep and complete aspiration of the cyst, resulting in total obliteration of the lining. Since the probe used in radial-probe EBUS is inserted through the working channel of a flexible bronchoscope, its use is limited to real-time therapeutic or diagnostic procedures. Convex-probe EBUS also enables real-time procedures to be performed under ultrasound guidance, and allows deep and complete aspiration, resulting in the collapse of the cyst and adhesion of the mucosal lining. Our study also supports the utility of EBUS for the palliative treatment of mediastinal cysts.

### Acknowledgements

We thank Ms Fumie Saegusa and Mr Fumio Horiuchi for support during the cytological diagnosis. We are also grateful to Dr Matthew Wong for his insightful comments preparing this manuscript.

Written consent was obtained from the patient for publication of the details of his case.

### References

- [1] Yasufuku K, Chiyo M, Koh E, Moriya Y, Iyoda A, Sekine Y, Shibuya K, Iizasa T, Fujisawa T. Endobronchial ultrasound guided transbronchial needle aspiration for staging of lung cancer. *Lung Cancer* 2005;50:347–54.
- [2] Yasufuku K, Nakajima T, Motoori K, Sekine Y, Shibuya K, Hiroshima K, Fujisawa T. Comparison of endobronchial ultrasound, positron emission

- tomography, and CT for lymph node staging of lung cancer. *Chest* 2006;130:710–8.
- [3] Herth FJ, Eberhardt R, Vilmann P, Krasnik M, Ernst A. Real-time endobronchial ultrasound guided transbronchial needle aspiration for sampling mediastinal lymph nodes. *Thorax* 2006;61:795–8.
- [4] Takeda S, Miyoshi S, Minami M, Ohta M, Masaoka A, Matsuda H. Clinical spectrum of mediastinal cysts. *Chest* 2003;124:125–32.
- [5] Patel SR, Meeker DP, Biscotti CV, Kirby TJ, Rice TW. Presentation and management of bronchogenic cysts in the adult. *Chest* 1994;106:79–85.
- [6] St-Georges R, Deslauriers J, Duranceau A, Vaillancourt R, Deschamps C, Beauchamp G, Page A, Brisson J. Clinical spectrum of bronchogenic cysts of the mediastinum and lung in the adult. *Ann Thorac Surg* 1991;52:6–13.
- [7] Cioffi U, Bonavina L, De Simone M, Santambrogio L, Pavoni G, Testori A, Peracchia A. Presentation and surgical management of bronchogenic and esophageal duplication cysts in adults. *Chest* 1998;113:1492–6.
- [8] Martinod E, Pons F, Azorin J, Mouroux J, Dahan M, Faillon JM, Dujon A, Lajos PS, Riquet M, Jancovici R. Thoracoscopic excision of mediastinal bronchogenic cysts: results in 20 cases. *Ann Thorac Surg* 2000;69:1525–8.
- [9] Zambudio AR, Lanzas JT, Calvo MJ, Fernandez PJ, Paricio PP. Non-neoplastic mediastinal cysts. *Eur J Cardiothorac Surg* 2002;22:712–6.
- [10] van Beers B, Trigaux JP, Weynants P, Collard JM, Melange M. Foregut cyst of the mediastinum: fluid re-accumulation after transbronchial needle aspiration. *Br J Radiol* 1989;62:558–60.
- [11] Read CA, Moront M, Carangelo R, Holt RW, Richardson M. Recurrent bronchogenic cyst. An argument for complete surgical excision. *Arch Surg* 1991;126:1306–8.
- [12] Galluccio G, Lucantoni G. Mediastinal bronchogenic cyst's recurrence treated with EBUS-FNA with a long-term follow-up. *Eur J Cardiothorac Surg* 2006;29:627–9.