

Case report

A rare constellation of empyema, lung abscess, and mediastinal abscess as a complication of endobronchial ultrasound-guided transbronchial needle aspiration

Chun-Ta Huang^a, Chung-Yu Chen^a, Chao-Chi Ho^{b,*}, Chong-Jen Yu^b^a Department of Internal Medicine, National Taiwan University Hospital, Yun-Lin Branch, Yunlin, Taiwan^b Department of Internal Medicine, National Taiwan University Hospital, Taipei, Taiwan

Received 28 September 2010; accepted 15 November 2010; Available online 22 December 2010

Abstract

The introduction of endobronchial ultrasound-guided transbronchial needle aspiration (EBUS-TBNA) brought about significant advancement in the field of bronchoscopy. The major indications for EBUS-TBNA are lung cancer staging and diagnosis of mediastinal lymphadenopathy. This procedure is minimally invasive and cost saving, and no complications have been described in large-scale studies. In this report, we present a case of empyema, lung abscess, and mediastinal abscess that developed in a patient undergoing EBUS-TBNA; the patient subsequently recovered uneventfully after aggressive surgical debridement and antimicrobial therapy.

© 2010 European Association for Cardio-Thoracic Surgery. Published by Elsevier B.V. All rights reserved.

Keywords: Abscess; Empyema; Endobronchial ultrasound; Transbronchial needle aspiration

1. Introduction

Endobronchial ultrasound-guided transbronchial needle aspiration (EBUS-TBNA) is a minimally invasive method for investigating the mediastinum for staging of non-small-cell lung cancer and for diagnosing mediastinal lesions accessible via the major airway. This procedure has a high diagnostic value and avoids the general anesthesia that is required for mediastinoscopy. In addition, no complications of this procedure were reported in large-scale studies [1].

We report herein a case of serious and uncommon infective complication after EBUS-TBNA and discuss associated issues.

2. Case report

A 68-year-old man was admitted to a university-affiliated hospital with symptoms, including anorexia, malaise, and shortness of breath, persisting since 10 days.

The patient's history was remarkable for diabetes and hepatitis B virus-related hepatocellular carcinoma (HCC). The patient had undergone four sessions of trans-arterial chemoembolization for HCC. However, routine follow-up

abdominal computed tomography (CT) performed 2 months before presentation showed recurrence of HCC, and a chest radiograph obtained then revealed increased right paratracheal opacity. Chest CT demonstrated a hypodense nodule near the trachea (Fig. 1(A)), and EBUS-TBNA was performed to determine its exact nature. Many specimens were retrieved, and the patient tolerated the procedure well. Cytological examination by cell block analysis of the TBNA specimens revealed that the lesion was a metastatic HCC. The patient received the best supportive care thereafter.

On admission, chest auscultation revealed inspiratory crackles in the right upper lung field, and laboratory tests revealed the white blood cells count to be $12.1 \times 10^9 \text{ l}^{-1}$ (neutrophils 83% and lymphocytes 9%) and serum level of C-reactive protein to be 8.2 mg dl^{-1} . The chest radiograph showed progressively enlarged right paratracheal opacity and newly developed opacity in the right upper lobe. Unexpectedly, loculated right pleural effusion, abscess in the right upper lobe, and multiloculated mediastinal abscess were found on chest CT (Fig. 1(B) and (C)). The patient was treated with broad-spectrum antibiotics and referred for surgical debridement. Intra-operative findings included fibropurulent fluid in the pleural cavity, lung parenchyma, and mediastinum. Pathological examination of the debrided tissue revealed fibrinous debris, necrotic tissue, and neutrophil aggregation. *Streptococcus viridans* was isolated from multiple culture specimens of the debridement material. The patient was smoothly weaned from mechanical

* Corresponding author at: Department of Internal Medicine, National Taiwan University Hospital, 7 Chung-Shan South Rd, Taipei 100, Taiwan.
Tel.: +886 2 23562905; fax: +886 2 23582867.

E-mail address: ccho1203@ntu.edu.tw (C.-C. Ho).

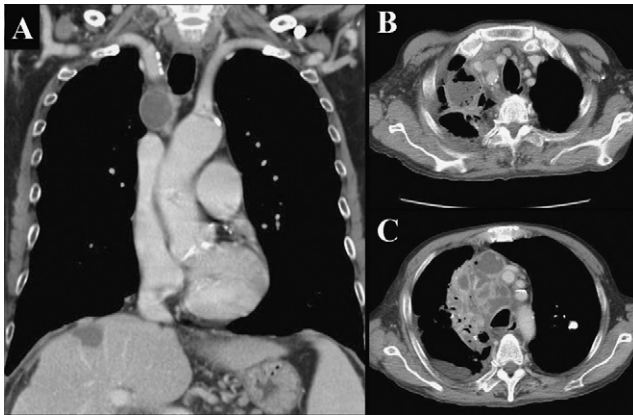


Fig. 1. (A) Chest CT before bronchoscopy showing a hypodense nodule near the trachea. (B and C) Chest CT one day after admission showing loculated right pleural effusion, abscess in the right upper lobe, and multiloculated mediastinal abscess.

ventilation on the 7th postoperative day and was discharged 10 more days later under oral antibiotic treatment.

3. Discussion

One of the attractive features of EBUS-TBNA has been the lack of reported complications; however, a complication rate of 0% for a novel procedure implies that the procedure has been performed only in an insufficient number of cases and, therefore, information about the rate of complications is unavailable. Two recently published case studies demonstrated infective complications after EBUS-TBNA [2,3]. The case presented herein was considered to have widespread intrathoracic infection caused by EBUS-TBNA based on the following reasons: (1) radiographic evidence of the progression of the mediastinal lesion shortly after the procedure; (2) temporal relationship between infection and the procedure; and (3) the rare simultaneous occurrence of empyema, lung abscess, and mediastinal abscess, suggesting a complication of invasive procedures. Taken together, these cases indicate that EBUS-TBNA is not free from complications, and bronchoscopists should be aware of potential procedure-related infection.

We concur with the opinion of Haas that infection is introduced by direct inoculation of oral commensals into the target structures while repeatedly manipulating the aspiration needle through the working channel of the bronchoscope [3]. In line with this theory of pathogenesis, *S. viridans*, a common contaminant of the oropharynx, was identified as the culprit pathogen in the present case. Recent study has also demonstrated that contamination of the TBNA needle with oropharyngeal flora is a common event during EBUS-TBNA and may predispose patients to focal infection at the

site of TBNA puncture [4]. The same study found that bacteremia following TBNA was not uncommon [4]; however, the infection in our patient was unlikely to be caused by hematogenous seeding due to bacteremia because of the absence of other infection foci, the spread of infection into adjacent anatomical structures, and the absence of positive blood cultures. *S. viridans* is normally considered to be of low virulence, but it can occasionally cause serious infection [5]. Accordingly, while treating infective complications in such cases, antimicrobial agents with activity against oral and nasopharyngeal organisms should be empirically used.

Unlike the previous reports, in the present case, the patient did not develop fever during the clinical course; further, this patient had the largest extent of intrathoracic infection. Patients in a chronically debilitated state may not be able to evoke a systemic inflammatory response, especially infected with low-virulence *S. viridans*. This leads to a smoldering process, and the infection spread insidiously and widely. Therefore, such patients should be closely monitored for infection symptoms after EBUS-TBNA, and imaging studies used judiciously to detect early signs of infection.

With the increasing use of EBUS-TBNA worldwide, it is anticipated that more and more infective complications will be reported; this will help resolve several unanswered questions, regarding such complications, including the susceptible hosts, procedure-related risk factors, true incidence, exact pathogenesis, involved pathogens, appropriate antimicrobial therapy and surgical intervention, and outcomes. Complications encountered at present should be managed on a case-by-case basis.

The present case reinforces the existence of serious infective complications of EBUS-TBNA. The infection is presumably due to cross-contamination that leads to inoculation of oral and nasopharyngeal commensals into the mediastinum. Empirical antimicrobial therapy in patients with such infection should include agents active against these indigenous organisms. Each patient should be closely monitored for the development of signs and symptoms of infection following EBUS-TBNA.

References

- [1] Varela-Lema L, Fernandez-Villar A, Ruano-Ravina A. Effectiveness and safety of endobronchial ultrasound-transbronchial needle aspiration: a systematic review. *Eur Respir J* 2009;33:1156–64.
- [2] Parker KL, Bizakis CS, Zervos MD. Severe mediastinal infection with abscess formation after endobronchial ultrasound-guided transbronchial needle aspiration. *Ann Thorac Surg* 2010;89:1271–2.
- [3] Haas AR. Infectious complications from full extension endobronchial ultrasound transbronchial needle aspiration. *Eur Respir J* 2009;33:935–8.
- [4] Steinfert DP, Johnson DF, Irving LB. Incidence of bacteraemia following endobronchial ultrasound-guided transbronchial needle aspiration. *Eur Respir J* 2010;36:28–32.
- [5] Jerng JS, Hsueh PR, Teng LJ, Lee LN, Yang PC, Luh KT. Empyema thoracis and lung abscess caused by viridans streptococci. *Am J Respir Crit Care Med* 1997;156:1508–14.