

Cite this article as: Chen X, Li Q-p, Ji G-z, Ge X-x, Zhang X-h, Zhao X-y *et al.* Two-year follow-up for 45 patients with achalasia who underwent peroral endoscopic myotomy. *Eur J Cardiothorac Surg* 2015;47:890–6.

## Two-year follow-up for 45 patients with achalasia who underwent peroral endoscopic myotomy

Xia Chen<sup>a</sup>, Quan-peng Li<sup>a</sup>, Guo-zhong Ji<sup>a</sup>, Xian-xiu Ge<sup>a</sup>, Xiu-hua Zhang<sup>a</sup>, Xiang-yang Zhao<sup>b</sup> and Lin Miao<sup>a,\*</sup>

<sup>a</sup> The Medical Center for Digestive Diseases, the Second Affiliated Hospital of Nanjing Medical University, Digestive Endoscopy Institute, Nanjing Medical University, Nanjing, China

<sup>b</sup> The Digestive Department, Lishui County People's Hospital, Nanjing, Jiangsu, China

\* Corresponding author. The Medical Center for Digestive Diseases of the Second Affiliated Hospital of Nanjing Medical University, 121 Jiang Jiayuan, Nanjing 210011, China. Tel: +86-189-51762836; fax: +86-25-58509931; e-mail: zhanghaoran010115@aliyun.com (L. Miao).

Received 2 April 2014; received in revised form 9 June 2014; accepted 19 June 2014

### Abstract

**OBJECTIVES:** Achalasia is an oesophageal disorder characterized by abnormalities of peristalsis and impaired swallowing-induced relaxation. The therapeutic approach at present remains palliative. Peroral endoscopic myotomy (POEM) is thought to be less invasive and to maintain the function of the lower oesophageal sphincter postoperatively. However, the effects of POEM still need to be evaluated and understood.

**METHODS:** We analysed the outcome for 45 achalasia patients who underwent POEM in our centre, described the details of surgery and evaluated the effects by 4 s integrated relaxation pressure (4s-IRP). All patients were followed up for at least 2 years and were assessed by the dysphagia score, the Eckardt score, oesophageal manometry and the gastro-oesophageal reflux disease (GERD) Q-questionnaire. According to the new Chicago classification of oesophageal motility using high-resolution manometry, the patients were diagnosed and classified into types I, II and III.

**RESULTS:** The average age of the patients was  $46.32 \pm 19.04$  years (range 26–72 years), and the ratio of women to men was 1.81. All patients were suffering from dysphagia; more than half of them experienced regurgitation. The data revealed that POEM considerably reduced the 4s-IRP, dysphagia score and Eckardt score postoperatively (all  $P < 0.05$ ). The patients with type III achalasia had higher values of 4s-IRP than the others (type I,  $P = 0.025$ ; type II,  $P = 0.022$ ) before treatment and at 3 months after treatment (type I,  $P = 0.028$ ; type II,  $P = 0.047$ ). In type I patients, GERD symptoms were more likely to appear at 24 months after POEM than in type II and III patients ( $P = 0.001$  and  $P < 0.001$ , respectively).

**CONCLUSIONS:** Peroral endoscopic myotomy provides definite relief of symptoms in these patients with achalasia and offers them long-term therapeutic benefit. Considering the risks of surgery, we believe that POEM is a better choice than surgery for achalasia patients and carries lower risk. However, our study is a preliminary exploration; therefore, larger-scale studies are needed for further research on POEM.

**Keywords:** Achalasia • Peroral endoscopic myotomy • High-resolution manometry • Integrated relaxation pressure

### INTRODUCTION

Achalasia is an oesophageal disorder of unknown aetiology, characterized by abnormalities of peristalsis and impaired swallowing-induced relaxation. Its incidence is about 0.5–1 per 100 000 per year, without any difference in symptoms depending on age or gender. Clinical signs include dysphagia, retrosternal pain, regurgitation of food and weight loss [1, 2]. High-resolution manometry (HRM) with analysis of the oesophageal pressure topography has great sensitivity for achalasia, enabling the details to be measured and reducing the movement artifact created by oesophageal shortening. Based on the presence of contractile activity and pressurization, achalasia is divided into three subtypes [3]; type I is characterized by absence of contractile activity and absence of pressurization, type II by swallowing-induced pan-oesophageal pressurization and type III by spastic contractile activity. Conventional treatments include drugs, pneumatic dilatation,

endoscopic botulinum toxin injection or surgical therapy. All these therapeutic approaches provide palliative care, and there is little improvement in motor abnormalities of the oesophageal body.

Peroral endoscopic myotomy (POEM) was first applied to treat achalasia by Inoue *et al.* [4] in 2010. Since that time, it has been thought to provide some advantages, in that it is less invasive than the other available options and better at maintaining the function of the lower oesophageal sphincter [5]. However, the effects of POEM on patients with achalasia still need to be evaluated and understood.

In this study, we carried out a respective review of 45 achalasia patients who underwent POEM in our centre. We analysed their clinical features and followed up every patient for at least 2 years in order to assess the changes after POEM. Our aim was to evaluate the early outcomes of POEM and long-term effects on patients with achalasia and to judge whether this technique is acceptable as a less invasive and effective alternative to traditional treatments.

## PATIENTS AND METHODS

### Patients

Between December 2010 and February 2014, 45 patients with achalasia who underwent POEM in our centre were selected for our study. Based on the new Chicago classification on HRM, the patients were diagnosed and classified into types I, II and III. All patients provided written consent. The protocols were approved by the Second Affiliated Hospital of Nanjing Medical University Institutional Ethics Committee.

### Oesophageal manometry

The patients underwent HRM (Given Imaging, Los Angeles, CA, USA) before procedures and at 3, 6, 12, 18 and 24 months post-operatively. The study was carried out using 36 circumferential sensors spaced at 1 cm intervals. The measurements included basal lower oesophageal sphincter pressure and 10 swallows of 5 ml of water. All manometric analyses were carried out using MMS software (Mano View software; Sierra Scientific Instruments Inc., Los Angeles, CA, USA) as previously described [6]. The 4 s integrated relaxation pressure (4s-IRP) was adopted as one of the observation indexes to evaluate the effects of treatment. The type of achalasia was classified according to the Chicago classification based on the analysis of distal oesophageal pressurization using the pressurization front velocity in the distal oesophageal segment [7].

### Peroral endoscopic myotomy operation

Based on the procedure described in previous studies [4] and our own animal studies (unpublished data), we performed POEM following the steps (Fig. 1):

- (i) Incision of the oesophageal mucosa. Submucosal injection (a mixture of methylene blue and saline) was performed 10–12 cm above the gastro-oesophageal junction in the right posterior wall of the oesophagus. Using a hook knife, a vertical incision approximately 2 cm in length was made in the mucosal layer to expose the submucosa.
- (ii) Tunnelling by endoscopic submucosal dissection. Dissection was performed from top to bottom along the submucosa of the oesophagus and extended to approximately 3 cm below the gastro-oesophageal junction into the gastric fundus using a hook knife to create a submucosal tunnel.
- (iii) Endoscopic myotomy of the circular muscle. A vertical incision of the circular muscle was made under a gastroscopy-based view from the top down, from 8–10 cm above the gastro-oesophageal junction to 2 cm below the gastro-oesophageal junction using an Insulated-tip diathermic knife. During the myotomy, all shallow and deep circular muscle bundles were cut off, as described the longitudinal muscle bundle was preserved as far as possible, and the transparent cap breaking the longitudinal muscle was avoided. Any bleeding was immediately controlled with electrocoagulation.
- (iv) Closure of mucosal incision with metal clips. After the wound had been washed and bleeding well controlled, metal clips were used to suture the mucosal incision.
- (v) A gastrointestinal decompression tube was placed under gastroscopy.

The patients were fasted after POEM. The tube was removed 2–4 days later, and a liquid diet was administered for 2–4 days, respectively. Any complications were controlled with standardized processes.

### Follow-up

The duration of follow-up for every patient was at least 2 years after POEM. Symptoms were assessed in all patients using the dysphagia score, the Eckardt score and the gastro-oesophageal reflux disease (GERD) Q-questionnaire, as described in previously published articles [5, 8, 9] (Table 1). The assessment of GERD Q-score was carried out when the patients had not taken a proton pump inhibitor for at least 3 days.

### Statistical analysis

Statistical analysis was performed using SPSS 13.0. The results are expressed as means  $\pm$  standard deviation; one-way ANOVA and general linear model repeated-measures analysis were used as needed, and a *P* value of  $<0.05$  was considered to be significant.

## RESULTS

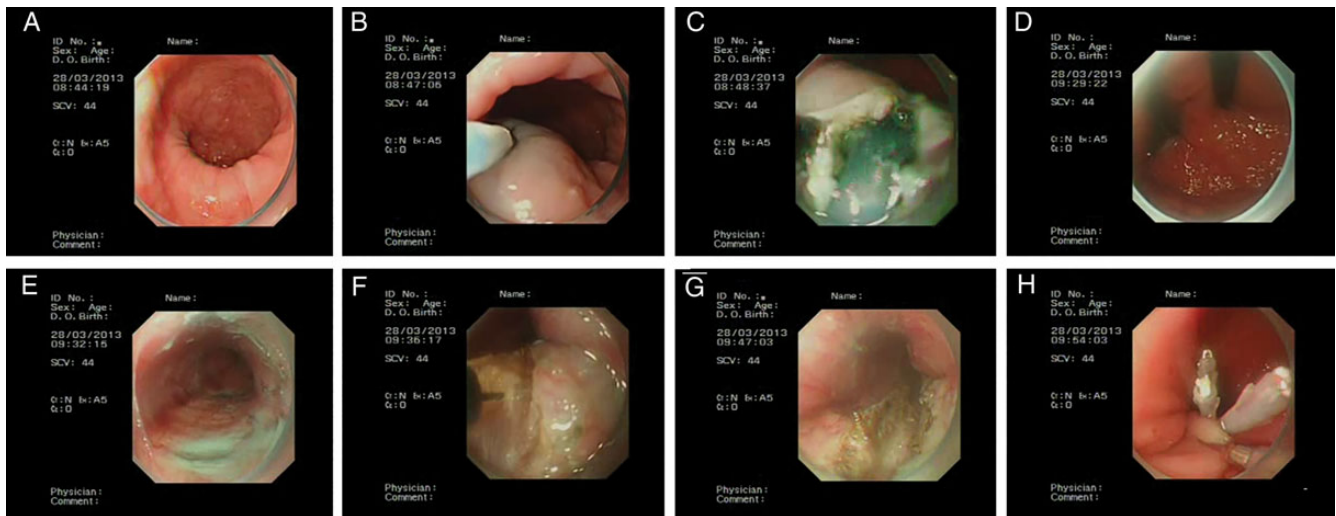
### Patient characteristics

Between January 2010 and December 2013, 45 patients with achalasia (16 men and 29 women) were admitted for POEM in the Second Affiliated Hospital of Nanjing Medical University. Patients mainly resided in Jiangsu province, Anhui province, Zhejiang province or Shandong province.

The average age of the patients was  $46.32 \pm 19.04$  years (range 26–72 years); 29 were women, and the ratio of women to men was 1.81 ( $n = 16$ ). All patients were suffering from dysphagia, more than half of them experienced regurgitation ( $n = 23$ , 51.11%), and 16 (25.56%) experienced chest pain and 6 (13.33%) weight loss. Only 9 patients (20.00%) had respiratory complications, mainly presenting as a nocturnal cough and aspiration. Among the 45 patients, 14 were classified as type I, 24 as type II and 7 as type III (Table 2).

### Outcomes of peroral endoscopic myotomy

Some patients had previously undergone pneumatic dilatation and experienced recurrent dysphagia. We excluded the patients who had experienced endoscopic botulinum toxin injection and stenting for safety reasons. All of the POEMs were successfully performed without any deaths. The mean duration of the procedure was  $73.78 \pm 24.22$  min. The mean length of the submucosal tunnel created was  $13.00 \pm 1.37$  cm and the average length of myotomy  $9.56 \pm 1.53$  cm. The mean visual analog scale pain score was  $7.18 \pm 1.11$  on postoperative day 1, which decreased significantly to  $2.24 \pm 0.68$  at discharge ( $P < 0.001$ ; Table 3).



**Figure 1:** (A) Appearance of the dilated and distorted oesophagus. (B) A submucosal injection (a mixture of methylene blue and saline) was made 10–12 cm above the gastro-oesophageal junction in the right posterior wall of the oesophagus. (C) A vertical incision approximately 2 cm in length was made in the mucosal layer using a hook knife to expose the submucosa. (D) Dissection was carried out using a hook knife from top to bottom along the submucosa of the oesophagus and extended to approximately 3 cm below the gastro-oesophageal junction into the gastric fundus. (E) Creation of a submucosal tunnel. (F) Endoscopic myotomy of the circular muscle. (G) During the myotomy, all shallow and deep circular muscle bundles were cut off, as described the longitudinal muscle bundle was preserved as far as possible, and the transparent cap breaking the longitudinal muscle was avoided. Any bleeding was immediately controlled by electrocoagulation. (H) Closure of the mucosal incision with metal clips.

**Table 1:** Severity of dysphagia as assessed by the dysphagia score and the Eckardt score

Dysphagia score				
Grade				
0	Able to eat normal diet/no dysphagia			
1	Able to swallow some solid foods			
2	Able to swallow only semi-solid food			
3	Able to swallow liquids only			
4	Unable to swallow anything/total dysphagia			
Eckardt score	Weight loss (kg)	Dysphagia	Retrosternal pain	Regurgitation
0	None	None	None	None
1	<5	Occasional	Occasional	Occasional
2	5–10	Daily	Daily	Daily
3	>10	Each meal	Each meal	Each meal

**Complications**

In the early stage of this study (at 6 months), there were 5 cases (13.33%) with complications presenting during the operations: 2 cases with junctional flap perforation, 2 with emphysema and 1 with bleeding. All these complications were controlled via endoscopy, without surgical intervention. There were no further complications during the remainder of the study.

**Follow-up**

We followed up these 45 patients for 2 years; the rates of follow-up for POEM were therefore 100%. Postoperatively, we measured dysphagia scores, Eckardt scores, the values of 4s-IRP and GERD Q-scores.

Prior to POEM, the dysphagia scores were  $3.50 \pm 0.52$ ,  $3.79 \pm 0.41$  and  $3.43 \pm 0.53$  in the groups of type I, II and III patients, respectively. They were  $0.64 \pm 0.50$ ,  $0.67 \pm 0.48$  and  $0.71 \pm 0.49$ , respectively, at 3 months after POEM. The scores were respectively  $0.86 \pm 0.36$ ,  $0.83 \pm 0.38$  and  $0.86 \pm 0.38$  at 6 months,  $0.93 \pm 0.47$ ,  $1.00 \pm 0.66$  and  $0.85 \pm 0.38$  at 12 months,  $1.0 \pm 0.63$ ,  $1.08 \pm 0.50$  and  $1.29 \pm 0.49$  at 18 months and  $1.2 \pm 0.43$ ,  $1.13 \pm 0.54$  and  $1.29 \pm 0.49$  at 24 months after POEM. No differences between the three groups ( $P=0.778$ ) were found. All patients who underwent POEM experienced less pronounced symptoms of dysphagia after treatment than before (all  $P < 0.05$ ). We did not observe any difference between 6 and 12 months ( $P=0.424$ ), between 12 and 18 months ( $P=0.106$ ) or between 18 and 24 months ( $P=0.079$ ) after POEM (Fig. 2).

The Eckardt scores were  $6.64 \pm 1.08$ ,  $6.23 \pm 1.06$  and  $6.14 \pm 0.90$  before POEM in the type I, II and III groups, respectively; the scores were, respectively,  $1.21 \pm 0.70$ ,  $0.79 \pm 0.69$  and  $0.71 \pm 0.65$  at

3 months,  $1.07 \pm 0.62$ ,  $0.88 \pm 0.74$  and  $0.71 \pm 0.69$  at 6 months,  $1.49 \pm 0.76$ ,  $1.00 \pm 0.88$  and  $0.86 \pm 0.69$  at 12 months,  $1.57 \pm 0.76$ ,  $1.25 \pm 0.79$  and  $0.86 \pm 0.69$  at 18 months and  $2.00 \pm 0.68$ ,  $2.08 \pm 0.83$ ,  $2.00 \pm 0.82$  at 24 months after POEM. No difference were found in the three groups ( $P=0.061$ ). The patients had higher scores before treatment than after treatment (all  $P < 0.05$ ). We also did not observe any difference between 3 and 6 months ( $P=0.688$ ), 3 and 12 months ( $P=0.106$ ) or 12 and 18 months ( $P=0.123$ ) after POEM (Fig. 3).

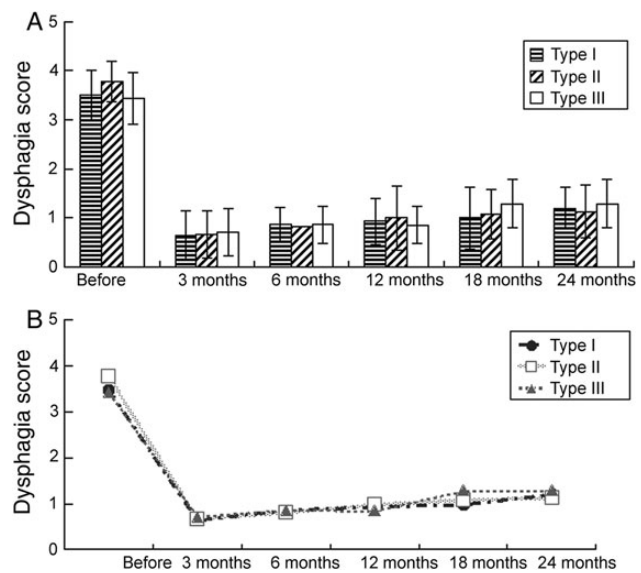
Prior to POEM, the values of 4s-IRP were  $23.81 \pm 5.03$ ,  $24.10 \pm 5.26$  and  $29.82 \pm 4.57$  in the of type I, II and III patients, respectively; the scores were  $10.54 \pm 1.27$ ,  $11.07 \pm 1.53$  and  $13.70 \pm 7.10$  at 3 months,  $11.24 \pm 1.83$ ,  $11.13 \pm 1.17$  and  $11.77 \pm 1.58$  at 6 months,  $10.61 \pm 1.89$ ,  $11.21 \pm 1.68$  and  $11.33 \pm 1.48$  at 12 months,  $11.37 \pm 1.53$ ,  $11.30 \pm 1.54$  and  $11.74 \pm 1.07$  at 18 months and  $11.09 \pm 1.51$ ,  $11.08 \pm 1.38$  and  $10.94 \pm 1.19$  at 24 months after POEM. Type III patients had a higher value than type I and II ( $P=0.025$ ,  $P=0.022$ ) before treatment; we also found the differences at 3 months after treatment (type I,  $P=0.028$ ; type II,  $P=0.047$ ). The significant differences were observed in the three type groups at various times ( $P=0.001$ ). Different types of achalasia had different responses to POEM; however, all patients had lower scores after treatment than before (all  $P < 0.05$ ). We did not find any

differences between the values at 3, 6, 12, 18 and 24 months after the procedure (Fig. 4).

During the follow-up period, three (6.67%) patients needed a standard-dose of proton pump inhibitor to control symptoms of GERD. Before POEM, the GERD Q-scores of the groups of type I, II and III patients were, respectively,  $1.93 \pm 0.73$ ,  $1.75 \pm 0.79$  and  $2.00 \pm 0.58$ ; after POEM the scores were, respectively,  $2.14 \pm 0.53$ ,  $2.17 \pm 0.48$  and  $2.14 \pm 0.38$  at 3 months,  $2.86 \pm 1.03$ ,  $2.83 \pm 0.96$  and  $3.14 \pm 1.21$  at 6 months,  $2.93 \pm 1.07$ ,  $2.67 \pm 1.37$  and  $3.00 \pm 1.15$  at 12 months,  $3.57 \pm 1.28$ ,  $3.33 \pm 1.17$  and  $2.71 \pm 1.25$  at 18 months and  $5.14 \pm 1.79$ ,  $3.71 \pm 0.91$  and  $2.71 \pm 0.76$  at 24 months. Type I patients were more prone to the appearance of GERD symptoms at 24 months after POEM than type II and III patients ( $P=0.001$  and  $P < 0.001$ , respectively). Apart from the lack of change between 6 and 12 months ( $P=0.768$ ), 6 and 18 months ( $P=0.257$ ) or 12 and 18 months ( $P=0.179$ ), the scores were all different at other times (all  $P < 0.05$ ; Fig. 5).

**Table 2:** Clinical and epidemiological features

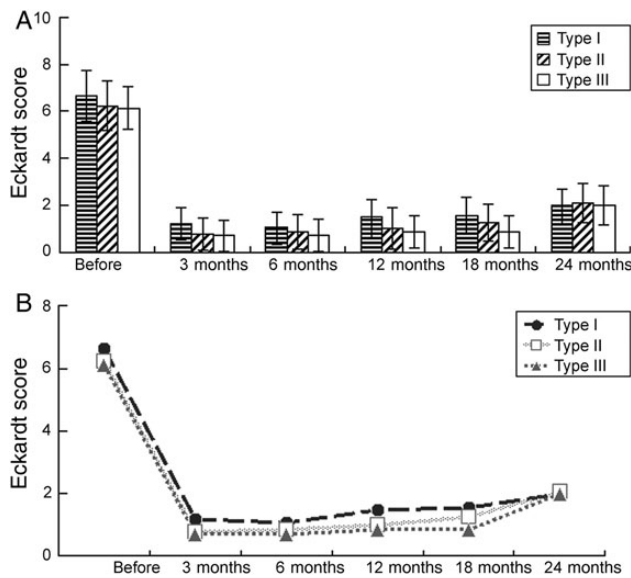
Characteristic	n (%)
Gender	
Male	16 (35.56)
Female	29 (64.44)
Age (years; mean $\pm$ SD)	46.32 $\pm$ 19.04 (range 26–72)
Clinical manifestation	
Duration of symptoms (years; mean $\pm$ SD)	12.68 $\pm$ 9
Dysphagia	45
Regurgitation	23 (51.11%)
Chest pain	16 (25.56%)
Weight loss	6 (13.33%)
Respiratory complications (nocturnal cough and aspiration)	9 (20.00%)
Classification	
Type I	14 (31.11%)
Type II	24 (53.33%)
Type III	7 (15.56%)



**Figure 2:** (A) Results of dysphagia scores analysed by one-way ANOVA. There was no difference between the three groups at any time point (all  $P > 0.05$ ). (B) Results of dysphagia scores with general linear model repeated-measures analysis. There was no difference between the three groups ( $P=0.778$ ). All scores were lower after treatment than before (all  $P < 0.05$ ), but no difference was observed between 6 and 12 months ( $P=0.424$ ), between 12 and 18 months ( $P=0.106$ ) or between 18 and 24 months after peroral endoscopic myotomy (POEM;  $P=0.079$ ).

**Table 3:** Operative outcomes of peroral endoscopic myotomy

n	Type (high-resolution manometry)	History of endoscopic therapy (pneumatic dilatation)	Duration of procedure (min)	Length of submucosal tunnel (cm)	Length of myotomy (cm)	Complications (n)	Visual analog scale pain score, 1 day postoperative	Visual analog scale pain score at discharge
14	I	3	76.07 $\pm$ 29.23	12.93 $\pm$ 1.38	9.64 $\pm$ 1.45	1	7.36 $\pm$ 1.01	2.14 $\pm$ 0.66
24	II	6	75.63 $\pm$ 22.76	12.96 $\pm$ 1.43	9.50 $\pm$ 1.64	2	7.08 $\pm$ 1.14	2.21 $\pm$ 0.72
7	III	1	62.86 $\pm$ 17.29	13.28 $\pm$ 1.25	9.57 $\pm$ 1.51	2	7.14 $\pm$ 1.35	2.57 $\pm$ 0.53
Total 45		10 (22.22%)	73.78 $\pm$ 24.22 $P > 0.05$	13.00 $\pm$ 1.37 $P > 0.05$	9.56 $\pm$ 1.53 $P > 0.05$	5 (11.11%)	7.18 $\pm$ 1.11 $P > 0.05$	2.24 $\pm$ 0.68 $P < 0.001$



**Figure 3:** (A) Results of Eckardt scores analysed by one-way ANOVA. There was no difference between the three groups at any time point (all  $P > 0.05$ ). (B) Results of Eckardt scores with general linear model repeated-measures analysis. No differences were found between the three groups ( $P = 0.061$ ). The patients had higher scores before than after treatment (all  $P < 0.05$ ). We did not observe any difference between 3 and 6 months ( $P = 0.688$ ), 3 and 12 months ( $P = 0.106$ ) or 12 and 18 months after POEM ( $P = 0.123$ ).

## DISCUSSION

Achalasia is described as a primary oesophageal motor disorder of unknown aetiology, whose current treatment is palliative and intended to reduce oesophageal sphincter pressure. Drugs have limited usefulness in clinical practice and are not considered as a therapeutic measure. Endoscopic injection of botulinum toxin, pneumatic dilatation and stent placement in the oesophagus may initially produce excellent or good results in patients, but their effects are not positive in long-term follow-up studies [10]. In some articles [11, 12] these endoscopic interventions have been compared with surgery, but the findings are difficult to interpret due to patient heterogeneity and the use of different surgical techniques. Gastroenterologists [13–15] insist that surgery is an important option in patients refractory to treatment and in younger patients, but endoscopy is often cited as the primary therapeutic approach. There is still argument about the most appropriate treatment for patients with achalasia.

Peroral endoscopic myotomy is a novel approach to performing oesophageal myotomy through a long submucosal tunnel. As reported by some researchers [4, 16], POEM is an effective method to settle the impaired swallowing-induced relaxation with less invasion than surgery. However, the new technique is not well known. Until now, studies have focused on the details of the operation, rarely on its effects and especially its long-term effects. We followed up 45 patients who underwent POEM in our centre over a 2-year period. To determine the effects of POEM, we looked for differences between the initial effects and the long-term outcome, assessed by the dysphagia score, Eckardt score and GERD Q-questionnaire.

For all 45 patients included in our study, the dysphagia scores and Eckardt scores (which are the standards by which the clinical severity of dysphagia is judged in patients with achalasia) decreased,

and the IRP of the lower oesophageal sphincter was lower than before endoscopic interventions in these patients. The aim of all treatments for achalasia is to reduce the pressure of the lower oesophageal sphincter, in order to improve oesophageal emptying and prevent the development of megaesophagus [17]. According to published studies [18, 19], surgery that combines oesophagogastric extra-mucosal myotomy with fundoplication seems to be the best choice for achalasia, because it is more effective than pneumatic dilatation, endoscopic injection of botulinum toxin or oesophageal stent placement in the long term. Considering that the oesophageal sphincter is disrupted in a similar manner by POEM, this treatment should have the same applicability as surgery.

The IRP is a more complex measurement of deglutitive oesophagogastric junction relaxation than the end-expiratory nadir pressure. Unlike conventional manometric methods, IRP exhibits 98% sensitivity and 96% specificity for distinguishing achalasia patients from control subjects and patients with other diagnoses [20]. In fact, IRP has proved to be an exact metric to differentiate intact from impaired oesophagogastric junction relaxation [21]. We chose 4s-IRP as the measure in the study because 4s-IRP is much better in terms of sensitivity and specificity than other indexes for diagnosing and following up achalasia patients.

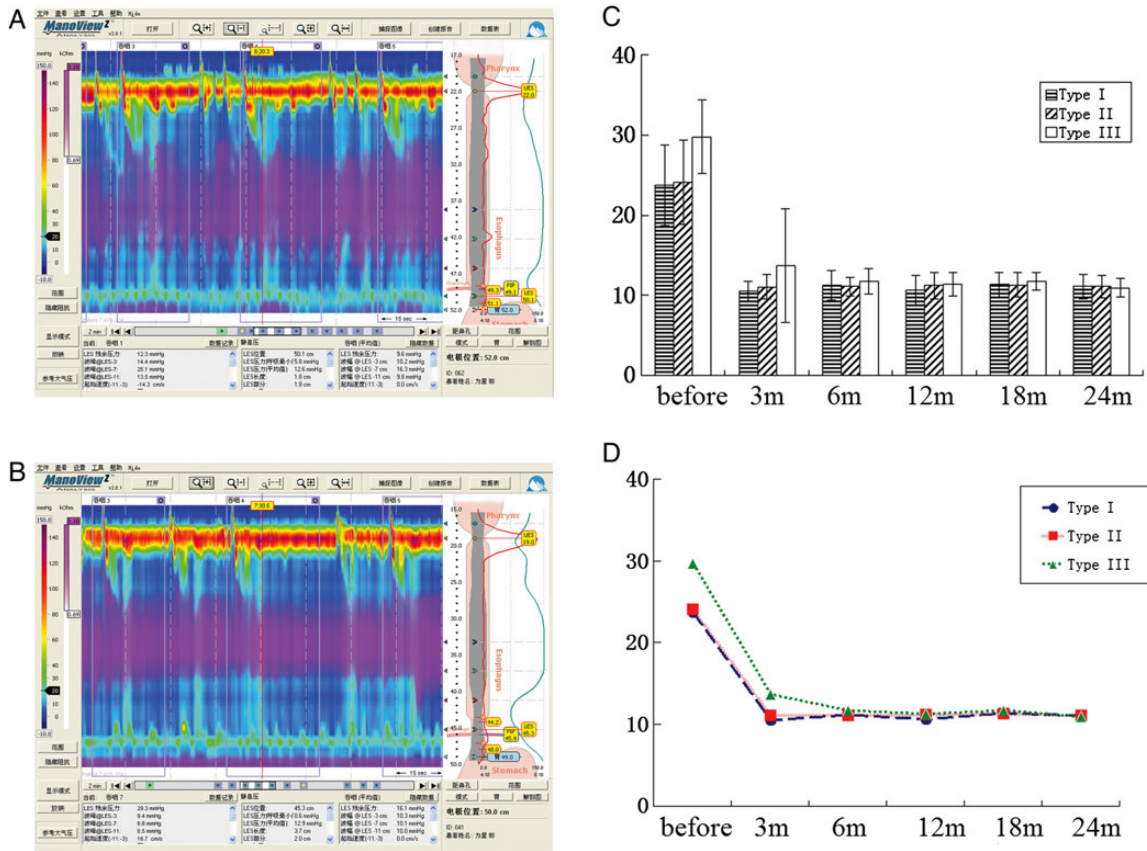
Our results revealed that POEM was effective and that the patients who underwent this intervention were all in good condition, with a low dysphagia score, Eckardt score and 4s-IRP throughout the 2 years of follow-up. Considering the risks of conventional surgery for achalasia patients, we believe that POEM, which appears to provide a similar effect with lower cost and less risk, is a better choice.

Moreover, laparoscopic Heller's myotomy as first-intention therapy is reserved for young patients less than 40 years old [22]. These disadvantages of surgical treatments are probably redressed by POEM, which minimizes the operative risk and has no age limitation. Given that the POEM intervention takes place only in the inner circular muscle fibres, avoiding any dissection of the gastro-oesophageal junction, the function of the lower oesophageal sphincter should be preserved.

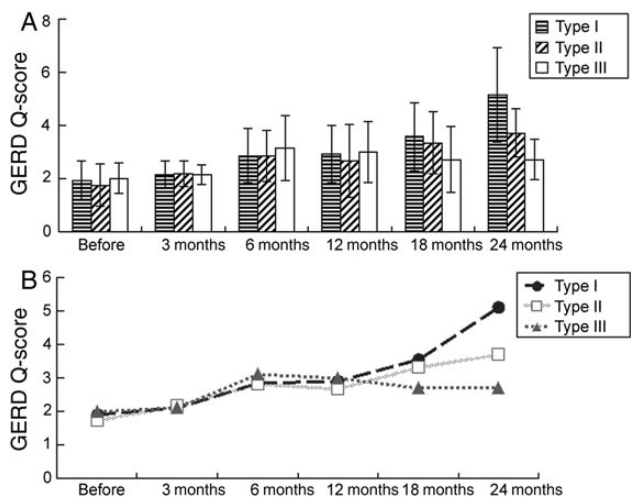
On the assumption that one advantage would be to protect patients from symptoms of GERD, which are usually encountered as one of the surgical complications because of damage to the physical structures of the lower oesophageal sphincter and gastro-oesophageal junction, we investigated the GERD Q-score throughout follow-up. We found that only 3 patients needed take medication to control GERD symptoms after POEM. We deduced that this situation is probably due mainly to the fact that POEM only affects the inner circular muscle fibres; thus the physiological function of the gastro-oesophageal junction is well retained.

According to the new Chicago classification, achalasia is classified into type I, II and III on the basis of oesophageal body motility. It has been shown that type II patients have a better response than type I or III patients to pneumatic dilatation, endoscopic botulinum toxin injection or surgical myotomy [3, 23, 24]. We analysed the effects of POEM according to the different types of achalasia and found that there was no difference in the three types in terms of symptom relief; however, type III patients seemed to have a sharp decrease in 4s-IRP and type I patients were prone to the appearance of GERD symptoms. However, considering the size of our study, the differences between the three types of achalasia need more data for confirmation.

In conclusion, by combining the advantages of endoscopy and surgery, POEM offers therapeutic benefit for as long as 2 years. With less risk and fewer limitations than surgery, POEM may be a



**Figure 4:** (A) Graph of oesophageal high-resolution manometry (HRM) before POEM; the 4 s integrated relaxation pressure (4s-IRP) was 17.6 mmHg. (B) Graph of oesophageal HRM after POEM in the same patient; the 4s-IRP was 9.6 mmHg. (C) Results of 4s-IRP scores analysed by one-way ANOVA. Type III patients had higher values than those of type I and II patients before treatment ( $P = 0.025$  and  $P = 0.022$ , respectively) and at 3 months after treatment ( $P = 0.028$  and  $P = 0.047$ , respectively). (D) Results of 4s-IRP scores with general linear model repeated-measures analysis. Significant differences were observed in the three type groups at various times ( $P = 0.001$ ). All groups had lower scores after treatment than before (all  $P < 0.05$ ), but we did not find any differences at 3, 6, 12, 18 and 24 months after the procedure.



**Figure 5:** (A) Gastro-oesophageal reflux disease questionnaire (GERD Q)-scores analysed by one-way ANOVA. Type I group had a higher score at 24 months after POEM than type II and III patients ( $P = 0.001$  and  $P < 0.001$ , respectively). (B) The GERD Q-scores with general linear model repeated-measures analysis. Except for no changes between 6 and 12 months ( $P = 0.768$ ), 6 and 18 months ( $P = 0.257$ ) or 12 and 18 months ( $P = 0.179$ ), the scores were all different at other times (all  $P < 0.05$ ).

better alternative treatment for achalasia. However, we could not include many patients with different types of achalasia in our study because oesophageal manometry by HRM has become available in our centre only since January 2010. It is a pity that our study was carried out on small scale, because this may have caused bias or distortion of the data in some way. Even so, given that there has been little investigation of the short- and long-term effects of POEM in detail, our study may be of value as a preliminary exploration. Larger-scale studies are needed for further research on POEM.

**Conflict of interest:** none declared.

**REFERENCES**

- [1] Richter JE. Oesophageal motility disorders. *Lancet* 2001;358:823–8.
- [2] Vaezi MF, Pandolfino JE, Vela MF. ACG clinical guideline: diagnosis and management of achalasia. *Am J Gastroenterol*. 2013;108:1238–49.
- [3] Pandolfino JE, Kwiatek MA, Nealis T, Bulsiewicz W, Post J, Kahrilas PJ. Achalasia: a new clinically relevant classification by high-resolution manometry. *Gastroenterology* 2008;135:1526–33.
- [4] Inoue H, Minami H, Kobayashi Y, Sato Y, Kaga M, Suzuki M *et al.* Peroral endoscopic myotomy (POEM) for esophageal achalasia. *Endoscopy* 2010; 42:265–71.

- [5] Bai Y, Du Y, Zou D, Jin Z, Zhan X, Li ZS *et al.* Gastroesophageal Reflux Disease Questionnaire (GerdQ) in real-world practice: a national multicenter survey on 8065 patients. *J Gastroenterol Hepatol* 2013;28:626–31.
- [6] Inoue H, Tianle KM, Ikeda H, Hosoya T, Onimaru M, Yoshida A *et al.* Peroral endoscopic myotomy for esophageal achalasia: technique, indication, and outcomes. *Thorac Surg Clin* 2011;21:519–25.
- [7] Kahrilas PJ, Ghosh SK, Pandolfino JE. Esophageal motility disorders in terms of pressure topography. The Chicago Classification. *J Clin Gastroenterol* 2008;42:627–35.
- [8] Mellow MH, Pinkas H. Endoscopic laser therapy for malignancies affecting the esophagus and gastroesophageal junction: analysis of technical and functional efficacy. *Arch Intern Med* 1985;145:1443–6.
- [9] Eckardt VF, Aignherr C, Bernhard G. Predictors of outcome in patients with achalasia treated by pneumatic dilatation. *Gastroenterology* 1992;103:1732–8.
- [10] Campos GM, Vittinghoff E, Rabl C, Takata M, Gadenstätter M, Lin F *et al.* Endoscopic and surgical treatments for achalasia: a systematic review and meta-analysis. *Ann Surg* 2009;249:45–57.
- [11] Gheorghe C, Bancila I, Tutuian R, Iacob R, Tomulescu V. Predictors of short term treatment outcome in patients with achalasia following endoscopic or surgical therapy. *Hepatogastroenterology* 2012;59:2503–7.
- [12] Weber CE, Davis CS, Kramer HJ, Gibbs JT, Robles L, Fisichella PM. Medium and long-term outcomes after pneumatic dilation or laparoscopic Heller myotomy for achalasia: a meta-analysis. *Surg Laparosc Endosc Percutan Tech* 2012;22:289–96.
- [13] Rabenstein T. Two arguments in favor of surgery. *Dtsch Arztebl Int* 2012;109:534.
- [14] Eckardt AJ, Eckardt VF. Treatment and surveillance strategies in achalasia: an update. *Nat Rev Gastroenterol Hepatol* 2011;8:311–9.
- [15] El Hak NG, Hamdy E, Abdalla T, Kandel T, El Raof AA, El Hemaly M *et al.* Laparoscopic Heller myotomy for achalasia: analysis of successes and failures. *Hepatogastroenterology* 2012;59:1450–4.
- [16] von Renteln D, Fuchs KH, Fockens P, Bauerfeind P, Vassiliou MC, Werner YB *et al.* Peroral endoscopic myotomy for the treatment of achalasia: an international prospective multicenter study. *Gastroenterology* 2013;145:309–11.
- [17] Francis DL, Katzka DA. Achalasia: update on the disease and its treatment. *Gastroenterology* 2010;139:369–74.
- [18] Rebecchi F, Giaccone C, Farinella E, Campaci R, Morino M. Randomized controlled trial of laparoscopic Heller myotomy plus Dor fundoplication versus Nissen fundoplication for achalasia: long-term results. *Ann Surg* 2008;248:1023–30.
- [19] Chen Z, Bessell JR, Chew A, Watson DI. Laparoscopic cardiomyotomy for achalasia: clinical outcomes beyond 5 years. *J Gastrointest Surg* 2010;14:594–600.
- [20] Ghosh SK, Pandolfino JE, Rice J, Clarke JO, Kwiatek M, Kahrilas PJ. Impaired deglutitive EGJ relaxation in clinical esophageal manometry: a quantitative analysis of 400 patients and 75 controls. *Am J Physiol Gastrointest Liver Physiol* 2007;293:G878–85.
- [21] Kahrilas PJ, Peters JH. Evaluation of the esophagogastric junction using high resolution manometry and esophageal pressure topography. *Neurogastroenterol Motil* 2012;24:11–9.
- [22] Stefanidis D, Richardson W, Farrell TM, Kohn GP, Augenstein V, Fanelli RD. Society SAGES guidelines for the surgical treatment of esophageal achalasia. *Surg Endosc* 2012;26:296–311.
- [23] Rohof WO, Salvador R, Annese V, Bruley des Varannes S, Chaussade S, Costantini M *et al.* Outcomes of treatment for achalasia depend on manometric subtype. *Gastroenterology* 2013;144:718–25.
- [24] Pandolfino JE, Ghosh SK, Rice J, Clarke JO, Kwiatek MA, Kahrilas PJ. Classifying esophageal motility by pressure topography characteristics: a study of 400 patients and 75 controls. *Am J Gastroenterol* 2008;103:27–37.