

Cite this article as: Shen Y, Wang H, Feng M, Xi Y, Tan L, Wang Q. Single- versus multiple-port thoracoscopic lobectomy for lung cancer: a propensity-matched study. *Eur J Cardiothorac Surg* 2016;49:i48–i53.

# Single- versus multiple-port thoracoscopic lobectomy for lung cancer: a propensity-matched study<sup>†</sup>

Yaxing Shen<sup>‡</sup>, Hao Wang<sup>‡</sup>, Mingxiang Feng, Yong Xi, Lijie Tan\* and Qun Wang

Department of Thoracic Surgery, Zhongshan Hospital of Fudan University, Shanghai, China

\* Corresponding author. Department of Thoracic Surgery, Zhongshan Hospital of Fudan University, 180 Fenglin Road, Shanghai 200032, China. Tel: +86-13-681972151; fax: +86-21-64041990; e-mail: tan.lijie@zs-hospital.sh.cn (L. Tan).

Received 11 June 2015; received in revised form 31 August 2015; accepted 9 September 2015

## Abstract

**OBJECTIVES:** In this retrospective study, we aimed to compare single-port (SP) and multiport (MP) video-assisted thoracoscopic surgery (VATS) for the surgical resection of non-small-cell lung cancer (NSCLC).

**METHODS:** Between October 2013 and October 2014, a total of 411 consecutive NSCLC patients who underwent VATS lobectomy in the Department of Thoracic Surgery, Zhongshan Hospital of Fudan University, were enrolled. Propensity-matched analysis, incorporating pre-operative clinical features, was used to compare the perioperative outcomes and analyse the safety and efficacy between SP and MP VATS lobectomies for NSCLCs.

**RESULTS:** There were 115 patients in the SP group, and 296 patients in the MP group from October 2013 to October 2014. Propensity matching produced 100 pairs in this retrospective study. During the operation, the lobectomy took less time in the SP than in the MP ( $65.7 \pm 14.8$  vs  $81.3 \pm 13.6$ ,  $P < 0.001$ ) group, while the duration of lymphadenectomy was longer in the SP group ( $29.6 \pm 16.7$  vs  $17.4 \pm 13.3$ ,  $P < 0.001$ ). The total operation duration, the volume of estimated blood loss ( $55.1 \pm 9.0$  ml vs  $58.7 \pm 7.1$  ml,  $P = 0.22$ ) and the length of post-operative hospital stay ( $4.7 \pm 1.2$  days vs  $5.3 \pm 1.4$  days,  $P = 0.05$ ) were similar between the two groups. Postoperatively, SP and MP groups showed similar results in terms of morbidity and mortality.

**CONCLUSIONS:** In comparison with conventional VATS, SP VATS lobectomy showed better safety and efficacy in the surgical resection of NSCLCs. Further studies based on larger populations and better methodology are required to determine its further benefits towards patients.

**Keywords:** Uniportal surgery • Video-assisted thoracic surgery • Lung cancer

## INTRODUCTION

In comparison with the initial report on single-port (SP) video-assisted thoracoscopic surgery (VATS) 10 years ago [1], higher proportion of major lung resections were recorded in most of the recent publications [2]. The indication of SP surgery has been widened from biopsy to lobectomy for the surgical resection of lung cancer [3]. While lesser ports are being applied during the surgery, the question as to whether VATS would be easier using an SP remains uncertain.

Early in 2011, Gonzalez-Rivas *et al.* [4] reported their experience of SP VATS lobectomy, the first worldwide-published study on major lung resection. Meanwhile, a little evidence has been collected on SP VATS to verify its advantage over multiple-port (MP) procedures. A recent propensity-matched study by Liu showed shorter operative time and less blood loss in SP VATS [5]. However,

the author chose to include both lobectomy and segmentectomy, while segmentectomy was technically more demanding than lobectomy. Besides, surgeons performing SP VATS would take some time to reach the learning curve plateau, which would contribute to the potential bias of the study [6]. In spite of the inspiring work from Liu, we consider that there could be more information to be mined in the comparison between the two techniques.

On the basis of our primary results from SP VATS [7], we herein summarize our experience based on the comparison between SP and MP VATS lobectomies.

## MATERIALS AND METHODS

The study was approved by the institutional review board and the ethics committee of Zhongshan Hospital, Fudan University. Preoperative examination including electrocardiography, pulmonary function test, chest computed tomography scan, bronchoscope and brain magnetic resonance imaging were administered to exclude the candidates for curative surgery.

<sup>†</sup>Presented at the 3rd Asian Single-Port VATS Symposium & Live Surgery, The Chinese University of Hong Kong, Hong Kong, China, 26–27 March 2015.

<sup>‡</sup>The first two authors contributed equally to the manuscript.

The inclusion criteria for VATS lobectomy were as follows:

- (i) patients with clinically staged T1–3N0M0 tumours;
- (ii) patients without previous history of cancer;
- (iii) patients without previous history of chest surgery;
- (iv) patients with an American Society of Anesthesiologists (ASA) score of I–II.

Senior consultant surgeons in Zhongshan Hospital, Fudan University, performed all surgeries. The conventional VATS lobectomy was initiated in 2003. The first SP VATS lobectomy was performed in October 2013 [7], and the initial 15 cases were not included due to the learning curve effect. Clinical features including age, sex, forced expiratory volume in the first second (FEV<sub>1</sub>), tumour location (upper/non-upper lobe) and diameter, tumor stage, histology, operation duration, estimated volume of blood loss, morbidity and mortality were recorded.

### Surgical technique of single-port video-assisted thoracoscopic surgery lobectomy

**Anaesthesia and analgesia.** All patients received a combination of epidural and general anaesthesia, and were provided with patient-controlled analgesia postoperatively. After intravenous induction, each patient was intubated with a double-lumen endotracheal tube to accomplish single-lung ventilation. Patients' vital signs were followed during the operation. All patients were extubated at the end of surgery and transferred to the ward.

**Position.** The patient was kept in a folding knife gesture (with the cranial side raised up and caudal side pushed down) in the lateral decubitus position (Fig. 1). Intraoperatively, the surgeon and the assistant stood on the abdominal side of the patient. The assistant stood at the footstool. The entire procedure was performed under screen observation and the surgical video was recorded.

**Video-assisted thoracoscopic surgery lobectomy.** In SP VATS lobectomy, a 3.5-cm incision was made at the fourth intercostal space along the anterior axillary line for upper lobe resection and the fifth intercostal space for middle and inferior lobe resection. A soft plastic wound protector was applied to the incision without rib-spreading. The 10-mm 30° thoracoscope (Karl Storz, GmbH & Co., Tuttlingen, Germany) was introduced in the superior side of the incision during the lobectomy. The designed surgical

instruments (Fig. 2), together with the harmonic shear (Ethicon Endo-Surgery, Inc., Cincinnati, OH, USA) or hook electro-cautery were applied during the procedure.

The bronchus, vein and artery were divided anatomically, and dissected separately using endoscopic staplers (Covidien, Mansfield, MA, USA, or Ethicon Endo-Surgery, Inc.) or ligated by using hem-o-locks (Weck Surgical, Teleflex, Limerick, PA, USA) before dissection. The dissection order varied as per the fissure development and the tumour location: Usually, in the cases of lower or middle lobe lesions, the dissection order was vein, artery and bronchus and, in the cases of upper lobe lesions, the dissection order would be switched to artery, vein and bronchus (Fig. 3).

The specimen was taken out in the specimen bag (Ethicon Endo-Surgery, Inc.). Conventionally, systemic mediastinal lymph node dissection would be performed after the removal of the target lobe. A 28-Fr chest tube was inserted at the end of the operation, and this would be removed in case there was no air leakage and the volume of drainage was less than 200 ml per day 24 h postoperatively.

In MP VATS lobectomy, a 1.0-cm incision was made at eighth intercostal space along the mid-axillary line to introduce the thoracoscopic 10-mm trocar (Ethicon Endo-Surgery, Inc.). The second incision (3–4 cm) was made at the fifth or sixth intercostal space along the anterior axillary line and the third incision was made at the triangle of auscultation, and a 5-mm trocar was introduced for thoracoscopic manipulation.

As was described in a previous publication [8], after thoracoscopic exploration, the primary vascular structures were identified and mobilized. The dissection of pulmonary vein came as the first step after the confirmation of venous drainage of the target lobe. Then branches of the pulmonary artery were divided by using endoscopic staplers (Covidien or Ethicon Endo-Surgery, Inc.), followed by the target bronchus. In case a well-developed fissure was observed intraoperatively, the branches of pulmonary arteries were mobilized and dissected to minimize the repeated turnover of the target lobe.

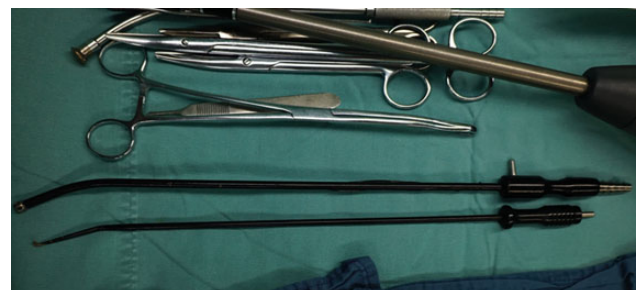Systemic mediastinal lymphadenectomy was performed after the target lobe was taken out. Two chest tubes (28-Fr, 22-Fr) were placed separately through the observational and second incision, and the chest tube was removed in case there was no air leakage and the volume of drainage was less than 200 ml per day 24–36 h postoperatively.

### Analysis

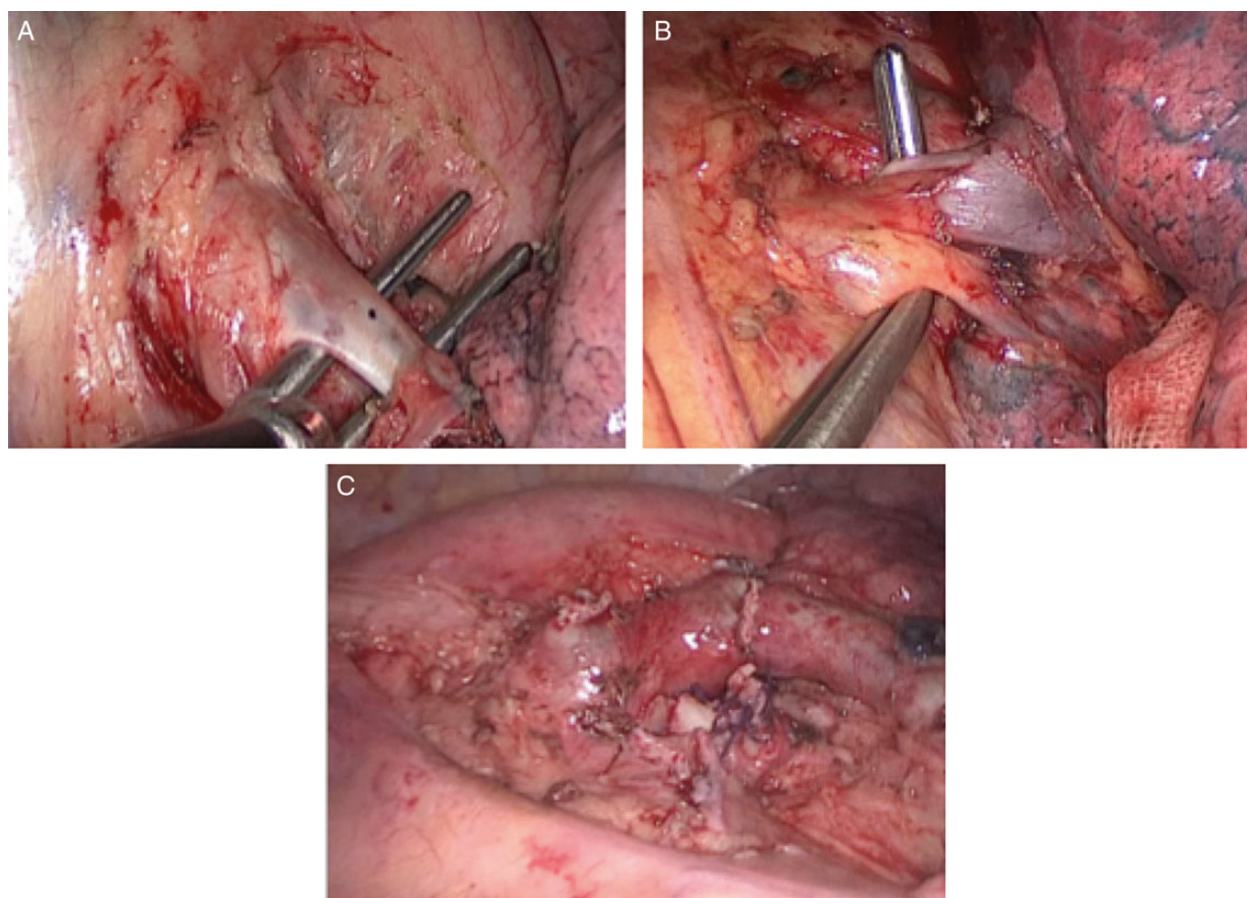
Clinical information from all included patients was collected from the institution's database by trained surgical coordinators. All data collected were tabulated using Microsoft Excel for further analysis.



**Figure 1:** The patient position during single-port video-assisted thoracoscopic surgery.



**Figure 2:** The designed surgical instruments for single-port video-assisted thoracoscopic surgery.



**Figure 3:** The single-port left upper lobectomy.

Propensity score-matched analysis was performed for the comparison between SP and MP VATS lobectomies. The SP-MP pairs were matched according to the propensity score generated by using a logistic regression model (SPSS, IBM SPSS Statistics, Chicago, IL, USA, version 22.0). The included parameters were age, sex, FEV<sub>1</sub>, tumour histology, tumour diameter, the completeness of the fissure and the extent of pleural adhesion. The one-to-one match was achieved by using the nearest neighbour-matching algorithm. The flowchart summarizing the patients' inclusion and matching results is listed in Fig. 4.

Surgical videos were independently reviewed by two experienced surgeons (Lijie Tan and Mingxiang Feng). The development of fissure and thoracic adhesions were reviewed, and the duration of lobectomy and lymphadenectomy was recorded separately. Data analysis was undertaken using SPSS software (SPSS, IBM SPSS Statistics, version 22.0). Variables were compared using Student's *t*-test, the  $\chi^2$  test and the Mann-Whitney *U*-test. A two-sided *P* value of <0.05 was considered statistically significant.

## RESULTS

### Clinical features

Between October 2013 and October 2014, a total of 115 SP VATS lobectomies were attempted in Zhongshan Hospital of Fudan University. Beside the first 15 cases, 100 lobectomies were performed through a single port (SP), after the propensity-scored analysis, 100 MP VATS lobectomies were matched in this

retrospective study. The clinical features of the study cohort before and after matching are listed in Table 1.

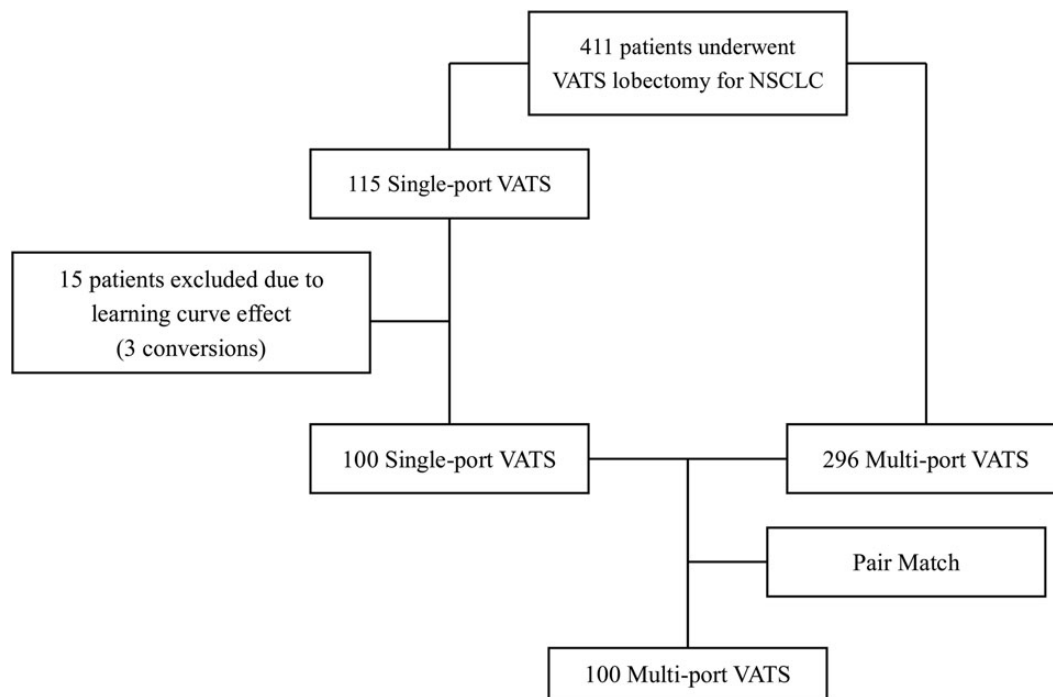
Intraoperatively, there were two conversions (2%) in the SP group: An additional port was introduced in one left upper lobectomy due to an iatrogenic injury to the ascending branch of the pulmonary artery; the bleeding was controlled after the main trunk of the left pulmonary artery was taped and the rupture was sutured. Another conversion occurred during the left upper lobectomy: The sticky lymph nodes were found to be invasive to the basal branch of the inferior pulmonary artery. Thoracotomy was applied to control the bleeding of the artery. Pathological diagnosis confirmed the lymph node without tumour metastasis. In MP, there was one conversion to open thoracotomy due to severe adhesion in the thoracic cavity. The surgery was completed after the adhesiolysis.

The average operation duration in SP and MP was similar ( $95.3 \pm 16.9$  vs  $98.8 \pm 15.3$  min,  $P = 0.13$ ). While the duration of lobectomy was shorter in SP ( $65.7 \pm 14.8$  vs  $81.3 \pm 13.6$  min,  $P < 0.001$ ), the duration of lymphadenectomy was longer in SP than in MP ( $29.6 \pm 16.7$  vs  $17.4 \pm 13.3$  min,  $P < 0.001$ ). The average volume of estimated blood loss ( $55.1 \pm 9.0$  vs  $58.7 \pm 7.1$  ml,  $P = 0.22$ ), and the average number of harvested lymph nodes were similar between the two groups  $21.4 \pm 5.6$  vs  $20.9 \pm 5.2$ ,  $P = 0.54$ ). The clinical results are recorded in Table 2.

### Morbidity and mortality

No mortality was recorded in either group. A total of 11 patients developed complications (4 vs 7 in SP and MP, respectively),





**Figure 4:** The flowchart of the study. VATS: video-assisted thoracoscopic surgery; NSCLC: non-small-cell lung cancer.

including 7 prolonged air leakages lasting for more than 5 days, 3 atelectasis requiring bronchoscopic suction after the surgery and 1 empyema requiring prolonged drainage. After the removal of the chest tube, all patients were discharged following the confirmation of lung re-expansion by chest X-rays. The average post-operative length of stay in hospital was  $4.7 \pm 1.2$  days in SP and  $5.3 \pm 1.4$  days ( $P = 0.05$ ) in MP. Prolonged stay or readmission to the intensive care unit was not recorded in this cohort.

## DISCUSSION

In this retrospective study, we compared the SP and MP VATS lobectomies for non-small-cell lung cancer (NSCLC). Beside its safety and feasibility in the surgical resection of lung cancer, a shorter duration was recorded during the lobectomy for lung cancer. The results from our single centre showed high efficacy in SP VATS.

Undoubtedly, patients would benefit from this surgery with less traumatic manipulations [9–11]. In 2004, Rocco first reported on SP thoracoscopic wedge resection [12]. Since then, several articles have confirmed the safety and feasibility of SP operation as a simple procedure. In 2011, Gonzalez-Rivas reported the experience on uniportal lobectomy, which was the world's first report on uniportal major lung resection [4]. Following that, Gonzalez-Rivas *et al.* have published serial reports on segmentectomy, pneumonectomy and sleeve lobectomy [13–15]. Until now, the indications of single-port VATS would be similar to conventional VATS. However, in spite of its growing acceptance, the benefit of single-port thoracic surgery has remained difficult to describe [16, 17].

In MP VATS, an upper lobectomy was usually challenging during the dissection along the truncus anterior branch of the pulmonary artery; the iatrogenic injury would lead to major bleeding and subsequent manipulation was technically demanding during the operation [18]. However, in SP VATS lobectomy, the mobilization of the apical branch was switched as the first step. In that

order, the identification and dissection were simple and clear through the incision located at the fourth intercostal space, with improved visualization described in a geometrical study on uniportal surgery [19], and that explained the shorter duration of SP lobectomy.

Since the incision was close to the hilum, and the systemic lymphadenectomy would require dissections at least three separate stations away from the incision [20], lymph node dissections were relatively difficult in SP VATS. Among them, the most difficult part was the sub-carinal lymph node dissection, which is usually located far away from the incision. In this study, the number of harvested lymph nodes was similar between the two groups, while SP required more than MP. When this is factored in, the effective time period needed for SP and MP is similar.

In this study, we excluded the first 15 cases to minimize the bias due to the learning curve effect because every surgical procedure required certain case volumes to reach the plateau of performance [21]. As most surgeons who turned to SP VATS had some experience on minimally invasive surgery, the difficulty lay mostly in how to pass the staplers through the inter-space among the mediastinal vessels. Meanwhile, in case safety would be compromised or the operation ran into difficulty, additional ports or thoracotomy would be favoured. In the initial 15 cases, we observed three conversions (20%) when staplers could not pass through the mediastinal vessels (superior pulmonary vein) and caused sequential bleedings. The rate decreased to 1 conversion out of the following 100 cases (1%) and was comparable with conventional VATS in lobectomy. The results suggested that SP was safe after practice with a relatively small number of cases. Similar findings were reported in recent papers [22, 23].

Some studies argued on the disadvantage of SP VATS [24]. One might feel ergonomic discomfort at the conversion from conventional to SP VATS. Yet the following improvements were made during the first 15 cases on single-port VATS in our hospital: Firstly, the position of the assistant surgeon: the assistant surgeon stood

**Table 1:** Clinical features before and after matching

	All patients			Propensity-matched patients		
	SP (n = 100)	MP (n = 296)	P	SP (n = 100)	MP (n = 100)	P
Age (years)	61.5 ± 7.9 (56, 68)	63.4 ± 8.3 (58, 69)	0.05	61.5 ± 7.9 (56, 68)	60.9 ± 7.8 (56, 67)	0.57
FEV <sub>1</sub>	2.32 ± 0.31 (2.06, 2.69)	2.41 ± 0.29 (2.18, 2.64)	0.02	2.32 ± 0.31 (2.06, 2.69)	2.31 ± 0.63 (2.16, 2.63)	0.27
Tumour diameter (cm)	2.53 ± 0.86 (1.95, 3.56)	2.36 ± 0.84 (1.85, 3.60)	0.71	2.53 ± 0.86 (1.95, 3.56)	2.50 ± 0.90 (1.94, 3.46)	0.76
Sex						
Male	56 (56%)	172 (58%)	0.49	56 (56%)	55 (55%)	0.89
Female	44 (44%)	124 (42%)		44 (44%)	45 (45%)	
Histology						
SC	20 (20%)	45 (15%)	0.26	20 (20%)	16 (16%)	0.46
AD	80 (80%)	251 (75%)		80 (80%)	84 (84%)	
Fissure						
Developed	69 (69%)	193 (65%)	0.54	69 (69%)	72 (72%)	0.64
Not well developed	31 (31%)	103 (35%)		31 (31%)	28 (28%)	
Thoracic adhesion						
No adhesion	71 (71%)	196 (66%)	0.38	71 (71%)	67 (67%)	0.54
Adhesion	29 (29%)	100 (34%)		29 (29%)	33 (33%)	
Tumour location						
Upper lobe	53 (53%)	130 (44%)	0.12	53 (53%)	51 (51%)	0.78
Non-upper lobe	47 (47%)	166 (56%)		47 (47%)	49 (49%)	
T stage						
T1a	26 (26%)	72 (24%)	0.41	26 (26%)	28 (28%)	0.86
T1b	52 (52%)	144 (49%)		52 (52%)	50 (50%)	
T2a	20 (20%)	72 (24%)		20 (20%)	21 (21%)	
T2b	2 (2%)	5 (2%)		2 (2%)	1 (1%)	
T3a	0 (0%)	3 (1%)		0 (0%)	0 (0%)	
T3b	0 (0%)	0 (0%)		0 (0%)	0 (0%)	
N stage						
0	62 (62%)	168 (57%)	0.37	62 (62%)	56 (56%)	0.41
1	24 (24%)	79 (27%)		24 (24%)	28 (28%)	
2	9 (9%)	34 (11%)		9 (9%)	10 (10%)	
3	5 (5%)	15 (5%)		5 (5%)	5 (5%)	

Discrete data are expressed as number with percentages: n (%).

Continuous data are expressed as mean ± SD (interquartile range).

FEV<sub>1</sub>: forced expiratory volume in the first second; SC: squamous cell cancer; AD: adenocarcinoma; SP: single-port; MP: multiport; SD: standard deviation.

**Table 2:** Comparison on perioperative outcomes

	SP (n = 100)	MP (n = 100)	P
Operation duration	95.3 ± 16.9 (80, 105)	98.8 ± 15.3 (87, 110)	0.13
Lobectomy	65.7 ± 14.8 (53, 76)	81.3 ± 13.6 (70, 93)	<0.001
Lymphadenectomy	29.6 ± 16.7 (24, 35)	17.4 ± 13.3 (15, 25)	<0.001
Blood loss (ml)	55.1 ± 9.0 (49, 58)	58.7 ± 7.1 (54, 62)	0.22
Number of lymph nodes	21.4 ± 5.6 (16, 26)	20.9 ± 5.2 (17, 26)	0.54
Length of stay (days)	4.7 ± 1.2 (4, 5)	5.3 ± 1.4 (4, 6)	0.05
Conversion	1 (1%)	2 (2%)	1.00
Morbidity	4 (4%)	7 (7%)	1.00
Mortality	0 (0%)	0 (0%)	0.00

Discrete data are expressed as number with percentages: n (%).

Continuous data are expressed in mean ± SD (interquartile range) formation.

SP: single-port; MP: multiport; SD: standard deviation.

at the footstool, and the shoulder of the assistant was kept in adduction with extended arms throughout the procedure, and that would result in better ergonomics when compared with the posture where the shoulder was kept in abduction with both arms flexed. Secondly, the refinement of surgical instruments: Since the incision was narrow in width, a curved instrument would facilitate

the dissection around hilar structures better than with straight instruments; so a tiny and curved suction stick was invented for the procedure. Although there is lack of objective evidence, the surgical refinements contributed to the better ergonomics in SP VATS and assured continuity during the whole procedure. In SP VATS, advantages seemed to be shown on the surgeon's learning

curve and ergonomics, which helped explain its fast spread throughout the world. 'Easy to learn and happy to do', the development of SP VATS continues.

The retrospective design using propensity-matched methods and the relatively small sample size are the main limitations of this study. As was described in previous publications, a randomized controlled study would be impossible to compare SP and MP surgeries [25]; the development of methodology on clinical trials might help to uncover the potential advantages of this emerging technique.

## Funding

This work was supported by the American Association for Thoracic Surgery's Evarts A. Graham Memorial Traveling Fellowship. It was also supported by the National Natural Science Foundation of China (Grant No. 81400681).

**Conflict of interest:** none declared.

## REFERENCES

- [1] Rocco G, Martucci N, La Manna C, Jones DR, De Luca G, La Rocca A *et al.* Ten-year experience on 644 patients undergoing single-port (uniportal) video-assisted thoracoscopic surgery. *Ann Thorac Surg* 2013;96:434–8.
- [2] Gonzalez-Rivas D, Paradela M, Fernandez R, Delgado M, Fieira E, Mendez L *et al.* Uniportal video-assisted thoracoscopic lobectomy: two years of experience. *Ann Thorac Surg* 2013;95:426–32.
- [3] Ng CS, Rocco G, Wong RH, Lau RW, Yu SC, Yim AP. Uniportal and single-incision video-assisted thoracic surgery: the state of the art. *Interact CardioVasc Thorac Surg* 2014;19:661–6.
- [4] Gonzalez-Rivas D, de la Torre M, Fernandez R, Mosquera VX. Single-port video-assisted thoracoscopic left upper lobectomy. *Interact CardioVasc Thorac Surg* 2011;13:539–41.
- [5] Wang BY, Liu CY, Hsu PK, Shih CS, Liu CC. Single-incision versus multiple-incision thoracoscopic lobectomy and segmentectomy: a propensity-matched analysis. *Ann Surg* 2015;261:793–9.
- [6] Cao C, Petersen RH, Yan TD. Learning curve for video-assisted thoracoscopic lobectomy. *J Thorac Cardiovasc Surg* 2014;147:1727.
- [7] Feng M, Shen Y, Wang H, Tan L, Mao X, Liu Y *et al.* Uniportal video assisted thoracoscopic lobectomy: primary experience from an Eastern center. *J Thorac Dis* 2014;6:1751–6.
- [8] McKenna RJ Jr, Houck W, Fuller CB. Video-assisted thoracic surgery lobectomy: experience with 1,100 cases. *Ann Thorac Surg* 2006;81:421–5.
- [9] Andreetti C, Menna C, Ibrahim M, Ciccone AM, D'Andrilli A, Venuta F *et al.* Postoperative pain control: videothoracoscopic versus conservative mini-thoracotomic approach. *Eur J Cardiothorac Surg* 2014;46:907–12.
- [10] Sihoe AD. The evolution of minimally invasive thoracic surgery: implications for the practice of uniportal thoracoscopic surgery. *J Thorac Dis* 2014;6:S604–17.
- [11] Ng CS, Lau KK, Gonzalez-Rivas D, Rocco G. Evolution in surgical approach and techniques for lung cancer. *Thorax* 2013;68:681.
- [12] Rocco G, Martin-Ucar A, Passera E. Uniportal VATS wedge pulmonary resections. *Ann Thorac Surg* 2004;77:726–8.
- [13] Gonzalez-Rivas D, Fieira E, Mendez L, Garcia J. Single-port video-assisted thoracoscopic anatomic segmentectomy and right upper lobectomy. *Eur J Cardiothorac Surg* 2012;42:e169–71.
- [14] Gonzalez-Rivas D, de la Torre M, Fernandez R, Garcia J. Video: single-incision video-assisted thoracoscopic right pneumonectomy. *Surg Endosc* 2012;26:2078–9.
- [15] Gonzalez-Rivas D, Fernandez R, Fieira E, Rellan L. Uniportal video-assisted thoracoscopic bronchial sleeve lobectomy: first report. *J Thorac Cardiovasc Surg* 2013;145:1676–7.
- [16] Jimenez MF. Uniportal versus standard video-assisted thoracoscopic surgery for lung lobectomy: changing the standards requires scientific evidence. *Eur J Cardiothorac Surg* 2015;47:916.
- [17] Young R, McElnay P, Leslie R, West D. Is uniportal thoracoscopic surgery less painful than multiple port approaches? *Interact CardioVasc Thorac Surg* 2015;20:409–14.
- [18] Guo ZH, Kang MQ, Lin RB, Zheng W, Zhu Y, Zheng B *et al.* Management of the pulmonary artery during video-assisted thoracoscopic left upper lobectomy. *World J Surg* 2014;38:2645–51.
- [19] Bertolaccini L, Rocco G, Viti A, Terzi A. Geometrical characteristics of uniportal VATS. *J Thorac Dis* 2013;5:S214–6.
- [20] Swanson SJ, Herndon JE, D'Amico TA, Demmy TL, McKenna RJ Jr, Green MR *et al.* Video-assisted thoracic surgery lobectomy: report of CALGB 39802—a prospective, multi-institution feasibility study. *J Clin Oncol* 2007;25:4993–7.
- [21] Huang CL, Liu CC, Cheng CY, Lin CH, Wu YC, Wang BY. Learning thoracoscopic lobectomy in resident training. *Thorac Cardiovasc Surg* 2014;62:690–5.
- [22] Kim HK, Choi YH. The feasibility of single-incision video-assisted thoracoscopic major pulmonary resection performed by surgeons experienced with a two-incision technique. *Interact CardioVasc Thorac Surg* 2015;20:310–5.
- [23] Okyere S, Attia R, Toufektzian L, Routledge T. Is the learning curve for video-assisted thoracoscopic lobectomy affected by prior experience in open lobectomy? *Interact CardioVasc Thorac Surg* 2015;21:108–12.
- [24] Bertolaccini L, Viti A, Terzi A. Ergon-trial: ergonomic evaluation of single-port access versus three-port access video-assisted thoracic surgery. *Surg Endosc* 2015;29:2934–40.
- [25] Wang BY, Tu CC, Liu CY, Shih CS, Liu CC. Single-incision thoracoscopic lobectomy and segmentectomy with radical lymph node dissection. *Ann Thorac Surg* 2013;96:977–82.