

Impacted maxillary canines and root resorptions of neighbouring teeth: a radiographic analysis using cone-beam computed tomography

Caroline S. Lai^{*,†}, Michael M. Bornstein^{*,†}, Lothar Mock^{*}, Benjamin M. Heuberger^{***}, Thomas Dietrich^{****} and Christos Katsaros^{*}

^{*}Department of Orthodontics and Dentofacial Orthopedics, ^{**}Department of Oral Surgery and Stomatology, School of Dental Medicine, University of Bern, Switzerland, ^{***}Clinic for Oral and Maxillofacial Surgery, Hospital of Luzern, Switzerland and ^{****}Department of Oral Surgery, The School of Dentistry, University of Birmingham, UK

[†]These authors have contributed equally to this study

Correspondence to: Michael M. Bornstein, Department of Oral Surgery and Stomatology, School of Dental Medicine, University of Bern, Freiburgstrasse 7, CH-3010 Bern, Switzerland. E-mail: michael.bornstein@zmk.unibe.ch

SUMMARY The study analyses the location of impacted maxillary canines and factors influencing root resorptions of adjacent teeth using cone-beam computed tomography (CBCT). In addition, the interrater reliability between observers of two different dental specialties for radiographic parameters will be evaluated. CBCT images of patients who were referred for radiographic localization of impacted maxillary canines and/or suspicion of root resorptions of adjacent teeth were included. The study analysed the exact three-dimensional location of the impacted canines in the anterior maxilla, frequency and extent of root resorptions, and potential influencing factors. To assess interrater agreement, Cohen's correlation parameters were calculated.

This study comprises 113 patients with CBCT scans, and 134 impacted canines were analysed retrospectively. In the patients evaluated, 69 impacted canines were located palatally (51.49 per cent), 41 labially (30.60 per cent), and 24 (17.91 per cent) in the middle of the alveolar process. Root resorptions were found in 34 lateral incisors (25.37 per cent), 7 central incisors (5.22 per cent), 6 first premolars (4.48 per cent), and 1 second premolar (0.75 per cent). There was a significant correlation between root resorptions on adjacent teeth and localization of the impacted canine in relation to the bone, as well as vertical localization of the canine. Interrater agreement showed values of 0.546–0.877. CBCT provides accurate information about location of the impacted canine and prevalence and degree of root resorption of neighbouring teeth with high interrater correlation. This information is of great importance for surgeons and orthodontists for accurate diagnostics and interdisciplinary treatment planning.

Introduction

Impaction is defined by the lack of eruption of a tooth into the appropriate position in the dental arch within the time and physiological limits of the normal eruption process (Maverna and Gracco, 2007). Maxillary permanent canines are the second most frequently impacted teeth after third molars (Walker *et al.*, 2005; Liu *et al.*, 2008), with a prevalence of approximately 1–3 per cent (Preda *et al.*, 1997; Chaushu *et al.*, 1999; Mason *et al.*, 2001; Walker *et al.*, 2005). Most studies report that palatal displacement (80–90 per cent) of impacted maxillary canines is more common than labial displacement (10–20 per cent) (Ericson and Kurol, 2000; Walker *et al.*, 2005; Bjerklin and Ericson, 2006). However, using computed tomography (CT), Bjerklin and Ericson (2006) found the canines to be localized labially in 40 per cent of the cases, palatally in 42 per cent, and in a mid-alveolar position in 18 per cent. In a study using cone-beam computed

tomography (CBCT), Liu and coworkers (2008) found an even more frequent labial displacement of the canines, with percentages of 45 (labial), 40 (palatal), and 18 (mid-alveolar).

Complications due to ectopic eruption of maxillary canines—such as root resorption of adjacent teeth, ankylosis of the canine, and (follicular) cyst formation—have been reported (Ericson and Kurol, 1987a, 1988, 2000; Liu *et al.*, 2008). Many studies have shown that root resorption in combination with ectopic maxillary canines occurs more often in female patients (Sasakura *et al.*, 1984; Ericson and Kurol, 1987b; Peck *et al.*, 1994; Rimes *et al.*, 1997). An accurate diagnosis of exact canine position and potential root resorptions may influence which of various orthodontic-surgical treatment options is chosen, such as: 1. orthodontic alignment of the impacted tooth after surgical exposure; 2. extraction of the resorbed lateral incisor, orthodontic alignment of the impacted tooth after surgical exposure in the position of the extracted tooth, space closure, and reshaping

of the canine to serve as lateral incisor; 3. orthodontic alignment of the impacted tooth after surgical exposure, extraction of the resorbed lateral incisor, and replacement of the lateral incisor by autotransplantation or implantation (Bjerklin and Ericson 2006; Alqerban *et al.*, 2009a,b).

CBCT studies analysing the location of impacted maxillary canines and related root resorption of adjacent incisors are still rare in the literature (Walker *et al.*, 2005; Liu *et al.*, 2008; Oberoi and Knuettel, 2012). Some of these studies have a small sample size and report only limited correlations between canine impaction and root resorption. Furthermore, the data lacks information regarding interrater reliability of the radiographic image analysis.

Sound justification of radiographic examinations in children and young adults is important due to the higher risks associated with exposure (Horner *et al.*, 2011). Traditional radiological examination of children undergoing orthodontic assessment relies on a panoramic radiograph, supplemented by a lateral cephalometric and intraoral radiographs. In recent years, the availability of CBCT has led to this technique being used by a growing number of clinicians as a means of radiological examination. A recent review of Kapila and coworkers (2011) provides a useful summary of the current status of CBCT in orthodontics.

In this study, the primary outcome variables were to evaluate the three-dimensional location of impacted maxillary canines, the frequency, extent, and determinants of root resorptions of neighbouring teeth using CBCT imaging. The secondary outcome variables analyse the interrater reliability between observers of two different dental specialties for radiographic parameters.

Materials and methods

Patients

CBCT images from patients who were referred for radiographic localization of impacted/ectopically erupting maxillary canines (uni- or bilateral) with or without suspicion of resorption of neighbouring teeth were consecutively admitted to the present study. The database between January 2009 and December 2010 of the Section of Dental Radiology and Stomatology, Department of Oral Surgery and Stomatology, University of Bern, was used. Patients with a known cleft palate were excluded from further analysis.

Methods

To keep the radiation dose to a minimum, all CBCT images were taken using a limited or dentoalveolar field of view (FOV: 4×4 , 6×6 , or 8×8 cm; 3D Accuitomo XYZ Slice View Tomograph, Morita Corp., Kyoto, Japan) so that only the area of clinical interest was irradiated. A basic voxel size of 0.08 mm was used for evaluation of all FOVs included. The operating parameters were set at 5.0 mA and 80 kV, and the exposure time was 17.5 seconds. The data were reconstructed in slices, and examined slice by slice in all three

dimensions (sagittal, coronal, and axial) on 1:1 scaled images using a specialized software program (i-Dixel, Morita Corp., Kyoto, Japan). Initially, all images were reformatted to place the palate/floor of the nose in a horizontal position in the sagittal views, and the central incisors in a vertical position in the coronal views. When needed, the magnifying tool and the ruler of the viewer were used. The following analysis and measurements were performed for every included subject:

1. Three-dimensional localization of the impacted canine:
 - (a) Sagittal: location of the crown of the impacted canine in relation to the neighbouring teeth (mostly lateral incisors) classified in labial, median, or palatal position (Figure 1) was assessed using sagittal and/or coronal CBCT scans.
 - (b) Vertical: location of the cusp tip in relation to the long axis of the neighbouring incisor, subdivided into coronal, cervical third of the root, middle third of the root, apical third of the root, or apical to the root tip (Figure 2).
 - (c) Transversal: measurement of the cusp tip in relation to the midline based on the linear measurement methods proposed by Walker *et al.* (2005). The shortest distance between the tip of the impacted canine and the mid-palatal sutures was measured perpendicularly in mm on respective axial CBCT scans (Figure 3).
2. Type of impaction in relation to the bone, grouped into full bony impaction, retention with soft tissue coverage, or retention without soft tissue coverage.
3. Development of the root of the impacted canine, classified as complete root development with closed apex, almost complete root development with open apex, $\frac{3}{4}$ of the root length developed, or $\frac{1}{2}$ of the root length developed.
4. Follicle size measurement at the widest area of the follicle perpendicular to the crown of the impacted canine on

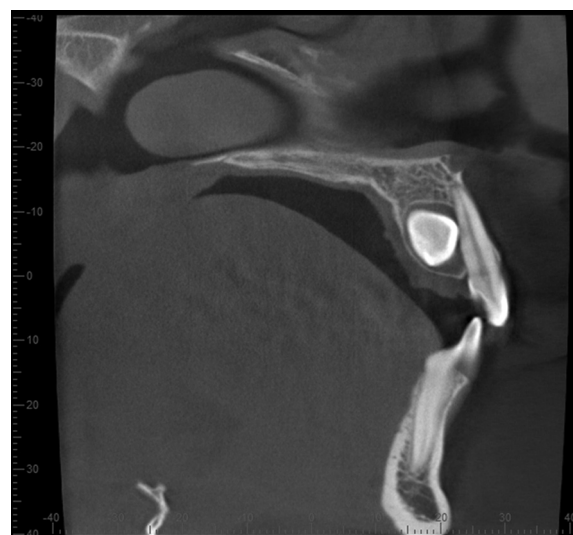


Figure 1 Representative example of a sagittal CBCT scan exhibiting a palatally located impacted canine.

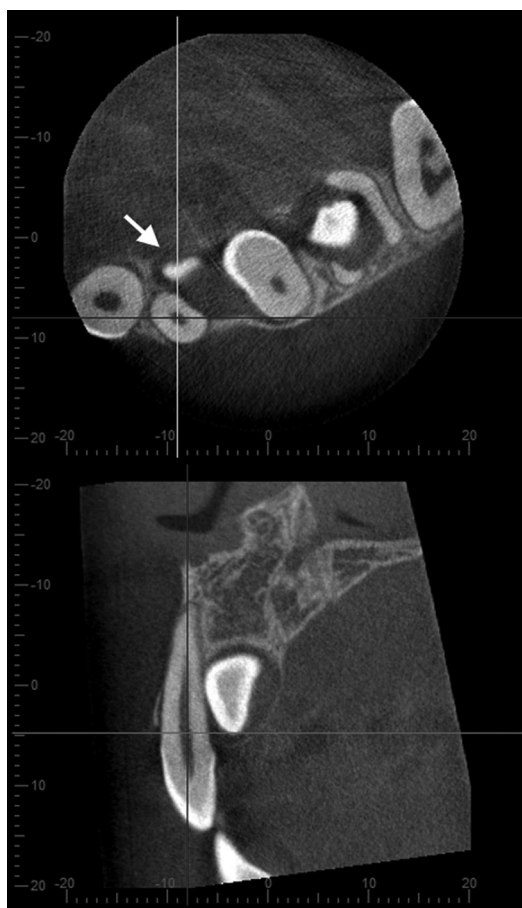


Figure 2 Vertical location of the cusp tip (arrow) in relation to the long axis of the neighbouring lateral incisor on sagittal and axial CBCT scans, representative example.

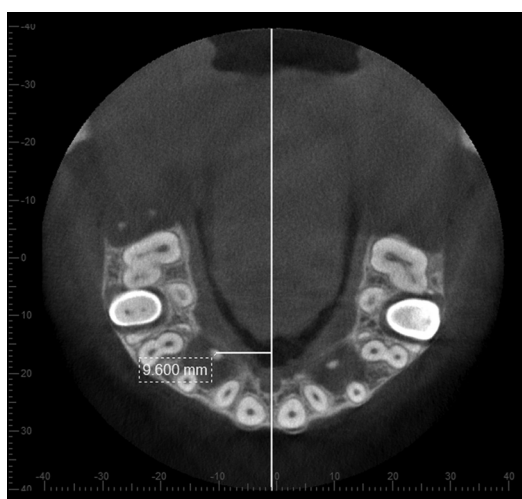

Figure 3 Example of transversal measurement of the distance between the canine cusp tip in relation to the maxillary midline on an axial CBCT scan.

coronal and axial CBCT slices. Distances greater than 3 mm were considered to be an enlarged follicle (Ericson *et al.*, 2001).

5. Presence of deciduous canines and possible root resorption of deciduous canines, subdivided into missing canine, canine with intact root, or resorbed root.
6. Morphology of the lateral incisor: missing, peg shaped, and normal.
7. Proximity to and/or direct contact of the impacted canine with incisors or premolars (yes/no). Proximity was defined by ≤ 0.5 mm distance between the two teeth (Walker *et al.*, 2005). If yes: location of the contact in relation to the long axis of the involved tooth, classified as the cervical, middle, or apical third of the root.
8. Root resorption of incisors or other teeth (premolars and deciduous canines). Location of the root resorption in relation to the long axis of the involved tooth, classified as the cervical, middle, or apical third of the root. Resorption was graded based on the system suggested by Ericson and Kurol (2000):
 - (a) No resorption: intact root surface, the cementum layer may have been lost.
 - (b) Slight resorption: resorption up to half of the dentine thickness (Figure 4A).
 - (c) Moderate resorption: resorption of the dentine midway to the pulp or more, the pulp lining being unbroken (Figure 4B).
 - (d) Severe resorption: resorption reaches the pulp (Figure 4C).

All CBCT scans were reviewed by a single experienced orthodontist (C.S.L.). Additionally, the sagittal location of the impacted canine, and the presence, location, and severity of root resorption of neighbouring teeth, were also independently evaluated by another orthodontist (L.M.) and an oral surgeon (B.M.H.) to evaluate interrater agreement. To quantify the correlation between impaction and resorption (primary outcome variables), any disagreement between the observers was resolved by discussion for further analysis.

Statistical analysis

Summary statistics were calculated for all assessed parameters. To assess interrater agreement, unweighted Cohen's kappas were calculated. Logistic regression was used to calculate crude as well as age- and gender-adjusted odds ratios, and two-sided 95% confidence intervals (CI) were calculated to evaluate the association between various factors and the prevalence of root resorption of at least one adjacent tooth. To account for clustering of bilateral teeth, generalized estimating equations with an exchangeable correlation matrix were used. All statistical tests were two-sided at $\alpha = 0.05$ and were performed using STATA 11.2 (Stata Corp., College Station, TX, USA).

Results

In this study, a total of 113 patients with CBCT scans were enrolled, and 134 impacted canines were analysed retrospectively. The mean age of the patients was 19.35 years

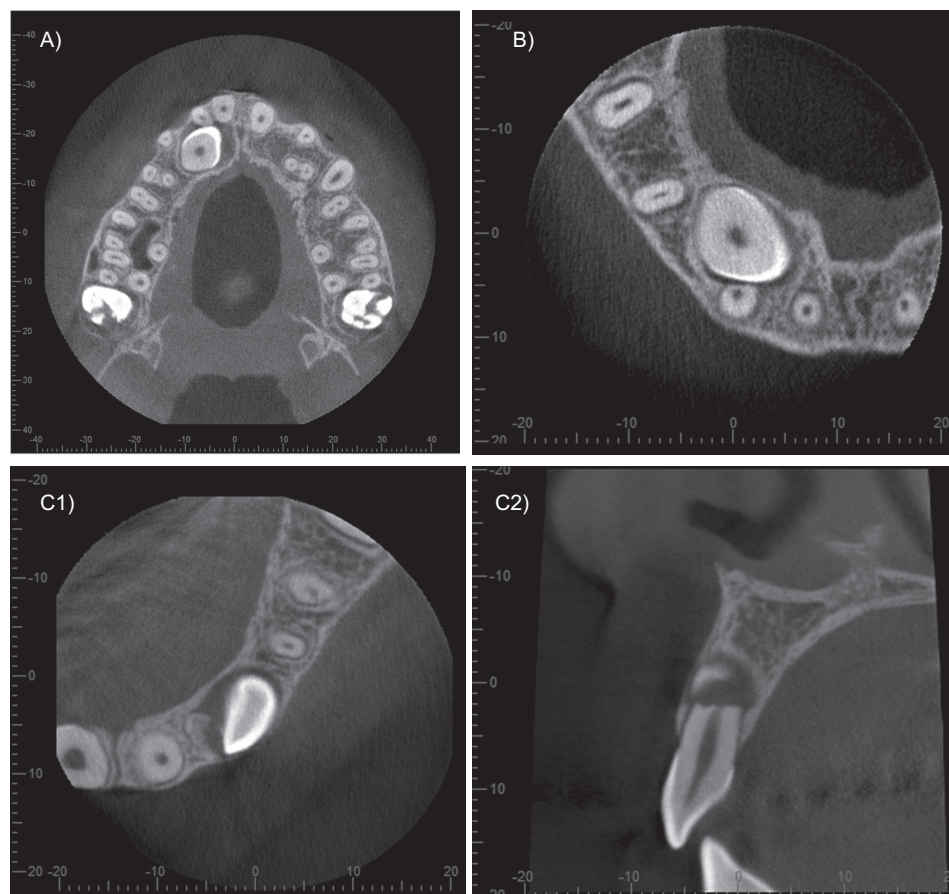


Figure 4 Representative example of different types root resorption: (A) slight root resorption on a right lateral incisor; (B) moderate root resorption on a right lateral incisor; (C1) severe root resorption on a left lateral incisor (axial CBCT scan); (C2) Same patient as in C1 (sagittal CBCT scan).

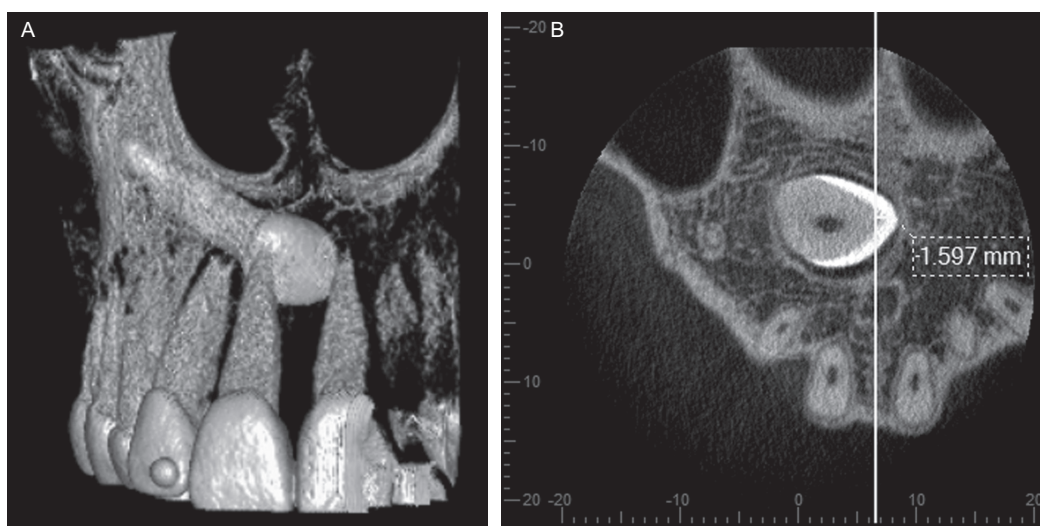

Figure 5 Representative example of an impacted canine crossing the maxillary midline (A: volume rendered image and B: axial CBCT scan).

(range: 8.7–77.2 years, $SD \pm 13.65$ years). Of the 113 included patients, 39 (34.51 per cent) were male and 74 (65.49 per cent) were female (Table 1). Unilateral impaction was present in 92 patients (81.4 per cent), and 21 patients (18.6 per cent)

presented with bilateral impaction. Among these, 64 impacted canines were located on the right side (47.76 per cent).

The analysis of the three-dimensional location revealed that most of the impacted canines were located in a palatal

Table 1 Descriptive data regarding morphology and location of impacted canines.

Canines	<i>n</i> = 134, unilateral = 92 (81.42%), bilateral = 21 (18.58%)		
Patients	<i>n</i> = 113		
Age (mean)	19.35 years, range = 8.7–77.2 years		
Gender	Male	39 (34.51%)	
	Female	74 (65.49%)	
Canine type	Right	64 (47.76%)	
	Left	70 (52.24%)	
Root development	Complete root, closed apex	82 (61.19%)	
	Complete root, open apex	27 (20.15%)	
	¾ Root development	22 (16.42%)	
	½ Root development	3 (2.24%)	
Follicle size	<3 mm “no”	51 (38.06%)	
	≥3 mm “yes”	83 (61.94%)	
Deciduous canine	Missing	88 (65.67%)	
	Existent, resorbed	35 (26.12%)	
	Existent, not resorbed	11 (8.21%)	
Morphology of lateral incisor	Missing	4 (2.99%)	
	Normal	95 (70.90%)	
	Peg shaped	35 (26.12%)	
Canine localization sagittal	Labial	41 (30.60%)	
	Palatal	69 (51.49%)	
	Median	24 (17.91%)	
Canine localization in relation to bone	Full bony impaction	57 (42.54%)	
	Retention with soft tissue coverage	72 (53.73%)	
	Retention without soft tissue coverage	5 (3.73%)	
Canine localization vertical	Coronal	25 (18.66%)	
	Cervical third	44 (32.84%)	
	Middle third	33 (24.63%)	
	Apical third	27 (20.15%)	
	Supraapical	5 (3.73)	
Canine localization transversal	Mean = 8.74 mm, range = –1.6–26 mm, SD ± 5.3 mm		

	Central incisor	Lateral incisor	First premolar	Second premolar
Proximity/direct contact	No = 99 (73.88%) Yes = 35 (26.12%)	No = 29 (21.64%) Yes = 101 (75.37%) Missing = 4 (2.99%)	No = 112 (83.58%) Yes = 22 (16.42%)	No = 131 Yes = 3 (2.24%)
Location of proximity/direct contact				
Cervical third	7 (5.22%)	14 (10.45%)	4 (2.99%)	1 (0.75%)
Middle third	19 (14.18%)	58 (43.28%)	7 (5.22%)	0
Apical third	9 (6.72%)	29 (21.64%)	11 (8.21%)	2 (1.49%)
Resorption	No = 127 (94.78%) Yes = 7 (5.22%)	No = 96 (71.64%) Yes = 34 (25.37%)	No = 128 (95.52%) Yes = 6 (4.48%)	No = 133 (99.25%) Yes = 1 (0.75%)
Location of resorption				
Cervical third	0	2 (1.49%)	0	0
Middle third	4 (2.99%)	16 (11.49%)	2 (1.49%)	0
Apical third	3 (2.24%)	16 (11.49%)	4 (2.99%)	1 (0.75%)
Severeness of resorption				
Mild	3 (2.24%)	12 (8.96%)	3 (2.24%)	1 (0.75%)
Moderate	1 (0.75%)	5 (3.73%)	0	0
Severe	3 (2.24%)	17 (12.69%)	3 (2.24%)	0

position (51.49 per cent, 69 canines), and only 30.6 per cent (41 canines) were located buccally. In most cases, the vertical location of the canine cusp tip in relation to the long axis of the adjacent tooth was in the cervical third of the root (32.84 per cent, 44 teeth), followed by a location in the middle third (24.63 per cent, 33 canines), and in the apical third (20.15 per cent, 27 canines). The mean distance of the cusp tip of the impacted canine to the midline of the upper jaw was 8.74 mm (range: 1.6–26 mm). Only two impacted canines crossed the transversal midline (Figure 5). Transposition of the impacted canine was found in only two cases. For further details, see Table 1.

In relation to the bone, most canines exhibited retention with soft tissue coverage (53.73 per cent, 72 canines), followed by canines with complete bone coverage (42.54 per cent, 57 canines). In 61.94 per cent (83 cases) of the cases, the follicle was enlarged. In the population analysed, 35 peg-shaped laterals (26.12 per cent) and 4 missing laterals (2.99 per cent) were found. In 82 cases the impacted canines showed complete root development (81.34 per cent), and in 27 cases the root development was almost complete. For further details, see Table 1.

For the 134 ectopic canines, 41 adjacent incisors exhibited signs of resorption: 34 lateral incisors (25.37 per cent) and 7 central incisors (5.22 per cent). In six cases with root resorption on central incisors, the lateral incisors exhibited signs of resorption as well. Only six adjacent first premolars (4.48 per cent) and one second premolar (0.75 per cent) with root resorption were found. Among the 21 bilateral cases, there were 4 cases with bilateral root resorption on adjacent incisors and 2 cases with only one side affected. Root resorption on permanent incisors was located primarily in the middle third of the root (48.78 per cent), followed by the apical third of the root (46.34 per cent) and the cervical third of the root (4.88 per cent). In 36 cases there was a visible contact between the impacted canine and the resorbed incisor. For further details, see Table 1.

There was no correlation between age of the patient and prevalence of root resorption ($P = 0.49$), but a slightly higher prevalence of resorption was found for older patients when the patients were divided by age into two groups: ≥ 18 years and < 18 years, although this difference was not statistically significant ($P = 0.316$). A statistically significant higher prevalence of root resorption was present when there was complete root development of the impacted canine with a closed apex compared with when there was incomplete root development of the canine ($P = 0.049$). Although not statistically significant, female subjects seemed to be more affected than male subjects ($P = 0.39$). For further details, see Table 2.

Visible contact between the impacted canines and the neighbouring teeth with and without root resorption was frequently found, mostly for lateral incisors (101 cases), for central incisors (35 cases), for first premolars (22 cases), and for second premolars (3 cases). The location of contact

was found to be in the middle third of the root in 84 of the cases (52.17 per cent), in the apical third in 51 cases (31.68 per cent), and in the cervical third in 26 cases (16.15 per cent). For further details, see Table 1.

With regard to root resorption and three-dimensional localization of the canines in the sagittal plane, there was no difference in prevalence of root resorption on adjacent teeth between labially and palatally impacted canines ($P = 0.375$). Regarding retention with or without soft tissue or bone coverage, there was a higher prevalence of root resorption in adjacent teeth when the canine was fully covered by bone ($P = 0.043$). Furthermore, there was a significant correlation between prevalence of root resorption and location of the cusp tip in the vertical plane in relation to the long axis of the adjacent teeth. Compared to a coronal or supraapical location of the cusp tip, there was a higher risk of resorption when the cusp tip was located in the cervical, middle, or apical third of the root of the adjacent tooth ($P = 0.01$). Furthermore, no correlation could be found between root resorption and peg-shaped ($P = 0.878$) or missing laterals ($P = 0.581$). For further details, see Table 2.

In 46 of the cases, deciduous canines were still present, and 34 of those exhibited resorbed roots. In 20 cases with root resorptions, the follicle of the impacted canine was enlarged. Direct contact between the impacted canine and the resorbed deciduous tooth was found in only 2 out of 34 (5.9 per cent) deciduous canines, compared with 41 out of 49 (83.7 per cent) resorbed permanent teeth (OR 88.3, 95% CI 17.1, 457).

Interrater agreement evaluated for the sagittal location of the impacted canine, and the presence, location, and severity of root resorption of neighbouring teeth for the three different observers exhibited values ranging from 0.546 to 0.877 (Cohen's kappa; Table 3).

Discussion

The prevalence of disturbances in eruption of the maxillary canines seems to vary within a range of 1–3 per cent (Preda *et al.*, 1997; Chaushu *et al.*, 1999; Mason *et al.*, 2001; Walker *et al.*, 2005), and females seem to be more affected (Becker *et al.*, 1981; Preda *et al.*, 1997; Ericson and Kurol 2000). In our study, there were more female subjects than males resulting in a ratio of almost 2:1. Walker and coworkers (2005) speculate that the difference in overall craniofacial growth and development between the sexes, as well as genetics, could be possible reasons for that finding. Another reason could be that girls and women seek orthodontic treatment more frequently than males. Furthermore, Zilberman and coworkers postulate that an experimental group represents a biased sample and may show higher or different gender ratios than in a true epidemiological (general) population (Zilberman *et al.*, 1990).

In our study sample, we found a high prevalence of palatally impacted canines (51.49 per cent). In European and North American samples, impacted maxillary canines

Table 2 Statistical analysis regarding root resorptions in correlation with various clinical/radiographic parameters.

Variable	Crude estimates			Adjusted age and gender		
	OR	95% CI	Level of significance	OR	95% CI	Level of significance
Age						
≥18 years	1.00	Reference		—	—	—
<18 years	0.61	(0.24,1.59)	$P = 0.316$	—	—	—
Gender						
Male	1.00	Reference		—	—	—
Female	1.44	(0.62,3.32)	$P = 0.393$			
Root development						
Complete root, closed apex	1.00	Reference		1.00	Reference	
Complete root, open apex	0.79	(0.30,2.07)	$P = 0.630$	0.68	(0.25,1.85)	$P = 0.451$
Incomplete root development (1/2–3/4)	0.34	(0.10,1.12)	$P = 0.077$	0.28	(0.08,0.99)	$P = 0.049$
Follicle						
<3 mm “no”	1.00	Reference		1.00	Reference	
≥3 mm “yes”	1.78	(0.81,3.89)	$P = 0.148$	1.93	(0.80,4.64)	$P = 0.144$
Localization sagittal						
Labial	1.00	Reference		1.00	Reference	
Palatal	0.68	(0.23,1.58)	$P = 0.375$	0.71	(0.29,1.75)	$P = 0.461$
Median	0.56	(0.18,1.77)	$P = 0.326$	0.57	(0.18,1.83)	$P = 0.345$
Localization in relation to bone						
Full bony impaction	1.00	Reference		1.00	Reference	
Retention with/without soft tissue coverage	0.46	(0.22,0.98)	$P = 0.043$	0.45	(0.21,0.97)	$P = 0.042$
Localization vertical						
Coronal/supraapical	1.00	Reference		1.00	Reference	
Cervical third	3.81	(1.11,12.96)	$P = 0.032$	3.98	(1.17,13.59)	$P = 0.027$
Middle third	4.00	(1.12,14.25)	$P = 0.033$	4.27	(1.16,15.64)	$P = 0.029$
Apical third	4.45	(1.13,15.74)	$P = 0.021$	4.68	(1.31,16.72)	$P = 0.017$
Localization vertical						
Coronal/supraapical	1.00	Reference		1.00	Reference	
Cervical/middle/apical third	4.05	(1.31,12.49)	$P = 0.015$	4.27	(1.37,13.26)	$P = 0.01$
Lateral incisors						
Normal	1.00	Reference		1.00	Reference	
Peg shaped	0.95	(0.40,2.24)	$P = 0.913$	0.93	(0.40,2.21)	$P = 0.878$
Missing	0.42	(0.03,6.74)	$P = 0.540$	0.46	(0.03,7.29)	$P = 0.581$

Table 3 Interrater agreement between two experienced orthodontists (C.L. and L. M.) and an oral surgeon (B.H.) using Cohen's kappa values.

Variable	Kappa values
Labiopalatal location of the impacted canine	0.877
Prevalence of proximity/direct contact	0.858
Location of proximity/direct contact	0.546
Prevalence of root resorption	0.649
Severity of root resorption	0.783

Kappa values: no agreement, <0; slight, 0–0.2; fair, 0.21–0.40; moderate, 0.41–0.60; substantial, 0.61–0.80; almost perfect, 0.81–1 (Landis and Koch, 1977)

were also more often found to be located palatally (85–92.6 per cent) (Preda *et al.*, 1997; Ericson and Kurol 2000). In Asian samples, however, impacted canines were more often located buccally (45.2 per cent) than palatally (40.5

per cent) (Liu *et al.*, 2008). Earlier studies have shown that labial and palatal displacement of maxillary canines are very different phenomena (Jacoby, 1983; Peck *et al.*, 1994). Labial displacement is usually due to an inadequate dental arch space, whereas palatal displacement often occurs despite adequate arch space. The etiology of palatally displaced canines can be divided into local or genetic factors. Local factors, such as persistent deciduous canines, delayed eruptive pathways, and missing or anomalous lateral incisors, have been described (Bass, 1967; Becker *et al.*, 1981). Differences between various studies with regard to prevalence and location of impacted canines may also be due to differences in patient selection.

The etiology of root resorption is still unclear. It has been postulated that enlarged dental follicles, as well as the pressure caused by an erupting tooth, may be responsible for root resorption of adjacent teeth (Marks *et al.*, 1997). However, Ericson and coworkers (2001) have concluded, based on a CT examination, that the dental follicle does not

cause root resorption of permanent teeth. They concluded that resorption of the permanent maxillary incisor is caused by the physical contact between the incisor and the canine, and by direct pressure from the canine as a part of the eruption process (Ericson *et al.*, 2001). An ectopic canine with a well-developed root, erupting medially to the long axis of the adjacent incisor and inclined $\geq 25^\circ$ to the midline of the jaw, presented the greatest risk for root resorption of the lateral incisor (Ericson and Kurol, 1987b, 2000).

This study supports previous findings that there is a correlation between prevalence of root resorption of permanent teeth and proximity/contact of the impacted canine. In the present sample, 30 resorbed lateral incisors showed proximity/contact with the impacted canine, as did 6 resorbed central incisors, 5 resorbed first premolars, and 1 resorbed second premolar. Only four lateral incisors, one central incisor, and one first premolar were resorbed without direct canine contact. In this study, there was an overall but not statistically significant tendency for enlarged canine follicles to occur together with root resorption. Therefore, our study supports the findings of Ericson and coworkers (2001), but due to the limited sample size some caution is still necessary. In addition, there seems to be a borderline statistical risk of root resorption if the root development of the impacted canine was complete and the apex closed compared with incomplete root development.

The position of the impacted canine may have an influence on root resorption. There was a higher but not statistically significant prevalence of root resorption when the canine was located labially. A significant correlation between root resorption and full bony impaction of the canine was found ($P = 0.043$). Furthermore, there may be a higher risk of root resorption of neighbouring teeth when the cusp tip is located along the long axis of the root of the adjacent tooth, and there seems to be a significantly lower risk of root resorption when the canine cusp tip is located supraapically or coronally. There was no correlation between root resorption and gender in our study. Nonetheless, females seem to have a tendency toward higher risk of root resorption, which was also documented in previous reports (Ericson and Kurol, 1987b, 2000).

The reported incidence of root resorption also depends on the radiographic imaging method used. Conventional periapical X-rays have been shown to be an inaccurate method for diagnosing root resorption (Ericson and Kurol, 1987a,b). The prevalence of root resorption on maxillary incisors using intraoral X-rays was reported to be 12 per cent (Ericson and Kurol, 1987b). Even when using a step-wise (Ericson and Kurol, 1986) or the tube shift method (Clark, 1909), as well as in combination with panoramic views and lateral cephalographs, root resorption may be overlooked in 50 per cent of the cases (Chaushu *et al.*, 1999; Ericson and Kurol, 2000; Mason *et al.*, 2001; Heimisdottir *et al.*, 2005). By using three-dimensional visualization, the diagnostic accuracy is significantly increased, since beam

projection is always orthogonal and provides information in all three planes of the skull (Becker *et al.*, 2010; Haney *et al.*, 2010; Pazera *et al.*, 2011). CBCT for three-dimensional visualization was introduced in dentistry more than a decade ago (Mah *et al.*, 2003). CBCT scans have become established for orthodontic diagnostic and treatment planning procedures, such as the localization of ectopic teeth, evaluation before orthognathic surgery, visualization of the temporomandibular joint, airway analysis, and the assessment of cleft palate patients (Nakajima *et al.*, 2005; Bjerklin and Ericson, 2006; Bornstein *et al.*, 2010). *In vitro* studies on human skulls have shown no significant differences between different CBCT systems for assessing the severity of root resorptions (Alqerban *et al.*, 2009a, 2011b). Nevertheless, different voxel sizes of different CBCT devices could influence the detectability of initial or slight root resorptions. There is definitely a need to evaluate the influence of different CBCT operating parameters on the diagnosis and classification of severity of root resorptions.

In a CT study analysing 12 patients with 17 impacted canines, Ericson *et al.* (2000) found that the ipsilateral lateral incisor was the tooth most commonly affected by root resorption (38 per cent), followed by the ipsilateral central incisor (9 per cent). In addition, there was a high correlation between the CT diagnosis and direct visual observation of the roots of extracted teeth. Liu *et al.* (2008) found root resorption in 27.2 per cent of lateral and 23.4 per cent of central incisors. Root resorption on premolars appears to be rare (Postlethwaite, 1989; Cooke and Nute, 2005). In our study, we found root resorption in 25.37 per cent of the lateral incisors, 5.22 per cent of the central incisors, 4.48 per cent of the first premolars, and 0.75 per cent of the second premolars. A lower percentage (17.7 per cent) of root resorption on permanent teeth was reported in a recent study evaluating CT scans (Cernochova *et al.*, 2011), with a prevalence of 12.6 per cent for lateral incisors, 4.8 per cent for first premolars, and 2.1 per cent for central incisors. In contrast to our study, only 'severe' root resorption was recorded, explaining the lower percentages.

Root resorption as result of impacted canines seems to be a rapid, progressive process that almost always ceases once the impacted canine has been removed from the affected root area (Becker and Chaushu, 2005). Even with pulpal involvement, lateral incisors with root resorption may not exhibit clinical symptoms and may show good long-term healing and prognosis (Milberg, 2006; Falahat *et al.*, 2008). Previous studies have shown that the amount of information obtained from three-dimensional analysis is significantly greater than from conventional periapical and panoramic radiography (Ericson and Kurol, 2000; Alqerban *et al.*, 2011a), and consequently this may have an influence on the treatment plan (Bjerklin and Ericson, 2006; Botticelli *et al.*, 2010; Haney *et al.*, 2010; Wriedt *et al.*, 2012). Bjerklin and Ericson (2006) have shown that almost 44 per cent of the treatment plans were modified after CT investigations brought further information about the presence of root resorption.

CBCT provides accurate information about location of the canine, which is of diagnostic importance for planning potential surgical procedures (Becker *et al.*, 2010). Despite the expected advantage of CBCT imaging in tooth localization, it is important to consider also the impact on management of patients, the increased radiation dose and the likely higher cost of CBCT examinations in comparison with conventional radiography that has served dentists and specialist orthodontists well over many years. In a recent systematic review, the SEDENTEXCT consortium suggests (Horner *et al.*, 2011) that where it was practice to use multi-slice CT scans for localization of unerupted teeth (Alqerban *et al.*, 2009b), CBCT is likely to be preferred today.

CBCT has clear advantages over CT, the most important being less radiation administered to the patient (Cohenca *et al.*, 2007; Hirsch *et al.*, 2008). Nevertheless, it is of importance to use smaller FOV for CBCT imaging when possible, thus adhering to the ALARA (as low as reasonably achievable) principle in medical radiology (McCollough *et al.*, 2009). To the best of our knowledge, this study is the first in the dental literature to assess interrater agreement for the severity and location of root resorption between three observers from different dental specialties. In previous studies, CBCT or CT scans were analysed by one single observer (Cernochova *et al.* 2011), or twice at two different time points by the same observer (Liu *et al.*, 2008), with assessment of intrarater reliability.

This study resulted in high interrater agreement as to the location of the impacted canine in the sagittal plane and the prevalence of proximity/direct contact of the impacted canine and the adjacent roots. Furthermore, there was substantial agreement between the two orthodontists and the oral surgeon in assessing the prevalence and the severity of root resorption on adjacent teeth – a finding that certainly has a major impact on treatment planning. To assess potential differences between orthodontists and oral surgeons in evaluating CBCT images, more observers would be needed. However, there was only a moderate agreement for the location of proximity. Although a ruler was used, the predefined range of ≤ 0.5 mm for defining a contact between teeth may be a factor influencing interrater reliability. Future studies are needed to evaluate if and how diagnostic parameters can be refined to result in higher interrater reliability scores.

Conclusions

Precise localization of an impacted canine in the sagittal plane, as well as assessment of the presence and degree of root resorption of neighbouring teeth, is mandatory in order for surgeons and orthodontists to be able to make an accurate diagnosis and interdisciplinary treatment plan. When used to supplement clinical examination and conventional radiographic imaging, CBCT provides additional accurate information about location of the impacted canine and

prevalence and degree of root resorption of neighbouring teeth, with high interrater correlation. This study found a statistically significant correlation between root resorption on adjacent teeth and localization of the impacted canine in relation to bone or soft tissue coverage as well as vertical localization of the impacted canine in relation to the long axis of the neighbouring incisor.

Acknowledgements

The authors are grateful to Walter B. Bürgin, School of Dental Medicine, University of Bern, for his assistance in the statistical analysis.

References

- Alqerban A, Jacobs R, Souza P C, Willems G 2009a In-vitro comparison of 2 cone-beam computed tomography systems and panoramic imaging for detecting simulated canine impaction-induced external root resorption in maxillary lateral incisors. *American Journal of Orthodontics and Dentofacial Orthopedics* 136: 764.e1–11
- Alqerban A, Jacobs R, Lambrechts P, Loozen G, Willems G 2009b Root resorption of the maxillary lateral incisor caused by impacted canine: a literature review. *Clinical Oral Investigations* 13: 247–255
- Alqerban A, Jacobs R, Fieuws S, Willems G 2011a Comparison of two cone beam computed tomographic systems versus panoramic imaging for localisation of impacted maxillary canines and detection of root resorption. *European Journal of Orthodontics* 33: 93–102
- Alqerban A, Jacobs R, Fieuws S, Nackaerts O, The SEDENTEXCT Project Consortium, Willems G 2011b Comparison of 6 cone-beam computed tomography systems for image quality and detection of simulated canine impaction-induced external root resorption in maxillary lateral incisors. *American Journal of Orthodontics and Dentofacial Orthopedics* 140: e129–139
- Bass T B 1967 Observations on the misplaced upper canine tooth. *The Dental Practitioner* 18: 25–33
- Becker A, Chaushu S 2005 Long-term follow-up of severely resorbed maxillary incisors after resolution of an etiologically associated impacted canine. *American Journal of Orthodontics and Dentofacial Orthopedics* 127: 650–654
- Becker A, Chaushu S, Casap-Caspi N 2010 Cone-beam computed tomography and the orthosurgical management of impacted teeth. *Journal of the American Dental Association* 141: 14S–18S
- Becker A, Smith P, Behar R 1981 The incidence of anomalous maxillary lateral incisors in relation to palatally-displaced cuspids. *Angle Orthodontist* 51: 24–29
- Bornstein M M, Pazera P, Katsaros C 2010 The use of three-dimensional reconstructions in the diagnosis of impacted teeth. In: Daskalaki A (ed.). *Informatics in oral medicine: advanced techniques in clinical and diagnostic technologies*. Hershey: Medical Information Science Reference, pp. 171–181
- Botticelli S, Verna C, Cattaneo P M, Heidmann J, Melsen B 2010 Two-versus three-dimensional imaging in subjects with unerupted maxillary canines. *European Journal of Orthodontics* 33: 344–349
- Bjerklin K, Ericson S 2006 How a computerized tomography examination changed the treatment plans of 80 children with retained and ectopically positioned maxillary canines. *Angle Orthodontist* 76: 43–51
- Cernochova P, Krupa P, Izakovicova-Holla L 2011 Root resorption associated with ectopically erupting maxillary permanent canines: a computed tomography study. *European Journal of Orthodontics* 33: 483–491
- Chaushu S, Chaushu G, Becker A 1999 The use of panoramic radiographs to localize displaced maxillary canines. *Oral Surgery, Oral Medicine, Oral Pathology, Oral Radiology, and Endodontology* 85: 511–516

- Clark C A 1909 Radiographs of the teeth and associated parts. *Proceedings of the Royal Society of Medicine* 2: 39–46
- Cohenca N, Simon J H, Roges R, Morag Y, Malfaz J M 2007 Clinical indications for digital imaging in dento-alveolar trauma. Part 1: Traumatic injuries. *Dental Traumatology* 23: 95–104
- Cooke M E, Nute S J 2005 Maxillary premolar resorption by canines: three case reports. *International Journal of Paediatric Dentistry* 15: 210–212
- Ericson S, Bjerklin K, Falahat B 2001 Does the canine dental follicle cause resorption of permanent incisor roots? A computed tomographic study of erupting maxillary canines. *Angle Orthodontist* 72: 95–104
- Ericson S, Kurol J 1986 Radiographic assessment of maxillary canine eruption in children with clinical signs of eruption disturbance. *European Journal of Orthodontics* 8: 133–140
- Ericson S, Kurol J 1987a Radiographic examination of ectopically erupting maxillary canines. *American Journal of Orthodontics and Dentofacial Orthopedics* 91: 483–492
- Ericson S, Kurol J 1987b Incisor resorption caused by maxillary cuspids. A radiographic study. *Angle Orthodontist* 57: 332–346
- Ericson S, Kurol J 1988 Resorption of maxillary lateral incisors caused by ectopic eruption of the canines: A clinical and radiographic analysis of predisposing factors. *American Journal of Orthodontics and Dentofacial Orthopedics* 94: 503–513
- Ericson S, Kurol J 2000 Incisor resorptions due to ectopic maxillary canines imaged by computerized tomography: a comparative study in extracted teeth. *Angle Orthodontist* 70: 276–283
- Falahat B, Ericson S, Mak D'Amico R, Bjerklin K 2008 Incisor root resorption due to ectopic maxillary canines: a long-term radiographic follow-up. *Angle Orthodontist* 78: 778–785
- Haney E, Gansky S A, Lee J S, Johnson E, Maki K, Miller A J, Huang J C 2010 Comparative analysis of traditional radiographs and cone-beam computed tomography volumetric images in the diagnosis and treatment planning of maxillary impacted canines. *American Journal of Orthodontics and Dentofacial Orthopedics* 137: 590–597
- Heimisdottir K, Bosshardt D, Ruf S 2005 Can the severity of root resorption be accurately judged by means of radiographs? A case report with histology. *American Journal of Orthodontics and Dentofacial Orthopedics* 128: 106–109
- Hirsch E, Wolf U, Heinicke F, Silva M A 2008 Dosimetry of the cone beam computed tomography Veraviewepocs 3D compared with the 3D Accutomo in different fields of view. *Dentomaxillofacial Radiology* 37: 268–273
- Horner K, Armitt G, 2011 SEDENTEXCT project members 2011 Radiation protection: cone beam CT for dental and maxillofacial radiology. Evidence based guidelines. v2.0 final. (http://www.sedentexct.eu/files/guidelines_final.pdf)
- Jacoby H 1983 The etiology of maxillary canine impactions. *American Journal of Orthodontics* 84: 125–132
- Kapila S, Conley R S, Harrell Jr W E 2011 The current status of cone beam computed tomography imaging in orthodontics. *Dentomaxillofacial Radiology* 40: 24–34
- Landis J R, Koch G G 1977 The measurement of observer agreement for categorical data. *Biometrics* 33: 159–174
- Liu D G, Zhang W L, Zhang Z Y, Wu Y T, Ma X C 2008 Localization of impacted maxillary canines and observation of adjacent incisor resorption with cone-beam computed tomography. *Oral Surgery, Oral Medicine, Oral Pathology, Oral Radiology, and Endodontology* 105: 91–98
- Mah J K, Danforth R A, Bumann A, Hatcher D 2003 Radiation absorbed in maxillofacial imaging with a new dental computed tomography device. *Oral Surgery, Oral Medicine, Oral Pathology, Oral Radiology, and Endodontology* 96: 508–513
- Marks S C, Schroeder H E, Andreasen J O 1997 Theories and mechanism of tooth eruption. In: Andreasen J O, Kölsen-Pedersen J, Laskin D M (eds). *Textbook and color Atlas of tooth impactions*. Mosby, St Louis, pp. 20–65
- Mason C, Papadakou P, Roberts G J 2001 The radiographic localization of impacted canines: a comparison of methods. *European Journal of Orthodontics* 23: 25–34
- Maverna R, Gracco A 2007 Different diagnostic tools for the localization of impacted maxillary canines: clinical considerations. *Progress in Orthodontics* 8: 28–44
- McCollough C H, Primak A N, Braun N, Kofler J, Yu L, Christner J 2009 Strategies for reducing radiation dose in CT. *Radiologic Clinics of North America* 47: 27–40
- Milberg D J 2006 Labially impacted maxillary canines causing severe root resorption of maxillary central incisors. *Angle Orthodontist* 76: 173–176
- Nakajima A, Sameshima G T, Arai Y, Homme Y, Shimizu N, Dougherty SrH 2005 Two- and three-dimensional orthodontic imaging using limited cone beam-computed tomography. *Angle Orthodontist* 75: 895–903
- Oberoi S, Kneuppel S 2012 Three-dimensional assessment of impacted canines and root resorption using cone beam computed tomography. *Oral Surgery, Oral Medicine, Oral Pathology, Oral Radiology* 113: 260–267
- Pazera P, Bornstein M M, Pazera A, Sendi P, Katsaros C 2011 Incidental maxillary sinus findings in orthodontic patients: a radiographic analysis using cone beam computed tomography (CBCT). *Orthodontics and Craniofacial Research* 14: 17–24
- Peck S, Peck L, Kataja M 1994 The palatally displaced canine as a dental anomaly of genetic origin. *Angle Orthodontist* 64: 249–256
- Peck S, Peck L, Kataja M 1996 Prevalence of tooth agenesis and peg-shaped maxillary lateral incisor associated with palatally displaced canine (PDC) anomaly. *American Journal of Orthodontics and Dentofacial Orthopedics* 110: 441–443
- Postlethwaite K M 1989 Resorption of premolar roots by ectopic canines. *British Dental Journal* 9: 23–24
- Preda L, La Fianza A, Di Maggio E M, Dore R, Schifino M R, Campani R *et al.* 1997 The use of spiral computed tomography in the localization of impacted maxillary canines. *Dentomaxillofacial Radiology* 26: 236–241
- Rimes J R, Mitchell C N T, Wilmott D R 1997 Maxillary incisor root resorption in relation to the ectopic canine: a review of 26 patients. *European Journal of Orthodontics* 19: 79–84
- Sasakura H, Yoshida T, Murayama S, Hanada K, Nakajima T 1984 Root resorption of upper permanent incisor caused by impacted canine. *International Journal of Oral Surgery* 13: 299–306
- Walker L, Enciso R, Mah J 2005 Three-dimensional localization of maxillary canines with cone-beam computed tomography. *American Journal of Orthodontics and Dentofacial Orthopedics* 128: 418–423
- Wriedt S, Jaklin J, Al-Nawas B, Wehrbein H 2012 Impacted upper canines: examination and treatment proposal based on 3D versus 2D diagnosis. *Journal of Orofacial Orthopedics* 73: 28–40
- Zilberman Y, Cohen B, Becker A 1990 Familial trends in palatal canines, anomalous lateral incisors, and related phenomena. *European Journal of Orthodontics* 12: 135–139