

BEST POSTERS IN NOVEL IMAGING TECHNIQUES IN HEART FAILURE

P6212

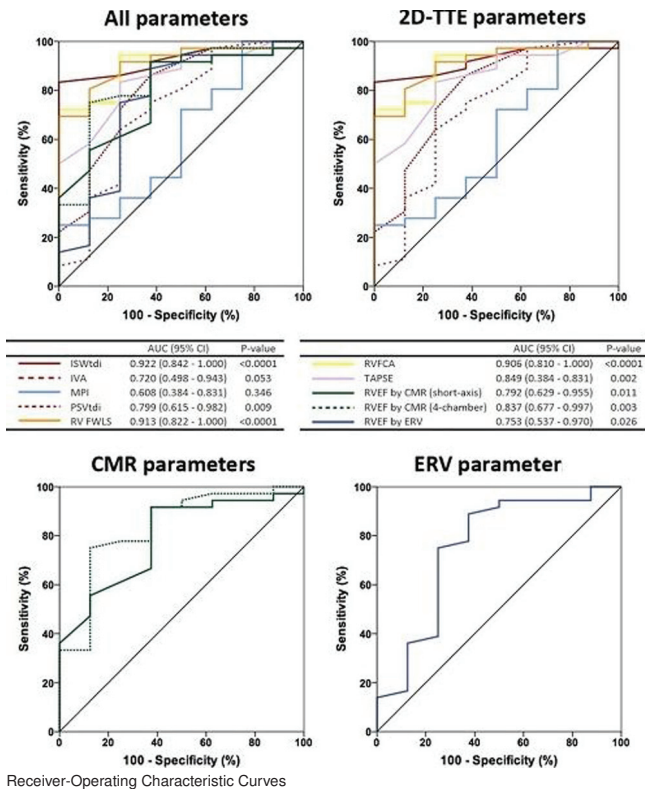
What is the best imaging technique to explore right ventricular function at the time of multimodality cardiovascular imaging?

S. Cazalbou¹, V. Chong Fah Shen¹, A. Petermann², D. Eyharts¹, P. Fournier¹, E. Cariou¹, Y. Lavie-Badie¹, A. Hennig², J. Roncalli¹, H. Rousseau², D. Carrie¹, M. Galinier¹, I. Berry³, O. Lairez¹. ¹Toulouse Rangueil University Hospital (CHU), Department of Cardiology, Toulouse, France; ²Toulouse Rangueil University Hospital (CHU), Department of Radiology, Toulouse, France; ³Toulouse Rangueil University Hospital (CHU), Department of Nuclear Medicine, Toulouse, France. On behalf of Department of Cardiology, University Hospital of Rangueil, Toulouse, France

Background: Right ventricular (RV) function is a powerful independent predictor of adverse heart failure outcomes. Several RV imaging parameters have been proposed to detect patients at risk new-onset acute heart failure. The objective of our study was to compare the predictive value of main RV systolic parameters for outcome.

Methods: One hundred patients underwent comprehensive cardiovascular imaging modalities including two-dimensional (2D) transthoracic echocardiography (TTE), cardiac magnetic resonance imaging (CMR) and tomographic equilibrium radionuclide ventriculography (ERV) for the assessment of RV function. The composite primary endpoint was explored in the retrospective cohort of 79 patients and defined by the occurrence of a major adverse cardiac event (MACE), i.e., death, heart transplantation, or new-onset acute heart failure. Intra- and inter-rater reliabilities for each RV systolic function parameter were explored in a prospective cohort of 21 patients.

Results: Mean NYHA class and left ventricular ejection fraction were 1.7±0.9 and 46±17%, respectively. During a mean follow-up of 13±9 months, 13 (20%) patients reached the composite primary endpoint. The areas under the receiver operator characteristic curves for the prediction of MACE were 0.922 (P<0.0001), 0.913 (P<0.0001), 0.906 (P<0.0001), 0.849 (P=0.002), 0.837 (P=0.003), 0.799 (P=0.009), 0.792 (P=0.011), 0.753 (P=0.026), 0.720 (P=0.053) and 0.608 (0.346) for integral systolic S' wave tricuspid annular velocity, RV free wall longitudinal strain, RV fractional area change, tricuspid annular plane systolic excursion, RV ejection fraction (RVEF) by CMR using the 4-chamber slices, peak systolic S' wave tricuspid annular velocity, RVEF by CMR using short-axis slices, RVEF by ERV, RV myocardial performance index, and RV myocardial acceleration during isovolumic contraction, respectively. All RV systolic function had intra- and inter-rater reliabilities above 0.9 except RV fractional area change, tricuspid annular plane systolic excursion, RVEF by CMR using short-axis slices and RVEF by ERV.



Conclusion: Among comprehensive cardiovascular imaging modalities allowing the assessment of RV function, echocardiographic parameters, and particularly integral systolic S' wave tricuspid annular velocity and RV free wall longitudinal strain, have the best prognostic performance and the best rater reliabilities.

P6213

Role of different phenotypic groups of thalassemia major patients studied by CMR

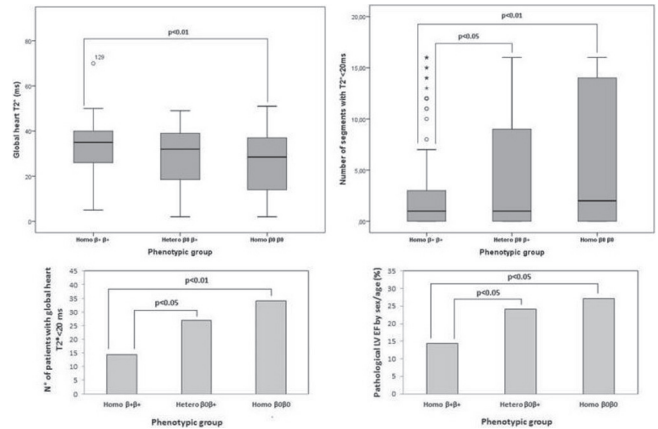
L. Pistoia¹, A. Meloni¹, S. Salvadori², S. Renne³, P. Giuliano⁴, P. Caccamo⁴, M. Rocca⁵, L. Rigoli⁶, M.P. Smacchia⁷, L. Maffei⁸, A. Spiga⁹, V. Spadola¹⁰, N. Romano¹¹, D. Maddaloni¹², A. Pepe¹. ¹Gabriele Monasterio Foundation, Pisa, Italy; ²Institute of Clinical Physiology, CNR, Pisa, Italy; ³P.O. "Giovanni Paolo II", Lamezia Terme, Italy; ⁴Ospedale Civico, Palermo, Italy; ⁵P.O. ASL 5, Crotona, Italy; ⁶U.O. Polyclinic G. Martino, Messina, Italy; ⁷Polyclinic Umberto I, Roma, Italy; ⁸Ospedale "Sant'Eugenio", Roma, Italy; ⁹P.O. Pediatrico Microcitemico "A.CAO", Cagliari, Italy; ¹⁰Azienda Ospedaliera Civile - O.M.P.A. Ragusa, Ragusa, Italy; ¹¹Santa Maria Nuova Hospital, Reggio Emilia, Italy; ¹²Ospedale "Engles Profili", Fabriano, Italy

Introduction: Beta thalassemia major (β-TM) displays a great deal of phenotypic heterogeneity, not fully investigated in terms of cause-effect.

Aim: We aimed to detect if different phenotypic groups could be related to different levels of cardiac impairments, evaluated by cardiovascular magnetic resonance (CMR).

Methods: We studied retrospectively 671 β-TM patients (age 30.1 years, 52.9% females) enrolled in the Myocardial Iron Overload in Thalassemia (MIOT) network. Myocardial iron overload was assessed by using a multislice multiecho T2* approach. Cine sequences were obtained to quantify biventricular functional parameters.

Results: Three groups of patients were identified: heterozygotes (N=279), homozygotes β+ (N=154), homozygotes β° (N=238). No significant differences for sex, age and haemato-chemical parameters were found among the groups. Transfusional needs resulted significantly lower in the homozygous β+ patients than the heterozygous (34.7 U vs 38.0 U, P<0.05) and the homozygous β° patients (34.7 U vs 41.6, P<0.0001). After adjusting for the transfusional requirements, the homozygous β+ group versus the homozygous β° group showed higher global heart T2* values (32.4 ms vs 26.2 ms, P<0.01); the number of segments with T2* <20ms and the number of patients with a global heart T2* value <20ms were significantly lower in the homozygous β+ group when compared to the other groups (see Figure). Moreover, after adjusting for cardiac iron, the homozygous β+ group showed a lower number of patients with a pathological left ventricular ejection fraction (LVEF) than the heterozygous and homozygous β° groups (27.2% vs 24.2% vs 14.3% P<0.05) (see Figure).



Conclusions: The homozygous β+ TM patients showed less myocardial iron overload and a concordant lower frequency of systolic heart dysfunction and cardiac remodelling. These data support the knowledge of the different phenotypic groups in the clinical and instrumental management of β-TM patients.

Funding Acknowledgements: The MIOT project receives "no-profit support" from industrial sponsorships (Chiesi Farmaceutici S.p.A. and ApoPharma Inc.).

P6214

The value of cardiac magnetic resonance imaging in the diagnosis of chagas heart disease in a non-endemic zone

E. Refoyo, E. Trigo, G. Guzman, S. Valbuena, S. Rosillo, J. Caro, E. Cuesta, M. Fernandez-Velilla, J.L. Lopez-Sendon. University Hospital La Paz, Madrid, Spain

Chagas disease (CD), is one of the most prevalent of all tropical infectious diseases imported in Spain, with underdiagnosed cases.

Main objectives: 1) To estimate the prevalence of anatomical and functional cardiac abnormalities of Chagas' disease of recent serological diagnosis, in a non endemic zone before starting treatment. 2) To assess the usefulness of cardiac magnetic resonance imaging to detect cardiac involvement in patients with Chagas disease compared to electrocardiogram and transthoracic echocardiography, either conventional or advanced.

Material and methods: An observational, prospective cohort study; carried out from 2015 to 2017.