

P3836

Myocardial work distribution in hypertensive patients with basal septal hypertrophy - a non-invasive assessment with left ventricular pressure-strain relations

F. Loncaric¹, M. Marciniak², J.F. Fernandes², L. Nunno³, M. Mimbreno³, L. Tirapu³, L. Sanchis³, A. Doltra³, D. Fabijanovic⁴, M. Cikes⁴, P. Lamata², B. Bijmens⁵, M. Sitges³

¹Institute of Biomedical Research August Pi Sunyer (IDIBAPS), Barcelona, Spain; ²Kings College London, Department of Biomedical Engineering, London, United Kingdom; ³Hospital Clinic de Barcelona, Barcelona, Spain; ⁴University Hospital Centre Zagreb, Department of Cardiovascular Diseases, Zagreb, Croatia; ⁵Institució Catalana de Recerca i Estudis Avançats (ICREA), Barcelona, Spain

Funding Acknowledgement: Spanish Ministry of Economy and Competitiveness (TIN2014-52923-R), Fundacio La Marató de TV3 (040310), H2020-MSCA-ITN-2016 (764738)

Background and aim: Localized basal septal hypertrophy (BSH) is a known marker of hypertension. However, the underlying functional significance of this morphologic finding is not clear. Non-invasive LV pressure estimates and speckle-tracking deformation curves can be used to quantify myocardial work (MW), which may offer insights into work distribution in increased afterload leading to better understanding of the early changes in hypertensive heart disease. The aim is to assess segmental strain and MW indices in hypertensive patients with and without BSH, as well as in healthy controls.

Methods: An echocardiogram was performed on a total of 149 patients with a diagnosis of long-standing hypertension and on 19 healthy age and sex-matched controls. The septum was measured at basal and mid-level in parasternal long-axis and four-chamber views. A two-part criterion - a positive visual assessment of an abrupt change in septal thickness seen in the 4C or PLAX view and a basal to mid-septal ratio ≥ 1.4 - was used to identify BSH. LV speckle-tracking was performed in 4C, 2C, and 3C views. Myocardial work index was calculated between mitral valve closing and opening. Average regional values of strain and MW indices were calculated by averaging the 4C, 3C, and 2C basal, mid, and apical segments.

Results: BSH was present in 19.2% (n=28) of the hypertensive cohort.

There were no differences in LV ejection fraction or global longitudinal strain between the subgroups. The basal inferoseptum and antero-septum were thicker in the hypertensive patients, significantly more so in the BSH subgroup, which was coupled with a proportional decrease in local deformation. Averaged regional deformation values showed a gradient increasing from base to apex in all subgroups, more pronounced in the BSH patients due to significantly impaired average basal deformation (controls vs. non-BSH vs. BSH: -18.33 ± 1.92 vs. -17.24 ± 2.14 vs. $-15.56 \pm 2.08\%$, $p < 0.001$). This deformation pattern was reflected in myocardial work distribution in hypertension, showing the basal region performing a lower percentage of global work, especially so in the BSH patients, while the apical region performed a significantly higher percentage, with a trend of further increase in the BSH subgroup (Figure 1).

Conclusion: Localised BSH, a structural finding in one-fifth of the hypertensive population, is related to functional impairment in regional systolic deformation and a pronounced redistribution of myocardial work during the cardiac cycle. An apex-to-base gradient in myocardial work signals an apical compensation of basal impairment in the setting of increased afterload. Clinical follow-up of patients is needed in order to assess the prognostic relevance of these findings.

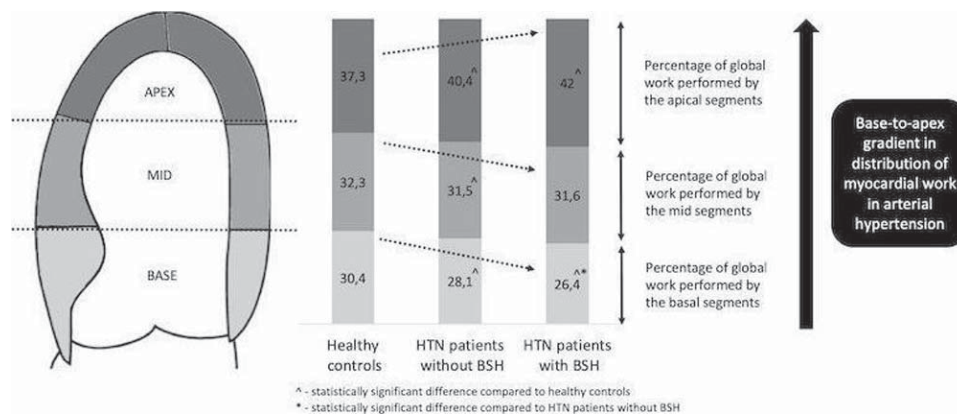


Figure 1