

The effects of chemotherapy on arterial inflammation assessed by 18 FDG PET-CT in patients with Lymphoma

E. Solomou¹, I. Koutagiar¹, N. Ioakimidis¹, D. Terentes-Printzios¹, A. Georgakopoulos², A. Pouli³, A. Sioni³, I. Karakitsios², P. Kafouris⁴, A. Gaitanis², N. Pianou², C. Aggeli¹, D. Tousoulis¹, C. Vlachopoulos¹, C. Anagnostopoulos²

¹Hippokraton General Hospital, 1st Cardiology Department, Athens Medical School, Athens, Greece; ²Academy of Athens Biomedical Research Foundation, Center for Experimental Surgery, Clinical and Translational Research, Biomedical Research Foundation, Athens, Greece; ³Agios Savvas General Oncology Hospital, Department of Hematology, Athens, Greece; ⁴Academy of Athens Biomedical Research Foundation, Center of Systems Biology, Athens, Greece

Funding Acknowledgement: Type of funding source: None

Introduction: Anti-cancer treatment can lead to increased cardiovascular morbidity among lymphoma survivors. This may be the result of direct effect of treatment on heart function, or indirect acceleration of atherosclerosis. 18F-fluorodeoxyglucose (FDG) uptake is a sensitive and robust marker for assessment of atherosclerotic inflammation.

Purpose: To investigate the effects of chemotherapy on arterial inflammation using FDG-PET CT in patients with lymphoma.

Methods: Fifty nine (mean age 58 ± 17 years) patients with Hodgkin (n=39) or non-Hodgkin lymphomas (n=20) underwent 18FDG PET-CT imaging at baseline, interim and after completion of chemotherapy as part of their routine protocol. Arterial inflammation was assessed by arterial target to background ratio (TBR) of the aortic wall along the entire aorta. The index vessel TBR (the vessel with the higher value at baseline) was used for assessment of arterial inflammation. Patients with Hodgkin Lymphomas (HL) underwent therapy with Doxorubicin, bleomycin, vinblastine and dacarbazine (ABVD). The interim of their treatment was set at 1 to 3 days prior to initiating the 3rd chemotherapy cycle. Patients with non Hodgkin Lymphomas (NHL) underwent therapy with cyclophosphamide, doxorubicin, vincristine, and prednisone+rituximab (R-CHOP). The interim of their treatment was set at 2 weeks post the 4th chemotherapy cycle. All patients were reassessed 6 weeks after chemotherapy completion.

Results: There were no differences in age and atherosclerotic risk factors (hypertension, diabetes, dyslipidemia and smoking), between the two groups (all $P > 0.05$). Similarly, there were no differences in mean (\pm SD) index vessel TBR between HL and NHL patients (2.4 ± 0.7 vs 2.7 ± 0.9 , respectively, $P = 0.65$). In the whole study population the index vessel TBR progressively decreased after the end of therapy (by 0.53 ± 0.11 , from baseline to 6 weeks following the end of therapies) ($F = 10.94$, $P < 0.001$, ANOVA). The index vessel TBR decreased in both HL and NHL patients at 6 weeks after therapy compared to baseline level (all $P < 0.01$, ANOVA, figure). The decrease at the interim scan was more pronounced in NHL compared to HL patients, however at 6 weeks after chemotherapy completion the index vessel TBR decreased further in patients with HL, while it increased slightly compared to interim levels in NHL patients (figure 1).

Conclusion: Arterial inflammation is reduced during and post-chemotherapy in patients with lymphoma. The index vessel TBR changes at the interim phase and 6 weeks after therapy completion indicate a different effect of specific treatment regimes in arterial inflammation between HL and NHL patients.

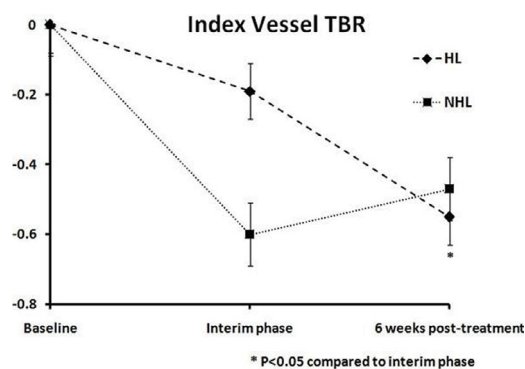


Figure 1