

CLINICAL CASE CORNER 1

P461

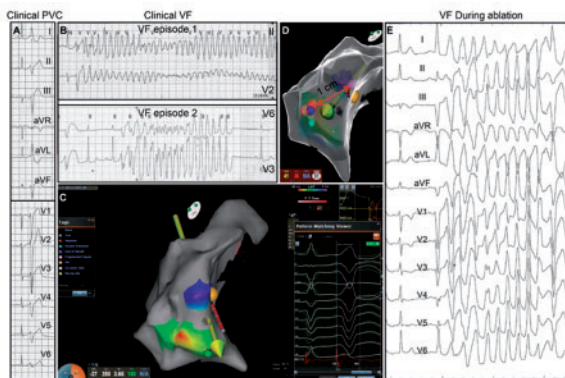
Catheter ablation of idiopathic ventricular fibrillation using remote magnetic navigation

S. Dang¹; PK. Jacobsen²; S. Pehrson²; X. Chen²

¹Wuxi people's hospital Affiliated to Nanjing Medical University, Department of cardiology, Wuxi, China People's Republic of; ²Rigshospitalet, Copenhagen, Denmark

Funding Acknowledgements: This work was supported by National Natural Science Foundation of China (81400297) and Jiangsu province Young Medical Talents (QNRC2016185).

Idiopathic ventricular fibrillation (VF) is characterized by spontaneous VF in the absence of any identifiable structural or functional cardiac disease. It has been reported that radiofrequency (RF) catheter ablation is effective in treating idiopathic VF initiated by premature ventricular complexes (PVCs) using manual ablation technique. However, it is unknown whether idiopathic VF can be successfully ablated using remote magnetic navigation (RMN). We report on a 41-year-old female, who was rescued from twice sudden cardiac deaths with documented episodes of VF. All VF episodes were initiated by monomorphic PVCs (Fig A-B). After systematic examination, no evidence of ischemic or structural cardiac disease was found and the left ventricular ejection fraction was also normal. Then ablation procedure was performed. An irrigated-tip ablation catheter was advanced into the right ventricle (RV) via the right femoral vein and along SL0 sheath. Using RMN, 3-dimensional electroanatomic mapping was subsequently performed with fast anatomical mapping (FAM). After that, a remap of activation was created by pattern matching of Carto 3-Version 6. The earliest intracardiac bipolar electrogram (47 ms) were found near distal Purkinje system of RV (Fig C). Delivery of RF energy to the foci had to be terminated as frequent VF/polymorphic VT occurred during RF applications (Fig E). RF energy was then applied to the proximal Purkinje fibers, 10 mm away from the triggers (Fig D). After incomplete bundle branch block was achieved, VF was no longer inducible during the subsequent PVC ablation. The patient is scheduled for an ICD implantation. To the best of our knowledge, this was the first case report of successful catheter ablation using RMN for VF triggered by PVCs. Although the best therapeutic option in patients with idiopathic VF is secondary prevention with an ICD, catheter ablation of PVCs triggering idiopathic VF is effective, which could reduce the electronic storm and shocks of ICD. In this case, the trigger PVCs was ablated first to decrease VF storm before ICD implantation. It has been reported that Purkinje network is related to VF occurrence. The RF catheter ablation induced lots of VF episodes in this patient, but after ablation proximal Purkinje fibers, VF episodes did not come again. In conclusion, catheter ablation using RMN for VF triggered by PVCs is an effective approach. Ablation of proximal Purkinje fibers first might be a safe strategy to prevent deadly VF during PVCs ablation.



Abstract P461 Figure.

P462

Unexpected serious collateral damage during pericardial puncture for endo-epicardial ventricular tachycardia ablation - a case series

M. Khan¹; AA. Hendriks¹; SC. Yap²; WR. Berger¹; GS. De Ruiter¹; T. Szili-Torok²

¹Hospital Onze Lieve Vrouwe Gasthuis, electrophysiology, Amsterdam, Netherlands;

²Erasmus Medical Center, electrophysiology, Rotterdam, Netherlands

Background: Endo-epicardial substrate homogenisation applied for ventricular tachycardia (VT) after myocardial infarction may be beneficial especially in the presence of

a transmural scar. Subxiphoidal pericardial puncture contains a risk of complications, there its route to the pericardium is in the proximity of surrounding extrapericardial structures with a significant patient to patient anatomic variance.

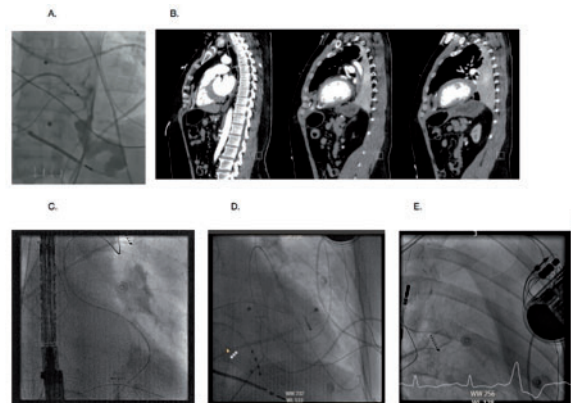
Purpose: We present two cases where pericardial subxiphoidal anterior puncture resulted in damage to the left internal mammary artery (LIMA).

Results: Both patients were referred for VT ablation and after giving consent included in the Epilogue study 'Ventricular tachycardia in ischemic cardiomyopathy; a combined endo-epicardial ablation as the first procedure versus a stepwise approach', in the endo-epicardial homogenisation arm.

Case 1. After an uncomplicated endo-epicardial VT procedure the pericardial sheath was replaced over the wire by a pericardial drain. Blood was noticed in the drain. A contrast injection demonstrated extravasation in the thorax and not the pericardium (Figure A). After ensuring the patient was stable an urgent CT scan was performed which confirmed a pericardial drain positioned at an anterior position of the heart, that brushed a side branch of the LIMA (Figure B). Within few hours after the procedure the drain production stopped and was removed without complications.

Case 2. To accomplish epicardial access a subxiphoid anterior puncture was performed under constant lateral fluoroscopy. During the first puncture the guide wire aligned the cardiac silhouette as demonstrated on fluoroscopy (Figure C). However the wire took off higher than the normal pericardial folds. Advancing the guidewire further confirmed its localisation in the pleural space (Figure D). During a second attempt the needle unintentionally slid over the pericardium resulting in a higher position than necessary. A third attempt resulted in successful epicardial access. During mapping increasing inotropic support was necessary to treat hypotension and impeded continuation of the ablation procedure. Repeated fluoroscopy revealed extensive pleural fluid on the left thorax (Figure E). Immediate drainage of the pleural space resulted in 2 litres of blood. On the OR emergency lateral thoracotomy was performed. A laceration of the LIMA near the 6th intercostal space, was repaired with a single suture.

Conclusion: A LIMA laceration, a complication of a pericardial puncture can stay temporarily concealed and may lead to a potential life threatening condition. An anterior approach is preferred to avoid right ventricular puncture, yet can potentially increase the incidence of LIMA lacerations. Caution is needed to avoid a higher than usual puncture when approaching the pericardium during needle advancement.



Abstract P462 Figure. case 1(A, B) Figure case 2(C,D,E)

P463

Risk assessment for primary prophylactic ICD implantation in hypertrophic cardiomyopathy using the risk calculator: discrepancy between theory and clinical practice?

T. Kleemann; M. Strauss; K. Kouraki; N. Werner; R. Zahn

Medizinische Klinik B, Klinikum Ludwigshafen, Ludwigshafen, Germany

Background: In hypertrophic cardiomyopathy (HCM) ESC guidelines recommend the use of a risk calculator to assess the risk of sudden cardiac death (SCD). Aim of the study was to compare the calculated risk of SCD at baseline in HCM patients with the incidence of malignant ventricular arrhythmias during follow-up.

Methods and results: A total of 27 of 2017 (1.3%) patients of the prospective single-centre ICD-registry Ludwigshafen had a HCM and underwent primary prophylactic ICD implantation. Patients were stratified according to the risk score into a low,