

## Wireless ECG embedded in a necklace enables reliable detection of atrial fibrillation

Santala OE.<sup>1</sup>; Lipponen JA.<sup>2</sup>; Jantti H.<sup>3</sup>; Rissanen TT.<sup>4</sup>; Halonen J.<sup>5</sup>; Hartikainen J.<sup>5</sup>; Kolk I.<sup>5</sup>; Pohjantahti-Maaroos H.<sup>5</sup>; Tarvainen MP.<sup>2</sup>; Valiaho E-S<sup>1</sup>; Martikainen T.<sup>6</sup>

<sup>1</sup>University of Eastern Finland, School of Medicine, Kuopio, Finland

<sup>2</sup>University of Eastern Finland, Department of Applied Physics, Kuopio, Finland

<sup>3</sup>Kuopio University Hospital, Center for Prehospital Emergency Care, Kuopio, Finland

<sup>4</sup>North Karelia Central Hospital, Heart Center, Joensuu, Finland

<sup>5</sup>Kuopio University Hospital, Heart Center, Kuopio, Finland

<sup>6</sup>Kuopio University Hospital, Department of Emergency Care, Kuopio, Finland

**Funding Acknowledgements:** Government grant, Heart2save Ltd cooperation.

Background/Introduction:

Atrial fibrillation (AF) is the most common arrhythmia and a fast-growing public health problem worldwide. Main and the most severe complication of AF is an embolic stroke. Approximately 25% of all strokes are caused by AF. AF is often symptomless and intermittent, making its detection and diagnosing challenging. Many AF patients have both symptomatic and asymptomatic periods of arrhythmia. In addition, during the early stage of the disease, AF is often paroxysmal making the diagnosis of AF a major clinical challenge.

**Purpose:** Wearable ECG devices could enable repetitive rhythm monitoring over a long term and thus improve the probability of AF detection. Wearable devices have the advantage of being easily available. However, they also need to be reliable and their design should appeal customers. Our aim was to study the suitability and reliability of novel measurement technique (necklace-ECG, Figure1) for the diagnosis of AF.

**Methods:** The study population consisted of 145 adult volunteers at Kuopio University Hospital emergency department (66 AF and 79 sinus rhythm (SR)), diagnosed from continuous 3-lead ECG recording. All study subjects performed a thirty-second self-performed ECG recording with a single-lead necklace-embedded ECG recorder (necklace-ECG) keeping the recorder between palms of their hands. The ECG recordings were analyzed with automatic AF detection algorithm. Two cardiologists interpreted independently in blinded fashion the necklace-ECG recordings and simultaneously registered 3-lead ECGs which served as golden standard for the final rhythm diagnosis.

**Results:** Necklace-ECG produced an interpretable ECG recording in 91.0%/86.2% patients (Doc1/Doc2, respectively). Additionally, 93.1% of ECG recordings were interpretable by the automatic analysis service (98.7% in SR patients and 86.4% of AF patients).

Based on the necklace ECG recording, cardiologists were able to diagnose AF with sensitivity of 98.2%/96.3% (Doc1/Doc2, respectively) and specificity of 100% (Doc1 and Doc2, respectively). The automatic arrhythmia algorithm diagnosed AF with sensitivity of 94.7% and specificity of 100%.

**Conclusions:** The necklace-ECG device produces ECG recording with sufficient quality for the detection of AF with good sensitivity and specificity as evaluated both by cardiologist and automated AF-detection algorithm. Thus, wearable necklace-ECG provides a new and easy method for screening, identifying and diagnosing AF.

Abstract Figure 1

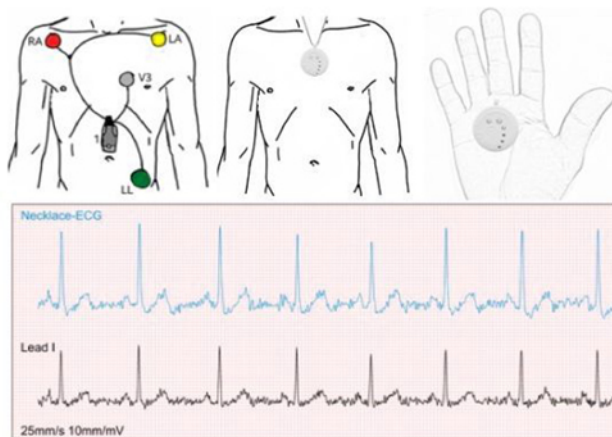


Figure 1. Necklace-ECG and Holter-ECG, devices and ECG-strips. In the measuring position, the necklace-ECG was placed between palms.