

The dynamics of rapid sperm transport through the female genital tract: evidence from vaginal sonography of uterine peristalsis and hysterosalpingoscintigraphy

G.Kunz¹, D.Beil², H.Deininger², L.Wildt³ and G.Leyendecker^{1,4}

¹Departments of Obstetrics and Gynecology and ²Radiology I, Städtische Kliniken Darmstadt, Academic Teaching Hospital of the University of Frankfurt, Darmstadt and ³Division of Gynecologic Endocrinology and Reproductive Medicine, Department of Obstetrics and Gynecology, University of Erlangen, Erlangen, Germany

⁴To whom correspondence should be addressed

Vaginal ultrasonography of uterine peristalsis during the follicular phase of the menstrual cycle demonstrates an increasing frequency and intensity of subendometrial and myometrial peristaltic waves as the follicular phase progresses. During this time the numbers of contraction waves with a fundo-cervical direction decrease considerably in favour of waves of contraction with a cervico-fundal direction. There is evidence that rapid sperm transport through the female genital tract is passive and is provided by these uterine contractions. Using hysterosalpingoscintigraphy, rapid sperm transport was studied by placing technetium-labelled albumin macrospheres of sperm size at the external os of the uterine cervix and following their path through the female genital tract. Ascension of the macrospheres occurred immediately following deposition at the external os of the cervix. As early as 1 min thereafter, the macrospheres had reached the intramural and isthmic part of the tube. Quantitatively, the extent of ascension increased with progression of the follicular phase. While only a few macrospheres entered the uterine cavity and even fewer the tubes during the early follicular phase, the proportion of macrospheres that entered the uterine cavity increased dramatically during the mid-follicular phase despite continuing limited entry into the tube. During the late follicular phase there was considerable ascension of the macrospheres which was directed preferentially into the tube ipsilateral to the dominant follicle. These data indicate that rapid transport of the spermatozoa through the female genital tract is under the endocrine control of the dominant follicle, ensuring the preferential accumulation of spermatozoa at the site of fertilization.

Key words: female genital tract/hysterosalpingoscintigraphy/sperm transport/uterine peristalsis/vaginal sonography

Introduction

Rapid sperm transport from the vagina to the Fallopian tubes within minutes has been described in many species including

man (Hartman, 1962; Mortimer, 1983; Hunter, 1987; Drobnis and Overstreet, 1992; Harper, 1994). Since the known velocity of sperm movement does not allow for the coverage, within a few minutes, of such a long distance through the female genital tract, rapid sperm transport is considered a passive phenomenon and has been ascribed to uterine contractions (Birnholz, 1984; Oike *et al.*, 1988; Abramovicz and Archer, 1990; De Vries *et al.*, 1990; Lyons *et al.*, 1991). In this respect, the uterus may be viewed as a peristaltic pump. Using vaginal sonography, waves of uterine contractions have been demonstrated with a highest frequency during midcycle (Lyons *et al.*, 1991). These waves were directed mainly from the cervical canal to the fundal part of the uterine cavity (cervico-fundal peristalsis), while during menstruation and at a lower frequency they were directed from the uterine cavity towards the cervix (fundo-cervical peristalsis). This indicates a hormonal control over uterine peristalsis and thus rapid sperm transport.

Attempts have been made, i.e. by using inert particles such as charcoal, to obtain insights into the mechanisms of rapid sperm ascension within the genital tract. However, the evidence derived from these and similar studies is limited because of possible artefacts introduced by invasive techniques such as anaesthesia and laparotomy (Egli and Newton, 1961; Settlage *et al.*, 1973).

These methodological drawbacks are not encountered in hysterosalpingoscintigraphy (HSSG; Iturralde and Venter, 1981; Becker *et al.*, 1988; Steck *et al.*, 1991). This method allows the study of utero-tubal transport *in vivo* without stress and injury. Technetium-labelled albumin macrospheres are placed into the posterior vaginal fornix and the ascension of these particles within the female genital tract can be documented by serial scintigrams.

In this study, serial HSSG was performed during the follicular phase of the menstrual cycle to obtain insights into the mechanisms that govern rapid sperm ascension in the female genital tract. Because uterine peristalsis appears to be essential for rapid sperm transport, uterine contractions were documented by vaginal sonography during the follicular phase of the cycle in a parallel study.

Materials and methods

Patients

A total of 64 women aged 22–46 years (mean 30) entered this study after giving informed consent. All had regular menstrual cycles, a history of fertility or were suffering from andrological sterility. In the group of women ($n = 36$) undergoing vaginal sonography for uterine peristalsis (VSUP), none had endometriosis, eight had proven fertility and 28 suffered from secondary tubal or andrological sterility.

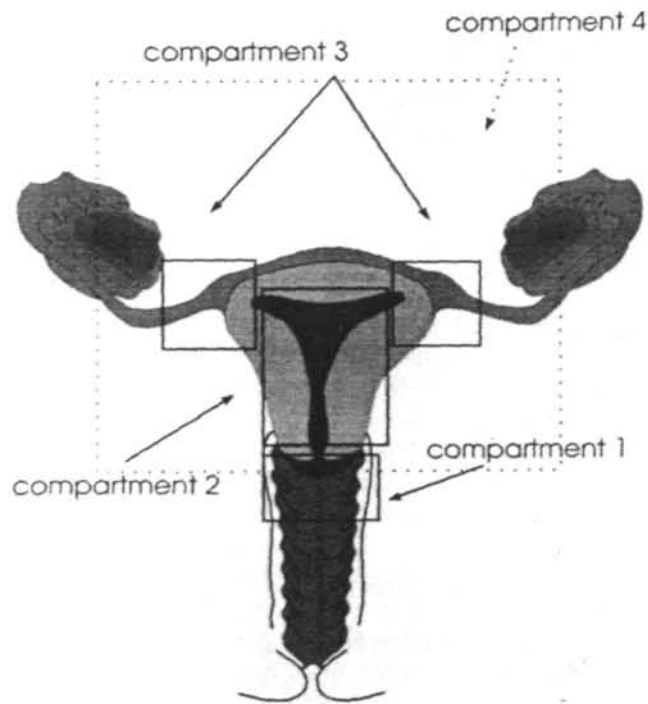


Figure 1. A schematic representation of the female genital tract showing the four compartments chosen, with compartment 1 representing the upper vagina, compartment 2 the uterine cavity, compartment 3 the isthmic part of the tubes and compartment 4 the peritoneal cavity.

Tubal sterility and endometriosis were excluded by laparoscopy in all women undergoing HSSG ($n = 28$).

Vaginal sonography of uterine peristalsis

VSUP was performed with a 7.5 MHz probe (Sonoline SI-45; Siemens, Erlangen, Germany). The probe was placed in such a position to yield a sagittal section of the whole uterus. It was kept in a fixed position for a period of 5 min. The whole scan was videotaped for a quantitative assessment of uterine peristalsis. To obtain a precise estimation of the frequency of the contraction waves, the tape was replayed at five times the regular speed. This also facilitated the determination of the wave direction (cervico-fundal versus fundocervical peristalsis).

Hysterosalpingoscintigraphy

HSSG was performed according to the method described by Iturralde and Venter (1981) and Becker *et al.* (1988). Albumin microspheres (Solco MAA; Nuclear GmbH, Grenzach-Wyhlen, Germany) with a 95% mean diameter of 5–40 μm were labelled with technetium and suspended in normal saline 5 min prior to application; 0.5 ml of the suspension containing $\sim 2 \times 10^6$ labelled albumin particles with a radioactivity of ~ 25 MBq with $< 0.1\%$ of free technetium were placed by a syringe into the posterior vaginal fornix with the patient in the supine position; the patient's position was not changed during the whole procedure.

Serial anterior-posterior scintigrams were performed using a gamma camera (Orbiter; Siemens) over a period of 32 min, starting 1 min after application of the suspension. During the first 18 min the radioactivity was measured every minute, and thereafter every 2 min.

For the assessment of the ascension of the labelled microspheres, the genital tract was subdivided into four compartments. The upper vagina (the place of application) was compartment 1, while the uterine cavity and the Fallopian tubes were compartments 2 and 3

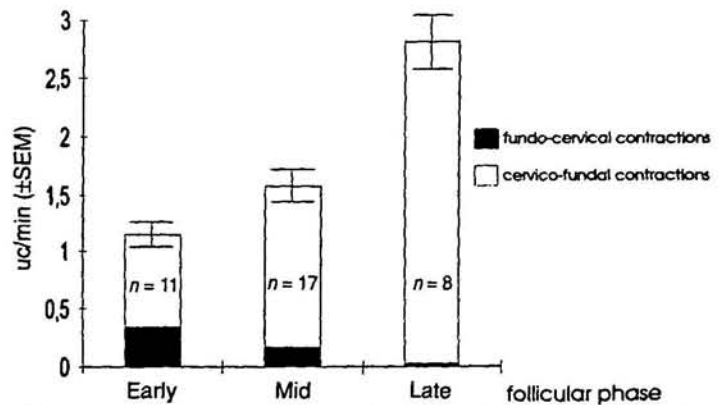


Figure 2. Histogram showing the frequency of the subendometrial uterine peristaltic waves during the early, mid- and late follicular phases of the cycle, as determined by vaginal ultrasonography [uterine contractions (UC)/min \pm SEM]. The relative distribution of fundocervical contractions versus cervico-fundal contractions during these different phases of the cycle is also indicated.

respectively. In all patients the localization of the dominant follicle was documented, when possible. Thus, in the assessment of the ascension into compartment 3, transport into the right or left tube, and into the tube ipsi- or contralateral to the dominant follicle, was recorded. The peritoneal cavity was designated compartment 4 (Figure 1).

The camera used provided colour prints using a spectrum of colours ranging from black through yellow and red to blue, roughly showing the relative distribution of radioactivity (black indicated the highest and blue the lowest intensity measured). For a quantitative assessment of the ascension of the labelled albumin microspheres within the female genital tract, the scans of 1, 16 and 32 min following application of the particles were selected. Regions of interest corresponding to the chosen compartments were determined independently by a radiologist and gynaecologist. The counts were measured within each compartment and expressed as a percentage of the total.

HSSG and VSUP were performed during the early, mid- and late follicular phases of the cycle. These phases were related to the ovarian functional status by determining the diameter of the dominant follicle by vaginal sonography and measurement of the serum oestradiol concentration using a commercially available radioimmunoassay kit (Oestradiol MAIA; Serono Diagnostics GmbH, Freiburg, Germany). Following VSUP and HSSG, the cycles were further monitored by ultrasound and/or progesterone concentration measurements. Thus, it was documented that the studies were performed in the proliferative phases of normal ovulatory cycles. Patients were advised not to conceive during an HSSG cycle. No conception occurred in such a cycle.

Statistical analysis

Statistical analyses were performed using Student's *t*-test.

Results

VSUP

Figure 2 summarizes the findings obtained following VSUP in 36 women. The mean values of the frequency of uterine contractions increased significantly ($P < 0.05$), from 1.2 contractions/min in the early follicular phase, to 1.6 contractions/min in the mid-follicular phase and to 2.8 contractions/min in the late follicular phase of the cycle. Over the same time period, the proportion of fundocervical contraction waves

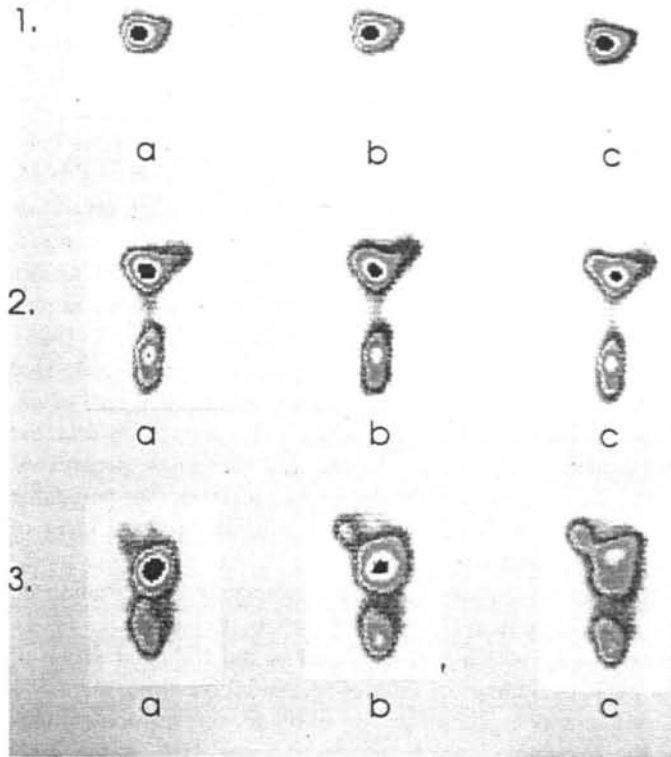


Figure 3. Representative colour prints obtained by hysterosalpingoscintigraphy in three different patients (panel 1, early follicular phase; panel 2, mid-follicular phase; and panel 3, late follicular phase). In each patient, scintigrams were performed at 1–2 min intervals. In this figure, only the scintigrams obtained 1 (a), 16 (b) and 32 min (c) after vaginal application of the labelled microspheres are shown. In the patient at the mid-follicular phase (panel 2), the dominant follicle was in the left ovary, while in the patient at the late follicular phase (panel 3), the dominant follicle was situated in the right ovary.

decreased significantly ($P < 0.05$) from 31 to 12 to 1% respectively.

HSSG

Figure 3 shows representative scintigrams obtained during the early (1), mid- (2) and late (3) follicular phases of the menstrual cycle at 1 (a), 16 (b) and 32 (c) min after application of the microsphere suspension. They show the ascension of the labelled particles from the vaginal depot (compartment 1), to the uterine cavity (compartment 2) into the Fallopian tubes (compartment 3). The relative scintigraphic intensity, indicated by the different colours (increasing radioactivity from blue to red to yellow to black) on each print, demonstrated the site of maximum radioactivity and thus the location of the highest number of particles and the level (compartment) up to which some of the particles had ascended.

In the early follicular phase most of the radioactivity remained at the site of application. Some radioactivity was demonstrated in the uterine cavity (compartment 2) and only faint signs were seen at the site of the tubes (compartment 3).




Figure 4. Enlarged colour print of the scintigram shown in Figure 3.3b. The regions of interest are outlined in black, i.e. the upper vagina, the uterine cavity and the Fallopian tubes. The relative distribution of total counts can easily be seen.

In the mid-follicular phase, considerable radioactivity was observed in compartment 2, while the radioactivity in compartment 3 increased slightly. In the late follicular phase, considerable radioactivity was found in compartment 3, with a decrease in radioactivity in compartment 1.

Figure 4 shows an enlargement of the scintigram in Figure 3.3b. Evaluation was made on the basis of total counts in the regions of interest (compartments).

A summary of these findings in 28 women is shown in Figure 5, with the counts being expressed as a percentage of the total in the respective regions of interest. For the early, mid- and late follicular phases of the cycle, different distribution patterns of radioactivity in the vaginal tract were observed. During the early follicular phase of the cycle, most of the radioactivity remained at the site of application. However, there was already a remarkable and rapid ascension into the uterine cavity. Little radioactivity ascended into the tubes, which could not yet be related to a dominant follicle. A strong ascension into the uterus occurred during the mid-follicular phase, with a marked ascension into one of the tubes, showing that already during this phase of the cycle a quantitative orientation of the particles had taken place towards the tube ipsilateral to the dominant follicle. This tendency was expressed

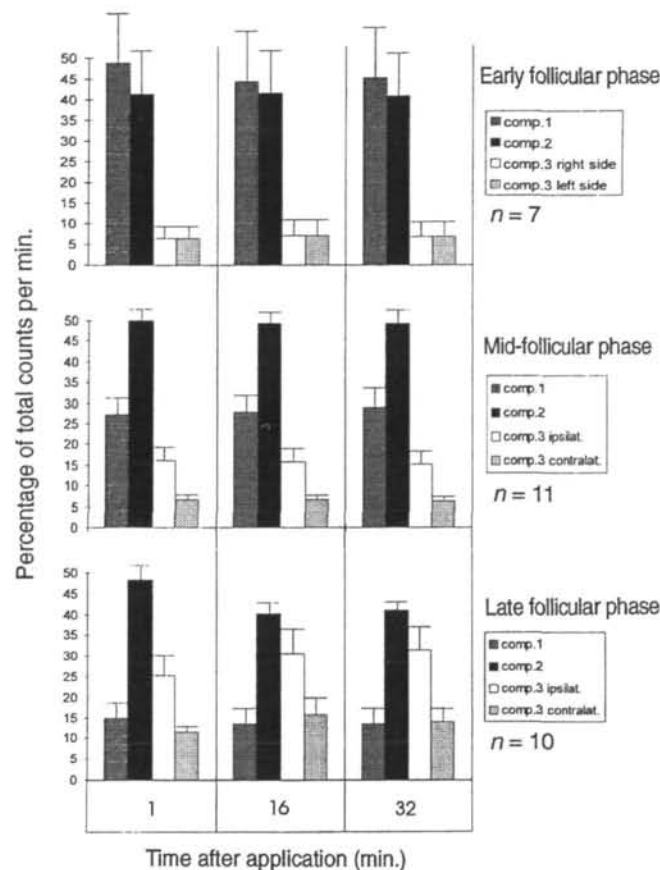


Figure 5. Distribution of the percentage of total counts, representing the labelled albumin macrospheres, within the female genital tract at 1, 16 and 32 min after vaginal application during the early, mid- and late follicular phases. During the early follicular phase of the cycle the counts were distributed equally between the right and left Fallopian tubes, while in the mid- and late follicular phases of the cycle the percentage of counts in the tube ipsilateral to the dominant follicle was higher than that in the tube contralateral to the dominant follicle.

even more strongly during the late follicular phase. In general, there was an increasing ascension of the macrospheres within the female genital tract in parallel with the progression of the follicular phase. While the distribution pattern of radioactivity did not change significantly from 1 to 32 min after application of the macrospheres during the early and mid-follicular phases, there was, during the late follicular phase, a continuing ascension of the radioactivity into the tubes between 1 and 16 min after application of the macrospheres. This ascension was directed mainly into the tube ipsilateral to the dominant follicle. As judged from the colour prints shown in Figure 3, no radioactivity was ever found in compartment 4.

The decrease of the vaginal depot of radioactivity from the early to the late follicular phase 1, 16 and 32 min after application of the macrospheres was statistically significant ($P < 0.02$). The amount of radioactivity in compartment 3 (tube of the dominant follicle) increased significantly from the early to the late follicular phase at 1, 16 and 32 min ($P < 0.05$) and from the mid- to the late follicular phase at 16 and 32 min ($P < 0.05$) after application of the macrospheres. In the mid- and late follicular phases of the cycle, the amount of radioactivity in the ipsilateral and contralateral tubes to the

dominant follicle differed significantly ($P < 0.05$) at 1, 16 and 32 min after application of the labelled particles.

Table I summarizes the results of the serum oestradiol and follicular size measurements obtained during the study.

Discussion

Rhythmic contractions of the non-pregnant uterus have been demonstrated in many species including man (Hendricks, 1966; Cibils, 1967; Martinez-Gaudio *et al.*, 1973). High-resolution sonography has made it possible to demonstrate these contractions without invasive techniques. These contractions mostly involve the subendometrial layer of the myometrium and may only be detected by endometrial movements (Birnholtz, 1984). Following their first description, they have been characterized further (Oike *et al.*, 1988; De Vries *et al.*, 1990; Lyons *et al.*, 1991; Fukuda and Fukuda, 1994). The contractions increase in frequency and intensity as the follicular phase progresses, with an inverse pattern during the luteal phase. The peristaltic waves of the endometrium and the subendometrial layer of the myometrium are directed from the cervical canal to the fundal part of the uterus, while only during menstruation do they exhibit a fundo-cervical direction (Lyons *et al.*, 1991). In our study, which was restricted to the follicular phase of the cycle excluding the time of menstrual bleeding, there was a considerably higher proportion of fundo-cervical contractions at the beginning, which decreased from 31% in the early follicular phase to 12% in the mid-follicular phase and ~1% in the late follicular phase (Figure 2). Thus, almost all peristaltic waves of the uterus during the late follicular phase had a cervico-fundal direction. They also appeared to be more intense at this stage than during the other parts of the follicular phase which might be related to the thickness of the endometrium, rendering more pronounced movements. However, in comparison with the early follicular phase, a thicker proportion of the myometrium appeared to be involved in the contractions.

The frequency of the contractions did not decrease during the 5 min period of ultrasound examination. Furthermore, the contractions were also observed with transvesical scanning (Birnholtz, 1984). Thus, it is very unlikely that the uterine peristalsis was induced by the vaginal ultrasound examination. In contrast, it can be assumed that uterine peristalsis during the menstrual cycle is a continuous phenomenon with a varying frequency, intensity and direction of the contraction waves, depending on the phase of the cycle, and does not require a specific stimulus for initiation. However, these studies do not exclude a coital enhancement of the uterine contractions.

Because the frequency, intensity and direction of uterine peristalsis depend on the phase of the cycle, an endocrine control of this phenomenon by the ovary may be assumed. In this respect, oxytocin and prostaglandins may function as mediators (Eliasson and Posse, 1960; Hein *et al.*, 1973; Karim and Hillier, 1973; Fuchs *et al.*, 1985; Lefebvre *et al.*, 1994a,b).

The demonstration of spermatozoa in the Fallopian tubes within minutes of copulation or insemination indicates that rapid sperm ascension is not active but is rather provided by uterine contractions (Harper, 1994). It is reasonable to assume

Table I. Diameter of the dominant follicle and the serum oestradiol concentrations during the early, mid- and late follicular phases in the patients examined by vaginal sonography for uterine peristalsis (VSUP) and hysterosalpingoscintigraphy (HSSG) (values are means \pm SD)

Phase of cycle	VSUP			HSSG		
	<i>n</i>	Follicular diameter (mm)	Oestradiol concentration in serum (pmol/l)	<i>n</i>	Follicular diameter (mm)	Oestradiol concentration in serum (pmol/l)
Early follicular	11	<11	102.0 \pm 47.0	7	<11	117.0 \pm 39.3
Mid-follicular	17	13.9 \pm 1.6	231.0 \pm 114.2	11	14.4 \pm 1.7	235.0 \pm 114.5
Late follicular	8	18.3 \pm 1.4	642.0 \pm 391.0	10	19.3 \pm 3.1	764.0 \pm 361.2

that the cervico-fundal uterine peristalsis, which increases in frequency and intensity towards midcycle, provides the forces required for this rapid sperm transport.

The HSSG allows, by serial images, the documentation of the ascension of labelled inert particles through the genital tract *in vivo*. The albumin microspheres used in our study resemble spermatozoa in their size (3 \times 30 μ m). The size of 95% of the macroaggregates was between 5 and 40 μ m. Thus, the demonstration of their ascension through the genital tract may be considered to be a representation of passive sperm transport.

According to these data (Figure 5), the following concept of the dynamics of rapid sperm ascension within the female genital tract may be proposed. Rapid sperm ascension occurs immediately following deposition of the ejaculate at the external os of the cervix. As soon as 1 min thereafter, spermatozoa reach the intramural and isthmic parts of the tube. Quantitatively, however, the extent of ascension increases with the progression of the follicular phase. While only a few spermatozoa enter the uterine cavity and even fewer enter the tubes during the early follicular phase, the proportion of spermatozoa which enter the uterine cavity increases dramatically during the mid-follicular phase with still only a limited entry into the tubes at this stage. During the late follicular phase there is considerable ascension of the spermatozoa into the tubes.

The most striking finding in our study is the preferential direction of rapid sperm transport into the tube ipsilateral to the dominant follicle. This corresponds to recent findings during surgery that the number of spermatozoa around ovulation was higher in the tube ipsilateral to the dominant follicle than in the tube on the other side (Williams *et al.*, 1993). Our data show that this directed passive ascension of spermatozoa (microspheres) into the dominant tube has already begun during the mid-follicular phase as soon as a dominant follicle can be demonstrated (Figures 3 and 5).

Furthermore, our studies with inert particles suggest that this directed ascension is not a property of the spermatozoa and is thus not provided by mechanisms such as chemotaxis, but rather constitutes a specific utero-tubal function controlled by the dominant follicle in that the uterine myometrium with its specific architecture (Goertler, 1930) is activated and contracts in a manner providing this directed transport.

In these normal females with proven tubal patency, there were no indications that the albumin microspheres entered the peritoneal cavity to a large degree. In contrast, they were rather retained in the isthmic part of the tube. Therefore,

HSSG cannot be considered to be a study method for tubal patency, as suggested by Steck *et al.* (1991).

The arrest of passive sperm transport in the isthmic part of the tube appears to be of significance in the physiological process of reproduction (Harper, 1994). Electron microscope studies have demonstrated significant morphological, and by inference functional, changes in the tubal epithelium during the menstrual cycle (Jansen, 1980; Amso *et al.*, 1994a,b; Crow *et al.*, 1994). Jansen (1980) first described the pre-ovulatory appearance of secretory cells in the isthmic part of the tube as being responsible for the development of an isthmic mucus plug during this phase of the cycle. This plug is probably responsible for the isthmo-tubal arrest of passive sperm ascension and may serve, following the cervical mucus and crypts, as a secondary tubal sperm reservoir (Harper, 1994).

It is of interest that the scant cervical mucus with little spinnbarkeit of the early follicular phase does not prevent a prompt passive transport of the particles within the female genital tract. The increasing secretion of less viscous mucus during the mid- and late follicular phases might facilitate the transport. However, the power of the uterine contractions appears to be the main determinant in this respect because in patients with endometriosis and uterine hyperperistalsis, our own work has shown that the particles are already ascending rapidly into the tubes during the early follicular phase (data not shown).

Over the period of 32 min, there was very little change in the distribution pattern of the radioactivity in the different compartments within the early and mid-follicular phases, and only a small one in the late follicular phase (Figure 5). This is at first sight surprising in view of the continuous peristaltic activity of the uterus at this time. We assume that only the portion of the suspension that has immediate and direct contact with the cervical os, and during the later parts of the follicular phase with the cervical mucus, is aspirated and transported by the uterine peristaltic pump. Because the patient does not move during the whole procedure, no further material applied achieves contact with this zone. Obviously, a few peristaltic waves within 1 min are sufficient to transport the particles that are in contact with this zone into the uterine cavity and into the isthmic part of the tube.

In conclusion, on the basis of the data obtained here and available from the literature, we postulate that rapid as well as sustained sperm transport is controlled by the same mechanism. Uterine contractions aspirate spermatozoa into the cervical mucus and the uterine cavity, and provide further transport into the isthmic part of the tubes. In the mid- and late follicular

phases of the cycle this transport is directed preferentially into the tube ipsilateral to the dominant follicle. This indicates that the mechanism of rapid and passive sperm transport is under the endocrine control of the dominant follicle. Some spermatozoa, probably the most motile ones, follow, by their own movement, the filamentous structures of the cervical mucus and enter the cervical crypts as a primary reservoir. This results in a partial sequestration of the spermatozoa, increasing the proportion of less motile and immotile spermatozoa that reach the tubes rapidly. This observation has probably led to the notion that rapid sperm ascension might not be essential for fertilization (Mortimer, 1983; Hunter, 1987). With progression of the follicular phase, increasing release of the spermatozoa from the primary reservoir occurs as they are flushed out of the crypts by the cervical secretion which becomes more profuse. On entering the mainstream of cervical secretion, they are caught by the uterine peristaltic system and rapidly transported in an aliquot of mucus (Fukuda and Fukuda, 1994), which protects them from leukocyte degradation within the uterine cavity (Harper, 1994), to the tube with its isthmus mucus as the secondary reservoir. Maximum cervical secretion around ovulation largely prevents motile spermatozoa from entering the cervical crypts, and thus, in combination with maximally increased uterine peristalsis, ensures that no or only minor sequestration of the spermatozoa occurs so that motile spermatozoa are transported directly to the tube ipsilateral to the dominant follicle where they are available for fertilization.

References

- Abramovicz, J.S. and Archer, D.F. (1990) Uterine endometrial peristalsis — a transvaginal ultrasound study. *Fertil. Steril.*, **54**, 451–454.
- Amso, N.N., Crow, J. and Shaw, R.W. (1994a) Comparative immunohistochemical study of oestrogen and progesterone receptors in the Fallopian tube and uterus at different stages of the menstrual cycle and the menopause. *Hum. Reprod.*, **9**, 1027–1037.
- Amso, N.N., Crow, J., Lewin, J. and Shaw, R.W. (1994b) A comparative morphological and ultrastructural study of endometrial gland and Fallopian tube epithelia at different stages of the menstrual cycle and the menopause. *Hum. Reprod.*, **9**, 2234–2241.
- Becker, W., Steck, T., Alber, P. and Borne, W. (1988) Hystero-salpingo-scintigraphy: a simple and accurate method of evaluating Fallopian tube patency. *Nuklearmedizin*, **27**, 252–257.
- Bimholz, J. (1984) Ultrasonic visualization of endometrial movements. *Fertil. Steril.*, **41**, 157–158.
- Cibils, L.A. (1967) Contractility of the nonpregnant human uterus. *Obstet. Gynecol.*, **30**, 441–461.
- Crow, J., Amso, N.N., Lewin, J. and Shaw, R.W. (1994) Morphology and ultrastructure of Fallopian tube epithelium at different stages of the menstrual cycle and the menopause. *Hum. Reprod.*, **9**, 2224–2233.
- De Vries, K., Lyons, E.A., Ballard, G., Levi, C.S. and Lindsay, D.J. (1990) Contractions of the inner third of the myometrium. *Am. J. Obstet. Gynecol.*, **162**, 679–682.
- Drobnis, E.Z. and Overstreet, J.W. (1992) Natural history of mammalian spermatozoa in the female reproductive tract. *Oxford Rev. Reprod. Biol.*, **14**, 1–46.
- Egii, G.E. and Newton, M. (1961) The transport of carbon particles in the human female reproductive tract. *Fertil. Steril.*, **12**, 151–155.
- Eliasson, R. and Posse, N. (1960) The effect of prostaglandin on the nonpregnant uterus *in vivo*. *Acta Obstet. Gynecol. Scand.*, **39**, 112.
- Fuchs, A.-R., Fuchs, F. and Soloff, M.S. (1985) Oxytocin receptors in nonpregnant human uterus. *J. Clin. Endocrinol. Metab.*, **60**, 37–41.
- Fukuda, M. and Fukuda, K. (1994) Uterine endometrial cavity movement and cervical mucus. *Hum. Reprod.*, **9**, 1013–1016.
- Goertler, K. (1930) Die Architektur der Muskelwand des menschlichen Uterus und ihre funktionelle Bedeutung. *Gegenbaurs Morpholog. Jahrb.*, **65**, 45–52.
- Harper, M.J.K. (1994) Gamete and zygote transport. In Knobil, E. and Neill, J.D. (eds), *The Physiology of Reproduction*. Raven Press, New York, NY, USA, pp. 123–187.
- Hartman, C.G. (1962) *Science and the Safe Period. A Compendium of Human Reproduction*. Williams and Wilkins, Baltimore, MD, USA.
- Hein, P.R., Eskes, T.K.A.B., Stolte, L.A.M., Braaksma, J.F. et al. (1973) The influence of steroids on uterine motility in the nonpregnant human uterus. In Josimovich, J.B. (ed.), *Uterine Contractions — Side Effect of Steroidal Contraceptives*. Wiley and Sons, New York, NY, USA, pp. 107–140.
- Hendricks, C.H. (1966) Inherent motility patterns and response characteristics in the nonpregnant uterus. *Am. J. Obstet. Gynecol.*, **96**, 824–841.
- Hunter, R.H.F. (1987) Human fertilization *in vivo* with special reference to progression, storage and release of competent spermatozoa. *Hum. Reprod.*, **2**, 329–332.
- Iturralde, M. and Venter, P.P. (1981) Hysterosalpingo-radiouclide scintigraphy. *Semin. Nucl. Med.*, **11**, 301–314.
- Jansen, R.P.S. (1980) Cyclic changes in the human Fallopian tube isthmus and their functional importance. *Am. J. Obstet. Gynecol.*, **136**, 292–308.
- Karim, S.M.M. and Hillier, K. (1973) The role of prostaglandins in myometrial contraction. In Josimovich, J.B. (ed.), *Uterine Contraction — Side Effects of Steroidal Contraceptives*. Wiley and Sons, New York, NY, USA, pp. 141–169.
- Lefebvre, D.L., Farookhi, R., Larcher, A., Neculcea, J. and Zingg, H.H. (1994a) Uterine oxytocin gene expression. I. Induction during pseudopregnancy and the estrous cycle. *Endocrinology*, **134**, 2556–2561.
- Lefebvre, D.L., Farookhi, R., Giaid, A., Neculcea, J. and Zingg, H.H. (1994b) Uterine oxytocin gene expression. II. Induction by exogenous steroid administration. *Endocrinology*, **134**, 2562–2566.
- Lyons, E.A., Taylor, P.J., Zheng, X.H., Ballard, G., Levi, C.S. and Kredentser, J.V. (1991) Characterization of subendometrial myometrial contractions throughout the menstrual cycle in normal fertile women. *Fertil. Steril.*, **55**, 771–775.
- Martinez-Gaudio, M., Yoshida, T. and Bentsson, L.P. (1973) Propagated and nonpropagated myometrial contractions in normal menstrual cycles. *Am. J. Obstet. Gynecol.*, **115**, 107–111.
- Mortimer, D. (1983) Sperm transport in the human female reproductive tract. *Oxford Rev. Reprod. Biol.*, **5**, 40.
- Oike, K., Obata, S., Tagaki, K., Matsuo, K., Ishihara, K. and Kikuchi, S. (1988) Observation of endometrial movement with transvaginal sonography. *J. Ultrasound Med.*, **7**, 99.
- Settlage, D.S.F., Motoshima, M. and Tredway, D.R. (1973) Sperm transport from the external cervical os to the Fallopian tubes in women. A time and quantitation study. *Fertil. Steril.*, **24**, 655–661.
- Steck, T., Wurfel, W., Becker, W. and Albert, P.J. (1991) Serial scintigraphic imaging for visualization of passive transport processes in the human Fallopian tube. *Hum. Reprod.*, **6**, 1186–1191.
- Williams, M., Hill, C.J., Scudamore, I., Dunphy, B., Cooke, I.D. and Barratt, C.L.R. (1993) Sperm numbers and distribution within the human Fallopian tube around ovulation. *Hum. Reprod.*, **8**, 2019–2026.

Received on August 16, 1995; accepted on November 11, 1995