

Endometrial micropolyps at fluid hysteroscopy suggest the existence of chronic endometritis

Ettore Cicinelli^{1,3}, Leonardo Resta², Roberto Nicoletti¹, Valeria Zappimbulso¹, Massimo Tartagni¹ and Nicola Saliani¹

¹1st Department of Obstetrics and Gynaecology and ²Institute of Pathology, Faculty of Medicine, University of Bari, Bari, Italy

³To whom correspondence should be addressed at: Department of Obstetrics and Gynaecology, University of Bari, Policlinico, Piazza Giulio Cesare, 70124 Bari, Italy. E-mail: Cicinelli@gynecology1.uniba.it

Presented at the 13th annual ESGE meeting, Cagliari, Italy, October 2004

BACKGROUND: At fluid hysteroscopy the presence of endometrial micropolyps (less than 1 mm of size) is a frequent finding. Although their origin is still unknown, in our experience they are associated with stromal edema, endometrial thickening and periglandular hyperhaemia that suggest the existence of chronic endometritis. This study will aim to describe these lesions and evaluate their inflammatory significance by comparing hysteroscopic and histological findings. **METHODS:** 820 women underwent hysteroscopy and endometrial biopsy. Sensitivity, specificity, positive and negative predictive values and accuracy of the micropolyps presence for the diagnosis of chronic endometritis were calculated. **RESULTS:** Micropolyps were found in 96 cases (11.7% of all hysteroscopies); in 90 (93.7%) of these cases histology confirmed the presence of chronic endometritis. In women without micropolyps, chronic endometritis was significantly less frequent (78 cases, 10.8%) ($P < 0.000001$). The likelihood of chronic endometritis for women with micropolyps was very high (odds ratio 124.2, confidence interval 50.3–205.4). The sensitivity, specificity, positive and negative predictive values were 54%, 99%, 94% and 89%, respectively; the diagnostic accuracy was 90%. **CONCLUSIONS:** The presence of endometrial micropolyps at fluid hysteroscopy is significantly associated with endometrial inflammation and can be considered a reliable diagnostic sign for this pathology.

Key words: chronic endometritis/endometrial micropolyps/hysteroscopy/saline distention

Introduction

The employment of saline as distention medium of the uterine cavity at hysteroscopy is today probably more common than standard CO₂ (Indman, 2000; Cicinelli *et al.*, 2003). Compared to gas, the employment of saline provides a smoother distention of the uterine cavity, continuous washing of the uterine cavity and floating of endometrial ingrowths. This implies that by using saline the endoscopic appearance of the endometrial surface may differ from that with CO₂. Thus, the diagnostic images described at standard CO₂ hysteroscopy may not correspond to that obtained at fluid hysteroscopy; in addition, some features never described at CO₂ hysteroscopy may surface during fluid hysteroscopy.

In a large series of diagnostic hysteroscopies using saline distention (Cicinelli *et al.*, 2003) we have frequently observed an atypical aspect of endometrial surface characterized by the presence of very small (less than 1 mm in size) pedunculated and vascularized polyps. These subtle lesions may be sporadic or may cover most of the endometrial surface (Figure 1A).

To the best of our knowledge, micropolyposis of the endometrium was never described and its significance is therefore unknown. In our experience, micropolyps are always associated with stromal edema, homogeneous or, more frequently, non-homogeneous endometrial thickening and focal or diffuse periglandular hyperhaemia; these signs are also found in case of chronic endometritis (Cravello *et al.*, 1997). Accordingly, our preliminary histological investigations showed that micropolyps were constituted by small vascularized ingrowths covered by endometrium. The stroma of micropolyps was characterized by an accumulation of inflammatory cells (lymphocytes, plasma cells or eosinophilic granulocytes) intermingled with normal stromal cells around small vessels and glandular structures (Figure 1B).

The aim of the present paper was to describe new hysteroscopic findings and to confirm the inflammatory significance of endometrial micropolyps. For this purpose we compared retrospectively the histological findings from women in whom hysteroscopy showed the presence of these lesions with that of women with no sign of micropolyps.

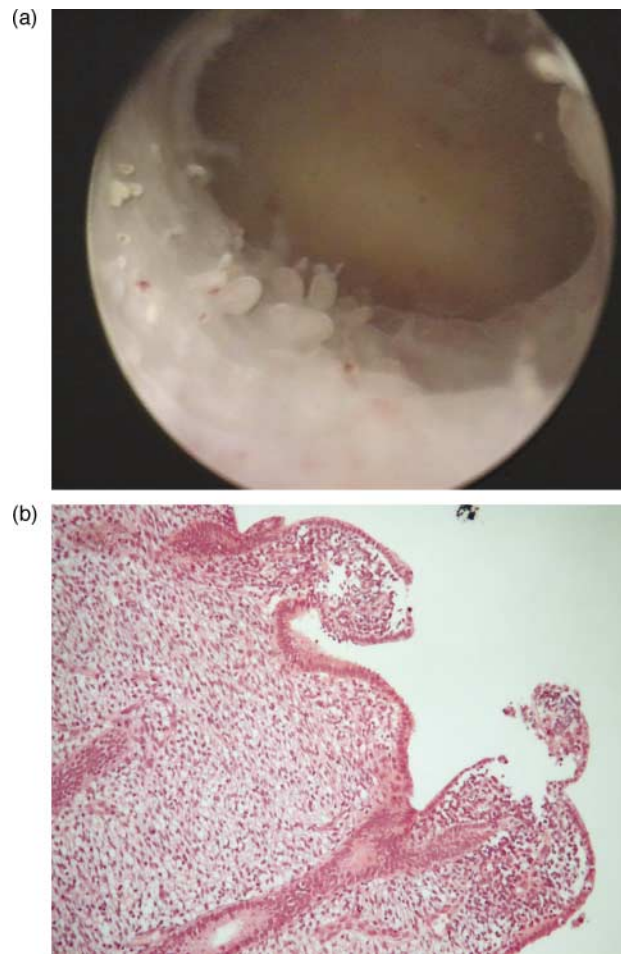


Figure 1. (A) Appearance at fluid hysteroscopy of endometrial micropolyps. Micropolyps appear as small (less than 1 mm size) endo-uterine ingrowths with a vascular axis, and float into the uterine cavity. (B) At histology, micropolyps appear as minimal new-growths with a vascular axis and covered by endometrium; the stroma of micropolyps is characterized by an accumulation of inflammatory cells (lymphocytes, plasmacells or eosinophilic granulocytes) intermingled with normal stromal cells around small vessels and glandular structures.

Materials and methods

In the period September 2003–May 2004 we examined 820 outpatients women referring to our Endoscopic Unit for diagnostic mini-hysteroscopy. The study was approved by our Institutional Review Board and all women gave their informed consent. The indications for hysteroscopy are shown in Table I.

Mini-hysteroscopies were performed using a lens-based 2.7 mm outer diameter (OD) mini-telescope, 105° angle of visual field equipped with a 3.5 mm OD single-flow diagnostic sheath (Slim-line hysteroscope, ACMI, Southborough, MA).

All hysteroscopies were performed in the follicular phase and the examinations were carried out using the speculum without tenaculum. Contraindications for hysteroscopy were the presence of heavy bleeding, severe cardio-vascular disease and suspected pregnancy. Cases of endometrial neoplasia were excluded from the study.

Saline was employed to distend the uterine cavity at a pressure generated by simple drop from a bag suspended 1 m above the patient. A 300 W light source with a xenon bulb (ACMI, Southborough, MA), a 3 charge couple device digital (CCD) camera

Table I. Indications for hysteroscopy and prevalence of the evidence of micropolyps for each indication in 820 women who underwent fluid hysteroscopy. Percentage values are reported in brackets. Pre-menopausal abnormal uterine bleeding (AUB) indicates women without evidence of any abnormality at transvaginal echography (TVE); C.E. histology means chronic endometritis at histology

Indications	Total	Micropolyps at hysteroscopy	C.E. histology
Pre-menopausal AUB	195	28 (14.4%)	47 (24.1%)
Post-menopausal bleeding	130	0	2 (1.5%)
Infertility	127	31 (24.4%)	50 (39.4%)
Polyp at TVE	164	22 (13.4%)	38 (23.2%)
Cervical polyp	92	6 (6.5%)	10 (10.9%)
Submucous myoma	51	1 (2.0%)	3 (5.9%)
Malformation	61	8 (13.1%)	18 (29.5%)
Total	820	96 (11.7%)	168 (20.5%)

(Micro-Digital IIIe, ACMI, Southborough, MA) and a 21 inch video color screen (Sony Trinitron, PVM-20M2MDE, Sinigawa-Ku, Tokyo, Japan) were used.

During hysteroscopy, both the anterior and posterior uterine walls were thoroughly examined by approaching the hysteroscope along the endometrial surface in order to get a view parallel to the endometrial surface. In this way, any irregularity of the endometrial surface was easily identified.

All hysteroscopies were performed by two of the authors (E.C., R.N.) who paid attention to the presence of micropolyps. Following the hysteroscopy, all patients underwent oriented endometrial biopsy by means of a 3 mm Novak's curette connected to a 20 ml syringe. The Novak's curette was directed towards the areas in which hysteroscopy showed the highest concentration of micropolyps.

All procedures were performed without any kind of anesthesia. A single oral dose of antibiotic was given at the end of examinations (800 mg pefloxacin).

Endometrial samples were fixed in neutral formaline and embedded in paraffin according to routine histological procedure. Five microsections were stained with hematoxylin–eosin. The histological examinations were performed by a single operator (L.R.) who was unaware of hysteroscopic findings. For the histological diagnosis of chronic endometritis the criteria described in the literature were employed (Greenwood and Moran, 1981). Attention was paid to the following features: superficial stromal edema, increased stromal density, pleomorphic stromal inflammatory infiltrate dominated by lymphocytes and plasma cells.

The frequency of histological signs of chronic endometritis in women with micropolyps was compared with that observed in women without micropolyps by using Chi-square test. A value of $P < 0.05$ was considered statistically significant.

Sensitivity, specificity, positive and negative predictive values of the presence of micropolyps for the existence of chronic endometritis confirmed histologically were calculated by means of a 2×2 table (Stempel, 1992); the accuracy of the micropolyps' presence for the diagnosis of chronic endometritis (true positive + true negative / total population) was also calculated.

Results

A flow diagram for the study is shown in Figure 2 and the prevalence of micropolyps at hysteroscopy for each group of indication is shown in Table I. Micropolyps were found in 96 cases (11.7% of all hysteroscopies). Micropolyps were always associated with other hysteroscopic signs of chronic endometritis (focal or diffuse hyperemia, stromal edema,

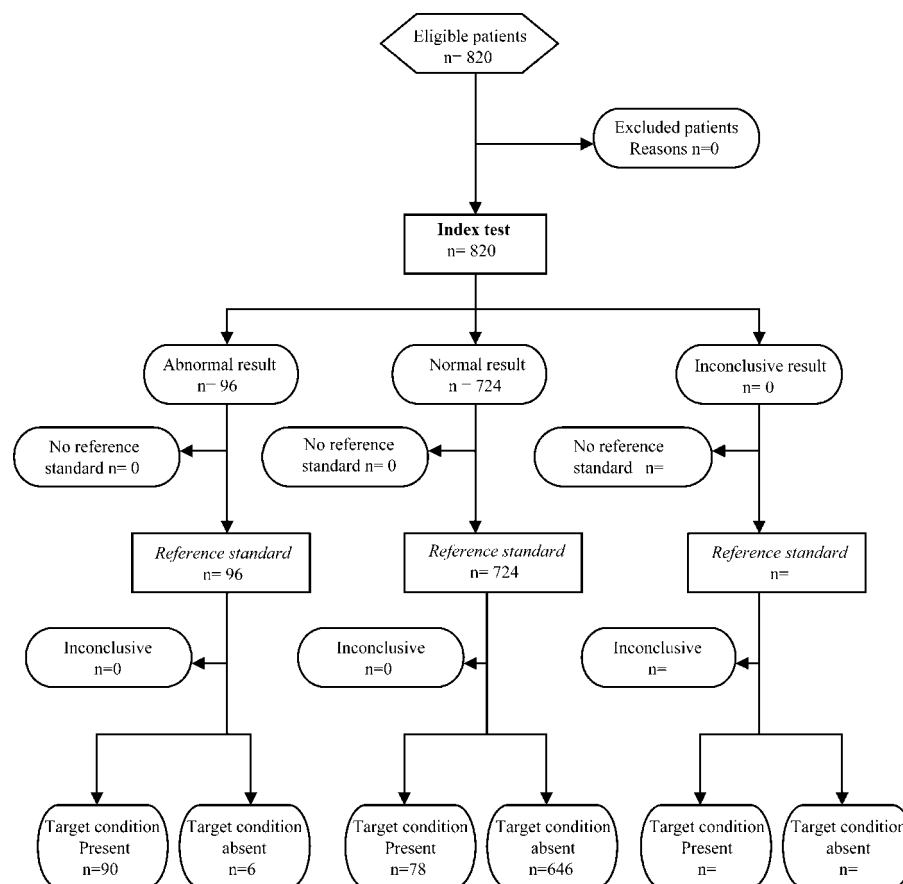


Figure 2. STARD Flow Diagram for a study of 820 women undergoing mini-hysteroscopy. An abnormal result represents the presence of micropolyps and the target condition is chronic endometritis.

homogeneous or, more frequently, non-homogeneous endometrial thickening).

In 90 (93.7%) out of 96 women with endometrial micropolyps the histological examination showed presence of chronic endometritis. In the remaining six cases the histology was found to be normal. Conversely, in women with no evidence of micropolyps, chronic endometritis at histological examination was significantly less frequent (78 cases, 10.8%) ($P < 0.000001$). The likelihood to have a histological diagnosis of chronic endometritis for women with micropolyps was very high (odds ratio 124.2, confidence interval 50.3–205.4).

By considering all cases of chronic endometritis confirmed at histological examination, presence of endometrial micropolyps at hysteroscopy was demonstrated in 53.6% of the cases. The sensitivity, specificity, positive and negative predictive values of the micropolyps' presence for the existence of chronic endometritis confirmed histologically was 54%, 99%, 94% and 89%, respectively; the diagnostic accuracy was 90%.

Discussion

The present study indicates that finding micropolyps at fluid hysteroscopy is associated with a 94% probability of chronic endometritis. However, the reverse observation is less secure; in patients with confirmed endometritis micropolyps were

only observed in 54% of the cases. Thus, the presence of endometrial micropolyps at fluid hysteroscopy can be considered a reliable diagnostic sign of chronic endometritis. To the best of our knowledge the association between endometrial micropolyps and chronic endometritis has not been described before.

From a diagnostic point of view, chronic endometritis is a pathology that it is difficult to identify. It is not detectable at transvaginal sonography and it can only be suspected in case of complications like adhesions, pyometra or hydrometra. Recently, the presence of vaginal polymorphonuclear leukocytes has been reported to have a high sensitivity and negative predictive value for the diagnosis of upper genital tract infection (Yudin *et al.*, 2003). Hysteroscopy is the best technique for identifying chronic endometritis. At direct inspection of the uterine cavity, chronic endometritis is characterized by the presence of areas of red endometrium flushed with a white central point, localized or scattered throughout the cavity, realizing a typical aspect called 'strawberry aspect' (Cravello *et al.*, 1997). The reddish color with a 'starry sky' white configuration is similar in appearance to diffuse colpitis seen with a colposcope. It may also appear as whitish plaques that are friable and bleed easily (Dotto *et al.*, 2003). However, each of these signs may be mild so that even at hysteroscopy the diagnosis may be doubtful or missed.

Presence of micropolyps is an additional finding during fluid hysteroscopy one must look for in order to support the suspicion of endometritis. Notwithstanding the small size, detection of these subtle lesions is easy when saline is used for distention, as it allows the micropolyps to float. On the contrary, when using CO₂, endometrial ingrowths are flattened against the endometrial surface. Moreover, using the saline the continuous washing of the uterine cavity also ensures a clear vision in the presence of mucus or easy bleeding, which are frequently present in the case of endometrial inflammation.

Our experience with endometrial micropolyps is in accordance with that reported with transvaginal hydrolaparoscopy; in fact, also in this case hydroflotation allows the detection of subtle lesions on the surface of tubes and ovaries, subtle lesions that are missed at conventional CO₂ laparoscopy (Gordts *et al.*, 2002).

In our study, presence of micropolyps agrees with the above described clinical symptoms attributed to chronic endometritis. In fact, the prevalence of micropolyps was higher in women undergoing hysteroscopy due to abnormal uterine bleeding (14.4% vs 11.7%); moreover, if we consider all together the indications related to bleeding [pre-menopausal abnormal uterine bleeding (AUB), suspected endometrial polyp, endocervical polyp, intracavitary myoma] they were present in up to 36.3% of cases of micropolyps.

Notably, while the prevalence of micropolyps in the overall population was 11.7%, this was 2.1-fold greater in women undergoing hysteroscopy due to infertility and 3.2-fold greater if we also consider women who underwent hysteroscopy due to infertility and with a suspected uterine malformation. This is in accordance with findings from Feghali and coworkers who found in 45% of cases some pathological finding at diagnostic hysteroscopy prior to IVF; most of these abnormalities were endometritis (Feghali *et al.*, 2003). Accordingly, Taylor and Frydman have reported that the inflammatory aspects of the endometrium (when observed by hysteroscopy) accompany the failures of IVF and that a positive correlation exists between endometrial congestion and positive sperm culture (Taylor and Frydman, 1996).

Micropolyps were detected in pre-menopausal women and not in post-menopausal women. This finding suggests that micropolyps, which are generated by the accumulation of inflammatory cells and edema in the stroma, are probably expressive of an active and strong endometrial reaction. It is known, indeed, that in case of endometrial inflammation, high concentration of macrophages, interleukins and local growth factors takes place (Dechaud *et al.*, 1998; Richter *et al.*, 1999). It is possible to speculate that epithelial and vascular postmenopausal atrophy prevent these modifications to take place and micropolyps to form.

This opens the question why micropolyps were present in only about 50% of the cases of chronic endometritis. We can speculate that in some cases we could have overlooked the lesions, or that different expression of endometrial factors or different infectious agents may explain this discrepancy. Unfortunately, in this study (which only aims at defining the significance of micropolyps), infectious investigations were

not performed and therefore we can not make any correlation between etiological agents and presence of micropolyps.

At histology, signs of chronic endometritis may be focal and as inflammatory cells are normally present in the endometrial mucosa the histological diagnosis of chronic endometritis is not always easy. In order to facilitate the histological diagnosis, we tried to obtain endometrial samples as large as possible. We therefore preferred to perform oriented endometrial biopsies by using a 3 mm Novak's curette instead of guided biopsies using endoscopic forceps. Moreover, as described above, all histological examinations were performed by the same experienced histopathologist (L.R.).

In six cases, histology did not confirm the inflammatory disease of the endometrium. Due to the fact that at hysteroscopy, micropolyps were always associated with at least one of the above mentioned other signs of endometritis, we can exclude that this discrepancy could be related to the absence of signs of inflammation, but are more likely due to the difficulty in the histological evaluation of this pathology.

In conclusion, the finding of micropolyps at fluid hysteroscopy strongly suggests the existence of chronic endometritis. Thanks to floating, the presence of endometrial micropolyps is easy to detect and this should always be looked for when hysteroscopy is performed due to AUB or infertility.

References

- Indman PD (2000) Instrumentation and distention media for the hysteroscopic treatment of abnormal uterine bleeding. *Obstet Gynecol Clin North Am* 27,305–315.
- Cicinelli E, Parisi C, Galantino P, Pinto V, Barba B and Schonauer S (2003) Reliability, feasibility, and safety of minihysteroscopy with a vaginoscopic approach: experience with 6,000 cases. *Fertil Steril* 80,199–202.
- Cravello L, Porcu G, D'Ercole C, Roger V and Blanc B (1997) Identification and treatment of endometritis. *Contracept Fertil Sex* 25,585–586.
- Greenwood SM and Moran JJ (1981) Chronic endometritis: morphologic and clinical observations. *Obstet Gynecol* 58,176–184.
- Stempel LE (1992) Eenie, meenie, minie, mo ... What do the data really show? *Am J Obstet Gynecol* 144,745–752.
- Yudin MH, Hillier SL, Wiesenfeld HC, Krohn MA, Amortegui AA and Sweet RL (2003) Vaginal polymorphonuclear leukocytes and bacterial vaginosis as markers for histologic endometritis among women without symptoms of pelvic inflammatory disease. *Am J Obstet Gynecol* 188,318–323.
- Dotto JE, Lerna B, Dotto JR, Jr and Hamou J (2003) Classification of microhysteroscopic images and their correlation with histologic findings. *J Am Assoc Gynecol Laparosc* 10,233–246.
- Gordts S, Campo R, Puttemans P, Verhoeven H, Gianaroli L, Brosens J and Brosens I (2002) Investigation of the infertile couple: a one-stop outpatient endoscopy-based approach. *Hum Reprod* 17,1684–1687.
- Feghali J, Bakar J, Mayenga JM, Segard L, Hamou J, Driguez P and Belaisch-Aillart J (2003) Systematic hysteroscopy prior to in vitro fertilization. *Gynecol Obstet Fertil* 31,127–131.
- Taylor S and Frydman R (1996) Hysteroscopy and sperm infection. *Contracept Fertil Sex* 24,549–551.
- Dechaud H, Maudelonde T, Daures JP, Rossi JF and Hedon B (1998) Evaluation of endometrial inflammation by quantification of macrophages, T lymphocytes, and interleukin-1 and -6 in human endometrium. *J Assist Reprod Genet* 15,612–618.
- Richter HE, Holley RL, Andrews WW, Owen J and Miller KB (1999) The association of interleukin 6 with clinical and laboratory parameters of acute pelvic inflammatory disease. *Am J Obstet Gynecol* 181,940–944.

Submitted on November 22, 2004; resubmitted on December 22, 2004; accepted on January 13, 2005