

A novel application of ^1H magnetic resonance spectroscopy: non-invasive identification of spermatogenesis in men with non-obstructive azoospermia

David S. Aaronson^{1,*}, Rahwa Iman², Thomas J. Walsh³,
John Kurhanewicz^{1,2,†}, and Paul J. Turek^{4,†}

¹Department of Urology, University of California San Francisco, San Francisco, CA 94117, USA ²Department of Radiology, University of California San Francisco, San Francisco, CA 94117, USA ³Department of Urology, University of Washington, Seattle, WA 98195, USA
⁴The Turek Clinic, San Francisco, CA 94133, USA

*Correspondence address. UCSF Medical Center, Department of Urology Ambulatory Care Center, Suite A633, San Francisco, CA 94117, USA. Tel: +1-415-353-2200; Fax: +1-415-476-1239; E-mail: daaronson@urology.ucsf.edu

Submitted on October 22, 2009; resubmitted on December 5, 2009; accepted on December 8, 2009

BACKGROUND: About 10% of infertile men have no sperm in their ejaculate due to poor or absent spermatogenesis, also known as non-obstructive azoospermia (NOA). Testis ^1H magnetic resonance spectroscopy (^1H -MRS) is a non-invasive imaging tool that can potentially identify and localize spermatogenesis in the testis. This study sought to identify metabolic signatures associated with various histological states of spermatogenesis in infertile men.

METHODS: Quantitative high resolution magic angle spinning spectroscopy was performed on snap frozen testicular tissue from 27 men with three classic histological patterns: (i) normal spermatogenesis (men with prior paternity undergoing vasectomy reversal), (ii) maturation arrest (early or late, MA) or (iii) Sertoli-cell only (SCO). Concentrations of 19 tissue metabolites were acquired from each biopsy specimen. One-way ANOVA analysis was used to determine inter-group differences in metabolite concentrations among the three histologic groups.

RESULTS: Phosphocholine (PC) and taurine tissue concentrations were significantly different between normal and SCO tissue. Mean PC concentrations were three times higher in normal testes compared with SCO (5.4 ± 1.4 versus 1.5 ± 0.3 mmol/kg; $P = 0.01$). No differences in metabolite concentrations were observed between normal and MA testes or between SCO and MA testes. Further histologic stratification of MA testes into subsets of those with (early) and without (late) spermatids or mature sperm, identified differences in PC concentrations. A predictive model for sperm presence with ^1H -MRS was developed based upon PC tissue concentrations.

CONCLUSIONS: PC concentrations are significantly higher in testes with spermatogenesis. This suggests that a unique metabolic signature for spermatogenesis is possible using ^1H -MRS which could aid in the non-invasive diagnosis of sperm in men with NOA.

Key words: MR spectroscopy / azoospermia / male infertility / spermatogenesis

Introduction

It is estimated that 10–15% of couples are infertile, and of those, nearly half will involve male factors (Thonneau *et al.*, 1991). Further, 6–10% of infertile men have no ejaculated sperm due to testicular failure, a condition termed non-obstructive azoospermia (NOA; Costabile and Spevak, 2001). Some NOA men have small numbers of sperm in the testicle which can be extracted using sperm retrieval techniques and used with *in vitro* fertilization and intracytoplasmic

sperm injection (ICSI) for biological pregnancies (Palermo *et al.*, 1992; Donoso *et al.*, 2007).

Unfortunately, determining which NOA men have retrievable sperm in the testicle is a clinical challenge. Potential predictors of successful sperm retrieval that have been examined include infertility diagnosis, history of ejaculated sperm, serum hormones, testis volume and testis biopsy histology (Schlegel *et al.*, 1997; Seo and Ko, 2001; Raman and Schlegel, 2003). Although all are poor predictors, the testicular biopsy best predicts the presence or absence of

[†] The last two authors share last authorship.

sperm (Ezeh *et al.*, 1999). Because of this dilemma, reproductive urologists have developed other sperm sampling strategies, such as diagnostic fine needle aspiration (FNA) testis 'mapping' or multi-biopsy microdissection sperm extraction, to predict or find sperm in NOA men (Schlegel, 1999; Turek *et al.*, 1999, 2000). Indeed, even with these newer technologies, some of which are quite invasive, sperm is found in only 60–65% of NOA men (Donoso *et al.*, 2007). Thus, reproductive medicine is in need of better and less invasive technologies that can determine whether NOA men have usable, mature sperm for ICSI.

^1H magnetic resonance spectroscopic (^1H -MRS) imaging has the potential to be a novel, non-invasive diagnostic tool that can identify sperm in NOA men. This technology merges ^1H spectroscopy with magnetic resonance imaging and can delineate differences in metabolism in as little as 0.16 ml of tissue (Kurhanewicz *et al.*, 2002). Unlike current fertility assessments, MRS has also been shown to be able to directly measure testis metabolic activity. In older studies using ^{31}P MRS, a variant of the ^1H -MRS, qualitative differences were observed in MR spectra between normal, ischemic and hormonally treated canine and rat testes (Bretan *et al.*, 1987; van der Grond *et al.*, 1991, 1992; Srinivas *et al.*, 2001). Thus, the potential for metabolic imaging of the testis to distinguish among various states of testis pathology is demonstrated.

Recent advances MR technology, including water and lipid suppression and improved spatial resolution, make metabolic mapping of the human testis even more plausible. Indeed, high-resolution magic angle spinning spectroscopy is a non-destructive, non-radioactive nuclear magnetic resonance (NMR) technique that can be applied to intact tissue samples and that provides solution-like NMR spectra for identification and quantification of individual tissue metabolites (Cheng *et al.*, 2001). In this study, we applied quantitative, high resolution, angle spinning ^1H -MRS spectroscopy, with Electronic REference To access *In Vivo* Concentrations (ERETIC) methodology (Tessem *et al.*, 2008), to assess the metabolic findings from frozen testis biopsy specimens with known normal and abnormal histologies. Our goal was to determine if a unique metabolic signature could be derived to characterize complete spermatogenesis.

Materials and Methods

Study design and patient population

This single center analysis was conducted on human testis biopsy specimens obtained from men with infertility or undergoing vasectomy reversal. Tissue specimens were obtained for banking with informed consent from the patient and institutional review board approval. Testis biopsies were derived from three groups of patients: (i) nine men undergoing vasectomy reversal with prior paternity (normal); (ii) nine men with NOA with histological or cytological findings (Meng *et al.*, 2000) consistent with maturation arrest (MA, early $n = 5$ and late, $n = 4$); and (iii) nine men with NOA and with pure histological or cytological findings of Sertoli-cell only (SCO) histology. The associated clinical features of the testis tissue donors were recorded for the purpose of the study. All patients were assessed with serum testosterone, luteinizing (LH) and follicle stimulating hormone (FSH) levels. The azoospermic individuals were then further evaluated cytologically and histologically with bilateral testicular FNA mapping, and testis biopsy (Turek *et al.*, 2000).

Specimen handling

Testis biopsies were obtained at time of vasectomy reversal in fertile men or during the diagnostic infertility evaluation of NOA. At the time of each procedure, a 25–50 mg sample of testis tissue was retrieved and split into two specimens: one half was flash frozen and stored at -80°C freezer and other half was sent for pathologic review.

Pathology and cytology

Testis biopsies from men undergoing vasectomy reversal were subject to histologic review to confirm normal spermatogenesis. Infertile men being evaluated for NOA had both histologic review of the biopsy specimen and cytologic review of the FNA mapping findings from remainder of the biopsied testis. Testis biopsies were evaluated according to the criteria of (Levin, 1979). Biopsy patterns were categorized as: normal spermatogenesis, hypoplasia or hypospermatogenesis, complete or early maturation arrest (EMA), SCO, incomplete or late maturation arrest (LMA) or other (including sclerosis). If a biopsy contained a single histologic pattern throughout the specimen, it was deemed a pure pattern. If biopsies exhibited two or more patterns, then a mixed pattern was assigned. Cytologic findings from FNA mapping from the remainder of the biopsied testis were classified histologically as reported earlier (Meng *et al.*, 2000). To reduce testis phenotypic variability as much as possible, only pure cytologic patterns from FNA mapping that corresponded to pure histologic patterns were included for SCO patients in this study.

^1H high resolution magic angle spinning spectroscopy

Frozen thawed testis tissues were weighed (mean 13.64 ± 6.89 mg) and placed into custom designed 20 or 35 μl leak proof zirconium rotors containing 3.0 μl D_2O + 0.75% TSP (3-(trimethylsilyl)-propionic-2,2,3,3-d4 acid sodium salt). ^1H -MRS data were acquired at 11.7T, 1°C , and 2250 Hz spin rate using a Varian INOVA spectrometer, equipped with a 4 mm gHX nanoprobe. Quantitative 1-D spectra were acquired with 2 s relaxation, 2 s pre-saturation, 2 s acquisition ($\text{TR} = 6$ s), 40 000 points, 20 000 Hz spectral width and 256 transients. The ERETIC method was used as a quantitative concentration standard (Tessem *et al.*, 2008). Data were quantified with a custom version of quantification software based on semi-parametric quantum estimation (QUEST), called high resolution-QUEST (HR-QUEST), adapted for analysis of short-echo time ^1H -MRS spectra containing 40 000 points (Ratney *et al.*, 2005). Basis set spectra of 19 metabolites were collected in solution and incorporated into the HR-QUEST fitting routine. The main MR-observable ^1H metabolites in the human testis—choline (Cho), creatine (Cr), glutamate (Glu), glutamine (Gln), lactate (Lac), myo-inositol (ml), phosphocreatine (PCr), phosphocholine (PC), phosphoethanolamine and taurine (Tau)—were quantified and evaluated. Peaks from known macromolecules and unidentified compounds were also included as part of the basis set. HR-QUEST estimated the background signal using a Hankel-Lanczos singular value decomposition (HLSVD) algorithm and iterated between fitting the metabolites and modeling the background six times. Finally, concentrations were calculated relative to the peak area of the ERETIC signal.

Two dimensional total correlation spectroscopy (TOCSY) ^1H -MRS data were also acquired for each biopsy sample and used to further quantify the relative amounts of PC glycerol phosphocholine (GPC), phosphoethanolamine (PE) and glycerol phosphoethanolamine as these metabolites overlap in the 1-D ^1H -MRS spectra of the testes. The TOCSY spectra were acquired using a rotor synchronized adiabatic (WURST-8) mixing scheme with 1 s presaturation delay, 0.2 s acquisition time, 40 ms mixing time, 24 transients/increment, $20\,000 \times 6000$ Hz spectral width, 4096×64 complex points, time ~ 1 h (Zektzer *et al.*, 2005).

Statistical analysis

An exploratory study using one-way ANOVA was performed to discern which metabolites, if any, would be significant indicators for the three histologies. A normality test was performed to assess for normal distribution.

Table 1 Clinical features, biopsy and cytology results for patient cohorts.

	Normal	Maturation arrest	Sertoli-cell only
Total number	9	9	9
Mean age (range)	45 (32–56)	35 (29–43)	36 (29–47)
Testosterone <350 ng/dl	NA	1	1
FSH > 15 IU/ml	NA	0	5
Biopsy findings			
Fibrosis/hyalinization	0	1	3
Leydig hyperplasia	0	1	4
Inflammation	0	0	1
Spermatids	0	1	0
Cytology findings			
Spermatids or sperm	NA	4	0

NA, not applicable; FSH, follicle-stimulating hormone.

Logistic regression analysis was performed using the binary dependent variable of testis biopsy histology (normal or SCO) and the independent variables, age and a solitary metabolite. For metabolites that had age-adjusted *P*-values <0.05, we modeled the predicted probability of 'normal spermatogenesis' for the EMA testis tissue samples using the logistic regression equation for normal versus SCO patients. Odds ratios (OR) with 95% confidence intervals were determined.

Results

A total of 27 patient biopsies were evaluated from men at vasectomy reversal or from men with non-obstructive azoospermia. Patients were identified on biopsy and/or FNA mapping as having normal (*n* = 9), MA (early, *n* = 5 and late, *n* = 4) or pure SCO (*n* = 9) histology. The mean age of the normal-fertile group was older than that of either of the other groups (Table 1).

Representative 1-D ¹H-MRS spectra from biopsies taken from patients having normal (A), MA (B) and SCO histology (C) are shown in Fig. 1. Spectral peaks are labeled with their corresponding metabolites and have been scaled to the ERETIC peak so they visually reflect true and actual differences in metabolite concentration. Note that the spectral peak labeled PC is markedly elevated in normal compared with SCO patients and the PC peak for the MA patients is between that of the normal and SCO groups. The GPC and PC resonances cannot be resolved in the 1-D testes spectra as they overlap. However, the 2-D TOCSY spectra of the same testis samples indicate that the PC peak, which is composed of both GPC and PC, was predominantly composed of PC (Fig. 2).

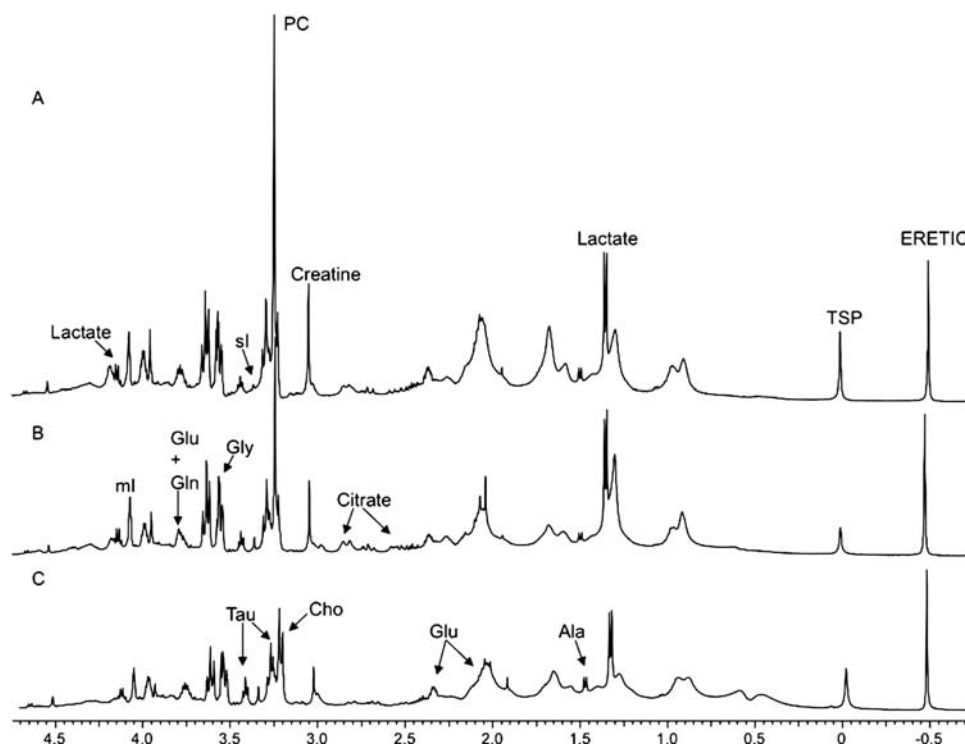


Figure 1 One-dimensional ¹H-MRS sample spectra of (A) normal (B) MA and (C) SCO testis biopsies from three patients.

Note the normalized peak at 3.2 ppm labeled PC in A is taller than in B or C. ¹H-MRS, ¹H magnetic resonance spectroscopy; MA, maturation arrest; SCO, Sertoli cell only.

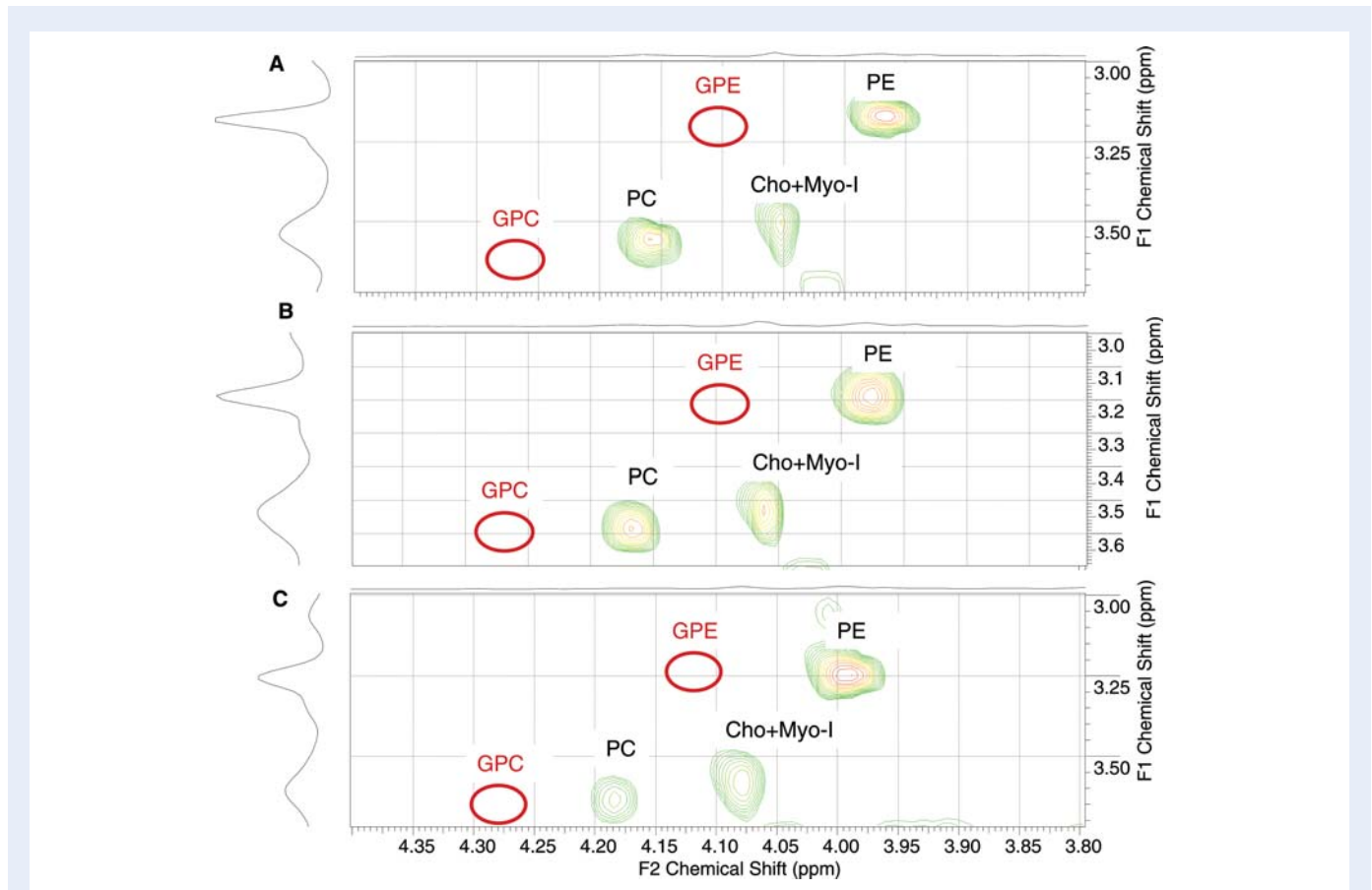


Figure 2 Two-dimensional spectral resolution of the PC peak for (A) normal, (B) MA and (C) SCO testis biopsies.

Red circle shows where labeled metabolite would exist if present. This demonstrates that the 1-D testis spectral peak of PC is composed predominantly of PC on 2-D TOCSY analysis. PC, phosphocholine; GPC, glycerol phosphocholine; GPE, glycerol phosphoethanolamine; PE, phosphoethanolamine; Cho + Myo-I, choline plus myo-inositol; ppm, parts per million.

Table II shows the mean concentration of each measured metabolite by histologic diagnosis and the standard deviation and OR with 95% confidence intervals using one-way ANOVA. Only the normal and SCO groups had metabolite concentrations that were statistically different. The MA group had a variation in the concentrations of most metabolites that were between the normal and SCO groups. Mean concentrations of PC were 2.8, 1.07 and 1.35 mmol/kg for the normal, SCO and MA groups, respectively [OR = 23.44, CI 95% (1.04–530.50) $P = 0.048$]. Finally, mean concentrations of taurine were significantly different at 0.96, 2.46 and 1.73 mmol/kg between the normal, SCO and MA groups, respectively [OR = 0.29, CI 95% (0.09–0.93) $P = 0.037$].

We examined the cytology and pathology reports for the patient cohorts to determine if there were any features such as the presence of spermatids or sperm that might explain the heterogeneity of metabolic findings in the MA group. We observed that testis biopsies that showed LMA patterns exhibited higher concentrations of PC than did specimens with EMA (data not shown). Figure 3 shows a univariate model of PC concentration and the probability of having spermatids or sperm. Normal testis tissue had a predicted probability of 1.0 and SCO had a probability of 0. The MA group harbored PC concentrations that spanned this entire range, but when accounting for the

presence of spermatids or sperm, we observed that a concentration of 1.5 mmol/kg or higher of PC predicted spermatid or sperm presence. This association was not evident for GPC or taurine concentrations.

Discussion

Male factor infertility due to NOA currently requires invasive testing (biopsy or FNA) to determine whether or not sperm is present. We propose a novel use of ^1H -MRS technology to potentially reduce the need for such invasive testing and present ex vivo testis data suggesting that it may have the power to differentiate among different histologic states of the testis. Our study attempts to quantify a metabolic signature for normal spermatogenesis using ex vivo analysis of testicular biopsies from fertile and infertile men with well-characterized histologic and cytologic abnormalities. Our results suggest that testis tissue containing spermatids or sperm carries a distinct chemical signature that can be distinguished by ^1H -MRS.

We found that PC concentrations were dramatically higher in patients with normal spermatogenesis compared with those with SCO histology. This is consistent with the fact that elevated PC concentrations are typically associated with states of high phospholipid

Table II Description of concentration measurement variables by group.

	Normal			SCO			Maturation arrested		
	n	Mean	SD	n	Mean	SD	n	Mean	SD
Alanine	9	1.034	0.423	9	1.564	0.579	9	0.970	0.639
Choline	9	0.389	0.128	9	0.549	0.255	9	0.315	0.225
Citrate	9	0.165	0.111	9	0.122	0.104	9	0.177	0.213
Glutamate	9	3.602	1.437	9	5.123	2.492	9	2.778	1.945
Glutamine	9	0.664	0.269	9	0.883	0.683	9	0.359	0.420
Glycine	9	2.071	0.891	9	4.808	3.727	9	1.745	1.080
MI	9	9.281	3.428	9	8.229	3.998	9	6.547	5.751
PC*	9	3.247	1.160	9	1.238	0.652	9	1.532	1.333
PE	9	26.020	9.321	9	25.940	11.677	9	15.373	12.333
Inositol	9	0.170	0.118	9	0.308	0.268	9	0.261	0.219
Taurine*	9	0.963	0.528	9	2.457	1.332	9	1.728	1.880
Total creatine	9	1.696	0.813	9	1.041	0.381	9	0.989	0.926
Lactate	9	4.726	2.995	9	6.028	2.418	9	4.434	3.838

*Significant difference between the normal and SCO groups for PC [OR = 23.44, CI 95% (1.04–530.50) $P = 0.048$] and Taurine (OR = 0.29, CI 95% (0.09–0.93) $P = 0.037$].

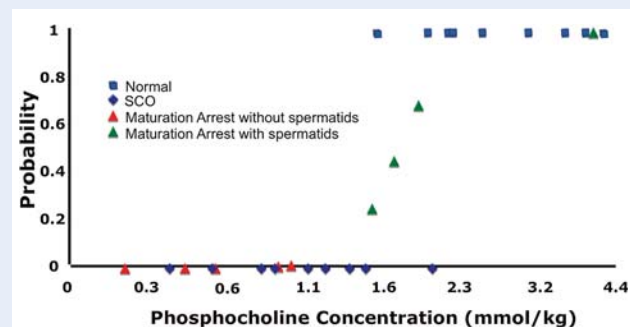


Figure 3 Graphic representation of univariate analysis of PC concentrations among normal, SCO, and MA testis biopsies.

The expected probability of finding sperm is plotted against testis tissue PC concentrations. Points on graph represent actual clinical tissue samples from study subjects. Note, the MA group is divided into green and red triangles based upon men with evidence of spermatids on cytology or pathology; SCO, Sertoli cell only.

membrane synthesis and active cellular proliferation (Cohen, 1988; Cox, 1996). In the testis, rates of cellular proliferation, as measured by phospholipid synthesis, are related to the number of proliferating germ cells, specifically, spermatogonia and spermatocytes undergoing meiosis to eventually become sperm. The support cells in the testis, specifically Leydig and Sertoli cells, reproduce only slowly and would therefore not be expected to contribute meaningfully to phospholipid synthesis. A testis producing sperm requires constant membrane synthesis, and therefore harbors a large substrate pool of PCs. In fact, the PC concentration differences observed here are higher than in other human tissues studied with this technology to date, including benign and malignant prostate (Swanson *et al.*, 2008). In addition, men with MA who had evidence of spermatids or mature sperm had more 'normal' PC levels than men without post-meiotic cells in the

biopsy. We also identified another tissue metabolite, taurine, that, on further analysis, may also play a role in predicting the presence of sperm in the testis.

Two areas of utility exist for this non-invasive diagnostic study in the field of male infertility. On further testing in the clinical setting, the *in vivo* use of ¹H-MRS may be able to replace the diagnostic testis biopsy to determine which azoospermic men have normal versus abnormal spermatogenesis. Thus, men with non-obstructive azoospermia may be able to be risk stratified prior to biopsy or FNA for the likelihood of finding sperm. This could reduce patient morbidity and also rationalize and redirect medical expenditures to other options for successful reproduction such as adoption or donor sperm insemination. Second, this technology has the power to interrogate testis metabolism in as many as 100 pixelated areas within the testis, thus increasing the sample size of assessing for sperm presence to exceed that of any of the commonly used and more invasive testis sperm detection or retrieval methods today.

Clearly, further testing *in vivo* is warranted before this technology is used clinically in the evaluation of male factor infertility. It must be further clarified that the *ex vivo* metabolic model developed here will correlate with *in vivo* clinical findings. The effects of freezing and thawing of biopsy tissue on spectroscopy findings relative to *in vivo* tissue assessment must also be further assessed. In addition, the observation that spermatids or mature sperm were found in some testes with MA histology suggests that accurate patient phenotyping is essential to the realization of a true metabolic signature for normal spermatogenesis. Our inclusion of global testis cytologic data from an extensive FNA mapping procedure was one approach to avoiding the biologic heterogeneity inherent in cases of non-obstructive azoospermia.

¹H-MRS is an FDA-approved, non-invasive diagnostic technology that could replace the more invasive testis biopsy or FNA in the evaluation of NOA. This study demonstrates that a unique and characteristic metabolic signature is definable for at least two testis histological

states (normal and SCO). It also appears that EMA histology may be further characterized into patterns that may or may not contain sperm. Further work with more patients will reveal whether it is possible to precisely identify a distinct metabolic signature for sperm presence, regardless of testis histopathology.

Funding

Aaronson was supported by a UCSF Resident Clinical and Translational Research Funding Grant.

References

- Bretan PN Jr, Vigneron DB, Hricak H, McClure RD, Yen TS, Moseley M, Tanagho EA, James TL. Assessment of testicular metabolic integrity with P-31 MR spectroscopy. *Radiology* 1987;**162**:867–871.
- Cheng LL, Wu C, Smith MR, Gonzalez RG. Non-destructive quantitation of spermine in human prostate tissue samples using HRMAS 1H NMR spectroscopy at 9.4 T. *FEBS Lett* 2001;**494**:112–116.
- Cohen JS. Phospholipid and energy metabolism of cancer cells monitored by 31P magnetic resonance spectroscopy: possible clinical significance. *Mayo Clin Proc* 1988;**63**:1199–1207.
- Costabile RA, Spevak M. Characterization of patients presenting with male factor infertility in an equal access, no cost medical system. *Urology* 2001;**58**:1021–1024.
- Cox IJ. Development and applications of *in vivo* clinical magnetic resonance spectroscopy. *Prog Biophys Mol Biol* 1996;**65**:45–81.
- Donoso P, Tournaye H, Devroey P. Which is the best sperm retrieval technique for non-obstructive azoospermia? A systematic review. *Hum Reprod Update* 2007;**13**:539–549.
- Ezeh UI, Taub NA, Moore HD, Cooke ID. Establishment of predictive variables associated with testicular sperm retrieval in men with non-obstructive azoospermia. *Hum Reprod* 1999;**14**:1005–1012.
- Kurhanewicz J, Swanson MG, Nelson SJ, Vigneron DB. Combined magnetic resonance imaging and spectroscopic imaging approach to molecular imaging of prostate cancer. *J Magn Reson Imaging* 2002;**16**:451–463.
- Levin HS. Testicular biopsy in the study of male infertility: its current usefulness, histologic techniques, and prospects for the future. *Hum Pathol* 1979;**10**:569–584.
- Meng MV, Cha I, Ljung BM, Turek PJ. Relationship between classic histological pattern and sperm findings on fine needle aspiration map in infertile men. *Hum Reprod* 2000;**15**:1973–1977.
- Palermo G, Joris H, Devroey P, Van Steirteghem AC. Pregnancies after intracytoplasmic injection of single spermatozoon into an oocyte. *Lancet* 1992;**340**:17–18.
- Raman JD, Schlegel PN. Testicular sperm extraction with intracytoplasmic sperm injection is successful for the treatment of nonobstructive azoospermia associated with cryptorchidism. *J Urol* 2003;**170**:1287–1290.
- Ratney H, Sdika M, Coenradie Y, Cavassila S, van Ormondt D, Graveron-Demilly D. Time-domain semi-parametric estimation based on a metabolite basis set. *NMR Biomed* 2005;**18**:1–13.
- Schlegel PN. Testicular sperm extraction: microdissection improves sperm yield with minimal tissue excision. *Hum Reprod* 1999;**14**:131–135.
- Schlegel PN, Palermo GD, Goldstein M, Menendez S, Zaninovic N, Veeck LL, Rosenwaks Z. Testicular sperm extraction with intracytoplasmic sperm injection for nonobstructive azoospermia. *Urology* 1997;**49**:435–440.
- Seo JT, Ko WJ. Predictive factors of successful testicular sperm recovery in non-obstructive azoospermia patients. *Int J Androl* 2001;**24**:306–310.
- Srinivas M, Degaonkar M, Gupta DK, Raghunathan P, Das SN, Mitra DK. Evaluation of developing rat testis by phosphorus 31P magnetic resonance spectroscopy and DNA flowcytometry. *Pediatr Surg Int* 2001;**17**:316–320.
- Swanson MG, Keshari KR, Tabatabai ZL, Simko JP, Shinohara K, Carroll PR, Zektzer AS, Kurhanewicz J. Quantification of choline- and ethanolamine-containing metabolites in human prostate tissues using 1H HR-MAS total correlation spectroscopy. *Magn Reson Med* 2008;**60**:33–40.
- Tessem MB, Swanson MG, Keshari KR, Albers MJ, Joun D, Tabatabai ZL, Simko JP, Shinohara K, Nelson SJ, Vigneron DB et al. Evaluation of lactate and alanine as metabolic biomarkers of prostate cancer using 1H HR-MAS spectroscopy of biopsy tissues. *Magn Reson Med* 2008;**60**:510–516.
- Thonneau P, Marchand S, Tallec A, Ferial ML, Ducot B, Lansac J, Lopes P, Tabaste JM, Spira A. Incidence and main causes of infertility in a resident population (1,850,000) of three French regions (1988–1989). *Hum Reprod* 1991;**6**:811–816.
- Turek PJ, Givens CR, Schriock ED, Meng MV, Pedersen RA, Conaghan J. Testis sperm extraction and intracytoplasmic sperm injection guided by prior fine-needle aspiration mapping in patients with nonobstructive azoospermia. *Fertil Steril* 1999;**71**:552–557.
- Turek PJ, Ljung BM, Cha I, Conaghan J. Diagnostic findings from testis fine needle aspiration mapping in obstructed and nonobstructed azoospermic men. *J Urol* 2000;**163**:1709–1716.
- van der Grond J, Laven JS, te Velde ER, Mali WP. Abnormal testicular function: potential of P-31 MR spectroscopy in diagnosis. *Radiology* 1991;**179**:433–436.
- van der Grond J, Laven JS, van Ehteld CJ, Dijkstra G, Grootegeod JA, de Rooij DG, Mali WP. The progression of spermatogenesis in the developing rat testis followed by 31P MR spectroscopy. *Magn Reson Med* 1992;**23**:264–274.
- Zektzer AS, Swanson MG, Jarso S, Nelson SJ, Vigneron DB, Kurhanewicz J. Improved signal to noise in high-resolution magic angle spinning total correlation spectroscopy studies of prostate tissues using rotor-synchronized adiabatic pulses. *Magn Reson Med* 2005;**53**:41–48.