

Diagnosing cellular defects in an unexplained case of total fertilization failure

Catherine M.H. Combelles^{1,*}, Kazuto Morozumi², Ryuzo Yanagimachi², Liben Zhu³, Janis H. Fox³, and Catherine Racowsky³

¹Biology Department, Middlebury College, Bicentennial Hall 346, Middlebury, VT 05753, USA ²Institute for Biogenesis Research, John A. Burns School of Medicine, University of Hawaii, Honolulu, HI 96822, USA ³Department of Obstetrics and Gynecology, Brigham and Women's Hospital, Harvard Medical School, Boston, MA 02115, USA

*Correspondence address. E-mail: ccombell@middlebury.edu

Submitted on November 22, 2009; resubmitted on February 14, 2010; accepted on February 18, 2010

ABSTRACT: Despite the advent of ICSI, cases of total fertilization failure (TFF) often lead to cycle cancellation with limited diagnostic and therapeutic strategies currently available. We report on the case of an infertile couple who failed to conceive after repeated IVF and ICSI. Sperm of the husband were morphologically normal and passed a functional test assessing their ability to activate mouse oocytes. Whether oocytes were activated artificially with calcium ionophore after injection of husband's or with donor sperm, all oocytes failed to fertilize. Multiple polar bodies and two disorganized spindle structures were predominantly observed, pointing towards a cytoplasmic defect in the oocytes as the primary cause of the couple's infertility. In fact, injection of husband's sperm into donor oocytes resulted in the delivery of healthy twins. This report describes a course of action that may be applied for couples with TFF after both IVF and ICSI.

Key words: fertilization failure / oocyte activation / chromosome / spindle / polar body

Introduction

Despite frequent use and success of IVF treatment for infertile couples, cases of total fertilization failure (TFF) continue to exist. Their consequences are devastating to the patients, with lost resources, incurred cost and much distress. Understanding the etiology of fertilization failure (FF) is of critical importance to assist in patient counseling and optimizing treatment.

The incidence of TFF after conventional IVF using sperm of normal quality has been reported to range from 5% (Bhattacharya *et al.*, 2001) to as high as 15–20% (Barlow *et al.*, 1990; Liu and Baker, 2000). While ICSI has overcome many fertilization problems, it does not completely eliminate TFF. In a randomized clinical trial comparing outcomes after ICSI or IVF for cases of non-male factor infertility, Bhattacharya *et al.* (2001) documented a TFF rate of 2 versus 5% for ICSI and IVF, respectively. Indeed, several large studies using ICSI for a variety of infertility diagnoses reported TFF at rates of 1.3% in 1779 cycles (Esfandiari *et al.*, 2005), and 3% in 2732 cycles (Liu *et al.*, 1995) and 1343 cycles (Flaherty *et al.*, 1998). Furthermore, 3 of 33 couples experienced recurring cycles of TFF (Flaherty *et al.*, 1998), and another 3 patients with unexplained infertility had repeated TFF (Ezra *et al.*, 1992).

The possible etiologies underlying TFF are complex (Swain and Pool, 2008) and may relate to cycle-specific parameters, yield and

quality of oocytes, availability of motile sperm and/or to severity of sperm defects (Liu *et al.*, 1995; Flaherty *et al.*, 1998; Kovacic and Vlaisavljevic, 2000; Mahutte and Arici, 2003; Esfandiari *et al.*, 2005). Sperm abnormalities may result in abnormal sperm decondensation, and/or aberrant pronuclear development, migration, and apposition and first mitosis (Asch *et al.*, 1995; Rawe *et al.*, 2002a, b). Some ICSI oocytes fail to activate (Dozortsev *et al.*, 1994; Asch *et al.*, 1995; Flaherty *et al.*, 1995a, b; Tesarik and Sousa, 1995; Schmiady *et al.*, 1996; Gook *et al.*, 1998; Kovacic and Vlaisavljevic, 2000; Rawe *et al.*, 2000) which, under some circumstances, has been successfully overcome by manipulating intracellular calcium levels in oocytes by the use of ionophore or electric pulses (Yanagida *et al.*, 1999; Eldar-Geva *et al.*, 2003; Murase *et al.*, 2004; Heindryckx *et al.*, 2005).

Several early studies of gamete ultrastructure (Sousa and Tesarik, 1994), staining of DNA (Van Wissen *et al.*, 1992; Flaherty *et al.*, 1995a, b, 1998) or whole chromosomes (Racowsky *et al.*, 1992; Dozortsev *et al.*, 1994; Schmiady *et al.*, 1996; Wall *et al.*, 1996; Rosenbusch and Schneider, 1999; Rosenbusch, 2000) have identified abnormal chromatin patterns and/or chromosome numbers, of either paternal or maternal origin, in non-fertilized oocytes. Recent studies of microtubules also revealed abnormal spindle and interphase microtubules, indicating that defects in oocyte cytoplasmic components may be a cause of failed fertilization (Asch *et al.*, 1995;

Eichenlaub-Ritter *et al.*, 1995; Gook *et al.*, 1998; Kovacic and Vlaisavljevic, 2000; Rawe *et al.*, 2000, 2001, 2002a, b; Miyara *et al.*, 2003). In the present report, we have performed similar analyses for an infertile patient whose oocytes were unable to be fertilized normally either by her husband's or by the donor sperm, even after stimulation using calcium ionophore.

Methods and Results

Patient history

A 35-year-old woman with a diagnosis of tubal factor, a borderline Clomid challenge test (D3/D10 FSH: 7.8/12.2 mIU/ml) and mild endometriosis, sought IVF treatment at our centre after trying to conceive for 4.5 years. Four previous Clomid stimulations, two FSH-intrauterine insemination (IUI) cycles and one natural IUI cycle all failed without any implantation.

Cycle 1: IVF

In IVF Cycle 1, Lupron/FSH stimulation yielded 13 follicles ≥ 12 mm in diameter, with the two lead follicles having a mean diameter of 16.5 mm on the day of the hCG injection and a peak estradiol (E_2) of 3816 pg/ml. A total of 19 oocytes were retrieved and inseminated using husband's sperm with normal count and progressive motility. None of the 19 oocytes had pronuclei 18 h after IVF; 12 oocytes had a single polar body, 4 had 2 polar bodies and 3 were at the metaphase I stage. All oocytes showed normal gross morphology and good sperm attachment.

Cycle 2: standard ICSI

Cycle 2 yielded 20 follicles ≥ 12 mm in diameter (peak E_2 of 3893 pg/ml) and 21 oocytes, 20 of which were classified as mature by the presence of a single polar body. On the basis of the first cycle cancellation owing to FF, fresh sperm from the husband was used to perform ICSI. None of the 20 injected oocytes exhibited pronuclei 17 h later, although each of 17 oocytes had two polar bodies. Gross morphology of these oocytes appeared normal.

Cycle 3: cancelled cycle

The patient began a third stimulation cycle (IVF Cycle 3) that was cancelled because of a drop in E_2 on Day 15.

After TFF with both IVF (Cycle 1) and ICSI (Cycle 2), the couple agreed to an experimental protocol in an attempt to overcome their complete fertilization block of unknown causes. Institutional Review Board Approval was obtained to use two protocols: one diagnostic, the other therapeutic.

Between Cycles 3 and 4: diagnostic evaluation of the husband's sperm

Diagnostically, two tests were performed to evaluate whether the underlying cause of TFF lay in the male gametes. The husband's sperm was examined by electron microscopy and no identifiable structural abnormalities were detected. Next, the ability of the husband's sperm to activate and form a pronucleus was tested using mouse oocytes as previously employed (Araki *et al.*, 2004; Murase *et al.*,

2004; Heindryckx *et al.*, 2005). *In vivo* ovulated mature mouse oocytes were randomized to one of four groups for injection with: (i) fresh sperm from the husband; (ii) frozen donor sperm; (iii) non-injected oocytes and (iv) sham-injected with medium only as an additional control. There was no difference in the ability of the husband (75%) versus donor (71%) sperm to fertilize mouse oocytes (based on the development into pronuclear and 2-cell stages). The non-injected oocytes did not spontaneously activate and there were no signs of fertilization in the sham group.

Cycle 4: ICSI with ionophore

Given the normalcy of the husband's sperm as based on structural and functional analyses, a therapeutic approach was adopted in Cycle 4 in which ICSI was combined with treatment of oocytes with calcium ionophore (Eldar-Geva *et al.*, 2003; Murase *et al.*, 2004; Heindryckx *et al.*, 2005), based on the assumption that the fertilization block could be a result of oocyte activation failure. In this cycle, 20 follicles (≥ 12 mm diameter) were measured on the day of hCG (E_2 : 4556 pg/ml), with 24 oocytes retrieved for ICSI; the 23 mature oocytes were randomized to injection either with fresh sperm from the husband, followed by two consecutive 10 min treatments with 10 μ M ionomycin 30 min apart ($n = 15$) (Heindryckx *et al.*, 2005) or with thawed donor sperm ($n = 8$). At about 17 h after ICSI, none of the injected oocytes in either group exhibited pronuclei, and all were judged unfertilized after a final assessment ~ 7 h later, at around 24 h after sperm injection.

Analyses of failed fertilized oocytes

All non-degenerate unfertilized oocytes ($n = 21$) were fixed and processed for analysis of cytoskeletal (microtubule- and microfilament-based) and chromatin organization using conventional fluorescence microscopy with a Zeiss Axioscope inverted microscope (Zeiss, Thornwood, NY, USA) and a Zeiss LSM 510 META confocal laser scanning microscope (Combelles *et al.*, 2003). For analyses, the oocytes were grouped by the source of sperm (husband or donor) and then classified according to patterns of chromatin, microtubule and microfilament organization as observed from microscopic examination. While our study did not include a control group, we completed all evaluations based on our previous analyses of human oocytes that were processed identically (Cekleniak *et al.*, 2001; Combelles *et al.*, 2002, 2003, 2005).

Group 1: oocytes injected with husband's sperm followed by ionophore activation

Of the 15 oocytes in this group, 1 was degenerate and discarded. The remaining 14 were fixed for examination of their cytological details. Of these oocytes, 1 had no detectable polar body, 1 had 4 polar bodies, while 12 had 2 polar bodies with chromosomes and microtubules. However, 9 of these 12 had 1 to 2 extra polar body-like structures some of which were fragmented and lacked chromosomes and microtubules. Microfilaments were organized as a thick cortical ring through the circumference of the oocytes with an abnormal disposition of intermittent regions of thicker and thinner cortical rings of microfilaments in 29% (4/14) of the oocytes. None of the 14 oocytes exhibited the typical single, barrel-shaped bipolar anastral configuration characteristic of normal human metaphase-II oocyte spindles (Cekleniak *et al.*, 2001; Combelles

Table 1 Quantification of chromatin and microtubule phenotype patterns in oocytes that failed to fertilize after ICSI with either husband's or donor sperm, treated or not with ionophore.

Groups	Total # of examined oocytes	Pattern A/B (%)	Pattern C (%)	Pattern D (%)	Pattern E (%)	Pattern F (%)	Pattern G (%)	Pattern H (%)
Husband (with ionophore)	14*	7 (50)	3 (21)	–	2 (14)	–	1 (7)	–
Donor (without ionophore)	7	1 (14)	–	2 (28)	2 (28)	1 (14)	–	1 (14)
Combined	21	8 (38)	3 (14)	2 (10)	4 (19)	1 (5)	1 (5)	1 (5)

Patterns A–H correspond to the phenotypes shown in Fig. 1. This summary accounts for all 20 oocytes with two chromatin- and/or microtubule-containing structures per oocyte. *The one oocyte displaying a single spindle structure and four polar bodies after injection with the husband's sperm was not included in the pattern classification above.

et al., 2002). One oocyte (the 1 with 4 polar bodies) had a single bipolar spindle, whereas the remaining 13 showed 2 aberrant spindles of various sizes with irregular and asymmetrical poles and varying chromosomal dispositions (Table 1). In some oocytes ($n = 7$), the condensed chromosomes were not aligned in an orderly manner at the equator, but rather were dispersed within the two spindles (Fig. 1A). In the remaining six oocytes, the chromosomes were dispersed in a very small second spindle ($n = 3$; Fig. 1C), scattered in the cortex in association with a few astral microtubules ($n = 1$; Fig. 1G, arrow) or associated with two late-telophase structures showing abnormal dispersion either within or near the microtubules of each midbody ($n = 2$; Fig. 1E). All spindle structures were located in the cortex, either on the same or opposite side(s) of the oocyte, and there was no consistent positioning of these structures in relation to the polar bodies.

Group 2: oocytes injected with donor sperm without the use of ionophore activation

Of the eight oocytes injected with donor sperm, one was degenerate by the time of fertilization examination. The remaining seven were fixed and subsequently classified according to their phenotypic pattern. Each of these fixed oocytes had two to three polar bodies, two of which always contained microtubules and condensed chromosomes. While patchiness of cortical microfilaments was observed in only one of the seven oocytes, none of the seven had normal metaphase II spindles. Five (71%) of them each had two cortically located structures with various microtubule and chromatin abnormalities: two oocytes each contained two midbodies with chromosomes at either end as well as with a few scattered in the neighbouring ooplasm (Fig. 1E, arrow); one oocyte had two bipolar spindles of rather normal appearance, with the exception of irregular poles and bushy microtubule fibres emanating from the outline of the spindle and chromosomes in early separation stages (Fig. 1B) and two oocytes each had one small bipolar spindle and nearly aligned chromosomes alongside a second non-bipolar to asymmetrically bipolar the spindle-like structure, yet with chromosomes remaining relatively tightly arranged (Fig. 1D). One oocyte contained two microtubule asters, each with chromosomes organized as a single tight clump (Fig. 1F). The remaining oocyte had a single small bipolar spindle (with dispersed chromosomes) in proximity to the polar bodies along with an oval decondensed chromatin structure and no microtubules associated with it (Fig. 1H).

Cycle 5: ICSI with husband's sperm and egg donation

On the basis of the phenotypic abnormalities observed in the patient's oocytes, the couple then proceeded, at their request, to Cycle 5 using egg donation and ICSI with the husband's sperm. Nine mature oocytes were injected, resulting in six zygotes, each having two pronuclei. Two embryos were transferred to the patient on Day 3, resulting in pregnancy and delivery at 36.0 weeks of healthy twins (girl and boy, each weighing 1989g).

Discussion

The collective results of the diagnostic approaches described in this report implicate an oocyte-specific defect in spite of normal morphological appearance of all oocytes prior to injection. Our diagnostic assessment permitted the identification of cytoplasmic abnormalities across a cohort of oocytes in a patient with recurrent FF. This is in contrast to previous studies in which few oocytes, typically of suboptimal quality, were evaluated in either the setting of partial FF (Van Wissen *et al.*, 1992; Asch *et al.*, 1995; Flaherty *et al.*, 1995a, b; Gook *et al.*, 1998; Kovacic and Vlaisavljevic, 2000; Miyara *et al.*, 2003) or TFF only in a single cycle (Ezra *et al.*, 1992; Rosenbusch, 2000). Given that the majority of such patients will go on to another treatment cycle with some fertilization ensuing, these earlier studies contrast our index case of recurring TFF.

Our analyses provided some advantages over previous studies investigating the etiology of FF. First, instead of using aged material typically fixed 2 days after ICSI (Sousa and Tesarik, 1994; Gook *et al.*, 1998; Rosenbusch and Schneider, 1999; Rosenbusch, 2000; Miyara *et al.*, 2003), we assessed oocytes fixed within a few hours of the fertilization check. Nevertheless, there was a 24 h delay from the time of ICSI to fixation, and future studies should always aim to fix oocytes as quickly as possible. Indeed, oocytes are sensitive to *in vitro* associated ageing. While we cannot exclude the possibility that the observed defects may be a result of, or exacerbated by, *in vitro* ageing, it is interesting to note that previous reports document spindle abnormalities of a different nature, with loss of spindle bipolarity and chromosome dispersal (Eichenlaub-Ritter *et al.*, 1988; Pickering *et al.*, 1988). Furthermore, ageing-associated spindle degeneration has been reported to arise only after 2 days in culture (Eichenlaub-Ritter *et al.*, 1988). In contrast, we observed two spindles per oocyte with

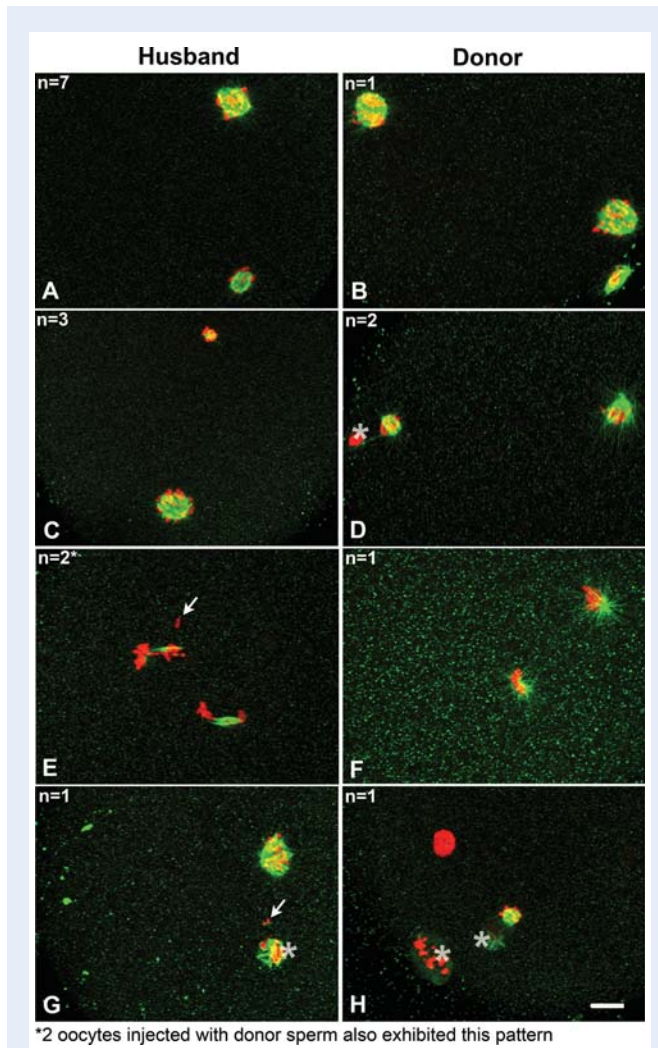


Figure 1 Three-dimensional confocal reconstructions of chromatin (red) and microtubule (green) patterns in oocytes that failed to fertilize after ICSI with either husband's (A, C, E and G) or donor (B, D, F and H) sperm. The patterns displayed in panels (A) and (B) represent the single most abundant phenotype (8/21 oocytes, 7 from husband and 1 using donor sperm) with two nearly bipolar spindles per oocyte and dispersed to almost aligned chromosomes. 3/14 oocytes injected with husband's sperm showed a bipolar spindle and a second very small spindle with dispersed chromosomes (C); none of the latter phenotype was observed in the donor sperm group (out of seven oocytes) while two of these oocytes demonstrated a bipolar spindle with nearly aligned chromosomes along with a second non-polar spindle (D). A total of four oocytes (two injected with husband's and two with donor sperm) possessed two midbody structures, two main chromosome groups, as well as scattered chromosomes (E). One oocyte injected with husband's sperm contained a non-bipolar spindle alongside a microtubule aster with a couple of scattered chromosomes (G). Lastly, the donor sperm group displayed one oocyte with two microtubule asters, each associated with a mass of condensed chromosomes (F) and another oocyte with a single spindle structure and a swollen clump of chromatin (H). Arrows represent chromosomes scattered in the ooplasm, and asterisks denote polar body structures apparent in the selected fields of view. Scale bar: 10 μm .

many of them retaining bipolarity and the presence of additional polar body structures after 1 day of culture.

A second strength of our study is that, to our knowledge, this is the first investigation to evaluate cytological features of TFF oocytes post-ICSI. Since ICSI failed to resolve the TFF, clearly sperm–oocyte contact defects were not exclusively responsible for the failure in our couple. Moreover, morphological and functional tests eliminated the possibility of a sperm deficiency per se as the husband's sperm was able to activate mouse oocytes without even the need for oocyte-activating agents, and the use of donor sperm resulted in identical ICSI fertilization defects as with the husband's sperm. So upon first inspection, this case was grossly classified as an oocyte-related activation failure, very similar in nature to that previously described and treated (Eldar-Geva *et al.*, 2003; Murase *et al.*, 2004; Heindryckx *et al.*, 2005, 2008). However, in our case, artificial oocyte activation failed to overcome the FF, thereby implicating an oocyte factor of a new, or at least more precise, nature within a broad categorization of 'activation failure'.

We can only speculate as to the exact underlying defect given that a single end-point, presumably the earliest arrest point, was analysed. It is unknown when the arrest exactly took place along the timeline of early fertilization events, that is, from oocyte activation to entry into interphase and progression through the first mitotic division. However, based on the absence of pronuclei at the fertilization check, and the presence of two spindles per oocyte, each characterized by broad anastral poles typical of meiotic spindles, it is likely that the failure occurred prior to entry into the interphase stage. Since oocytes were analysed after ICSI, we cannot conclude if the spindle defects resulted from sperm–oocyte interactions. Indeed, it is conceivable that multiple spindles were already present prior to ICSI. To address this, a subset of oocytes could be set aside for fixation following retrieval and/or PolScope imaging used to detect spindles non-invasively prior to ICSI (Rawe and Combelles, 2009). Because our current approach does not allow us to identify definitively the paternity of the meiotic spindles, the analysis of oocytes prior to ICSI would further prove useful, in at least confirming their maternal origins if both spindles were to be present prior to ICSI. However, if the two spindles were to exist only after ICSI, a more targeted analysis would help address whether the sperm chromatin was successfully incorporated in the oocyte. Sperm tails were not detected at the poles of any of the 21 analyzed oocytes and there was also no sign of prematurely condensed sperm chromatin. While these indicators are routinely used to detect the sperm contribution at fertilization (Asch *et al.*, 1995; Racowsky *et al.*, 1997; Miyara *et al.*, 2003) and there is a precedent for the occurrence of sperm ejection following ICSI (Flaherty *et al.*, 1995a; Schmiady *et al.*, 1996), a more thorough analysis is needed. It is relevant to note that ionophore treatment likely did not cause the defects described herein, given that spindle and chromosome abnormalities were comparable with or without the use of ionophore.

The two or more polar bodies observed per oocyte appeared to be true polar bodies rather than polar body fragments (Sousa and Tesarik, 1994; Flaherty *et al.*, 1998), although quantitative chromosomal analyses would be needed to confirm this with certainty. Interestingly, all oocytes possessed a single polar body prior to ICSI, indicating that additional polar body structures arose after injection. The presence of multiple polar bodies and spindles thus suggest that some aspects of spontaneous oocyte activation may have taken place; however, the programming sequence was clearly abnormal in all

oocytes examined, with failure to complete meiosis-II, or enter and progress normally through the complexities of activation towards interphase (Ducibella and Fissore, 2008). Regardless of the exact causes, the overriding deficiency appeared to lie in the oocyte.

The observed spindle structures possessed a set of gross abnormalities that may have arisen secondarily to cell cycle defects. Future and more targeted evaluations should focus on cytoplasmic deficiencies including cell cycle regulators such as M-phase promoting factor, c-MOS, Emi2, cdc20 and anaphase-promoting complex (Ducibella and Fissore, 2008; Horner and Wolfner, 2008). In frog and mouse oocytes, these molecular candidates all play a role in the transition of meiotic metaphase-II into mitotic interphase; furthermore, opportunities exist for spindle assembly checkpoint proteins to interact with some of these cell cycle modulators (Horner and Wolfner, 2008). Upstream of cell cycle regulation are calcium oscillations (Ducibella and Fissore, 2008), and it is possible that any deficiencies in these (in time, space and/or patterns) may fail to orchestrate the normal synchronization of oocyte activation events. The unique arrest point described herein thus merits further consideration in order to assign it a specific molecular defect. Only then may we be positioned to overcome the persistent M-phase environment of the ooplasm through fine manipulations, or calcium oscillations carefully altered in more specific and subtle ways than with ionomycin treatment.

Our study provides a framework for clinical care and diagnostic strategies. Analyses were performed without compromising the regular treatment of the couple as only discard oocyte material and semen samples were used. A treatment strategy (using calcium ionophore) was also attempted without efficacy thereby highlighting the need to devise other potential treatment options. Only when a more basic understanding of defects in FF is unraveled will we be positioned to test novel therapeutic avenues. Future efforts should be placed on identifying the cellular and molecular causes for any inherent and unexplained inability of morphologically normal oocytes to become fertilized (Gasca et al., 2008). Nevertheless, invaluable knowledge was acquired during our selected course of analysis, which enabled evidence-based counselling to our patient couple towards egg donation and fertilization with the husband's sperm, followed by the successful birth of healthy twins.

Authors' roles

Catherine M.H. Combelles performed the cytological analysis of oocytes and took the lead in the writing of the manuscript. Kazuto Morozumi participated in the morphological and functional assessments of the husband's sperm. Ryuzo Yanagimachi participated in the morphological assessment of the husband's sperm. Liben Zhu, MD, performed some of the mouse oocyte activation tests. Janis H. Fox, MD, oversaw the clinical management and monitoring of the patient couple throughout the course of their IVF treatment. Catherine Racowsky was responsible for the study design, overseeing the completion of the study, editing and finalizing of the manuscript.

Acknowledgements

We thank the entire team of clinical embryologists in the IVF programme at Brigham and Women's Hospital for their expertise and commitment to providing superb care of our patients' gametes and

embryos. We also extend our sincere appreciation to the patient couple for granting us permission to report our findings from their infertility treatment.

References

- Araki Y, Yoshizawa M, Abe H, Murase Y, Araki Y. Use of mouse oocytes to evaluate the ability of human sperm to activate oocytes after failure of activation by intracytoplasmic sperm injection. *Zygote* 2004;**12**:111–116.
- Asch R, Simerly C, Ord T, Ord VA, Schatten G. The stages at which human fertilization arrests: microtubule and chromosome configurations in inseminated oocytes which failed to complete fertilization and development in humans. *Hum Reprod* 1995;**10**:1897–1906.
- Barlow P, Englert Y, Puissant F, Lejeune B, Delvigne A, Van Rysselberge M, Leroy F. Fertilization failure in IVF: why and what next? *Hum Reprod* 1990;**5**:451–456.
- Bhattacharya S, Hamilton MP, Shaaban M, Khalaf Y, Seddler M, Ghobara T, Braude P, Kennedy R, Rutherford A, Hartshorne G et al. Conventional *in vitro* fertilisation versus intracytoplasmic sperm injection for the treatment of non-male-factor infertility: a randomised controlled trial. *Lancet* 2001;**357**:2075–2079.
- Cekleniak NA, Combelles CM, Ganz DA, Fung J, Albertini DF, Racowsky C. A novel system for *in vitro* maturation of human oocytes. *Fertil Steril* 2001;**75**:1185–1193.
- Combelles CM, Cekleniak NA, Racowsky C, Albertini DF. Assessment of nuclear and cytoplasmic maturation in *in vitro* matured human oocytes. *Hum Reprod* 2002;**17**:1006–1016.
- Combelles CM, Albertini DF, Racowsky C. Distinct microtubule and chromatin characteristics of human oocytes after failed *in vivo* and *in vitro* meiotic maturation. *Hum Reprod* 2003;**18**:2124–2130.
- Combelles CM, Fissore RA, Albertini DF, Racowsky C. *In vitro* maturation of human oocytes and cumulus cells using a co-culture three-dimensional collagen gel system. *Hum Reprod* 2005;**20**:1349–1358.
- Dozortsev D, De Sutter P, Dhont M. Behaviour of spermatozoa in human oocytes displaying no or one pronucleus after intracytoplasmic sperm injection. *Hum Reprod* 1994;**9**:2139–2144.
- Ducibella T, Fissore R. The roles of Ca(2+), downstream protein kinases, and oscillatory signaling in regulating fertilization and the activation of development. *Dev Biol* 2008;**315**:257–279.
- Eichenlaub-Ritter U, Stahl A, Luciani JM. The microtubular cytoskeleton and chromosomes of unfertilized human oocytes aged *in vitro*. *Hum Genet* 1988;**80**:259–264.
- Eichenlaub-Ritter U, Schmiady H, Kentenich H, Soewarto D. Recurrent failure in polar body formation and premature chromosome condensation in oocytes from a human patient: indicators of asynchrony in nuclear and cytoplasmic maturation. *Hum Reprod* 1995;**10**:2343–2349.
- Eldar-Geva T, Brooks B, Margalioth EJ, Zylber-Haran E, Gal M, Silber SJ. Successful pregnancy and delivery after calcium ionophore oocyte activation in a normozoospermic patient with previous repeated failed fertilization after intracytoplasmic sperm injection. *Fertil Steril* 2003;**79**(suppl. 3):1656–1658.
- Esfandiari N, Javed MH, Gotlieb L, Casper RF. Complete failed fertilization after intracytoplasmic sperm injection—analysis of 10 years' data. *Int J Fertil Womens Med* 2005;**50**:187–192.
- Ezra Y, Simon A, Laufer N. Defective oocytes: a new subgroup of unexplained infertility. *Fertil Steril* 1992;**58**:24–27.
- Flaherty SP, Payne D, Swann NJ, Matthews CD. Aetiology of failed and abnormal fertilization after intracytoplasmic sperm injection. *Hum Reprod* 1995a;**10**:2623–2629.

- Flaherty SP, Payne D, Swann NJ, Matthews CD. Assessment of fertilization failure and abnormal fertilization after intracytoplasmic sperm injection (ICSI). *Reprod Fertil Dev* 1995b;**7**:197–210.
- Flaherty SP, Payne D, Matthews CD. Fertilization failures and abnormal fertilization after intracytoplasmic sperm injection. *Hum Reprod* 1998;**13**(suppl. 1):155–164.
- Gasca S, Reyftmann L, Pellestor F, Reme T, Assou S, Anahory T, Dechaud H, Klein B, De Vos J, Hamamah S. Total fertilization failure and molecular abnormalities in metaphase II oocytes. *Reprod Biomed Online* 2008;**17**:772–781.
- Gook D, Osborn SM, Bourne H, Edgar DH, Speirs AL. Fluorescent study of chromatin and tubulin in apparently unfertilized human oocytes following ICSI. *Mol Hum Reprod* 1998;**4**:1130–1135.
- Heindryckx B, Van der Elst J, De Sutter P, Dhont M. Treatment option for sperm- or oocyte-related fertilization failure: assisted oocyte activation following diagnostic heterologous ICSI. *Hum Reprod* 2005;**20**:2237–2241.
- Heindryckx B, De Gheselle S, Gerris J, Dhont M, De Sutter P. Efficiency of assisted oocyte activation as a solution for failed intracytoplasmic sperm injection. *Reprod Biomed Online* 2008;**17**:662–668.
- Horner VL, Wolfner MF. Transitioning from egg to embryo: triggers and mechanisms of egg activation. *Dev Dyn* 2008;**237**:527–544.
- Kovacic B, Vlaisavljevic V. Configuration of maternal and paternal chromatin and pertaining microtubules in human oocytes failing to fertilize after intracytoplasmic sperm injection. *Mol Reprod Dev* 2000;**55**:197–204.
- Liu DY, Baker HW. Defective sperm-zona pellucida interaction: a major cause of failure of fertilization in clinical *in vitro* fertilization. *Hum Reprod* 2000;**15**:702–708.
- Liu J, Nagy Z, Joris H, Tournaye H, Smits J, Camus M, Devroey P, Van Steirteghem A. Analysis of 76 total fertilization failure cycles out of 2732 intracytoplasmic sperm injection cycles. *Hum Reprod* 1995;**10**:2630–2636.
- Mahutte NG, Arici A. Failed fertilization: is it predictable? *Curr Opin Obstet Gynecol* 2003;**15**:211–218.
- Miyara F, Aubriot FX, Glissant A, Nathan C, Douard S, Stanovici A, Herve F, Dumont-Hassan M, LeMeur A, Cohen-Bacrie P et al. Multiparameter analysis of human oocytes at metaphase II stage after IVF failure in non-male infertility. *Hum Reprod* 2003;**18**:1494–1503.
- Murase Y, Araki Y, Mizuno S, Kawaguchi C, Naito M, Yoshizawa M, Araki Y. Pregnancy following chemical activation of oocytes in a couple with repeated failure of fertilization using ICSI: case report. *Hum Reprod* 2004;**19**:1604–1607.
- Pickering SJ, Johnson MH, Braude PR, Houlston E. Cytoskeletal organization in fresh, aged and spontaneously activated human oocytes. *Hum Reprod* 1988;**3**:978–989.
- Racowsky C, Kaufman ML, Dermer RA, Homa ST, Gunnala S. Chromosomal analysis of meiotic stages of human oocytes matured *in vitro*: benefits of protease treatment before fixation. *Fertil Steril* 1992;**57**:1026–1033.
- Racowsky C, Prather AL, Johnson MK, Olvera SP, Gelety TJ. Prematurely condensed chromosomes and meiotic abnormalities in unfertilized human oocytes after ovarian stimulation with and without gonadotropin-releasing hormone agonist. *Fertil Steril* 1997;**67**:932–938.
- Rawe VY, Combelles CM. Human oocyte abnormalities: basic analyses and clinical applications. In: Carrell DT, Racowsky C, Schlegel PN, Van Voorhis BJ (eds). *Biennial Review of Infertility*. **1**, New York: Humana Press, 2009, 193–214.
- Rawe VY, Olmedo SB, Nodar FN, Doncel GD, Acosta AA, Vitullo AD. Cytoskeletal organization defects and abortive activation in human oocytes after IVF and ICSI failure. *Mol Hum Reprod* 2000;**6**:510–516.
- Rawe VY, Galaverna GD, Nodar FN, Brugo-Olmedo S, Vitullo AD. Cellular events during fertilization failure in humans. *Fertil Steril* 2001;**76**:375–376.
- Rawe VY, Brugo Olmedo S, Nodar FN, Vitullo AD. Microtubules and parental genome organisation during abnormal fertilisation in humans. *Zygote* 2002a;**10**:223–228.
- Rawe VY, Kopelman S, Nodar FN, Olmedo SB, Chillik CF. Pronuclear abnormalities and cytoskeletal organization during assisted fertilization in a patient with multifollicular ovarian response. *J Assist Reprod Genet* 2002b;**19**:152–157.
- Rosenbusch BE. Frequency and patterns of premature sperm chromosome condensation in oocytes failing to fertilize after intracytoplasmic sperm injection. *J Assist Reprod Genet* 2000;**17**:253–259.
- Rosenbusch BE, Schneider M. Recurrent failure of pronucleus formation after intracytoplasmic sperm injection. *Arch Gynecol Obstet* 1999;**262**:185–188.
- Schmiady H, Tandler-Schneider A, Kantenich H. Premature chromosome condensation of the sperm nucleus after intracytoplasmic sperm injection. *Hum Reprod* 1996;**11**:2239–2245.
- Sousa M, Tesarik J. Ultrastructural analysis of fertilization failure after intracytoplasmic sperm injection. *Hum Reprod* 1994;**9**:2374–2380.
- Swain JE, Pool TB. ART failure: oocyte contributions to unsuccessful fertilization. *Hum Reprod Update* 2008;**14**:431–446.
- Tesarik J, Sousa M. More than 90% fertilization rates after intracytoplasmic sperm injection and artificial induction of oocyte activation with calcium ionophore. *Fertil Steril* 1995;**63**:343–349.
- Van Wissen B, Eisenberg C, Debey P, Pennehouat G, Auger J, Bomsel-Helmreich O. *In vitro* DNA fluorescence after *in vitro* fertilization (IVF) failure. *J Assist Reprod Genet* 1992;**9**:564–571.
- Wall MB, Marks K, Smith TA, Gearon CM, Muggleton-Harris AL. Cytogenetic and fluorescent *in situ* hybridization chromosomal studies on *in vitro* fertilized and intracytoplasmic sperm injected 'failed-fertilized' human oocytes. *Hum Reprod* 1996;**11**:2230–2238.
- Yanagida K, Katayose H, Yazawa H, Kimura Y, Sato A, Yanagimachi H, Yanagimachi R. Successful fertilization and pregnancy following ICSI and electrical oocyte activation. *Hum Reprod* 1999;**14**:1307–1311.