

# The reliability of the histological diagnosis of endometritis in asymptomatic IVF cases: a multicenter observer study

J.C. Kasius<sup>1,\*</sup>, F.J.M. Broekmans<sup>1</sup>, D.M.D.S. Sie-Go<sup>2</sup>, C. Bourgain<sup>3</sup>, M.J.C. Eijkemans<sup>4</sup>, B.C. Fauser<sup>1</sup>, P. Devroey<sup>5</sup>, and H.M. Fatemi<sup>5</sup>

<sup>1</sup>Department of Reproductive Medicine and Gynaecology, University Medical Center Utrecht, 3584 CX Utrecht, The Netherlands

<sup>2</sup>Department of Pathology, University Medical Center Utrecht, 3584 CX Utrecht, The Netherlands <sup>3</sup>Department of Pathology, Academic Hospital at the Dutch-speaking Brussels Free University, 1090 Brussels, Belgium <sup>4</sup>Julius Center for Health Sciences and Primary Care, University Medical Center Utrecht, 3584 CG, Utrecht, The Netherlands <sup>5</sup>Center for Reproductive Medicine, Academic Hospital at the Dutch-speaking Brussels Free University, Brussels 1090, Belgium

\*Correspondence address. Fax: +31-88-7555433; E-mail: j.c.kasius@umcutrecht.nl

Submitted on February 13, 2011; resubmitted on July 12, 2011; accepted on August 17, 2011

**BACKGROUND:** Chronic endometritis is associated with abnormal uterine bleeding, recurrent abortion and infertility. It is a subtle condition, and therefore is difficult to diagnose. The diagnosis is ultimately based on the presence of plasma cells in the endometrial stroma on histopathological examination. Literature on the reproducibility of the diagnosis of chronic endometritis is lacking. Therefore, the aim of the current study was to assess the interobserver agreement of two pathologists in diagnosing chronic endometritis in asymptomatic, infertile patients.

**METHODS:** In the context of a randomized controlled trial, an endometrial biopsy was taken during a screening hysteroscopy prior to IVF. All endometrial samples were independently examined by two pathologist. The slides diagnosed with chronic endometritis were replenished with a random sample of the remaining slides up to a total of 100, then exchanged between the two pathologists and reassessed.

**RESULTS:** Of the 678 patients who underwent hysteroscopy, 19 patients were diagnosed with at least possible chronic endometritis (2.8%). Perfect agreement between the pathologists, before and after inclusion of 13 slides with additional immunohistochemistry staining, was found in 88 and 86% of reviews, respectively. The interobserver agreement was substantial, with kappa-values of 0.55 and 0.66, respectively.

**CONCLUSIONS:** The interobserver agreement in diagnosing chronic endometritis in asymptomatic infertile patients was found to be substantial. Although the diagnostic reliability is sufficient with the methods in the present study, the low prevalence and unknown clinical significance of endometritis warrants further study.

**Key words:** chronic endometritis / endometrial pathology / infertility / IVF / plasma cell

## Introduction

Chronic endometritis is a persistent inflammation of the inner lining of the uterine cavity. It is thought to be associated with abnormal uterine bleeding, recurrent abortion and infertility (Greenwood and Moran, 1981; Polisseni *et al.*, 2003; Romero *et al.*, 2004). In 12–46% of the hysteroscopy-guided endometrial biopsies in infertile patients, chronic endometritis was found to be present (Féghali *et al.*, 2003; Polisseni *et al.* 2003; Cicinelli *et al.*, 2005; Johnston-MacAnanny *et al.*, 2010). Detection and treatment has been reported to significantly improve pregnancy rates (Féghali *et al.*, 2003).

However, diagnosing chronic endometritis is known to be rather difficult. It is usually asymptomatic and hard to identify by most diagnostic tests. Although hysteroscopy enables direct visualization of the endometrial lining, variable results have been reported on its diagnostic accuracy in the detection of chronic endometritis (Polisseni *et al.*, 2003; Cicinelli *et al.*, 2005). Histological examination of an endometrial biopsy is known as the golden standard. Abnormal percentages of lymphocytes, leukocytic infiltration of both glands and stroma, and the presence of eosinophils or macrophages are the histological features described to be associated with chronic inflammation (Greenwood and Moran, 1981; Dechaud *et al.*, 1998;

Matteo et al., 2009; Adegboyega et al., 2010). Nevertheless, the presence of plasma cells in the endometrial stroma is the only histological criterion that is generally accepted for the diagnosis of chronic endometritis. The search for plasma cells can be interfered with or hampered by many conditions, such as mononuclear inflammatory cell infiltrates, stromal cell proliferation, the plasmacytoid appearance of stromal cells or a pronounced predecidual reaction in a late secretory endometrium (Greenwood and Moran, 1981; Crum et al., 1983; Adegboyega et al., 2010). As the presence of only one plasma cell is sufficient to diagnose chronic endometritis, histological detection obviously is time-consuming and difficult. Despite the fact that immunohistochemical markers that specifically stain plasma cells simplify the diagnostic decision, additional staining is not routinely provided in daily practice (Crum et al., 1983; Bayer-Garner et al., 2004).

The endometrial biopsy and histological examination has been widely used as a part of the infertility work-up in order to assess endometrium development during the luteal and/or the follicular phase. The accuracy as well as intra- and interobserver agreement of an endometrial biopsy for diagnosing luteal phase defects has been assessed thoroughly (Scott et al., 1993; Smith et al., 1995; Duggan et al., 2001; Myers et al., 2004). However in the literature, there is a lack of studies accessing the intra- or interobserver variation in diagnosing chronic endometritis. Therefore, the aim of this study was to assess the interobserver agreement in diagnosing chronic endometritis in asymptomatic, infertile patients.

## Materials and Methods

### Patients

In the period from June 2007 until September 2008, endometrial biopsies were obtained in the context of the TEA-trial ('Treatment Efficacy of unsuspected uterine Abnormalities') (Fatemi et al., 2010). The aim of this randomized controlled trial was to assess the treatment efficacy of intrauterine abnormalities on subsequent IVF or ICSI treatment (trial register number: NCT00830401). Patients under the age of 43 years indicated for fertility treatment at the University Medical Center Utrecht (UMC-U) or the Academic Hospital at the Dutch-speaking Brussels Free University (UZ-VUB) underwent office hysteroscopy prior to a first IVF/ICSI treatment cycle. Exclusion criteria were symptoms suggestive of intrauterine pathology, abnormalities at transvaginal ultrasound or a prior hysteroscopy examination. The Institutional Review Board of the two participating centers approved of the study, and informed consent was obtained.

### Hysteroscopy and endometrial biopsies

The hysteroscopy procedures were scheduled in the follicular phase of the menstrual cycle (Day 3–15), 1–3 months before starting the IVF/ICSI treatment. All procedures were performed in an outpatient setting, making use of a 5-mm outer-diameter continuous flow Bettocchi hysteroscope with 30° direction of view (Karl Storz Endoscopy, Stöpler Medical Instruments, Utrecht, The Netherlands and Olympus Belgium N.V., Aartselaar, Belgium). At the end of each procedure, an endometrial biopsy was obtained. At the UMC-U, a grasping forceps (Karl Storz, Endoscopie Nederland B.V., Nieuwegein, The Netherlands) was used to perform the biopsy from the posterior wall, halfway along the distance between the inner cervical os and the uterine fundus. At the UZ-VUB, a Pipelle de Cornier under local anesthesia was used to perform a blind biopsy (Laboratoire CCD, Paris, France).

## Histological examination

The endometrial biopsies were placed in a fixative of 4% phosphate-buffered formaldehyde and processed routinely into one or two hematoxylin and eosin (HE) stained slides per patient. At each research hospital, one pathologist, with a special interest and expertise in gynecological pathology, examined all endometrial samples obtained at that research hospital, independently from the other pathologist. Both pathologists were aware of the study design. However, the only clinical information provided was the day of the menstrual cycle on which the biopsy was taken and whether oral contraceptives had been used. A standard form was used to record the results of classifying the endometrial tissue samples, the presence or absence of plasma cells and other inflammatory cells (i.e. lymphocytes, neutrophilic granulocytes, histiocytes/macrophages and eosinophilic granulocytes) (Mazur and Kurman, 2005). An abnormal prevalence of different inflammatory cells, or lymphocytes destructing the endometrial tubuli were suggestive of chronic endometritis. However, the presence of plasma cells ultimately set the diagnosis of chronic endometritis. According to the findings during histopathology examination, the concluding diagnosis was reported by the pathologist. The diagnostic categories were as follows: no chronic endometritis, possibly chronic endometritis and evident chronic endometritis.

In cases where the diagnosis remained doubtful after the assessment of the HE-stained tissue sections, additional immunohistochemistry for the plasma cell marker CD138, alone or in combination with staining for the B-cell markers CD20 or CD79a, was performed. For CD138, the Clone B-B4 antibody (batch 605, Serotec) was used by applying a dilution of 1:1000. For plasma cells and B-lymphocytes CD79a, the Clone JCB117 antibody (batch 2791, DAKO) was used at a dilution of 1:200. For B-lymphocytes CD20, the Clone L26 antibody (batch 083, DAKO) was used at a dilution 1:400. For all antibodies, antigen retrieval in citrate buffer was applied and staining was done with the Bond-Max autostainer (Leica).

## Histological revision for observer agreement

The slides of patients diagnosed with possible or evident chronic endometritis, according to the first histological examination, were replenished by a sample of slides from the patients who were not diagnosed with chronic endometritis, up to a total of 50 per research center. The added patients without chronic endometritis were matched to the patients with chronic endometritis for the research hospital and the day of the menstrual cycle on which the hysteroscopy was performed and the biopsy was taken. The 50 slides of the replenished sample per research center were exchanged between both pathologists for a second evaluation. The histological revision was performed similarly to the original examination. Initially, only the HE stained slides were assessed. Thereafter, the pathologist could alter his or her opinion if additional immunohistochemistry appeared to be present.

## Statistical analysis

The pathologists' findings were statistically analyzed, using SPSS version 15.1 (SPSS Inc., Chicago, IL, USA) and R2.9.2 (R Development Core Team, 2009). The agreement between both pathologists on the slides of the histological reassessed sample was calculated. Their agreement on the diagnostic categories was evaluated for the findings based on HE stained slides alone or in combination with additional immunohistochemical staining. The interobserver agreement was calculated as the percentage of perfect agreement and corresponding weighted kappa-value. Kappa is a measure for agreement between observers corrected for the agreement expected to occur by chance ( $\kappa = (\text{Observed agreement} - \text{Agreement by Chance}) / (1 - \text{Agreement by chance})$ ). A kappa-value of <0.20 is interpreted as slight

agreement, a value between 0.21 and 0.40 as fair agreement, a value between 0.41 and 0.60 as moderate agreement, a value between 0.61 and 0.80 as substantial agreement and a value of 0.81–1.00 as almost perfect agreement (Landis and Koch, 1977). The weighted kappa takes into account the ordinary scale of categorical variables, so that different levels of agreement between categories contribute to the kappa-value (Fleiss and Cohen, 1973).

## Results

A total of 678 asymptomatic, infertile patients were included in the TEA trial and underwent office hysteroscopy (Fig. 1). The observed hysteroscopy findings are reported in Table I. The endometrial tissue samples of 606 patients could be adequately examined by the two pathologists (Table II). Histological examination failed in 11% of the participants, due to inability to complete the hysteroscopy procedure (1%), to perform the endometrial biopsy (3%) or to obtain sufficient endometrial tissue (7%).

Out of the population of 606 successfully biopsied patients, at first examination 587 were diagnosed as ‘no chronic endometritis’ (86.5%), 2 were diagnosed with ‘possible nonspecific chronic

endometritis” (0.3%) and 17 patients with ‘evident nonspecific chronic endometritis” (2.8%).

The slides of the 19 patients in whom possible or evident chronic endometritis was detected, added up with a matched selection out of the other slides up to a total of 50 per research hospital, were revised by the pathologist from the other research center. In this histological reassessed sample of 100 slides, the slides of 13 patients were additionally stained with immunochemical markers. Between the patients contributing to the analyzed histological revision sample ( $n = 100$ ) and those who did not ( $n = 506$ ), no significant differences were found regarding day of the cycle on which the hysteroscopy was performed, age, body mass index, duration of child wish, cause for the infertility or the rate of presence of an intrauterine abnormality at hysteroscopy.

**Table I Findings at hysteroscopy examination.**

Findings	Prevalence	%
Normal cavity	94	87.9
Abnormal cavity	13	12.1
Polyp	12	11.2
Myoma	1	0.9
Adhesion	0	0.0
Septum	2	1.9
Total	107	100

**Table II Patient characteristics of the sample of IVF/ICSI patients used for the histological revision.**

Variables	$n = 100$
Age	$32.98 \pm 3.96$
Duration of subfertility (years) <sup>a</sup>	$3.05 \pm 2.24$
Body mass index	$24.41 \pm 5.20$
TMC <sup>b</sup>	$65.67 \pm 120.32$
Day of menstrual cycle <sup>c</sup>	$9.66 \pm 3.74$
Infertility woman	
1. Primary	63 (63%)
2. Secondary	37 (37%)
Cause infertility	
1. Idiopathic	43 (43%)
2. Andrologic factor <sup>b</sup>	47 (47%)
3. Subfertile female <sup>d</sup>	10 (10%)

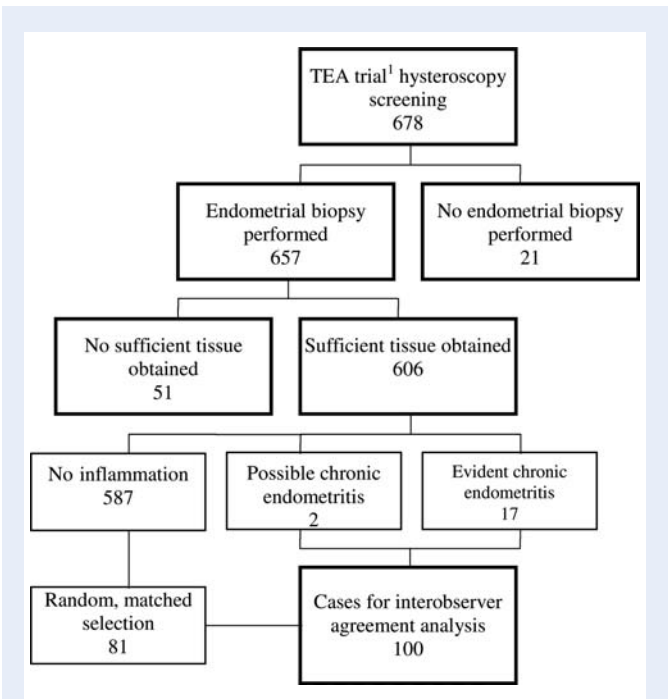
Values are expressed as mean  $\pm$  Standard deviation.

<sup>a</sup>Duration of attempt to become pregnant, in cases of secondary infertility calculated from the last ongoing pregnancy.

<sup>b</sup>Defined as TMC (total motile count, semen volume (ml) \* concentration spermatozoa (\*10<sup>9</sup>/ml) \* Grade A and B spermatozoa motility (%)) < 20  $\times$  10<sup>6</sup>.

<sup>c</sup>Day of the menstrual cycle on which the endometrial biopsy was obtained.

<sup>d</sup>Due to tubal pathology (incl. endometriosis Grade III and IV), anovulation or cervix factor.



**Figure 1** Flowchart illustrating the enriched sample method. Shown is the number of patients at each step towards the group of cases in which the endometrial samples were histologically examined by both pathologists and analyzed for the interobserver agreement. Cases initially diagnosed with chronic endometritis were replenished by a sample of randomly selected patients not initially diagnosed with chronic endometritis. Matching was performed for research center and day of menstrual cycle on which the endometrial biopsy was obtained. <sup>1</sup>The trial ‘Treatment Efficacy of unsuspected uterine Abnormalities’ on subsequent IVF or ICSI treatment (register number: NCT00830401).

Observer agreement in diagnosing chronic endometritis

The interobserver agreement was assessed in the sample of the slides of 100 patients, which were assessed by both pathologists. Based on solely the HE-stained tissue specimens, the pathologist at the UMC-U detected evident chronic endometritis in 12 patients (Table III), and in 1 case, the diagnosis remained doubtful. The pathologist at the UZ-VUB identified evident and possible chronic endometritis in 14 and 3 patients, respectively. They reported similar diagnostic categories in 88% of all 100 patients. The kappa-value for interobserver agreement was 0.546 (95% CI: 0.351–0.741), which represents moderate agreement.

Agreement analysis was also performed, after replacing the 13 HE stained slides by the corresponding slides with an additional immunohistochemistry staining. The pathologist at the UMC-U diagnosed evident and possible chronic endometritis in 14 and 5 patients (Table III). The findings of the pathologist at the UZ-VUB were 15 and 4, respectively. Perfect agreement on the diagnostic category appeared in 86%. The kappa for interobserver agreement when additional staining using immunohistochemical markers was included was 0.659 (95% CI: 0.463–0.855), which is interpreted as substantial agreement.

Discussion

Chronic endometritis generally is an asymptomatic condition and therefore difficult to diagnose. Although some subtle endometrial alterations have been described to be indicative for chronic endometritis, the diagnosis ultimately relies on the presence of plasma cells at histological examination (Greenwood and Moran, 1981; Dechaud et al., 1998; Matteo et al., 2009; Adegboyega et al., 2010). The current study demonstrates that the interobserver agreement in diagnosing nonspecific chronic endometritis in asymptomatic patients prior to a first IVF/ICSI treatment is substantial.

It is rather surprising that the interobserver agreement reached the level of ‘substantial’, while unequivocal and easy to determine criteria for the diagnosis nonspecific chronic endometritis are currently

absent. The diagnostic criterion for the identification of plasma cells with or without additional specific staining, as applied in the present study, may come with difficulties. Plasma cells generally are present in small amounts and may be mimicked or blurred by certain conditions of the endometrium or endometrial and inflammatory cells (Greenwood and Moran, 1981; Crum et al., 1983; Adegboyega et al., 2010). In the present study, endometrial tissue was obtained by a hysteroscopy-guided biopsy, which resulted in only a small sample of endometrium available for histological examination. In the UMC-U, a grasping forceps was used instead of a Pipelle de Cornier, which resulted in even smaller amounts of material in some cases. Moreover, the slides of the research hospitals also had a slightly different appearance due to variation in the routine processing of the endometrial tissue in the laboratories (difference in color and amount of tissue on one slide). Another limitation in the search for plasma cells may have been the absence of a standard additional immunohistochemistry staining on all endometrial biopsies. However, in daily practise, immunochemical markers are not routinely provided either. Taking into account all factors that could have hampered the diagnosis of chronic endometritis, the substantial reproducibility between observers is rather satisfying.

The results of the present study were based on a sample of 100 patients out of the whole study population in which a hysteroscopy-guided endometrial biopsy was obtained. The cases were selected on a specific criterion, namely the diagnosis of at least possible chronic endometritis by a pathologist, whereas the controls were randomly selected. This may have influenced the statistic assumption underlying the calculation of the kappa-values, though it seems not plausible to have occurred in this situation. Another consequence has been the difference in the prevalence of chronic endometritis between the sample and the whole study population. Thus, the use of an enriched sample instead of the whole patient population may have affected the study results. In our setting, it was the only feasible study design. Still, most processes of diagnosing based on operator judgment include elements of information on the likelihood of finding an abnormality and the specific question that has been put forward by, for instance, the clinician. As the pathologists were aware of these aspects, the approach chosen may not be really

Downloaded from https://academic.oup.com/humrep/article/27/1/153/713213 by guest on 11 April 2024

**Table III** Histological diagnosis by the pathologist of the UZ-VUB (horizontal) and the pathologist of the UMC-U (vertical) of the analyzed, revised group of 100 patients.

UZ-VUB	HE	UMC-U			UZ-VUB	CD	UMC-U		
		No <sup>a</sup>	Possibly <sup>a</sup>	Evident <sup>a</sup>			No <sup>a</sup>	Possibly <sup>a</sup>	Evident <sup>a</sup>
	No <sup>a</sup>	79	0	4		No <sup>a</sup>	76	1	4
	Possibly <sup>a</sup>	2	1	0		Possibly <sup>a</sup>	2	1	1
	Evident <sup>a</sup>	6	0	8		Evident <sup>a</sup>	3	3	9
Agreement		88%			Agreement		86%		
Weighted $\kappa$		0.546			Weighted $\kappa$		0.659		
95% CI		(0.351–0.741)			95% CI		(0.463–0.855)		

Also, the level of perfect interobserver agreement and corresponding kappa-values of diagnosing possible or evident chronic endometritis. Results split up for the findings based on the HE stained slides (on the left) and the findings if also the slides additionally stained with immunohistochemical markers (CD) are included (on the right).

<sup>a</sup>Referring to no chronic endometritis, possibly chronic endometritis and evident chronic endometritis.



remote from daily practice and thereby serves well as a model for reliability assessment.

Among the various endometrial abnormalities that can be enlightened by endometrial biopsy, the interobserver variation on hyperplasia and the luteal phase defect have been widely assessed. The WHO classification of endometrial hyperplasia of 1994 differentiates between simple and complex hyperplasia with or without atypia. The first study evaluating the agreement between six gynecologists on this WHO classification found a maximum kappa-value of 0.25 (95% CI 0.23–0.28) (Skov *et al.*, 1997). Two following studies, which used slightly different diagnostic categories, found moderate to substantial agreement between five pathologists, with kappa-values of 0.47–0.70 (Kendall *et al.*, 1998; Bergeron *et al.*, 1999).

In diagnosing luteal phase defects, the observer agreement was found to be somewhat disappointing. In 78 slides of infertile patients, the reproducibility of endometrial dating was assessed. The agreement among four pathologists on the dating categories 'proliferative', 'secretory', 'menstrual' or 'undateable' was substantial (maximum kappa-value: 0.70) (Duggan *et al.*, 2001). Furthermore, the observer agreement based on the diagnosis of 'in-phase' or 'out-of phase', defined as a 2-day difference between the histological date and the calculated luteal phase date based on the urinary LH surge, was evaluated. The reproducibility was shown to be moderate, with kappa-values between 0.4 and 0.6 in biopsies of 82 fertile and 83 infertile patients (Myers *et al.*, 2004).

To the best of our knowledge, reproducibility studies on diagnosing chronic endometritis are absent. In view of the results of the available observer studies on endometrial hyperplasia and luteal phase deficiencies, the reproducibility of diagnosing chronic endometritis is similar or slightly more promising.

The impact of chronic endometritis on fertility is controversial. The described prevalence varies widely and trials investigating the reproductive outcome of patients with chronic endometritis have reported contrary results (Czernobilsky, 1978). The prevalence of chronic endometritis has been described to be between 0.2 and 46% amongst infertile women (Wild *et al.*, 1986; Sahmay *et al.*, 1995; Féghali *et al.*, 2003; Polisseni *et al.* 2003; Cicinelli *et al.*, 2005; Johnston-MacAnanny *et al.*, 2010). Most recent studies have investigated a hysteroscopy-guided biopsy and found chronic endometritis in 12–46%. Those studies concern small patient populations, generally in which women had clinical symptoms justifying diagnostic hysteroscopy. Since the current study investigated a large group of consecutive women, without specific symptoms suggestive of uterine pathology, prior to starting a first IVF/ICSI cycle, the relatively low prevalence was to be expected. Regarding the impact of chronic endometritis on fertility, limited research is published. Recently published literature has shown that in 33 patients with two or more failed IVF attempts, the implantation rate of patients with chronic endometritis was significantly lower than controls without chronic endometritis, 12 versus 33% (Johnston-MacAnanny *et al.*, 2010). However, the ongoing pregnancy rate did not significantly differ between the patients of both groups. Moreover, in patients clinically suspected of pelvic inflammatory disease, the prevalence of infertility did not significantly differ between patients with or without chronic endometritis (Haggerty *et al.*, 2003).

The uncertainty on the impact of chronic endometritis on reproductive outcome also determines the importance of its detection.

Future research should be ideally in the form of a sufficiently powered prospective study in infertile women indicated for assisted reproductive technology in whom a standard biopsy is taken and the histopathology is related to subsequent outcome of treatment. Possibly, the inSIGHT trial, in which hysteroscopy with direct treatment of visible pathology is performed, with the addition of standard biopsy will contribute such data (trial register number NCT01242852). This multicenter trial has recently been started in The Netherlands. Moreover, a systematic review on individual patient data may allow for a larger data acquisition that will help assessing the exact significance of endometritis. Once the true impact is clarified by this future research, the usefulness of an endometrial biopsy in patients suffering from infertility can be determined. Nevertheless, the present interobserver agreement study has demonstrated that histological examination of an endometrial biopsy is a reproducible method for the diagnosis of chronic endometritis.

## Authors' roles

Authors J.C.K., F.J.M.B., B.C.F., P.D. and H.M.F. designed the initial study. F.J.M.B. and H.M.F. performed the hysteroscopy procedures. D.M.D.S.S.-G. and C.B. histologically examined all endometrial samples. J.C.K. coordinated, collected, analyzed and interpreted the data. F.J.M.B., D.M.D.S.S.-G., C.B., M.J.C.E. and H.M.F. participated in analyses and interpretation of the data. J.C.K., F.J.M.B. and H.M.F. wrote the paper. D.M.D.S.S.-G., C.B., M.J.C.E., B.C.F. and P.D. revised the manuscript. All authors approved the final draft. J.C.K. will act as guarantor for the paper.

## Conflict of interest

J.C.K., D.M.D.S.S.-G., C.B. and M.J.C.E. declare that they have no conflict of interest. F.J.M.B. is a member of the external advisory board for Ferring Pharmaceuticals, Hoofddorp, the Netherlands. He receives no monetary compensation. B.C.F. has received fees and grant support from the following companies (in alphabetic order): Andromed, Ardana, Ferring, Genovum, Glycotope, Merck Serono, Organon, Pantharei Bioscience, Philips, PregLem, Schering, Schering-Plough, Serono and Wyeth. P.D. has received fees and grant support from the following companies (in alphabetic order): Anecova, Besins, Ferring, Merck Serono, and Schering-Plough. H.M.F. is a member of the external advisory board for MSD/Organon Pharmaceuticals.

## References

- Adegboyega PA, Pei Y, McLarty J. Relationship between eosinophils and chronic endometritis. *Hum Pathol* 2010;**41**:33–37.
- Bayer-Garner IB, Nickell JA, Korourian S. Routine syndecan-1 immunohistochemistry aids in the diagnosis of chronic endometritis. *Arch Pathol Lab Med* 2004;**128**:1000–1003.
- Bergeron C, Nogales FF, Masseroli M, Abeler V, Duvillard P, Müller-Holzner E, Pickartz H, Wells M. A multicentric European study testing the reproducibility of the WHO classification of endometrial hyperplasia with a proposal of a simplified working classification for biopsy and curettage specimens. *Am J Surg Pathol* 1999;**23**:1102–1108.

- Cicinelli E, Resta L, Nicoletti R, Tartagni M, Marinaccio M, Bulletti C, Colafiglio G. Detection of chronic endometritis at fluid hysteroscopy. *J Minim Invasive Gynecol* 2005;**12**:514–518.
- Crum CP, Egawa K, Fenoglio CM, Richart RM. Chronic endometritis: the role of immunohistochemistry in the detection of plasma cells. *Am J Obstet Gynecol* 1983;**147**:812–815.
- Czernobilsky B. Endometritis and infertility. *Fertil Steril* 1978;**30**:119–130.
- Dechaud H, Maudelonde T, Daures JP, Rossi JF, Hedon B. Evaluation of endometrial inflammation by quantification of macrophages, T lymphocytes, and interleukin-1 and -6 in human endometrium. *J Assist Reprod Genet* 1998;**15**:612–618.
- Duggan MA, Brashert P, Ostor A, Scurry J, Billson V, Kneafsey P, Difrancesco L. The accuracy and interobserver reproducibility of endometrial dating. *Pathology* 2001;**33**:292–297.
- Fatemi HM, Kasius JC, Timmermans A, van DJ, Fauser BC, Devroey P, Broekmans FJ. Prevalence of unsuspected uterine cavity abnormalities diagnosed by office hysteroscopy prior to in vitro fertilization. *Hum Reprod* 2010;**25**:1959–1965.
- Féghali J, Bakar J, Mayenga JM, Ségard L, Hamou J, Driguez P, Belaisch-Allart J. Systematic hysteroscopy prior to in vitro fertilization. *Gynecol Obstet Fertil* 2003;**31**:127–131.
- Fleiss JL, Cohen J. The equivalence of weighted kappa and the intraclass correlation coefficient as measures of reliability. *Educ Psychol Meas* 1973;**33**:613–619.
- Greenwood SM, Moran JJ. Chronic endometritis: morphologic and clinical observations. *Obstet Gynecol* 1981;**58**:176–184.
- Haggerty CL, Ness RB, Amortegui A, Hendrix SL, Hillier SL, Holley RL, Peipert J, Randall H, Sondheimer SJ, Soper DE et al. Endometritis does not predict reproductive morbidity after pelvic inflammatory disease. *Am J Obstet Gynecol* 2003;**188**:141–148.
- Johnston-MacAnanny EB, Hartnett J, Engmann LL, Nulsen JC, Sanders MM, Benadiva CA. Chronic endometritis is a frequent finding in women with recurrent implantation failure after in vitro fertilization. *Fertil Steril* 2010;**93**:437–441.
- Kendall BS, Ronnett BM, Isacson C, Cho KR, Hedrick L, Diener-West M, Kurman RJ. Reproducibility of the diagnosis of endometrial hyperplasia, atypical hyperplasia, and well-differentiated carcinoma. *Am J Surg Pathol* 1998;**22**:1012–1019.
- Landis JR, Koch GG. The measurement of observer agreement for categorical data. *Biometrics* 1977;**33**:159–174.
- Matteo M, Cicinelli E, Greco P, Massenzio F, Baldini D, Falagario T, Rosenberg P, Castellana L, Specchia G, Liso A. Abnormal pattern of lymphocyte subpopulations in the endometrium of infertile women with chronic endometritis. *Am J Reprod Immunol* 2009;**61**:322–329.
- Mazur MT, Kurman RJ. *Diagnosis of Endometrial Biopsies and Curettings*. New York: Springer science + Business Media. Inc., 2005.
- Myers ER, Silva S, Barnhart K, Groben PA, Richardson MS, Robboy SJ, Leppert P, Coutifaris C. Interobserver and intraobserver variability in the histological dating of the endometrium in fertile and infertile women. *Fertil Steril* 2004;**82**:1278–1282.
- Polisseni F, Bambirra EA, Camargos AF. Detection of chronic endometritis by diagnostic hysteroscopy in asymptomatic infertile patients. *Gynecol Obstet Invest* 2003;**55**:205–210.
- R Development Core Team. *R: A Language and Environment for Statistical Computing*. Vienna, Austria: R Foundation for Statistical Computing, 2009. ISBN 3-900051-07-0, URL <http://www.R-project.org>.
- Romero R, Espinoza J, Mazor M. Can endometrial infection/inflammation explain implantation failure, spontaneous abortion, and preterm birth after in vitro fertilization? *Fertil Steril* 2004;**82**:799–804.
- Sahmay S, Oral E, Saridogan E, Senturk L, Atasu T. Endometrial biopsy findings in infertility: analysis of 12,949 cases. *Int J Fertil Menopausal Stud* 1995;**40**:316–321.
- Scott RT, Snyder RR, Bagnall JW, Reed KD, Adair CF, Hensley SD. Evaluation of the impact of intraobserver variability on endometrial dating and the diagnosis of luteal phase defects. *Fertil Steril* 1993;**60**:652–657.
- Skov BG, Broholm H, Engel U, Franzmann MB, Nielsen AL, Lauritzen AF, Skov T. Comparison of the reproducibility of the WHO classifications of 1975 and 1994 of endometrial hyperplasia. *Int J Gynecol Pathol* 1997;**16**:33–37.
- Smith S, Hosid S, Scott L. Endometrial biopsy dating. Interobserver variation and its impact on clinical practice. *J Reprod Med* 1995;**40**:1–3.
- Wild RA, Sanfilippo JS, Toledo AA. Endometrial biopsy in the infertility investigation. The experience at two institutions. *J Reprod Med* 1986;**31**:954–957.