

Safety and usefulness of cryopreservation of ovarian tissue to preserve fertility: a 12-year retrospective analysis

R. Imbert^{1,7}, F. Moffa^{1,8}, S. Tsepelidis^{1,9}, P. Simon², A. Delbaere^{1,3},
F. Devreker^{1,3}, J. Dechene³, A. Ferster⁴, I. Veys⁵, M. Fastrez⁶, Y. Englert^{1,3},
and I. Demeestere^{1,3,*}

¹Department of Obstetrics and Gynaecology, Fertility Clinic, Université Libre de Bruxelles, Erasme Hospital, Brussels, Belgium ²Unit of Gynaecology, Erasme Hospital, Université Libre de Bruxelles, Brussels, Belgium ³Research Laboratory on Human Reproduction, Faculty of Medicine, Université Libre de Bruxelles, Campus Erasme, Brussels, Belgium ⁴Department of Hematology-Oncology, Hôpital Universitaire des Enfants Reine Fabiola (HUDERF), Brussels, Belgium ⁵Department of Breast and Gynecological Surgery, Institut Jules Bordet, Brussels, Belgium ⁶Department of Obstetrics and Gynecology, CHU St Pierre, Brussels, Belgium ⁷Present address: Department of Gynecology-Andrology, Cliniques Universitaires Saint-Luc, Avenue Hippocrate, 10, Brussels 1200, Belgium ⁸Present address: Instituto Markez, Assisted Reproduction Service, Manuel Girona 33, MASIA, Barcelona 08034, Spain ⁹Present address: Nivelles Hospital Rue Samiette, Nivelles 1400, Belgium

*Correspondence address. Research Laboratory on Human Reproduction, Campus Erasme CP636, 808 route de Lennik, 1070 Bruxelles, Belgium. Tel: +32-2-5556358; E-mail: idemeest@ulb.ac.be

Submitted on February 5, 2014; resubmitted on May 13, 2014; accepted on May 27, 2014

STUDY QUESTION: Do the benefits of ovarian tissue cryopreservation outweigh the risks for patients seeking to preserve fertility before gonadotoxic treatment in various indications?

SUMMARY ANSWER: In >90% of the patients undergoing cryopreservation of ovarian tissue, oncological treatment was associated with a reduced ovarian reserve and in 30% of patients, premature ovarian failure (POF) occurred within 5 years.

WHAT IS KNOWN ALREADY: Ovarian tissue cryopreservation is an effective fertility preservation option, especially for pre-pubertal patients and patients who have a short time between diagnosis of a disease and gonadotoxic treatment.

STUDY DESIGN, SETTING, DURATION: This study retrospectively analysed ovarian function and fertility recovery rates, as well as ovarian tissue characteristics, of patients who underwent ovarian tissue cryopreservation at Erasme Hospital between 1999 and 2011.

PARTICIPANTS/MATERIALS, SETTINGS, METHODS: A total of 225 patients referred from 15 Belgian oncological units underwent cryopreservation of ovarian tissue before gonadotoxic therapy for malignant or benign diseases. There were 28 patients (12.4%) who died during follow-up due to recurrence of disease. One severe adverse event occurred during anaesthesia for ovarian tissue collection, leading to the death of the patient. Ovarian function and fertility outcomes were available for 114 patients including 13 girls who were pre-pubertal at the time of the procedure. Eight patients had undergone ovarian tissue transplantation in order to restore their fertility after remission of the disease.

MAIN RESULTS AND THE ROLE OF CHANCE: Breast cancer and haematological disease were the most frequent indications for ovarian tissue cryopreservation. Overall, 90% of post-pubertal patients were diagnosed with poor ovarian reserve (AMH < 0.5 ng/ml) after a mean of 50 months of follow-up (11–125 months), including 30% with POF (FSH > 40 IU/ml). Breast cancer patients had a lower rate of POF than did post-pubertal patients with haematological diseases (11 versus 34.5%, respectively), despite the older age (mean 31 versus 23.5 years old, respectively) of the breast cancer patients. Ovarian function returned in 71 post-pubertal patients without the need for grafts of cryopreserved tissue. Spontaneous pregnancies were reported for 33 of them, leading to 34 live births. Among the 13 pre-pubertal patients who reached pubertal age during the follow-up, 10 had POF. Eight patients received cryopreserved ovarian grafts to reverse POF and three of them have already become pregnant.

LIMITATIONS, REASONS FOR CAUTION: This study is a retrospective analysis. The cohort was not compared with a control group of patients who did not undergo the procedure.

WIDER IMPLICATIONS OF THE FINDINGS: After careful evaluation of the surgical risks, ovarian tissue cryopreservation can be proposed as an efficient option to preserve the fertility of children and young adults facing gonadotoxic therapies. However, alternative procedures such as oocyte or embryo cryopreservation should be considered as first options especially for older patients or if there is high risk of neoplastic cells within the ovaries.

STUDY FUNDING/COMPETING INTEREST: This study was supported by the Télévie, FNRS-FRSM and Fondation Belge contre le cancer. There are no competing interests to report.

Key words: ovarian tissue / cryopreservation / cancer / fertility preservation / *in vitro* maturation

Introduction

More than 10% of all cancers are diagnosed in young patients, often before they have completed their families (<http://www.kankerregister.org>). Malignancies occurring at a young age in females mainly include breast cancer, haematological diseases, colorectal carcinoma, thyroid carcinoma, carcinoma of the cervix and melanoma (Coccia et al., 2012). As the incidence of cancer is on the rise throughout the young population, so is the long-term survival rate (Steliarova-Foucher et al., 2004; Verdecchia et al., 2007). In Belgium, >80% of cancer patients aged between 15 and 49 at diagnosis now survive after 5 years of follow-up (<http://www.kankerregister.org>). Thus, offering an optimal quality of life to these young cancer survivors, including the preservation of their future fertility, has become a major goal for oncological facilities (Lee et al., 2006). Some 70% of young female cancer patients stated they were concerned about fertility at the time of diagnosis and 50% wanted to have children after treatment (Letourneau et al., 2012). However, chemotherapy agents and radiotherapy often have gonadotoxic effects that render a patient infertile (Levine et al., 2010). Premature ovarian failure (POF) occurs at a varying risk from low (<20%) to high (>80%) according to the treatment regimen and doses and the patient's age (Lee et al., 2006). Guidelines have been published by oncological and reproductive societies advocating that young patients treated with gonadotoxic regimens should be systematically informed about this infertility risk and about options to preserve their fertility (Lee et al., 2006; Committee et al., 2012; Loren et al., 2013).

One of those options receiving much attention is cryopreservation of ovarian tissue. Ovarian tissue harvesting can be performed without delaying oncological therapy and it is even feasible after chemotherapy has begun (Demeestere et al., 2003). It is the only option for pre-pubertal patients, and can be associated with *in vitro* maturation of immature oocytes. The procedure has been available as an experimental protocol for >15 years and the first pregnancies after orthotopic transplantation of cryopreserved ovarian tissue were reported in the 2000s. At least 26 babies have now been born after the grafting of cryopreserved ovarian tissue at the orthotopic site (Donnez et al., 2004; Meirow et al., 2005; Demeestere et al., 2006, 2007). The overall pregnancy rate after transplantation of ovarian tissue has been estimated at between 11 and 30% (Demeestere et al., 2009; Donnez et al., 2013). The first clinical pregnancy after ovarian tissue transplantation at the heterotopic site was recently reported (Stern et al., 2013).

While the success of ovarian tissue transplantation in restoring ovarian function and fertility is established, several issues are still under investigation. One of the main concerns is that grafting ovarian tissue that may harbour neoplastic cells could cause a recurrence of the disease (Meirow et al., 2008; Bockstaele et al., 2012; Bastings et al., 2013;

Dolmans et al., 2013a,b). Furthermore, the factors influencing how long ovaries will continue to function after grafting remain uncertain (Anderson et al., 2008; Demeestere et al., 2009). Analysis of the clinical outcomes of such patients as well as the characteristics and viability of cryopreserved ovarian tissue are essential to identify optimal patients and improve the procedure and its efficacy.

The objective of this study is to retrospectively evaluate the risk and benefits ratio of ovarian tissue cryopreservation by analysing ovarian function and fertility outcomes in a cohort of patients who underwent the procedure. The characteristics of the ovarian tissue analysed at the time of the procedure are also described in order to evaluate safety and efficacy issues.

Materials and Methods

Study population

Approval was obtained from Erasme Hospital's ethical committee for both cryopreservation and transplantation of ovarian tissue procedures. Patients under 36 years of age, with no evidence of ovarian insufficiency, negative serological tests and high or moderate risk of POF were eligible for ovarian tissue cryopreservation procedure (Demeestere et al., 2003, 2006, 2007). All patients and/or parents or legal guardians signed an informed consent form.

From March 1999 through June 2011, 225 patients underwent cryopreservation of ovarian tissue for fertility preservation. Ovarian function and fertility outcomes were available for 114 female patients including 13 pre-pubertal girls who were followed up for their endocrine status by the oncologist or the endocrinologist.

Cryopreservation of ovarian tissue

The ovarian tissue biopsies or unilateral ovariectomies were carried out at Erasme Hospital or in one of the 15 collaborating Belgian centres. Unilateral ovariectomy was usually proposed only for pre-pubertal patients, women having a major risk of POF or in the case of ovariectomy for other surgical indications. Tissues were transported to the IVF laboratory in Leibovitz L-15 medium (Life Technologies, Merelbeke, Belgium) at 4°C within 2 h of collection and immediately processed. The medulla was gently removed, the cortex was cut into small fragments ($\approx 5 \times 5 \times 1-2$ mm) and incubated for 30 min in a cryoprotectant solution containing Leibovitz medium supplemented with 1.5 M dimethyl sulfoxide (DMSO), 0.1 M sucrose (both from Sigma Aldrich, Diegem, Belgium) and 10% patient's serum or 1% human serum albumin at 4°C on a roller (serum was replaced by HAS 20% in 2004, Croix Rouge, Belgium) (Demeestere et al., 2007). Each fragment was then placed in a 2 ml cryovial containing the cryoprotectant medium and processed using the slow freezing protocol (Kryo 360, Planer, UK) with the following programme: start at 4°C, $-2^\circ\text{C}/\text{min}$ to -7°C (manual seeding), $-0.3^\circ\text{C}/\text{min}$ to -40°C , $-10^\circ\text{C}/\text{min}$ to -140°C and then plunged into liquid nitrogen (Demeestere et al., 2003).

Since 2004, one fragment of fresh ovarian tissue was always fixed for further histological analysis. Follicular density per mm² was evaluated as well as the presence of neoplastic cells using specific immunomarkers.

Thawing and ovarian tissue transplantation procedure

At least one fragment of ovarian tissue from all cancer patients was thawed before the transplantation procedure to confirm the absence of malignant cells. Fragments of ovarian tissue were thawed using a rapid protocol (2 min at room temperature then immersed 2 min in water at ~25°C) and washed for 5 min in four different Leibovitz L-15 medium solutions supplemented with reduced concentrations of cryoprotectants (DMSO 1, 0.5 and two with 0 M) (Demeestere et al., 2006, 2007). The transplantation procedure was performed in two steps (1-week interval laparoscopy). During the first laparoscopy, peritoneal and ovarian sites were prepared in order to induce neovascularization before grafting as previously described (Demeestere et al., 2009). During the second laparoscopy, the ovarian tissue was grafted preferentially at the orthotopic site. Additional ovarian tissue fragments were transplanted to other peritoneal (ovarian bursa) and/or subcutaneous (using abdominal trocar incision) sites.

Ovarian function and fertility follow-up

Patient follow-up was carried out by the gynaecologist of Erasme Hospital's oncofertility unit or by the patient's referring physician. Data regarding the hormonal profile (AMH, FSH, E2), the presence of menstruation and the fertility outcome of patients were collected. Serum levels of FSH and E2 were analysed by the hospital's departments of clinical biochemistry.

Serum AMH level was analysed by enzyme immunoassay using commercially available kits (AMH GenII Elisa; Beckman, Coulter, Brea, CA, USA) at the Chemistry Laboratory of Erasme. POF was defined as FSH ≥40 IU/l and amenorrhoea. Ovarian function was considered restored when patients

reported spontaneous menstruation and/or spontaneous pregnancy and/or FSH <40 IU/l.

Statistics

Statistical analyses were performed using SPSS 22 (IBM). Means were tested for homogeneity of variance and compared using one-way ANOVA followed by the Tukey honest significant difference test if equal variance between groups was assumed. Chi-square tests were used to compare the frequencies. The significance level was defined as *P* < 0.05

Results

Population and procedure

There were 300 patients counselled for ovarian tissue cryopreservation from March 1999 through June 2011. Of these, 75 patients did not undergo the procedure for various reasons. For these patients who were not eligible for ovarian tissue cryopreservation after counselling, the main reason was that the patient or her parents refused (34%), while 7 (9%) had surgical contraindications (Fig. 1).

Among the 225 patients who underwent ovarian tissue cryopreservation, 45 (20%) were minors aged between 0.8 and 17, including 27 who were pre-pubertal. Breast cancer was the most frequent diagnosis in the post-pubertal population, while haematological disease requiring haematopoietic stem cell transplantation (HSCT) was the primary diagnosis in the pre-pubertal patients (Fig. 2).

Beginning in 2004, fresh ovarian tissue sample was examined to assess their follicular count and the presence of neoplastic cells. A total of 181 fresh ovarian tissue samples were analysed (Table I). Follicular density was extremely variable from one biopsy to the next but was correlated

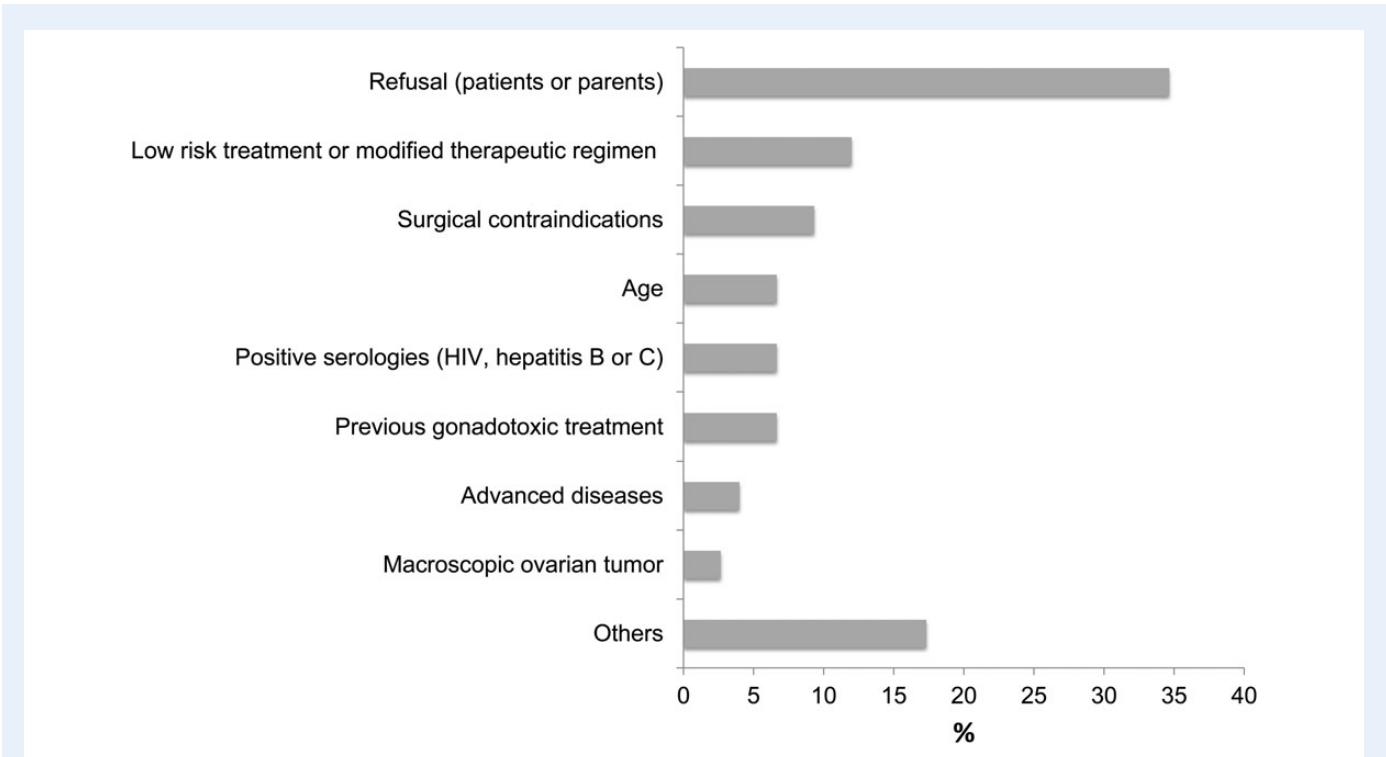


Figure 1 Proportions of patients who refused the cryopreservation of ovarian tissue procedure or who were not eligible after counselling.

with age ($P < 0.001$), being lowest among the older patients (breast cancer patients) (Table I). No difference in the follicular density was observed whether patients had received chemotherapy or not (Table I). For 15 patients, no follicles were found in fresh biopsies even though 7 of these patients subsequently reported spontaneous restoration of their menstruation cycles.

The mean number of cryopreserved fragments differed according to diagnosis; patients with borderline ovarian tumour had the fewest fragments, while patients with leukaemia had the most (Table I). More fragments were obtained after ovariectomy (25.4 ± 10.1) than after ovarian biopsies (17.9 ± 7.1) ($P = 0.005$). Tumour cells were found in biopsies from two patients with borderline ovarian tumours (Table I).

Adverse events

Twenty-five post-pubertal and three pre-pubertal patients died during follow-up due to disease recurrence (Fig. 3A and B). In addition, one 26-year-old patient died after ovarian tissue collection. She had systemic lupus erythematosus and had been admitted to emergency for acute glomerulonephritis, hypertension and anaemia. One month later, after recovering from this, she underwent laparoscopy to retrieve ovarian tissue for cryopreservation and was then scheduled for immunosuppressive

treatment including alkylating agents. Immediately after extubation in the operating room, buccal and nasal haemorrhage occurred. The patient was then intubated, transfused and transferred to the intensive care unit, diagnosed with acute respiratory distress syndrome (ARDS). She died 7 days later from sepsis.

Ovarian function and fertility outcomes

Of the 225 patients who underwent the procedure, data on the ovarian function and/or fertility outcomes were available for 114 patients who completed at least 1 year of follow-up (Fig. 3).

In the post-pubertal population, ovarian function analyses were collected in 101 patients (Fig. 3A). Before ovarian cryopreservation, all patients had an FSH levels <40 IU/l. AMH values were available in 37 patients before the cryopreservation procedure. Four patients (10.8%) had an AMH level <0.5 ng/ml. Two of these four patients had received chemotherapy. After oncological treatment, mean FSH levels significantly increased over time compared with initial levels ($P < 0.001$), while mean AMH levels significantly decreased ($P < 0.001$) (Fig. 4). Of the 101 patients, 71 experienced restored ovarian function, while 30 patients had POF (30.7%). The mean age was not significantly different between the 'restored ovarian function' and 'POF' groups (27.0 ± 6 versus

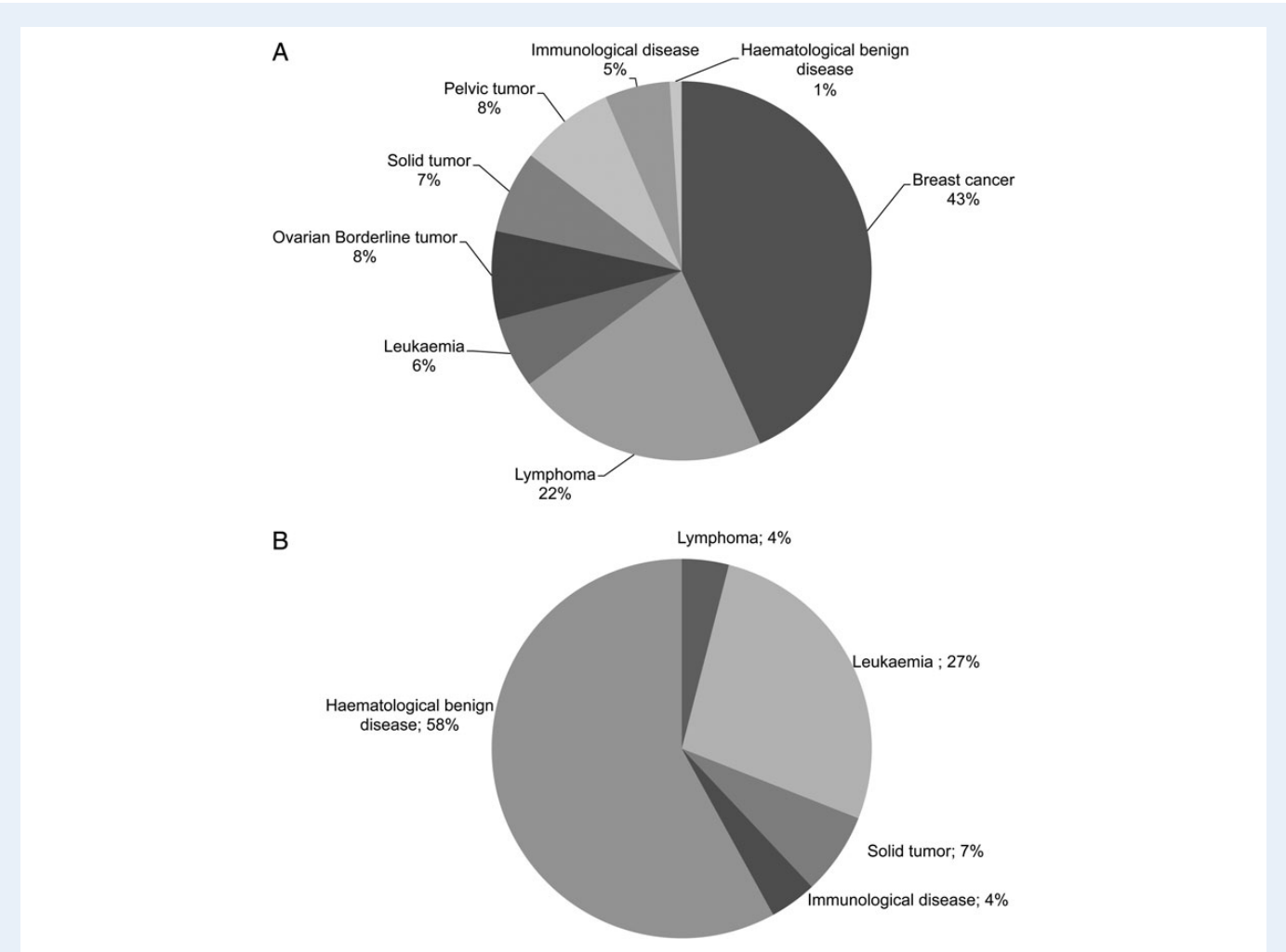


Figure 2 Indications for cryopreservation of ovarian tissue in post-pubertal (A) and pre-pubertal (B) populations.

Table 1 Characteristic of the ovarian tissue according to the diseases.

	All	Malignant					Benign		
		Breast cancer	Lymphoma	Leukemia	Borderline ovarian tumour	Solid tumour	Pelvic tumour	Autoimmune diseases	Haematologic benign
Clinical characteristics									
Number of patients	181	75	36	16	9	11	12	12	10
Mean age \pm SD (range)	24.6 \pm 8.4 (0–37)	30.5 \pm 3.5 ^a (20–37)	23.1 \pm 5.7 ^{a,b} (11–34)	15.6 \pm 7.4 ^{a,b,c,e} (4–35)	28.2 \pm 5.7 ^d (19–36)	19.6 \pm 8 ^{a,d} (3–30)	25.8 \pm 5.1 ^e (16–32)	20.3 \pm 8.4 ^{a,c,d} (0–34)	8 \pm 3.3 ^{a,b,d,e} (4–14)
Number of ovariectomy (%)	29/181 (16.02)	0/75 (0)	3/36 (8.33)	10/16 (62.5)	3/9 (33.3)	2/11 (18.2)	0/12 (0)	1/12 (8.3)	10/10 (100)
Number of patients treated by chemotherapy before cryopreservation procedure (%)	27/181 (14.9)	4/75 (5.3)	5/36 (13.9)	11/16 (68.8)	0/9 (0)	1/11 (9.1)	1/12 (8.3)	5/12 (41.7)	0/10 (0)
Ovarian tissue characteristics									
Mean fragments \pm SEM (range)	19.1 \pm 0.6 (5–59)	18.3 \pm 0.88 ^a (5–59)	19.6 \pm 1.32 (6–39)	26 \pm 2.26 ^{a,b,d,e} (12–41)	13.2 \pm 1.62 ^{b,c} (7–21)	18 \pm 1.76 (8–32)	15.9 \pm 1.94 ^e (7–32)	17 \pm 1.75 ^d (10–31)	24 \pm 3.16 ^c (8–40)
Follicle density per mm ² (without prior chemotherapy)									
<i>n</i>	154	71	31	5	7	10	10	7	10
Mean (SEM)	5.83 \pm 0.43	4.06 \pm 0.39	6.55 \pm 0.80	7.4 \pm 3.41	5.5 \pm 1.6	10.1 \pm 2.38	5.85 \pm 2.9	7.86 \pm 2.33	9.9 \pm 2.19
Range	0–30	0–14	0–18.5	3–21	0–10	2.5–28	0–30	1.5–20	0–19
Follicle density per mm ² (with prior chemotherapy)									
<i>n</i>	27	4	5	11	-	1	1	5	0
Mean (SEM)	5.70 \pm 0.78	5.13 \pm 1.71	5.1 \pm 2.05	7.0 \pm 1.5		5	6	4 \pm 1.1	
Range	0–14	2.5–10	0–12.5	0–14				0–6	
Presence of neoplastic cells									
No (%)	179 (98.9)	75 (100)	36 (100)	16 (100)	6 (75)	11 (100)	11 (100)	12 (100)	10 (100)
Yes (%)	2 (1.1)				2 (25)				

Different letters within the same row showed significant different results ($P < 0.05$).

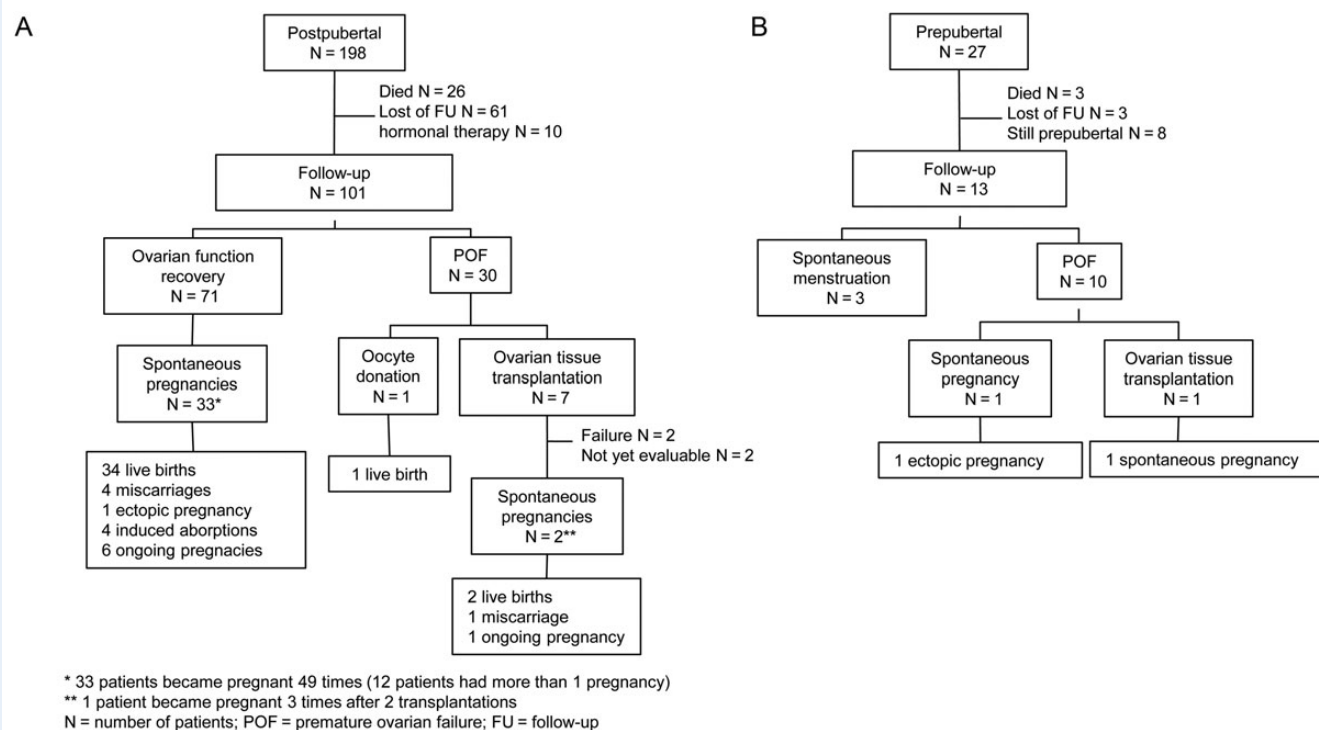


Figure 3 Flowchart of the ovarian function and fertility outcomes of post-pubertal (A) and pre-pubertal (B) patients who underwent ovarian tissue cryopreservation procedures.

26.8 ± 6 years, respectively, $P = 0.807$). One-third of patients had unilateral ovariectomy in the POF group compared with only 11% in the restored ovarian function group. However, unilateral ovariectomy was usually performed when high gonadotoxic treatments were programmed. Nine patients in the POF group had bilateral ovariectomy for borderline tumour or breast cancer. Despite the older mean age of breast cancer patients, those who had not been bilaterally ovariectomized had a higher ovarian function recovery rate than patients with haematological diseases (89 versus 65.5%, respectively). However, the majority of patients with restored ovarian function had poor ovarian reserve: 85% had an AMH level <0.5 ng/ml after 2 years of follow-up and an FSH > 20 IU/l was reported in 8 of these 60 patients. A total of 49 spontaneous pregnancies in 33 patients were reported after a mean follow-up of 50.3 months (18–148 months) in the restored ovarian function group, leading to 34 live births (Fig. 3A). Two pregnancies were obtained after ovulation induction.

Data from 13 pre-pubertal patients at the time of the cryopreservation procedure were available for the ovarian function analysis (Fig. 3B). For 10 of them (76.9%), now aged 11–27, POF was confirmed during follow-up (nine by hormonal tests and one by a physician's report). One patient treated prior to puberty was diagnosed with POF but regained irregular menstrual cycles at 25 years of age and experienced an ectopic pregnancy. Three patients, aged between 15 and 19, matured normally and progressed through menarche.

Ovarian tissue transplantation

Eight patients underwent ovarian tissue transplantation for fertility restoration after diagnosis of POF; one of these had been pre-pubertal at

the time of the cryopreservation procedure. Two of these patients had <5 months of follow-up and were excluded from the follow-up analysis, leaving six patients. Five experienced restored menstrual function at an average of 5 months after transplantation (Table II). All five patients had FSH levels return to premenopausal values, while AMH levels remained low. Five spontaneous pregnancies occurred. One patient became pregnant three times and delivered twice after two transplant procedures (Table II, Patient 1) (Demeestere et al., 2006, 2007, 2010). This patient continued to menstruate 7 years after the first graft. Another patient became pregnant, 9 months after transplantation (Table II, Patient 5). One patient was 13 years old at the time of cryopreservation and faced POF after HSCT. Ten years after ovarian tissue cryopreservation, she underwent ovarian tissue transplantation and regained normal ovarian function. She became pregnant 34 months after grafting (Table II, Patient 4). To our knowledge, this is the first case of fertility restoration in a girl that froze tissue before the onset of menarche. One patient failed to conceive before experiencing ovarian failure again 1 year later (Table II, Patient 2) and one never regained ovarian function (Table II, Patient 3). One patient recently regained ovarian function after transplantation and experienced her first menstrual cycle (Table II, Patient 6). None of these patients have seen their diseases return.

Discussion

Within 5 years after oncological treatment, >90% of women in our study had a low AMH level (<0.5 ng/ml), and around 30% experienced POF (FSH > 40 IU/l). Similarly, Dillon et al. (2013a,b) found that only 9% of reproductive-age cancer survivors had AMH levels that returned to

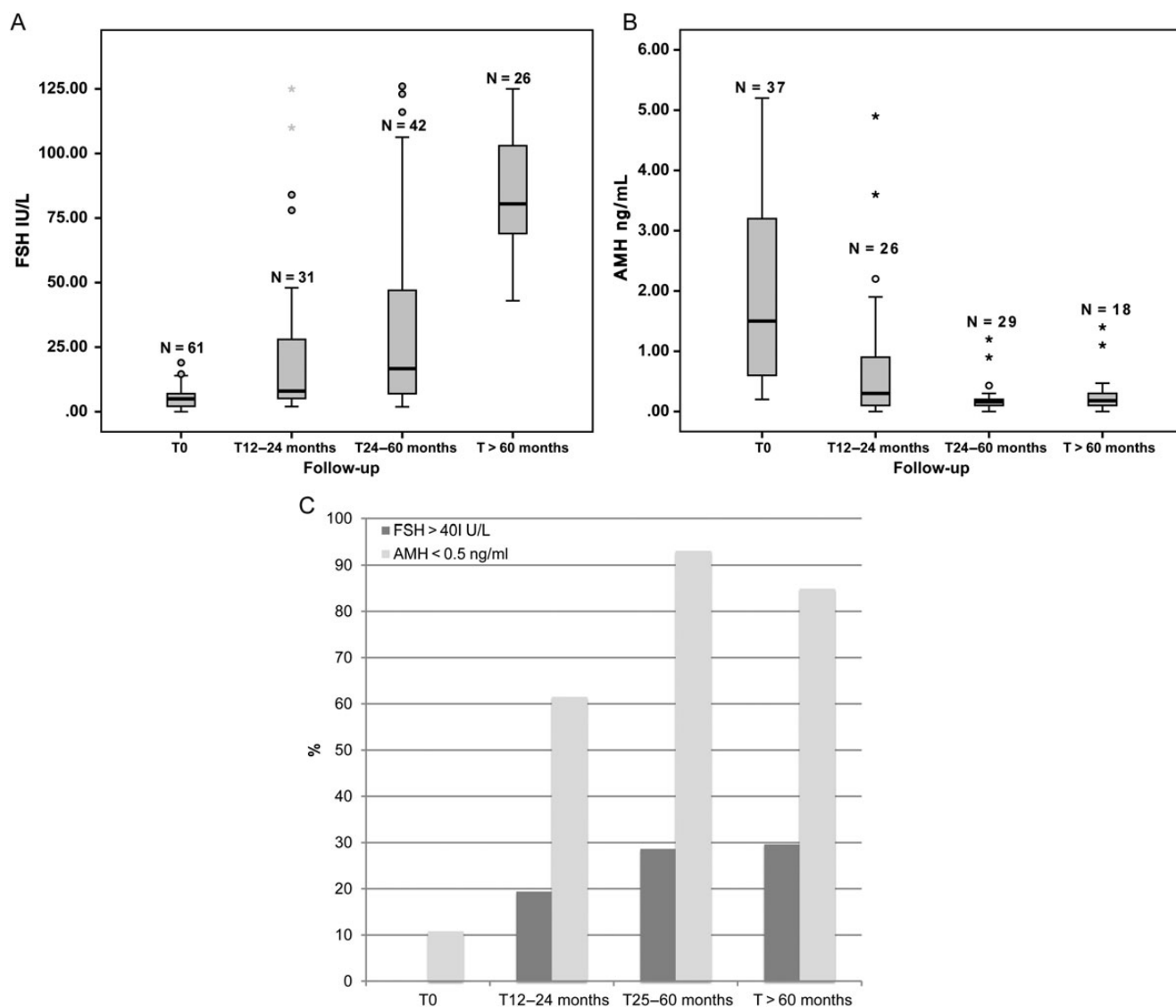


Figure 4 Hormonal profiles at the time of ovarian tissue cryopreservation (T0) and after 12–24 months (T12–24 months), 25–60 months (T25–60 months) and >60 months (T > 60 months) of follow-up in the cohort of post-pubertal patients. **(A)** and **(B)** represent the median FSH and AMH median values, respectively, with upper/lower quartile. **(C)** The percentage of patients with FSH > 40 IU/L and AMH < 0.5 ng/mL at different follow-up times.

pretreatment baseline levels. In a large population-based study from the Finnish Cancer registry, the probability of parenthood following early onset cancer was reduced by ~50% in patients compared with their siblings (Madanat *et al.*, 2008). In our cohort, both POF and infertility rates will probably increase over time. Although 34 patients had spontaneous pregnancies during the follow-up, we can extrapolate that about half of the patients may achieve later pregnancies as a benefit of the fertility preservation procedure. In pre-pubertal patients, only those with gonadotoxic regimens known to induce a high risk of POF were considered for ovarian tissue cryopreservation (Brougham and Wallace, 2005). More than 80% of our pre-pubertal patients received a regimen for HSCT, which explains the high rate of ovarian insufficiency observed after treatment. Previous studies showed that among childhood cancer survivors with regular menstruation and normal basal FSH, antral follicular count and ovarian volume were significantly lower than for the age-

matched control (Dillon *et al.*, 2013a,b; Larsen *et al.*, 2003). In our cohort, three of the pre-pubertal patients spontaneously progressed into puberty, but may become infertile due to poor ovarian reserve. Therefore, the infertility rate could climb higher when the younger members of our cohort attempt to start their families.

Ovarian tissue cryopreservation is a common option to preserve fertility, especially for premenarcheal patients and patients who have only a short delay before starting chemotherapy. The inclusion criteria vary from one centre to the another, especially in the age limit. Some guidelines provide for cryopreservation of ovarian tissue in females younger than 30 years old with a high risk of ovarian failure after gonadotoxic treatment as well as for those who had already received chemotherapy (Abir *et al.*, 2008; Anderson *et al.*, 2008). Others extend the option to women up to 39 years of age with a greater range of indications (Oktay and Oktem, 2009; Dolmans *et al.*, 2013a,b). We adopted an

Table II Ovarian function and fertility outcomes after cryopreserved ovarian tissue transplantation.

Patients	Type of the diseases	Age at tissue cryopreservation (years)	Age at transplantation (years)	Transplantation sites	Time to restoration of menstrual cycle (months)	Menstrual cycle length (days)	Duration of ovarian function (years)	Time to pregnancy (months)	Number of pregnancies	Number of live births
1	Hodgkin lymphoma ^a	24	29	O, P, SC	5	17–25	1.5	8	1	0
2	Breast cancer	35	30	O, SC	2	24–28	5	4 and 33	2	2
3	Colorectal cancer	31	39	O, SC	5	Irregular	1	Failure	–	–
4	Sickle cell disease	13	36	O, SC	Not restored	–	0	Failure	–	–
5	Non-Hodgkin lymphoma	23	22	O, SC	5	21–30	Ongoing	34	1	Ongoing
6	Hodgkin lymphoma	26	26	O, P	5	28–30	Ongoing	9	1	Ongoing
			29	O, P	5	?	Ongoing	–	–	–

O, ovarian site; SC, subcutaneous site; P, peritoneal site.
^aThe patient who underwent two transplantation procedures.

upper age limit of 35 years old in compliance with many centres and in consideration of the relatively low probability of pregnancy after ovarian tissue transplantation in older patients. In our cohort, the two patients who failed to regain fertility after transplantation were 35 and 31 years old at the time of ovarian tissue cryopreservation. In contrast, the four patients who completely recovered ovarian function were <30 years old at the time of the procedure, and three of them have already became pregnant (Demeestere et al., 2006, 2007). In the literature, the large majority of pregnancies reported after ovarian tissue graft have also been obtained in women younger than 30 years old at the time of the cryopreservation procedure (Donnez et al., 2011, 2013).

Based on the encouraging results obtained after transplantation in high-risk patients, the findings have indicated that ovarian tissue cryopreservation should be extended to patients whose treatments have a medium risk of ovarian insufficiency. That population would include women diagnosed with breast cancer. However, the breast cancer patients in our study had a higher mean age at diagnosis compared with others in the cohort. They also had lower follicular density in the cortex. As a consequence, the expected success rate of ovarian tissue transplantation is likely to be lower than for patients with other disease and treatment indicators. Despite the fact that no malignant cells were found in the ovarian tissue of breast cancer patients at the time of cryopreservation, the risk of reintroducing neoplastic cells during ovarian tissue transplantation must be investigated further (Bockstaele et al., 2012; Oktay, 2001). For breast cancer patients, protocols using gonadotrophin and letrozole have recently been developed in order to collect and vitrify mature oocytes without increasing estradiol levels (Azim et al., 2008). At present, we have adopted this protocol as the first option to assist breast cancer patients in preserving their fertility by cryopreserving oocytes or embryos before chemotherapy.

Immature oocytes can also be collected from antral follicles in ovarian tissue at the time of the cryopreservation procedure, matured *in vitro* and then cryopreserved (Revel et al., 2009; Fasano et al., 2011). For half of the patients who underwent ovarian tissue cryopreservation, this combined procedure offers an additional chance to become pregnant. The first live birth resulting from a cryopreserved embryo obtained from *in vitro*-matured oocytes collected after oophorectomy was recently reported (Prasath et al., 2014). Although further analyses should evaluate the competence of these oocytes, these results are encouraging. A systematic search for these immature oocytes during ovarian tissue cryopreservation, even in pre-pubertal girls, is warranted.

In our cohort, one death occurred following laparoscopy due to a severe anaesthesia complication. To our knowledge, this is the first report of death in a patient undergoing ovarian tissue cryopreservation procedure. Dolmans et al. (2013a) evaluated the safety of cryopreservation of ovarian tissue in a large cohort of 476 patients and did not report any severe adverse events during laparoscopy. In another cohort of 92 patients who completed a questionnaire > 18 months after removal of an entire ovary for cryopreservation, 27% reported complications from the operation. Three of them underwent additional surgeries for cutaneous infections or bladder lesions, and for one, laparoscopy was converted to laparotomy (Rosendahl et al., 2008). Other complications were considered minor (discomfort, pain, bleeding from cicatrices). These data highlight the need to carefully consider the health of patients before recommending the invasive procedure. In the case of acute progression of connective autoimmune diseases or malignancies severely affecting health status, the laparoscopy could be cancelled or postponed.

In conclusion, cryopreservation of ovarian tissue is an efficient option to preserve fertility in young patients facing or undergoing gonadotoxic therapies. Although this technique is usually well tolerated, it is invasive and severe adverse events have been reported. Therefore, it should be proposed only after careful evaluation of the surgical risks. As age is an important factor in success after transplantation, the efficiency of the procedure is optimal for children and young adults. Other options, such as vitrification of oocytes or embryos, may be a better choice for older patients or in patients with a high risk of neoplastic cells within the ovaries.

Acknowledgements

We would like to thank all the oncologists and gynaecologists from centres which refer patients to the fertility preservation programme at Erasme Hospital and therefore have contributed to this work: Bordet Institute (Brussels), CHU St Pierre (Brussels), Centre Hospitalier Interrégional Edith Cavell (Brussels and Braine L'Alleud), Iris Sud Hospital (Ixelles and Molière, Brussels), Clinique St Vincent (Rocourt), Clinique St Joseph (Liège), CHU Charleroi (Charleroi), CHU Ambroise Pare (Mons), CHU Tivoli (Tivoli), CHU Brugmann (Brussels), St Jean Clinic (Brussels), Chwapi Notre Dame (Tournai), HUDERF (Brussels).

Authors' roles

I.D. is responsible for the fertility preservation programme at Erasme Hospital and designed the study. R.I. and I.D. interpreted the data, performed the statistical analysis and wrote the manuscript. D.J. centralized and verified all the data and participated in the interpretation. F.M., S.T., A.D. and F.D. were involved in the fertility preservation programme and managed the patients at Erasme Hospital. A.F., I.V. and M.F. referred the patients and collected the data in the main collaborating centres. P.S. performed the ovarian tissue transplantation procedure. Y.E., A.D. and F.D. participated in critical discussions and decisions regarding the fertility preservation programme and reviewed the manuscript. All authors approved the final version of the manuscript.

Funding

This study was supported by the Télévie, the FRSM and the 'Fondation Belge contre le cancer'. I.D. is an FNRS Research Associate.

Conflict of interest

None declared.

References

- Abir R, Ben-Haroush A, Felz C, Okon E, Raanani H, Orvieto R, Nitke S, Fisch B. Selection of patients before and after anticancer treatment for ovarian cryopreservation. *Hum Reprod* 2008;**23**:869–877.
- Anderson RA, Wallace WH, Baird DT. Ovarian cryopreservation for fertility preservation: indications and outcomes. *Reproduction* 2008;**136**:681–689.
- Azim AA, Costantini-Ferrando M, Oktay K. Safety of fertility preservation by ovarian stimulation with letrozole and gonadotropins in patients with breast cancer: a prospective controlled study. *J Clin Oncol* 2008;**26**:2630–2635.
- Bastings L, Beerendonk CC, Westphal JR, Massuger LF, Kaal SE, van Leeuwen FE, Braat DD, Peek R. Autotransplantation of cryopreserved ovarian tissue in cancer survivors and the risk of reintroducing malignancy: a systematic review. *Hum Reprod Update* 2013;**19**:483–506.
- Bockstaele L, Tsepelidis S, Dechene J, Englert Y, Demeestere I. Safety of ovarian tissue autotransplantation for cancer patients. *Obstet Gynecol Int* 2012;**2012**:495142.
- Brougham MF, Wallace WH. Subfertility in children and young people treated for solid and haematological malignancies. *Br J Haematol* 2005;**131**:143–155.
- Coccia PF, Altman J, Bhatia S, Borinstein SC, Flynn J, George S, Goldsby R, Hayashi R, Huang MS, Johnson RH et al. Adolescent and young adult oncology. Clinical practice guidelines in oncology. *J Natl Compr Canc Netw* 2012;**10**:1112–1150.
- Committee IP, Kim SS, Donnez J, Barri P, Pellicer A, Patrizio P, Rosenwaks Z, Nagy P, Falcone T, Andersen C et al. Recommendations for fertility preservation in patients with lymphoma, leukemia, and breast cancer. *J Assist Reprod Genet* 2012;**29**:465–468.
- Demeestere I, Simon P, Englert Y, Delbaere A. Preliminary experience of ovarian tissue cryopreservation procedure: alternatives, perspectives and feasibility. *Reprod Biomed Online* 2003;**7**:572–579.
- Demeestere I, Simon P, Buxant F, Robin V, Fernandez SA, Centner J, Delbaere A, Englert Y. Ovarian function and spontaneous pregnancy after combined heterotopic and orthotopic cryopreserved ovarian tissue transplantation in a patient previously treated with bone marrow transplantation: case report. *Hum Reprod* 2006;**21**:2010–2014.
- Demeestere I, Simon P, Emiliani S, Delbaere A, Englert Y. Fertility preservation: successful transplantation of cryopreserved ovarian tissue in a young patient previously treated for Hodgkin's disease. *Oncologist* 2007;**12**:1437–1442.
- Demeestere I, Simon P, Emiliani S, Delbaere A, Englert Y. Orthotopic and heterotopic ovarian tissue transplantation. *Hum Reprod Update* 2009;**15**:649–665.
- Demeestere I, Simon P, Moffa F, Delbaere A, Englert Y. Birth of a second healthy girl more than 3 years after cryopreserved ovarian graft. *Hum Reprod* 2010;**25**:1590–1591.
- Dillon KE, Sammel MD, Ginsberg JP, Lechtenberg L, Prewitt M, Gracia CR. Pregnancy after cancer: results from a prospective cohort study of cancer survivors. *Pediatr Blood Cancer* 2013a;**60**:2001–2006.
- Dillon KE, Sammel MD, Prewitt M, Ginsberg JP, Walker D, Mersereau JE, Gosiengfiao Y, Gracia CR. Pretreatment antimüllerian hormone levels determine rate of posttherapy ovarian reserve recovery: acute changes in ovarian reserve during and after chemotherapy. *Fertil Steril* 2013b;**99**:477–483.
- Dolmans MM, Jadoul P, Gilliaux S, Amorim CA, Luyckx V, Squifflet J, Donnez J, Van Langendonck A. A review of 15 years of ovarian tissue bank activities. *J Assist Reprod Genet* 2013a;**30**:305–314.
- Dolmans MM, Luyckx V, Donnez J, Andersen CY, Greve T. Risk of transferring malignant cells with transplanted frozen-thawed ovarian tissue. *Fertil Steril* 2013b;**99**:1514–1522.
- Donnez J, Dolmans MM, Demylle D, Jadoul P, Pirard C, Squifflet J, Martinez-Madrid B, van Langendonck A. Livebirth after orthotopic transplantation of cryopreserved ovarian tissue. *Lancet* 2004;**364**:1405–1410.
- Donnez J, Silber S, Andersen CY, Demeestere I, Piver P, Meirow D, Pellicer A, Dolmans MM. Children born after autotransplantation of cryopreserved ovarian tissue. A review of 13 live births. *Ann Med* 2011;**43**:437–450.
- Donnez J, Dolmans MM, Pellicer A, Diaz-Garcia C, Sanchez Serrano M, Schmidt KT, Ernst E, Luyckx V, Andersen CY. Restoration of ovarian activity and pregnancy after transplantation of cryopreserved ovarian tissue: a review of 60 cases of reimplantation. *Fertil Steril* 2013;**99**:1503–1513.

- Fasano G, Moffa F, Dechene J, Englert Y, Demeestere I. Vitrication of in vitro matured oocytes collected from antral follicles at the time of ovarian tissue cryopreservation. *Reprod Biol Endocrinol* 2011;**9**:150.
- Larsen EC, Muller J, Schmiegelow K, Reznitzer C, Andersen AN. Reduced ovarian function in long-term survivors of radiation- and chemotherapy-treated childhood cancer. *J Clin Endocrinol Metab* 2003;**88**:5307–5314.
- Lee SJ, Schover LR, Partridge AH, Patrizio P, Wallace WH, Hagerty K, Beck LN, Brennan LV, Oktay K. American 'Society of Clinical Oncology recommendations on fertility preservation in cancer patients. *J Clin Oncol* 2006;**24**:2917–2931.
- Letourneau JM, Melisko ME, Cedars MI, Rosen MP. A changing perspective: improving access to fertility preservation. *Nat Rev Clin Oncol* 2011;**8**:56–60.
- Levine J, Canada A, Stern CJ. Fertility preservation in adolescents and young adults with cancer. *J Clin Oncol* 2010;**28**:4831–4841.
- Loren AW, Mangu PB, Beck LN, Brennan L, Magdalinski AJ, Partridge AH, Quinn G, Wallace WH, Oktay K, American Society of Clinical Oncology. Fertility preservation for patients with cancer: American society of clinical oncology clinical practice guideline update. *J Clin Oncol* 2013;**31**:2500–2510.
- Madanat LM, Malila N, Dyba T, Hakulinen T, Sankila R, Boice JD Jr, Lahteenmaki PM. Probability of parenthood after early onset cancer: a population-based study. *Int J Cancer* 2008;**123**:2891–2898.
- Meirow D, Levron J, Eldar-Geva T, Hardan I, Fridman E, Zalel Y, Schiff E, Dor J. Pregnancy after transplantation of cryopreserved ovarian tissue in a patient with ovarian failure after chemotherapy. *N Engl J Med* 2005;**353**:318–321.
- Meirow D, Hardan I, Dor J, Fridman E, Elizur S, Ra'anani H, Slyusarevsky E, Amariglio N, Schiff E, Rechavi G et al. Searching for evidence of disease and malignant cell contamination in ovarian tissue stored from hematologic cancer patients. *Hum Reprod* 2008;**23**:1007–1013.
- Oktay K. Ovarian tissue cryopreservation and transplantation: preliminary findings and implications for cancer patients. *Hum Reprod Update* 2001;**7**:526–534.
- Oktay K, Oktay O. Fertility preservation medicine: a new field in the care of young cancer survivors. *Pediatr Blood Cancer* 2009;**53**:267–273.
- Prasath EB, Chan ML, Wong WH, Lim CJ, Tharmalingam MD, Hendricks M, Loh SF, Chia YN. First pregnancy and live birth resulting from cryopreserved embryos obtained from in vitro matured oocytes after oophorectomy in an ovarian cancer patient. *Hum Reprod* 2014;**29**:276–278.
- Revel A, Revel-Vilk S, Aizenman E, Porat-Katz A, Safran A, Ben-Meir A, Weintraub M, Shapira M, Achache H, Laufer N. At what age can human oocytes be obtained? *Fertil Steril* 2009;**92**:458–463.
- Rosendahl M, Andersen CY, Ernst E, Westergaard LG, Rasmussen PE, Loft A, Andersen AN. Ovarian function after removal of an entire ovary for cryopreservation of pieces of cortex prior to gonadotoxic treatment: a follow-up study. *Hum Reprod* 2008;**23**:2475–2483.
- Steliarova-Foucher E, Stiller C, Kaatsch P, Berrino F, Coebergh JW, Lacour B, Parkin M. Geographical patterns and time trends of cancer incidence and survival among children and adolescents in Europe since the 1970s (the ACCISproject): an epidemiological study. *Lancet* 2004;**364**:2097–2105.
- Stern CJ, Gook D, Hale LG, Agresta F, Oldham J, Rozen G, Jobling T. First reported clinical pregnancy following heterotopic grafting of cryopreserved ovarian tissue in a woman after a bilateral oophorectomy. *Hum Reprod* 2013;**28**:2996–2999.
- Verdecchia A, Francisci S, Brenner H, Gatta G, Micheli A, Mangone L, Kunkler I, Group E-W. Recent cancer survival in Europe: a 2000–02 period analysis of EURO-CARE-4 data. *Lancet Oncol* 2007;**8**:784–796.