Human Reproduction, Vol.30, No.9 pp. 2107–2109, 2015
Advanced Access publication on June 9, 2015 doi:10.1093/humrep/dev128

human reproduction

CASE REPORT *Infertility*

Live birth after autograft of ovarian tissue cryopreserved during childhood

Isabelle Demeestere[1,2,*], Philippe Simon[3], Laurence Dedeken[4], Federica Moffa[1,6], Sophie Tsépélidis[1,2,7], Cecile Brachet[5], Anne Delbaere[1,2], Fabienne Devreker[1,5], and Alina Ferster[4]

[1]Research Laboratory on Human Reproduction, Faculty of Medicine, Université Libre de Bruxelles (ULB), Campus Erasme, CP636, 808 route de Lennik, 1070 Brussels, Belgium [2]Fertility Clinic, Department of Obstetrics and Gynaecology, Erasme Hospital, Université Libre de Bruxelles, 1070 Brussels, Belgium [3]Gynecology Clinic, Department of Obstetrics and Gynaecology, Erasme Hospital, Université Libre de Bruxelles (ULB), 1070 Brussels, Belgium [4]Department of Hematology-Oncology, Hôpital Universitaire des Enfants Reine Fabiola (HUDERF), 1020 Brussels, Belgium [5]Department of Endocrinology, Hôpital Universitaire des Enfants Reine Fabiola (HUDERF), 1020 Brussels, Belgium
[6]Present address: Instituto Marqués, Assisted Reproduction Service, Manuel Girona 33, MASIA, 08034 Barcelona, Spain
[7]Present address: Nivelles Hospital, Rue Samiette, 1400 Nivelles, Belgium

*Correspondence address. Tel: +32-2-5556358; E-mail: idemeest@ulb.ac.be

Submitted on April 3, 2015; resubmitted on May 7, 2015; accepted on May 14, 2015

ABSTRACT: Ovarian insufficiency is a major long-term adverse event, following the administration of a myeloablative conditioning regimen, and occurring in >80% of children and adolescents receiving such treatment for malignant or non-malignant disease. Cryopreservation of ovarian tissue is currently offered to preserve the fertility of these young patients. At least 35 live births have been reported after transplantation of cryopreserved ovarian tissue in adult patients, but the procedure remains unproven for ovarian tissue harvested at a prepubertal or pubertal age. We report here the first live birth after autograft of cryopreserved ovarian tissue in a woman with primary ovarian failure after a myeloablative conditioning regimen as part of a hematopoietic stem cell transplantation performed for homozygous sickle-cell anemia at age 14 years. This first report of successful fertility restoration after the graft of ovarian tissue cryopreserved before menarche offers reassuring evidence for the feasibility of the procedure when performed during childhood.

Key words: fertility preservation / childhood / ovarian tissue cryopreservation / transplantation / live birth

Introduction

Long-term survivors of hematological diseases diagnosed during childhood are increasing in number, owing to improvements in treatments and supportive care. Hematopoietic stem cell transplantation (HSCT) is now offered as curative therapy for a wide variety of malignant and non-malignant hematological disorders. However, the risk of subfertility and premature ovarian insufficiency (POI) following HSCT exceeds 80% in childhood cancer survivors, including teenagers (Brougham and Wallace, 2005; Borgmann-Staudt *et al.*, 2012). For prepubertal female patients who face a high risk of treatment-induced POI, the only option available to preserve fertility is the cryopreservation of ovarian tissue (Demeestere *et al.*, 2009; Imbert *et al.*, 2014; Wallace *et al.*, 2014). However, the successful outcome of this approach has been demonstrated only in patients who were adults at the time of their diagnosis (Stoop *et al.*, 2014; Donnez *et al.*, 2015). As yet, the efficacy of the procedure in children has remained unproven.

Case Report

We report the case of a woman aged 27 years, who was born in the Republic of Congo and diagnosed with sickle-cell anemia at the age of 5, having experienced several episodes of fever and severe anemia. Having emigrated to Belgium at the age of 11, her initial medical work-up revealed abnormal blood flow velocities on a transcranial Doppler echography. Subsequent treatment with hydroxyurea was initiated. Due to her significant disease severity, curative therapy with HSCT, made possible with the availability of a matched sibling donor, was required. The option of ovarian tissue cryopreservation to preserve fertility was offered and explained to both parents and child prior to the initiation of the conditioning regimen. The parents signed the written consent form. She had reportedly started puberty (breast development) at around 10 years of age and her hormonal profile showed follicle-stimulating hormone [FSH], luteinizing hormone [LH] and estradiol levels of 6.3, 2.9 IU/l and 28 pg/ml, respectively, in October 2000. At the time of the ovarian tissue cryopreservation procedure, she was

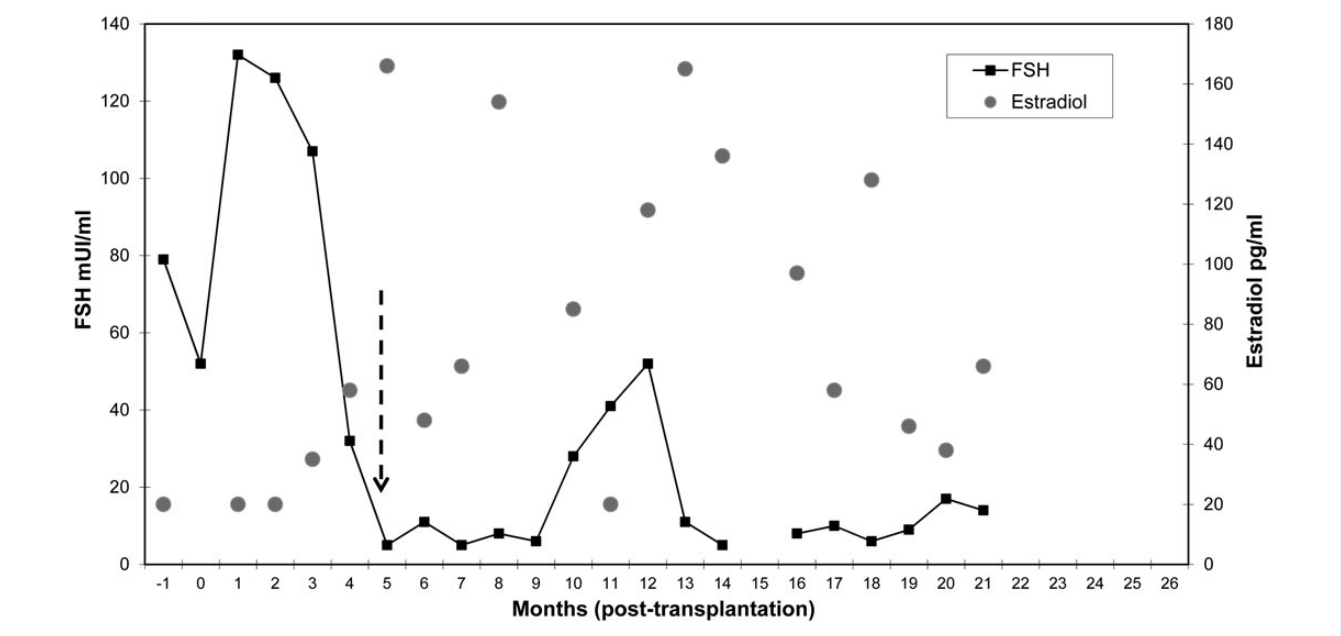

Figure 1 FSH and estradiol levels before and after autograft of cryopreserved ovarian tissue. The autograft procedure is represented at time 0 months. The arrow indicates the first menstruation.

aged 13 years and 11 months (height 158 cm and weight 37 kg), and had never experienced menstruation. A right oophorectomy was carried out by laparoscopy in June 2001, and 62 fragments of ovarian tissue (~2 × 3 × 1–2 mm) were cryopreserved, as previously described (Demeestere *et al.*, 2006). The conditioning regimen consisted of oral busulfan (16 mg/kg), cyclophosphamide (200 mg/kg) and anti-thymocyte globulin (ATG 12 mg/kg), and graft-versus-host disease (GVHD) prophylaxis with cyclosporin and methotrexate. Following HSCT, the patient developed grade II acute GVHD, and also limited chronic GVHD that required the continuation of immunosuppressive drugs for 18 months. All hematological values, as well as cerebral velocities, were normalized after HSCT, and full donor chimerism was obtained. As expected, following myeloablative conditioning, the patient developed primary ovarian failure, with elevated gonadotropins. Menarche was induced at the age of 15.5 years (Tanner stage A2P3M3) with the use of a third-generation estrogen–progesterone preparation.

Ten years later, the patient was counseled for her wish to become pregnant. After the interruption of hormonal supplementation, POI was confirmed by the presence of permanent amenorrhea and high gonadotropin levels (FSH 59 IU/l, LH 32 IU/l). The patient underwent ovarian tissue transplantation, in order to restore her fertility. Prior to transplantation, two fragments of ovarian tissue were thawed for follicular density assessment. Two and six follicles per millimeter square were observed in the fragments. Transplantation was performed by a two-step laparoscopy procedure (Demeestere *et al.*, 2006), using a da Vinci surgical robotic system in May 2011. Four thawed ovarian fragments were grafted on the residual left ovary, six were grafted in the right peritoneal bursa, and five were grafted subcutaneously using a trocar incision.

Following the grafting procedure, the FSH level progressively decreased, whereas both inhibin B and estradiol serum levels increased (Fig. 1). Four months later, the hormonal levels reached the premenopausal range (FSH 5 IU/l; LH 6 U/l; estradiol E2 166 pg/ml), and ovarian activity was observed in all transplanted sites on pelvic ultrasound imaging. Menstruation was first occurred 5 months post-transplantation of ovarian tissue and was followed by regular menstrual cycles thereafter. The patient had recourse to assisted reproductive technologies for male infertility, although all such treatments were discontinued due to relationship issues. Although she did not conceive during the first 2 years post-transplantation, she reported regular menstruation throughout this period. Basal FSH levels remained within the normal range throughout most of the menstrual cycles (Fig. 1), while anti-Müllerian hormone (AMH) levels remained undetectable. After more than two years post-transplantation, the patient had a spontaneous pregnancy with a new partner and spontaneously delivered a healthy boy in November 2014 (birthweight 3140 g, Apgar score of 9 and 10 at 1 and 5 min, respectively).

Ethical approval

The procedures were approved by ethical committees of the Erasme Hospital and of the Hôpital Universitaire des Enfants Reine Fabiola (Brussels, Belgium).

Discussion

This case reports the first live birth after transplantation of ovarian tissue harvested before menarche. To our knowledge, only two cases of cryopreserved ovarian tissue autograft, with the aim of inducing puberty, have been reported in children (Poirot *et al.*, 2012; Ernst *et al.*, 2013); in each case, ovarian function was restored for at least 19 months and puberty was successfully induced. While the use of an experimental and invasive procedure for this clinical indication raises a number of concerns (Anderson *et al.*, 2013), the authors showed, for the first time, the possibility of restoring endocrine function from

ovarian tissue harvested before puberty (Poirot *et al.*, 2012; Ernst *et al.*, 2013). The prepubertal ovary contains many follicles at an early stage of development, which is theoretically favorable for restoring ovarian function after grafting. However, the developmental competence of these oocytes remains poorly investigated. Immature oocytes collected from prepubertal ovarian tissue have been shown to mature *in vitro*, but to a lesser degree than those retrieved from adult tissue (Revel *et al.*, 2009; Fasano *et al.*, 2011). A recent study reported that ovarian tissue from prepubertal girls contains a larger proportion of abnormal follicles, compared with adult ovarian tissue, and *in vitro* activation of quiescent follicles also occurs differently, leading to limited follicular development (Anderson *et al.*, 2014). These data highlight the need to further investigate the viability of ovarian tissue transplantation for restoring fertility when the cryopreservation procedure occurs before the patient starts puberty.

While cryopreservation of ovarian tissue is a common procedure to preserve fertility in children, this report offers, for the first time, evidence for the long-term survival of autografts of ovarian tissue cryopreserved before menarche and the efficiency of the procedure to restore fertility.

Acknowledgement

We thank J. Dechene for her contribution to the fertility preservation program.

Authors' roles

I.D. was responsible for the fertility preservation program and performed the cryopreservation procedure. I.D. and L.D. contributed to the data collection and analysis and wrote the manuscript. A.F. contributed to the data collection and analysis, performed the HSCT, referred the patient for fertility preservation and revised the manuscript. C.B. contributed to the data collection and manuscript revision. P.S. performed the ovarian tissue transplantation procedure. F.M. and S.T. managed the patient during the transplantation and the follow up. A.D. and F.D. contributed to the development of the fertility preservation program, managed the patient for assisted reproductive treatments and contributed to the revision of the manuscript.

Funding

This program was supported by the Fondation Belge contre le Cancer and the Fonds de la Recherche Scientifique FNRS-Télévie. I.D. is a research associate at the FNRS.

Conflict of interest

None declared.

References

Anderson RA, Hindmarsh PC, Wallace WH. Induction of puberty by autograft of cryopreserved ovarian tissue in a patient previously treated for Ewing sarcoma. *Eur J Cancer* 2013;**49**:2960–2961.

Anderson RA, McLaughlin M, Wallace WH, Albertini DF, Telfer EE. The immature human ovary shows loss of abnormal follicles and increasing follicle developmental competence through childhood and adolescence. *Hum Reprod* 2014;**29**:97–106.

Borgmann-Staudt A, Rendtorff R, Reinmuth S, Hohmann C, Keil T, Schuster FR, Holter W, Ehlert K, Keslova P, Lawitschka A *et al.* Fertility after allogeneic haematopoietic stem cell transplantation in childhood and adolescence. *Bone Marrow Transplant* 2012;**47**:271–276.

Brougham MF, Wallace WH. Subfertility in children and young people treated for solid and haematological malignancies. *Br J Haematol* 2005;**131**: 143–155.

Demeestere I, Simon P, Buxant F, Robin V, Fernandez SA, Centner J, Delbaere A, Englert Y. Ovarian function and spontaneous pregnancy after combined heterotopic and orthotopic cryopreserved ovarian tissue transplantation in a patient previously treated with bone marrow transplantation: case report. *Hum Reprod* 2006;**21**:2010–2014.

Demeestere I, Simon P, Emiliani S, Delbaere A, Englert Y. Orthotopic and heterotopic ovarian tissue transplantation. *Hum Reprod Update* 2009; **15**:649–665.

Donnez J, Dolmans MM, Pellicer A, Diaz-Garcia C, Ernst E, Macklon KT, Andersen CY. Fertility preservation for age-related fertility decline. *Lancet* 2015;**385**:506–507.

Ernst E, Kjaersgaard M, Birkebaek NH, Clausen N, Andersen CY. Case report: stimulation of puberty in a girl with chemo- and radiation therapy induced ovarian failure by transplantation of a small part of her frozen/thawed ovarian tissue. *Eur J Cancer* 2013;**49**:911–914.

Fasano G, Moffa F, Dechene J, Englert Y, Demeestere I. Vitrification of in vitro matured oocytes collected from antral follicles at the time of ovarian tissue cryopreservation. *Reprod Biol Endocrinol* 2011;**9**:150.

Imbert R, Moffa F, Tsepelidis S, Simon P, Delbaere A, Devreker F, Dechene J, Ferster A, Veys I, Fastrez M *et al.* Safety and usefulness of cryopreservation of ovarian tissue to preserve fertility: a 12-year retrospective analysis. *Hum Reprod* 2014;**29**:1931–1940.

Poirot C, Abirached F, Prades M, Coussieu C, Bernaudin F, Piver P. Induction of puberty by autograft of cryopreserved ovarian tissue. *Lancet* 2012; **379**:588.

Revel A, Revel-Vilk S, Aizenman E, Porat-Katz A, Safran A, Ben-Meir A, Weintraub M, Shapira M, Achache H, Laufer N. At what age can human oocytes be obtained? *Fertil Steril* 2009;**92**:458–463.

Stoop D, Cobo A, Silber S. Fertility preservation for age-related fertility decline. *Lancet* 2014;**384**:1311–1319.

Wallace WH, Smith AG, Kelsey TW, Edgar AE, Anderson RA. Fertility preservation for girls and young women with cancer: population-based validation of criteria for ovarian tissue cryopreservation. *Lancet Oncol* 2014;**15**:1129–1136.