

Autotransplantation of cryopreserved ovarian tissue in cancer survivors and the risk of reintroducing malignancy: a systematic review

L. Bastings^{1,*}, C.C.M. Beerendonk¹, J.R. Westphal¹, L.F.A.G. Massuger¹, S.E.J. Kaal², F.E. van Leeuwen³, D.D.M. Braat¹, and R. Peek¹

¹Department of Obstetrics and Gynaecology (791), Radboud University Nijmegen Medical Centre, PO Box 9101, 6500 HB Nijmegen, The Netherlands ²Department of Medical Oncology (452), Radboud University Nijmegen Medical Centre, PO Box 9101, 6500 HB Nijmegen, The Netherlands ³Department of Epidemiology, The Netherlands Cancer Institute, PO Box 90203, 1006 BE Amsterdam, The Netherlands

*Correspondence address. Tel: +31-24-361-47-48; Fax: +31-24-3617177; E-mail: l.bastings@obgyn.umcn.nl

Submitted on September 23, 2012; resubmitted on March 29, 2013; accepted on April 8, 2013

TABLE OF CONTENTS

- Introduction
 - Methods
 - Study design
 - Study populations
 - Search strategy
 - Study selection
 - Data collection
 - Presentation of results
 - Results
 - Study selection
 - Tumours of the breast
 - Tumours of the genital tract
 - Tumours of the gastrointestinal tract
 - Lymphomas
 - Leukaemia
 - Tumours of the urinary tract
 - Tumours of the respiratory tract
 - Melanoma and malignant blue naevus
 - Bone and soft tissue tumours
 - Other tumours
 - Discussion
 - Principal findings and implications for clinical practice
 - Appropriateness of included studies
 - Implications for future research
 - Implications for fertility preservation choices
 - Registration of autotransplantation procedures
 - Conclusion
-

BACKGROUND: The risk of recurrent oncological disease due to the reintroduction of cancer cells via autotransplantation of cryopreserved ovarian tissue is unknown.

METHODS: A systematic review of literature derived from MEDLINE, EMBASE and the Cochrane Library was conducted. Studies on follow-up after autotransplantation; detection of cancer cells in ovarian tissue from oncological patients by histology, polymerase chain reaction or xenotransplantation; and epidemiological data on ovarian metastases were included.

RESULTS: A total of 289 studies were included. Metastases were repeatedly detected in ovarian tissue obtained for cryopreservation purposes from patients with leukaemia, as well as in one patient with Ewing sarcoma. No metastases were detected in ovarian tissue from lymphoma and breast cancer patients who had their ovarian tissue cryopreserved. Clinical studies indicated that one should be concerned about autotransplantation safety in patients with colorectal, gastric and endometrial cancer. For patients with low-stage cervical carcinoma, clinical data were relatively reassuring, but studies focused on the detection of metastases were scarce. Oncological recurrence has been described in one survivor of cervical cancer and one survivor of breast cancer who had their ovarian tissue autotransplanted, although these recurrences may not be related to the transplantation.

CONCLUSIONS: It is advisable to refrain from ovarian tissue autotransplantation in survivors of leukaemia. With survivors of all other malignancies, current knowledge regarding the safety of autotransplantation should be discussed. The most reassuring data regarding autotransplantation safety were found for lymphoma patients.

Key words: autotransplantation / ovarian tissue / fertility preservation / safety / cancer

Introduction

The past decade has seen a rapid increase in the number of ovarian tissue cryopreservation and autotransplantation procedures performed worldwide, resulting in 21 live births being reported from several countries (Donnez et al., 2012). As infertility due to premature ovarian failure may arise as a consequence of chemo- or radiotherapy (Larsen et al., 2003; Borgmann-Staudt et al., 2012; Morgan et al., 2012), oncological diseases are the leading indications for ovarian tissue cryopreservation (Feigin et al., 2007; Poirot et al., 2007; Anderson et al., 2008; Revel et al., 2009; Oktay and Oktem, 2010; Donnez and Dolmans, 2011; Lawrenz et al., 2011; Schmidt et al., 2011). Ovarian tissue harvesting is preferentially performed before the start of gonadotoxic treatment. As neither ovarian stimulation nor a partner is required, this specific fertility preservation strategy especially holds promise for adolescent and even prepubertal girls, as well as for women who cannot delay oncological therapy (Jadoul et al., 2010; Donnez and Dolmans, 2011).

Despite its clinical success, the procedure of autotransplantation after ovarian tissue cryopreservation comes with a significant issue of concern. Namely, ovarian grafts from oncological patients may harbour cancer cells and autotransplantation of such grafts could theoretically lead to recurrence of oncological disease (Reid and Marsden, 1980; Shaw et al., 1996; Meirrow et al., 1998, 2008; Kim et al., 2001; Seshadri et al., 2006; Sanchez-Serrano et al., 2009; Abir et al., 2010; Azem et al., 2010; Dolmans et al., 2010; Rosendahl et al., 2010, 2011b; Greve et al., 2012). As the ovarian strips that are analysed by histology or polymerase chain reaction (PCR) are no longer available for transplantation purposes, it remains unclear whether the strips that are actually transplanted are also devoid of cancer cells (Bastings et al., 2013).

The magnitude of the risk of reintroduction of a malignancy in specific situations is currently unknown, although it has been hypothesized to be influenced by cancer type and stage, the mass of malignant cells transferred, and the time of ovarian tissue harvesting in relation to oncological treatment (Kim, 2003; Akar and Oktay, 2005; Sonmezer et al., 2005; Rosendahl et al., 2010; Greve et al., 2012). Malignant diseases have been classified into three categories representing a low, intermediate or high risk of ovarian involvement (Sonmezer and Oktay, 2004; Akar

and Oktay, 2005; Sonmezer et al., 2005). Unfortunately, the exact magnitude of the risk of ovarian metastasis for these different categories remains unspecified as is the selection of relevant data supporting these classifications.

The recent development in the field of ovarian tissue autotransplantation has fuelled the urgency for reliable information on the safety of the procedure. With cryopreservation and autotransplantation procedures already being performed on a large scale during the last decade (Akar and Oktay, 2005; Donnez et al., 2006, 2012; Meirrow et al., 2007a, b; Anderson et al., 2008; Oktay and Oktem, 2010; Lawrenz et al., 2011; Schmidt et al., 2011), the number of cancer survivors requesting autotransplantation is expected to increase considerably in the near future. Exact figures on the number of cryopreservation procedures performed are unknown, as there is no international registry to which these procedures should be reported. Nevertheless, over 2500 cryopreservation procedures have been performed (C. Diaz and A. Pellicer, personal communication; K. Oktay, personal communication; Feigin et al., 2007; Meirrow et al., 2007a, b; Poirot et al., 2007; Anderson et al., 2008; Sanchez et al., 2008; Revel et al., 2009; Jadoul et al., 2010; Rosendahl et al., 2011b; Montag et al., FertiProtekt). Other factors possibly stimulating the demand for ovarian tissue autotransplantation are the increasing cancer incidence and improving cancer survival in the adolescent and young adult population (Aben et al., 2012). Finally, postponement of parenthood in Western countries (Mills et al., 2011) may enlarge the group of newly diagnosed cancer patients with an interest in fertility preservation options.

Ideally, patients requesting autotransplantation, as well as newly diagnosed cancer patients who consider cryopreservation of their ovarian tissue, should be comprehensively counselled on the risks of recurrent disease after autotransplantation when compared with their risk of oncological relapse when no autotransplantation would be performed (Kulp and Hubayter, 2011). The current study aims to systematically review all articles containing relevant information on the risk of reintroducing malignancy via ovarian transplants. In addition, this study will reveal gaps in the current knowledge.

Data from autotransplantation procedures performed thus far seem the most appropriate when it comes to assessing autotransplantation

safety. These studies, however, are relatively scarce and suffer from a short follow-up and low numbers of patients. Therefore, other parameters that can serve as a proxy for the risk of recurrent malignancy after autotransplantation will be taken into account. These include studies aimed at the detection of cancer cells in ovarian tissue from oncological patients by means of histology, PCR or xenotransplantation, as well as clinical or autopsy studies assessing the frequency of ovarian metastases in different oncological diseases.

Methods

Study design

We aimed to identify peer-reviewed studies meeting one of the following designs:

- (i) Studies describing the follow-up of cancer survivors after autotransplantation of cryopreserved ovarian tissue.
- (ii) Studies focussing on detection of residual cancer cells, in the ovarian tissue of oncological patients who had ovarian tissue cryopreservation, by histology, PCR or xenotransplantation.
- (iii) Studies in which ovarian involvement is reported for a group of cancer patients. The study populations from these studies consisted of cancer patients who have not had ovarian tissue cryopreservation. Both clinical studies and autopsy studies were included.
- (iv) Case reports and case series reporting on ovarian metastases in cancer patients. These studies were included only when no ovarian involvement was described for the specific tumour type and stage from clinical studies or studies focussing on the detection of residual malignant cells in ovarian tissue from cancer patients.

Study populations

Studies focussing on detection of residual disease in ovarian tissue

Study populations of these studies consisted of women who were part of a fertility preservation programme. All patients were premenopausal oncological patients who applied for ovarian tissue cryopreservation.

Clinical studies and case reports

Regarding clinical studies, we aimed to identify studies describing patients whose clinical situation and pattern of tumour spread and metastasis would best represent patients applying for ovarian tissue cryopreservation. Studies were excluded if:

- (i) their patient population included women with a premalignancy, primary ovarian cancer, widespread intraperitoneal malignant disease or a tumour directly adhering to the ovary;
- (ii) they only reported on ovarian metastases as the first site of recurrence;
- (iii) their patient population included women with a hereditary cancer syndrome associated with an increased risk of ovarian cancer, such as a BRCA1 or BRCA2 mutation, Lynch type II or Peutz Jeghers syndrome.

Studies including patients with tumours that already showed spread or metastases to other sites than the ovary were included only when a homogeneous study group was described.

Age also seems to be a relevant factor when it comes to the pattern of tumour spread, as it has been shown that patients with breast, intestinal or gastric cancer with ovarian spread are significantly younger than patients without ovarian involvement (Lerwill and Young, 2011). In multivariate analyses of two studies concerning cervical and gastric cancer, age proved to be a risk factor for ovarian metastasis (Kim *et al.*, 1999; Landoni *et al.*, 2007). For this reason, studies including patients who were post-menopausal at the time of oncological diagnosis were not taken into account. When no menstrual status was reported, female patients <51 years of age at the time of

oncological diagnosis were included, based on the observation that the median age of onset of menopause in Europe and Northern America ranges from 50.1 to 52.8 years (Pecorelli, 2009).

Autopsy studies

Data on the prevalence of ovarian involvement obtained from deceased patients' autopsy reports presumably represent an upper extreme. For this reason, autopsy studies reporting on post-mortem examination of female cancer patients, including the investigation of the ovaries, were included. Studies describing populations containing the following types of patients were excluded:

- (i) patients with a hereditary cancer syndrome associated with an increased risk of ovarian cancer, such as a BRCA1 or BRCA2 mutation, Lynch type II, or Peutz Jeghers syndrome;
- (ii) patients with primary ovarian cancer;
- (iii) patients who were post-menopausal or, if no menstrual status was given, older than 51 years of age at diagnosis.

Subgroups

When only part of a study population met the inclusion criteria, relevant subgroup(s) were analysed if possible. For instance, from studies describing both pre- and post-menopausal patients, only data regarding premenopausal women were extracted.

Search strategy

Relevant studies were identified from MEDLINE (using the PubMed database), EMBASE and the Cochrane Library, without any restrictions on the date of publication. A combination of Medical Subject Headings (MeSH) or Emtree terms and free text words, formulated after consultation of an information specialist from the Radboud University Nijmegen Library, was used to generate a list of citations. The search was restricted to articles written in the English language and was last updated mid-June 2012. Details on the search strategy for PubMed are displayed in Table I. This strategy was modified for EMBASE and the Cochrane Library. We complemented our electronic search with a manual search of bibliographies from relevant articles, aiming to identify additional relevant studies not captured by our electronic search.

Study selection

The selection of relevant studies was independently conducted by two reviewers (L.B. and R.P.). First, titles and abstracts were examined to decide whether the study might fulfil the predefined selection criteria. Secondly, full texts from selected articles were read to make a final inclusion or exclusion decision. When one or both reviewers were not sure about this final decision, consensus was resolved by discussing the article together or by arbitration by a third reviewer (C.C.B.).

Data collection

Data extraction was performed by two authors independently (L.B. and R.P.) and disagreement was resolved by consensus or arbitration by a third reviewer (C.C.B.) or by discussing the paper with a medical oncologist (S.E.K.) or gynaecological oncologist (L.F.M.). The following information was recorded from the included studies: author's names, publication year, study design, patient and tumour characteristics, oncological treatment and outcome of ovarian involvement. Additionally, duration of follow-up was recorded in follow-up studies after autotransplantation and in xenotransplantation studies. In studies reporting on analysis of ovarian tissue, diagnostic tools were also recorded.

Table I Search strategy for identification of studies in PubMed.

Type I studies (follow-up autotransplantation)	Type II studies (histology, PCR and xenotransplantation)	Type III and IV studies (clinical studies)
(Ovary[mesh] OR ovar*[tiab]) AND (Ovary/transplantation[mesh] OR transplantation, autologous[mesh] OR autologous transplant*[tiab] OR autotransplant*[tiab] OR autograft*[tiab] OR ovarian graft[tiab] OR reimplant*[tiab]) AND (Cryopreservation[mesh] OR cryopreserv*[tiab] OR cryofixat*[tiab] OR cryonic suspension* OR frozen-thawed[tiab] OR frozen[tiab] OR (fertility[tiab] AND preserv*[tiab]))	(Ovary[mesh] OR ovar*[tiab]) AND ((Histology[mesh] OR Polymerase chain reaction[mesh] OR histolog*[tiab] OR immunohistochemi*[tiab] OR histocytochemi*[tiab] OR polymerase chain reaction[tiab] OR polymerase chain reactions[tiab] OR PCR[tiab] OR pathology[mesh] OR ovary/pathology[mesh] OR patholog*[tiab]) OR (Transplantation, heterologous[mesh] OR xenotransplant*[tiab] OR xenograft*[tiab] OR heterograft*[tiab] OR heterologous transplant*[tiab] OR reimplant*[tiab] OR ovary/transplantation[mesh] OR transplant*[tiab])) AND (Neoplasms[mesh] OR neoplasm*[tiab] OR cancer[tiab] OR cancers[tiab] OR cancerous[tiab] OR malignancy[tiab] OR malignant[tiab] OR tumor[tiab] OR tumour[tiab] OR tumors[tiab] OR tumours[tiab] OR carcinoma[tiab] OR lymphoma[tiab] OR leukemia[tiab] OR leukaemia[tiab]) AND (Ovarian neoplasms/secondary[mesh] OR neoplasm, residual[mesh] OR minimal residual disease[tiab] OR ((tumor[tiab] OR tumour[tiab] OR tumors[tiab] OR tumours[tiab] OR disease[tiab] OR neoplasm[tiab] OR cancer[tiab] OR cancers[tiab] OR malignan*[tiab]) AND (residual[tiab] OR reseeding[tiab] OR contamination)))	(Ovary[mesh] OR ovar*[tiab]) AND (Ovarian neoplasms/secondary[mesh] OR Neoplasm metastasis[mesh] OR metasta*[tiab]) AND (‘Risk Assessment’[Mesh] OR ‘Risk Factors’[Mesh] OR risk[tiab] OR ovarian neoplasms/epidemiology[mesh] OR epidemiology[mesh] OR epidemiolog*[tiab] OR incidence[mesh] OR inciden*[tiab] OR prevalence[mesh] OR prevalen*[tiab] OR patients[tiab] OR cases[tiab] OR population[tiab] OR ‘Population’[Mesh] OR ‘Patients’[Mesh])

The search terms displayed in the four columns were combined with OR in the definitive search. Terms with [tiab] reflect free text terms appearing in title or abstract.

Presentation of results

For each tumour type, all relevant publications were discussed. Tumour stages (AJCC TNM classification, FIGO stages, Duke’s stages and Bormann stages) as described in the results may not reflect current classifications, as these are subjected to regular revisions. When tumour stages were not reported for the relevant subgroup of a particular study, tumour characteristics are presented for the study population as a whole. Data were not pooled due to the large methodological and clinical heterogeneity of the included studies, both due to different study designs and large differences in patient populations regarding tumour stages and other characteristics.

Results

Study selection

Our electronic search yielded 16 137 hits and 223 additional articles were derived from bibliographies. A flow scheme of our selection process is outlined in Fig. 1, following the PRISMA Statement (Preferred Reporting Items of Systematic Reviews and Meta-Analyses; Moher et al., 2009). After exclusion of 4855 duplicates and 9895 articles on title or abstract basis, the full texts of the remaining 1610 articles were screened.

A total of 1321 studies did not meet our eligibility criteria and were therefore excluded. This group consisted of 262 studies that did not provide original data or that did not meet one of the study types mentioned in our eligibility criteria. Although describing (the follow-up of) a

group of cancer patients, 522 clinical and autopsy studies were excluded since they did not report on ovarian metastases or even excluded patients with ovarian involvement. A total of 377 studies did not meet the criteria for age or menstrual status. There were 153 case reports excluded as they indicated ovarian involvement in a malignancy on which information was already available from clinical studies. Finally, from a total of seven studies, no full text version could be obtained by contacting the authors or by consulting international libraries. The remaining 289 articles were included in this review.

Tumours of the breast

Several cases of ovarian tissue autotransplantation in breast cancer patients have been described. Of these women, one had a local breast cancer recurrence (Rosendahl et al., 2011a). Obviously, this relapse may not have any relation to the autotransplantation of the ovarian tissue, as oncological recurrences do also occur spontaneously. Unfortunately, the authors did not explicitly state whether this ‘local recurrence’ referred to a recurrence in the breast or a recurrence near the ovarian transplant.

An additional breast cancer survivor was reported to be free of disease 18 months after transplantation (Sanchez-Serrano et al., 2009). Other reports did not explicitly state the health status of their patients during follow-up, although these patients are likely to be free of disease since most of them were pursuing pregnancy (Oktay et al., 2004; Andersen

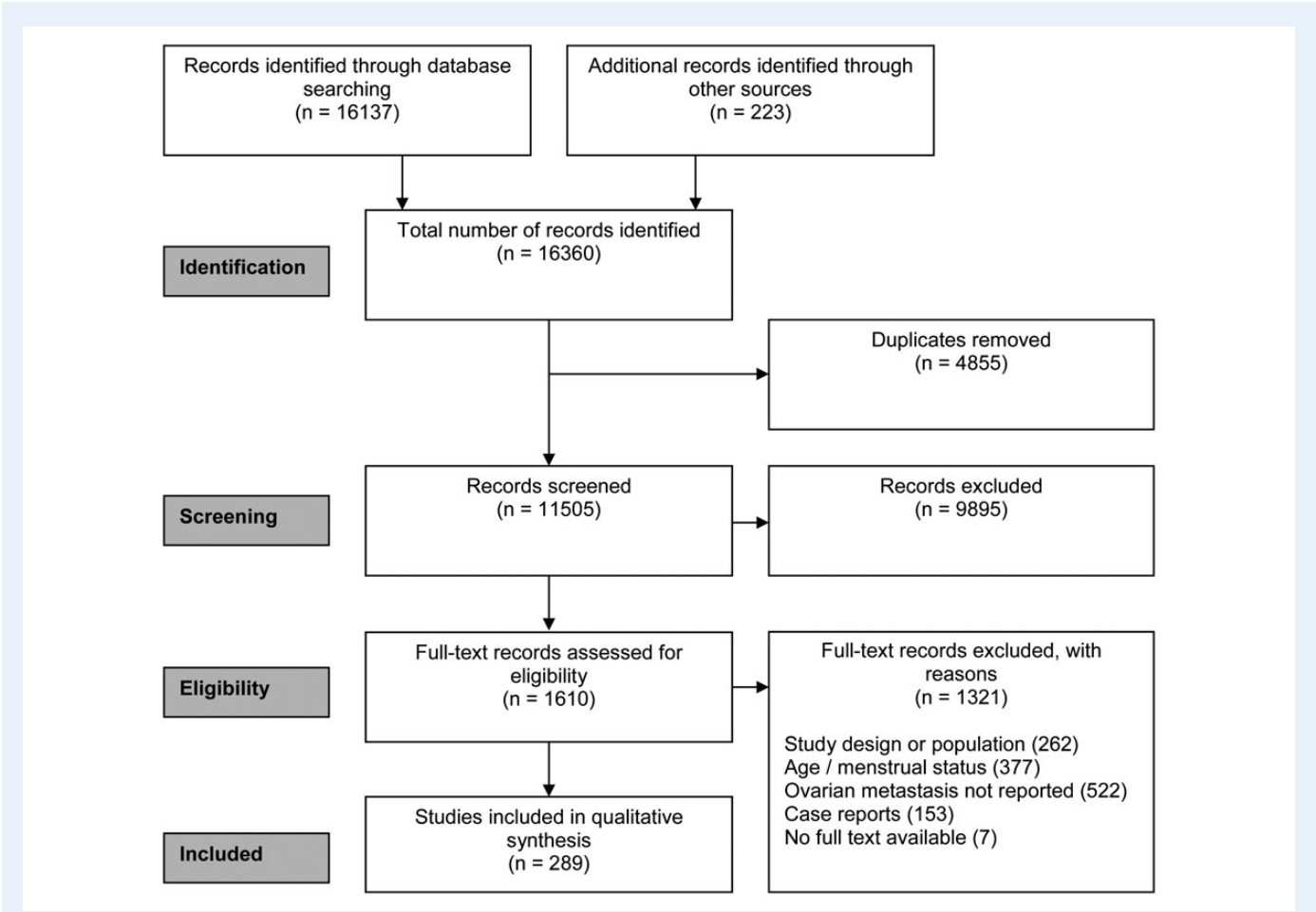


Figure 1 PRISMA flow chart of the systematic review process.

et al., 2008; Kim *et al.*, 2009; Oktay and Oktay, 2010; Sanchez-Serrano *et al.*, 2010; Schmidt *et al.*, 2011; Kim, 2012). The maximum duration of follow-up after autotransplantation was 19 months (Sanchez-Serrano *et al.*, 2010).

Histological examination and xenotransplantation of ovarian tissue from breast cancer patients have provided reassuring results (Table II). Two clinical studies indicated ovarian metastases in breast cancer patients, although the study with the largest population reported a very low percentage. However, results from autopsy studies suggested that ovarian metastases are fairly common in advanced breast cancer. As no explicit information on BRCA testing was reported in the clinical and autopsy studies, it remains unclear whether BRCA patients were part of the studies.

Tumours of the genital tract

Cervical carcinoma

Kim *et al.* (2004, 2009) have reported a total of four procedures of ovarian tissue autotransplantation in cervical cancer survivors (Kim, 2012; C. Diaz and A. Pellicer, personal communication; K. Oktay, personal communication). Histological analysis showed no ovarian involvement in these patients (Kim *et al.*, 2004, 2009). One patient had an oncological relapse and died shortly after autotransplantation. Although specific information about the nature of this oncological recurrence

cannot be found in the publication, the authors do not suspect the relapse to be a result from the autotransplantation, but consider it to be arisen spontaneously (Kim, 2012; C. Diaz and A. Pellicer, personal communication; K. Oktay, personal communication). Despite a maximum period of 7.5 years after ovarian tissue autotransplantation, the health status of the other patients was not described (Kim, 2012).

Apart from these autotransplantations, results were available from histological examination for only a small group of patients, as well as from clinical studies (Table III). Whereas most clinical studies reported low percentages of ovarian involvement in their populations, two studies reported metastases in more than 4% of the patients in their (sub)populations: one study with only 14 patients and another study with a subgroup of 146 premenopausal adenocarcinoma patients (Natsume *et al.*, 1999; Nakanishi *et al.*, 2001).

Endometrial carcinoma

One can hypothesize that patients suffering from endometrial cancer may not prefer cryopreservation of ovarian tissue, especially when facing hysterectomy or pelvic irradiation as cancer treatment. Nevertheless, these patients may wish to fulfil their child wish with the help of a surrogate mother in the future. Presumably due to the nature of the disease and its treatment, ovarian tissue autotransplantation has not been reported in endometrial cancer patients. Data from histological

Table II Epidemiological data from breast cancer studies.

First author, year	Sample size	Assessment	Menstrual status or age (years)	Characteristics: Study group	Characteristics: Patients with ovarian metastasis	Oncological therapy: Study group	Ovarian metastasis
Histology or PCR (OTC patients)							
Azem <i>et al.</i> (2010)	13	Histology/Histochemistry Fresh ovarian tissue	Premenopausal	OTC patients	–	No CT or RT	0%
Rosendahl <i>et al.</i> (2011b)	51	Histology/immunohistochemistry Cryopreserved and thawed ovarian tissue	Premenopausal	OTC patients Median tumour size 18 mm (5–75) (Data available for $n = 47$) N1: 44% (Data available for $n = 44$)	–	NR	0%
Sanchez-Serrano <i>et al.</i> (2009)	69	Histology/immunohistochemistry Fresh ovarian tissue $n = 63$; Cryopreserved and thawed tissue $n = 6$	Premenopausal	OTC patients Exclusion: BRCA1/2 or HER2neu mutation carriers ER+: 76.2%; PR+: 69.7% N0: 49.2%; N1: 50.8%	–	17% received CT before OTC	0%
Xenotransplantation							
Rosendahl <i>et al.</i> (2011a)	9	Xenotransplantation of cryopreserved and thawed ovarian cortex into immunodeficient nude mice. Histology 4 weeks after xenotransplantation	Premenopausal	OTC patients	–	NR	0%
Clinical studies							
Lecca <i>et al.</i> (1980)	15	Histology after therapeutic oophorectomy	Premenopausal	NR	NR	Radical mastectomy (all patients), RT, CT, hormonal therapy	46.7% (7/15)
Lee <i>et al.</i> (2010a, b)	406	Clinical follow-up (mean 74 ± 48.19 months)	≤ 35	Patients with IDC (Otherwise NR for subgroup)	NR	NR for subgroup	IDC: 0–0.2% (max 1/406) ^a
Autopsy							
Bumpers <i>et al.</i> (1993)	15	Autopsy; evaluation of medical records	< 50	Died of disseminated ILC	NR	NR	46.7% (7/15)
Kyono <i>et al.</i> (2010)	648	Autopsy	< 41	NR	NR	NR	24.2% (157/648) 0% (0/3) Age 11–20: 19.4% (14/72) Age 21–30: 25.0% (143/573) Age 31–40

OTC, ovarian tissue cryopreservation; ILC, infiltrating lobular carcinoma of the breast; IDC, infiltrating ductal carcinoma of the breast; LN, lymph node, CT, chemotherapy, RT, radiotherapy; max, maximum; NR, not reported.

^aAn exact percentage of ovarian involvement could not be derived from these studies, as age or menopausal status was not provided for the women with ovarian metastases.

Table III Epidemiological data from cervical cancer studies.

First author, year	Sample size	Assessment	Menstrual status or age (years)	Characteristics: Study group	Characteristics: Patients with ovarian metastasis	Oncological therapy: Study group	Ovarian metastasis
Histology or PCR (OTC patients)							
Azem <i>et al.</i> (2010)	2	Histology/ Histochemistry Fresh ovarian tissue	Premenopausal	OTC patients	—	No prior CT or RT	0%
Huser <i>et al.</i> (2007)	1	Histology Fresh ovarian tissue	Premenopausal	OTC patient Tumour stage NR	—	Prior treatment NR	0%
Xenotransplantation							
—							
Clinical studies							
Kim <i>et al.</i> (2008)	156	Histology	<45	SCC or Non-SCC; FIGO Stage IA-IIB	NR	RH + PLND + BSO with or without appendectomy No prior CT	3.2% (5/156)
Kodama <i>et al.</i> (2007)	109	NR Follow-up 1–143 months	<50	SCC, AC or ADSC; FIGO Stage IB-IIB	NR	RH + PLND (all patients) EPI, CT, chemoradiation	0–3.7% (max 4/109) ^a
Landoni <i>et al.</i> (2007)	807	Histology	<45	SCC, AC, or ADSC; FIGO stage IA2, IB or IIA	NR	RH + PLND + BSO	0.2% (2/807)
Morice <i>et al.</i> (2000, 2001)	95	Clinical follow-up (14–15 years)	<43	AC (N = 15) or SCC (N = 80) FIGO Stage IB1, IB2 or IIA LN + : 20%	Both cases: Age 34; SCC; Stage IB1; LN- RH + PLND + brachytherapy	RH + PLND VB (N = 84); EPI (N = 25)	2.1% (2/95) SCC: 2.5% (2/80) AC: 0% (0/15)
Nakanishi <i>et al.</i> (2001)	SCC: 556 AC: 146	Histology	Premenopausal	All SCC and AC patients who underwent BSO or USO and hysterectomy and PLND	SCC (N = 4); AC (N = 10)	Hysterectomy + PLND + BSO or USO	2.0% (14/702) SCC: 0.7% (4/556) AC: 6.8% (10/146)
Natsume <i>et al.</i> (1999)	14	Histology	≤40	SCC or AC FIGO stage IB, IIA and IIB	Case 1: Age 29, Stage IB AC Case 2: Age 27, Stage IIB, AC	RH + PLND + BSO	14.3% (2/14)
Pahisa <i>et al.</i> (2008)	28	Clinical follow-up (mean 44.3 ± 23.1 months; N = 4 lost to follow-up)	Premenopausal	AC (N = 6) or SCC (N = 22); FIGO Stage IB1 Patients who underwent oophorectomy	—	RH + PLND + BSO VB (N = 12); EPI (N = 5)	0% (0/28)
Parente <i>et al.</i> (1964)	88	Histology	≤50	Stage I epidermoid carcinoma	—	RH + PLND + BSO	0% (0/88)
Yamazawa <i>et al.</i> (2003)	69	Clinical follow-up (4–137 months)	<50	FIGO Stage IB1-II	NR	RH or simple hysterectomy, PLND, post-operative CT or RT	0–1.4% (max 1/69) ^a
Autopsy							
—							

AC, adenocarcinoma; SCC, squamous cell carcinoma; Non-SCC, non-squamous cell carcinoma; ADSC, adenosquamous cell carcinoma; RH, radical hysterectomy; PLND, pelvic lymph node dissection; CT, chemotherapy; RT, radiotherapy; EPI, External pelvic irradiation; VB, vaginal brachytherapy; BSO, bilateral salpingo-oophorectomy; USO, unilateral salpingo-oophorectomy; LN ±, lymph node positive/negative; NR, not reported.

^aAn exact percentage of ovarian involvement could not be derived from these studies, as age or menopausal status was not provided for the women who had ovarian metastasis. The minimum and maximum percentages of ovarian involvement that could possibly result from the data given are shown in the table.

examinations are scarce, while clinical studies with relatively small sample sizes are available (Table IV). These studies revealed that ovarian metastases could occur in patients with different tumour stages. One larger study including only FIGO I patients reported a relatively low percentage of ovarian involvement (Pan et al., 2011).

Other tumours of the female genital organs

No autotransplantation procedures have been reported in patients with other types of gynaecological malignancies. One study reported on the incidence of ovarian metastases in a group of patients who died after a diagnosis of uterine cancer, without specifying cancer type or stage (Kyono et al., 2010). Included in this study were four patients of 20 years or younger who had had uterine cancer without ovarian involvement. Amongst patients aged 21–30 years, 12.8% had ovarian metastases, while in patients aged 31–40, 13.3% had metastases.

Although the incidence of ovarian involvement in patients with other gynaecological malignancies cannot be obtained from studies with larger populations, case reports have indicated ovarian involvement in various malignancies. Ovarian metastases have been found in women with an epithelioid or placental site trophoblastic tumour (Xue et al., 2002; Aoki et al., 2005; Milingos et al., 2007; Shet et al., 2008; Lan et al., 2010), leiomyosarcoma (Young and Scully, 1990; Vasiljevic et al., 2008), endometrial stromal sarcoma (Young and Scully, 1990; Khalifa et al., 1996; Yilmaz et al., 2002) and other tumours (Tripathi et al., 2005).

Tumours of the gastrointestinal tract

Gastric cancer

Autotransplantation has not been performed in patients suffering from gastric cancer. Five clinical and autopsy studies were identified that presented data on ovarian involvement in gastric cancer (Table V), all from Asian countries. The incidences reported for ovarian metastases varied considerably. The lowest incidence (7.4%) was reported in a clinical follow-up study amongst 380 patients with gastric cancer (Yook et al., 2007). Two relatively small autopsy studies described metastases in all premenopausal patients studied, although one of these studies focused on gastric cancer patients who already had cervical metastases (Hirono et al., 1983; Imachi et al., 1993).

Colorectal, appendiceal and anal cancer

Two reports were retrieved describing ovarian tissue autotransplantation in a patient with anal cancer. However, no information was provided on the analysis of the ovarian tissue for malignant cells or on the health status of the patient after transplantation (Dittrich et al., 2008, 2009).

Data on histological examination of ovarian tissue from colon cancer patients undergoing ovarian tissue cryopreservation were scarce, while several clinical and autopsy studies indicated ovarian metastases to be present in colon carcinoma patients (Table VI). Unfortunately, the study populations were relatively small for four out of five clinical studies and the populations consisted of patients with varying tumour stages.

A single report on the frequency of ovarian metastases from appendiceal cancer reported an incidence of 28.6% and indicated that patients with advanced cancer stages were most at risk for having ovarian metastases (Dittrich et al., 2007). Additional case reports have described ovarian involvement in various histological types of appendiceal cancer (Lesnick and Miller, 1949; Wilson, 1962; Hesketh, 1963; Forsgren et al., 1974; Qizilbash, 1975; Fichera et al., 1976; Gamble, 1976; Didolkar

and Fanous, 1977; Paone et al., 1978; Bullon et al., 1981; Kashani and Levy, 1983; Tan and Lau, 1983; Merino et al., 1985; McBroom et al., 2000; Ayhan et al., 2005; Hristov et al., 2007; Powell et al., 2009; Timofeev et al., 2010).

Other tumours of the gastrointestinal tract

For tumours of other parts of the gastrointestinal tract, neither autotransplantation reports nor epidemiologic data were available. Nevertheless, ovarian involvement has been indicated in case reports describing patients with hepatocellular carcinoma (Oortman and Elliott, 1983; Young et al., 1992a, b; de Groot et al., 2000; Stippel et al., 2005; Montero et al., 2007; Lee et al., 2011; Benito et al., 2012), hepatoblastoma (Green and Silva, 1989) and bile duct or gallbladder carcinomas (Lashgari et al., 1992; Petru et al., 1992; Chang et al., 1997; Ayhan et al., 2001; Low et al., 2003; Miyagui et al., 2003; Garcia et al., 2004; Jain et al., 2006; Khunamornpong et al., 2007, 2008; Lee et al., 2009; Kumar et al., 2010; Singh et al., 2010; Pusiol et al., 2011). Tumours of the small bowel and pancreatic tumours were also shown to have the capacity to metastasize to the ovaries (Roley et al., 1990; Tsuruchi et al., 1995; Loke et al., 1997; Dunsmore and Lovell, 1998; Wysocki et al., 2001; Yanai et al., 2003; Ayhan et al., 2005; Husain et al., 2006; Maekawa et al., 2010).

Lymphomas

The follow-up from lymphoma survivors who received ovarian tissue autotransplantation has not been extensively described when it comes to disease status. Nevertheless, numerous autotransplantation procedures have been performed in lymphoma survivors and no recurrent cancer has been reported following transplantation (Radford et al., 2001; Donnez et al., 2004; Meirow et al., 2005; Schmidt et al., 2005, 2011; Demeestere et al., 2006, 2007, 2010; Donnez et al., 2006, 2008; Oktay, 2006; Rosendahl et al., 2006, 2011a; Meirow et al., 2007a, b; Andersen et al., 2008; Meirow, 2008; Dolmans et al., 2009; Oktay and Oktay, 2010; Silber et al., 2010; Akar et al., 2011; Oktay et al., 2011; Stern et al., 2011; Dittrich et al., 2012; Kim, 2012; Muller et al., 2012). In accordance with these findings, histological assessment and xenotransplantation of ovarian cortex fragments obtained for cryopreservation purposes has failed to reveal any tumour components (Table VII).

In a clinical study focussing on patients with lymphoma in the gynaecological organs, as well as an autopsy study regarding lymphoma patients, ovarian involvement has been described (Table VII). Unfortunately, these studies did not provide insight into the risk of ovarian involvement in different types of lymphoma. Case studies have indicated that ovarian metastases could occur in patients suffering from Hodgkin's and non-Hodgkin's lymphoma, Burkitt's lymphoma, large and small cell lymphoma, mixed lymphocytic histiocytic and lymphocytic lymphoma, lymphosarcoma and follicular lymphoblastoma (Epperson, 1950; Hahn, 1958; Nelson et al., 1958; Woodruff et al., 1963; Ziegler and Miller, 1966; Finkle and Goldman, 1974; Halpin, 1975; Armon, 1976; Rotmensch and Woodruff, 1982; Gupta et al., 1983; Osborne and Robboy, 1983; Konje et al., 1989; Liang et al., 1990; Monterroso et al., 1993; Skinner et al., 1993; McCarville et al., 2001; Bittinger et al., 2011; Pudasaini et al., 2011).

Table IV Epidemiological data from endometrial cancer studies.

First author, year	Sample size	Assessment	Menstrual status or age (years)	Characteristics: Study group	Characteristics: Patients with ovarian metastasis	Oncological therapy: Study group	Ovarian metastasis
Histology or PCR (OTC patients)							
Azem <i>et al.</i> (2010)	1	Histology/ Histochemistry Fresh ovarian tissue	Premenopausal	OTC patient	–	No CT or RT	0%
Xenotransplantation							
–							
Clinical studies							
Dundar <i>et al.</i> (2002)	24	Histology	<50	FIGO stage I–III EC	EC	Hysterectomy, partial omentectomy, LND, RT	41.7% (10/24)
Evans-Metcalf <i>et al.</i> (1998)	37	Histology	≤45	FIGO stage I–IV	NR	RH, BSO, RT	2.6% (1/39)
Farhi <i>et al.</i> (1986)	10	Clinical follow-up (3 months–10 years)	<25	Grade I–II AA: <i>n</i> = 6; AC: <i>N</i> = 3; ADSC: <i>N</i> = 1	Grade II ADSQ	Hysterectomy, BSO, RT, progestogens	10% (1/10)
Gitsch <i>et al.</i> (1995)	17	Clinical follow-up (12 months–78 years; <i>n</i> = 2 lost to follow-up)	Premenopausal	FIGO stage I–IV AC	AC FIGO stage IIIa: <i>n</i> = 1; stage IV: <i>n</i> = 2	RH, BSO, LND	17.6% (3/17)
Hachisuga <i>et al.</i> (2000)	81	Histology	<50	Grade I–III EC	EC	Hysterectomy, BSO, RT, CT	7.4% (6/81)
Hanprasertpong <i>et al.</i> (2008)	51	Histology	<45	FIGO stage I–III EC: <i>n</i> = 50; AA: <i>n</i> = 1	NR	Surgery, CT, RT	5.9% (3/51)
Kaku <i>et al.</i> (1993)	17	Clinical follow-up (4 months–11 years)	≤40	FIGO stage Ia–IIIc EC: <i>n</i> = 14; AA: <i>n</i> = 3; UC: <i>n</i> = 1 Grade I–III	FIGO stage IIIa AC Grade I	Hysterectomy, BSO, LND, RT, CT	5.9% (1/17)
Lee <i>et al.</i> (2007)	79	Histology	≤45	FIGO stage I–IV	EC: <i>n</i> = 3; mixed undifferentiated and EC: <i>n</i> = 1 LN+: <i>n</i> = 1	Hysterectomy, LND	5.1% (4/79)
Niwa <i>et al.</i> (2000)	14	Clinical follow-up (7–144 months)	<40	FIGO stage Ia–IVb: LN+: <i>n</i> = 5 EC with or without squamous differentiation	FIGO stage IIIb and IVb LN+ (<i>n</i> = 1) EC	CT, RT, surgery	14.3% (2/14)
Pan <i>et al.</i> (2011)	160	Histology	≤45	FIGO stage I	FIGO stage I (<i>n</i> = 3)	Primary total hysterectomy, BSO, LND No CT before surgery	1.9% (3/160)
Quinn <i>et al.</i> (1985)	32	Clinical follow-up (from <5 to >15 years)	Premenopausal	Stage I–IV	NR	Hysterectomy, PLN, BSO, RT	3.1% (1/32)
Walsh <i>et al.</i> (2005)	102	Histology Clinical follow-up after ovarian preservation	<45	FIGO stage I–III Grade I–III EC: <i>n</i> = 98 ADSC: <i>n</i> = 4	FIGO stage IIIa1: <i>n</i> = 1; IIIa2: <i>n</i> = 2	Hysterectomy, BSO (<i>n</i> = 86), CT, hormonal treatment	2.9% (3/102)

Continued

Table IV Continued

First author, year	Sample size	Assessment	Menstrual status or age (years)	Characteristics: Study group	Characteristics: Patients with ovarian metastasis	Oncological therapy: Study group	Ovarian metastasis
		(n = 16): 1–50 months					
Yamazawa et al. (2000)	20	Clinical follow-up (7–126 months)	Premenopausal	FIGO stage Ia–IIIb EC	EC	RH, CT, PLND, BSO	5% (1/20)
Zhou et al. (2005)	11	Histology	≤40	FIGO stage I–IV	FIGO stage I (n = 3)	hysterectomy, BSO, LND, CT, RT, progesterone	27.3% (3/11)
Autopsy	–						

ADSC, adenosquamous cell carcinoma; AA, adenoacanthoma; AC, adenocarcinoma; EC, endometrioid carcinoma; UC, undifferentiated carcinoma; RH, Radical hysterectomy; LND, lymph node dissection; PLND, pelvic lymph node dissection; CT, chemotherapy; RT, radiotherapy; BSO, bilateral salpingo-oophorectomy; LN ±, lymph node positive/negative; NR, not reported; OTC, ovarian tissue cryopreservation.

Leukaemia

Autotransplantation of ovarian tissue has never been reported for patients with leukaemia, presumably due to the alarming results from PCR analysis and xenotransplantation experiments. Indeed, ovarian involvement has been repeatedly indicated in different types of leukaemia by means of xenotransplantation or PCR analysis using a disease-specific molecular marker. In addition, ovarian involvement in leukaemia has been reported in autopsy studies (Table VIII).

Tumours of the urinary tract

Autotransplantation of ovarian tissue has not been performed in patients suffering from urinary tract tumours. Histological analysis of ovarian tissue from two patients with nephroblastoma showed no evidence of ovarian involvement (Poirot et al., 2007), although case reports did demonstrate ovarian involvement in nephroblastoma (Quint and Smith, 1999; McCarville et al., 2001).

Only one clinical study has reported on the incidence of ovarian metastases in a group of premenopausal female patients with a tumour of the urinary tract, namely carcinoma of the bilharzial urinary bladder (Soliman et al., 1976). In this study, no evidence of ovarian metastases was found in 103 patients. Despite these findings, several case reports have indicated ovarian involvement in bladder cancer patients (Rosas-Uribe and Luna, 1969; Bowlby and Smith, 1986; Hasegawa et al., 1989; Ishii et al., 2005; Lee et al., 2010a, b).

Renal cell carcinoma also has the potential to metastasize to the ovaries (Liu et al., 1992; Young and Hart, 1992; Spencer et al., 1993; Adachi et al., 1994; Hammock et al., 2003; Insabato et al., 2003; Anagnostou et al., 2009), as has transitional cell carcinoma of the urinary tract (Fossa et al., 1977; Hsiu et al., 1991; Oliva et al., 1995) and other urinary tract tumours (Gadd et al., 1960).

Tumours of the respiratory tract

No studies on ovarian tissue autotransplantation, xenotransplantation or histological analysis of ovarian tissue from lung cancer patients were retrieved. However, one autopsy study revealed a percentage of 20.9–24.8%

of ovarian metastases in patients with pulmonary carcinoma, depending on the patients' age (Kyono et al., 2010). Unfortunately, the former study as well as one case report did not specify the histological types or tumour stages of pulmonary carcinoma (Lee et al., 2009). However, case reports have indicated involvement in patients diagnosed with large and small-cell lung cancer and papillary-acinar adenocarcinoma (Malviya et al., 1982; Young and Scully, 1985; Nelson et al., 1992; Irving and Young, 2005; Sukumvanich et al., 2005). Other reports showed ovarian involvement in pulmonary papillary serous carcinoma (Householder et al., 2002; Chen et al., 2006), adenocarcinoma of the fetal lung type (Huysentruyt et al., 2010) and pulmonary blastoma (Yu et al., 2009).

Melanoma and malignant blue naevus

For melanoma, no studies reporting on autotransplantation of ovarian tissue, or epidemiology of ovarian involvement were retrieved from the literature. However, numerous case reports were identified describing ovarian metastases from melanoma (Silveira et al., 1977; Gonzalez and Hammond, 1983; Martinelli et al., 1984; Fitzgibbons et al., 1987; Blumenfeld et al., 1991; Young and Scully, 1991; Murphy et al., 1994; Remadi et al., 1997; Moselhi et al., 1998; Nakano et al., 1998; Piura et al., 1998; Santeusanio et al., 2000; Gupta et al., 2004; Rey-Caballero et al., 2004; Belagyi et al., 2006; Jeremic et al., 2006; Bloch-Marcotte et al., 2008; Boutis et al., 2008; Milicevic et al., 2008; Shuhaila et al., 2008; Abe et al., 2009; Bahat et al., 2009; Fenzl et al., 2011; Sbitti et al., 2011; Habek et al., 2012). Apart from cases of ovarian metastases from cutaneous melanomas of different body locations, reports on choroidal melanomas metastasizing to the ovaries were published (Santeusanio et al., 2000; Rey-Caballero et al., 2004; Bloch-Marcotte et al., 2008). In one study, a patient having ovarian involvement from a malignant blue naevus of the vulva was described (Spatz et al., 1998).

Bone and soft tissue tumours

For patients with bone and soft tissue tumours, autotransplantation has only been described for Ewing sarcoma. No oncological relapse was observed during follow-up after autotransplantation (Andersen et al.,

Table V Epidemiological data from gastric cancer studies.

First author, year	Sample size	Assessment	Menstrual status or age (years)	Characteristics: Study group	Characteristics: Patients with ovarian metastasis	Oncological therapy: Study group	Ovarian metastasis
Histology or PCR (OTC patients)							
—							
Xenotransplantation							
—							
Clinical studies							
Kim <i>et al.</i> (1999)	238	Clinical follow-up (2–108 months)	Premenopausal	Papillar and tubular, mucinous or SRCC AJCC stage Ia–IV Borrmann type I–IV	NR	Gastrectomy, LND	9.7% (23/238)
Yook <i>et al.</i> (2007)	380	Histology	<50	Moderately or poorly differentiated, mucinous, or SRCC Early carcinoma— Borrmann type IV	Borrmann type II–IV	NR	7.4% (28/380)
Autopsy							
Hirono <i>et al.</i> (1983)	8	Autopsy	Premenopausal	NR for subgroup	NR	Treated but not further specified	100% (8/8)
Imachi <i>et al.</i> (1993)	13	Autopsy	Premenopausal	Poorly differentiated AC or SRCC metastatic to the cervix Early carcinoma— Borrmann type IV	NR	(sub)total gastrectomy	100% (13/13)
Kyono <i>et al.</i> (2010)	1095	Autopsy	<40	NR	NR	NR	55.7% (611/1095) 0% (0/1) Age 0–10: 78.3% (18/23) Age 11–20: 60.4% (125/207) Age 21–30: 54.2% (468/864) Age 31–40

Stages in this table are according to the AJCC TNM or Borrmann classification.
SRCC, signet ring cell carcinoma; AC, adenocarcinoma; LND, lymph node dissection; NR, not reported.

2008; Ernst *et al.*, 2010; Schmidt *et al.*, 2011; Rosendahl *et al.*, 2011a). RT–PCR analysis of ovarian tissue obtained for autotransplantation purposes from eight Ewing sarcoma patients showed involvement in one case (Abir *et al.*, 2010). Nevertheless, other studies reporting on histological analysis of ovarian tissue from Ewing sarcoma patients did not find any sign of ovarian metastases (Poirot *et al.*, 2007; Azem *et al.*, 2010). Three case reports were retrieved describing ovarian metastasis from Ewing sarcoma in one 13-year-old and two 15-year-old girls (Young and Scully, 1990; Young *et al.*, 1993; Sullivan *et al.*, 2012). Reports on histological analysis of ovarian tissue aiming to identify the presence of minimal residual disease have been published for patients with osteosarcoma as well as rhabdomyosarcoma. Fortunately, no sign of ovarian involvement was found in any of these diseases (Poirot *et al.*, 2007; Azem *et al.*, 2010). However, some of the patients were subjected to chemotherapy before harvesting the ovarian tissue. Case studies have reported ovarian involvement in patients with osteosarcoma (Eltabbakh *et al.*, 1997) and rhabdomyosarcoma (Howarth *et al.*,

1980; Young and Scully, 1989; Young *et al.*, 1993; McCarville *et al.*, 2001). By means of xenotransplantation of ovarian tissue from five patients with sarcoma, no tumour components could be detected (Rosendahl *et al.*, 2011a). For the remaining malignancies of the bone or soft tissue, only case studies were obtained. Ovarian metastases were described in patients with (haem)angiosarcoma (Hermann *et al.*, 1984; Young and Scully, 1990), chondrosarcoma (Young and Scully, 1990; Konishi *et al.*, 1994), desmoplastic small round cell tumour (Young *et al.*, 1992a, b; Zaloudek *et al.*, 1995; Elhajj *et al.*, 2002; Parker *et al.*, 2002; Fang *et al.*, 2008; Ota *et al.*, 2010), clear cell sarcoma (Nugent *et al.*, 2009) and other tumours (Winfield *et al.*, 2007). **Other tumours** The only remaining indication for which ovarian tissue autotransplantation has been performed is neurectodermic tumour, but the

Table VI Epidemiological data from colorectal cancer studies.

First author, year	Sample size	Assessment	Menstrual status or age (years)	Characteristics: Study group	Characteristics: Patients with ovarian metastasis	Oncological therapy: Study group	Ovarian metastasis
Histology or PCR (OTC patients)							
Azem <i>et al.</i> (2010)	1	Histology/ Histochemistry Fresh ovarian tissue	Premenopausal	OTC patient with colon cancer	–	No CT or RT	0%
Xenotransplantation							
–							
Clinical studies							
Blamey <i>et al.</i> (1981)	201	Clinical follow-up (5–96 months)	≤49	Patients undergoing resection of a primary AC of the colon or rectum Duke's stage B–D	Duke's stage B and C	Resection	2.5% (5/201)
Cutait <i>et al.</i> (1983)	14	Clinical follow-up (NR)	Premenopausal	Adenocarcinoma of the colon Duke's stage A–C	Duke's stage C	Resection	7.1% (1/14)
Domergue <i>et al.</i> (1988)	38	Clinical follow-up (from 3 to >15 years)	<40	Patients treated for colorectal (mucinous) AC Duke's stage A–D	NR	Resection, CT, RT	7.9% (3/38)
MacKeigan and Ferguson, (1979)	18	Histology	Premenopausal	Patients who received prophylactic oophorectomy for colorectal AC	Duke's stage B: <i>n</i> = 1; C: <i>n</i> = 4; D: <i>n</i> = 1	Resection	33.3% (6/18)
Pitluk and Poticha (1983)	17	Clinical follow-up	≤40	AC of colon or rectum Duke's stage B–D	NR	Resection	23.5% (4/17)
Autopsy							
Kyono <i>et al.</i> (2010)	256	Autopsy	<40	NR	NR	NR	26.6% (68/256) 16.7% (2/12) Age 11–20: 31.1% (14/45) Age 21–30: 26.1% (52/199) Age 31–40

OTC, ovarian tissue cryopreservation; CT, chemotherapy; RT, radiotherapy; AC, adenocarcinoma; NR, not reported.

disease status after follow-up was not explicitly stated (Donnez *et al.*, 2006; Janse *et al.*, 2011). In another study where ovarian tissue from a patient with neuroectodermal tumour was analysed histologically, no visible tumour components were observed (Poirot *et al.*, 2007).

Data on histological analysis were available for patients who had ovarian tissue cryopreservation for medulloblastoma and neuroblastoma and suggested no ovarian involvement (Poirot *et al.*, 2007; Azem *et al.*, 2010). Nevertheless, case reports and autopsy data have indicated that ovarian involvement in neuroblastoma does occur (Himelstein-Braw *et al.*, 1977; Meyer *et al.*, 1979; Sty *et al.*, 1980; Young *et al.*, 1993; Somjee *et al.*, 1999; McCarville *et al.*, 2001; Miyauchi *et al.*, 2004).

Other case reports have described ovarian involvement in pancreatic neuroendocrine tumours (Oberge *et al.*, 2002; Moayedoddin *et al.*, 2006;

La Rosa *et al.*, 2011), thyroid carcinoma (Young *et al.*, 1994; Logani *et al.*, 2001; Brogioni *et al.*, 2007; Gosnell *et al.*, 2008), malignant thymoma (Yoshida *et al.*, 1981; Bott-Kothari *et al.*, 2000; Demirkiran *et al.*, 2009), malignant adrenal rest tumour (Akishima-Fukasawa *et al.*, 2011) and goblet cell carcinoid (Pearson and Fitzgerald, 1949; Shuster *et al.*, 1970; Robboy *et al.*, 1974; Subbuswamy *et al.*, 1974; Haqqani and Williams, 1977; Brown *et al.*, 1980; Olsson and Ljungberg, 1980; Hirschfield *et al.*, 1985; Miller *et al.*, 1988; Chen, 1990; Ikeda *et al.*, 1991; Young *et al.*, 1993; Roberts, 1997; Tjalma *et al.*, 2000; Mandai *et al.*, 2001; Byrn *et al.*, 2006). Retinoblastoma (McCarville *et al.*, 2001; Moshfeghi *et al.*, 2002), mesothelioma (Ayhan *et al.*, 2005), tumours of the salivary glands (Variakojis *et al.*, 1970; Longacre *et al.*, 1996; Buyukurt *et al.*, 2008) and other tumours (Jindal *et al.*, 2011) were also shown to have the capacity to metastasize to the ovaries.

Table VII Epidemiological data from lymphoma studies.

First author, year	Sample size	Assessment	Menstrual status or age (years)	Characteristics: Study group	Characteristics: Patients with ovarian metastasis	Oncological therapy: Study group	Ovarian metastasis
Histology OTC patients							
Huser <i>et al.</i> (2007)	4	Histology Fresh ovarian tissue	Premenopausal	OTC patients HL: $n = 3$ NHL: $n = 1$ Tumour stage NR	—	Prior treatment NR	0%
Kim <i>et al.</i> (2001)	18	Histology Fresh ovarian tissue	Premenopausal	OTC patients HL: $n = 13$ (3 primary disease, 10 recurrence) NHL: $n = 5$ (2 primary disease; three recurrence) Tumour stage NR	—	Prior treatment NR	0%
Meirow <i>et al.</i> (1998)	7	Histology Fresh ovarian tissue	Premenopausal	OTC patients HL Stage 2B: $n = 3$ Stage 3A: $n = 1$ Stage 4: $n = 3$	—	At least one patient had CT prior to OTC	0%
Meirow <i>et al.</i> (2008)	47	Histology/PCR/ immunohistochemical staining to detect Reed-Sternberg cells (HL) or molecular markers (NHL)	Premenopausal	OTC patients HL: $n = 33$ NHL: $n = 14$	—	CT before OTC: HL: $n = 16$ NHL: $n = 9$	0%
Oktaý and Oktem (2010)	18 or 19	Histology Fresh ovarian tissue	Premenopausal	OTC patients HL: $n = 12$ or 13 patients NHL: $n = 6$	—	NR	0%
Poirot <i>et al.</i> (2007)	3	Histology Fresh ovarian tissue	Prepubertal	OTC patients HL: $n = 1$ Lymphoma (NOS): $n = 2$	—	All patient underwent several courses of CT before OTC	0%
Seshadri <i>et al.</i> (2006)	26	Histology/immunohistochemistry	Premenopausal	OTC patients Stage III or IV: $n = 9$ Disease below diaphragm: $n = 7$	—	Prior CT: $n = 9$: ABVD: $n = 7$ Stanford V: $n = 1$ ChlVPP: $n = 1$	0%
Xenotransplantation							
Kim <i>et al.</i> (2001)	18	Xenotransplantation into 20 NOD/LtSz-SCID mice. Animal autopsy 16 weeks after transplantation	Premenopausal	OTC patients HL: $n = 13$ (3 primary disease, 10 recurrence) NHL: $N = 5$ (2 primary disease; 3 recurrence) Tumour stage NR	—	NR	0%
Rosendahl <i>et al.</i> (2011a)	9	Xenotransplantation of cryopreserved and thawed ovarian cortex into immunodeficient nude	Premenopausal	OTC patients with HL and NHL	—	NR	0%

Continued

Table VII *Continued*

First author, year	Sample size	Assessment	Menstrual status or age (years)	Characteristics: Study group	Characteristics: Patients with ovarian metastasis	Oncological therapy: Study group	Ovarian metastasis
Schmidt (2004)	1	mice. Histology 4 weeks after xenotransplantation Histological examination of tissue after xenotransplantation into SCID mouse Follow-up: 4 weeks	Premenopausal	OTC patient with B-cell lymphoma stage III of the mediastinum	–	No prior treatment	0%
Clinical studies Harris and Scully (1984)	19	Histological examination of resection specimens or biopsies	≤50	Patients with lymphoma of the uterine endometrium (<i>n</i> = 1), cervix (<i>n</i> = 16) or vagina (<i>n</i> = 2), retrospectively collected from consultation files. FIGO stages cervical lymphoma: Stage I: <i>n</i> = 9; stage 2: <i>n</i> = 6; Stage 3: <i>n</i> = 2 FIGO stages vaginal lymphoma: Stage I: <i>n</i> = 1; Stage IV: <i>n</i> = 1 FIGO stage endometrial lymphoma: Stage III	Case 1: 48-year-old woman with FIGO stage I cervical lymphoma Case 2: 34-year-old woman with FIGO stage III endometrial lymphoma	NR	10.5% (2/19)
Autopsy Kyono et al. (2010)	736	Autopsy	<40	NR	NR	NR	13.3% (98/736) 10.5% (8/76) Age 0–10: 10.7% (15/140) Age 11–20: 13.9% (27/194) Age 21–30: 14.7% (48/326) Age 31–40

OTC, ovarian tissue cryopreservation; HL, Hodgkin's lymphoma; NHL, non-Hodgkin's lymphoma; CT, chemotherapy; NOS, not otherwise specified; NR, not reported.

Table VIII Epidemiological data from leukaemia studies.

First author, year	Sample size	Assessment	Menstrual status or age (years)	Characteristics: Study group	Characteristics: Patients with ovarian metastasis	Oncological therapy: Study group	Ovarian metastasis
Histology or PCR (OTC patients)							
Courbiere et al. (2010)	1	Histology and RQ-PCR	Premenopausal	OTC patient with chronic phase CML	Chronic phase CML	Imatinib	100% (1/1)
Dolmans et al. (2010)	18	Histology and RT-PCR (n = 16)	Premenopausal or prepubertal	OTC patients with: CML: n = 6 ALL: n = 12	CML patients: aged 31 and 30 at OTC. No prior CT. ALL patients: 11–20 years old at OTC. Prior CT: n = 3	Eight patients received chemotherapy before OTC	50% (9/18) CML: 33.3% (2/6) ALL: 58.3% (7/12)
Greve et al. (2012)	25	Histology and PCR (n = 7)	Premenopausal or Prepubertal	OTC patients with: ALL: n = 11 AML: n = 10 CML: n = 3 JMML: n = 1	Four patients with positive PCR but negative histology: CML, chronic phase: n = 2 ALL, complete remission: n = 1 AML, complete remission: n = 1	18 patients received chemotherapy before OTC	16% (4/25)
Meirow et al. (2008)	9	Histology Fresh ovarian tissue: n = 9 PCR and histology on cryopreserved-thawed tissue: n = 2	Premenopausal	OTC patients with: AML: n = 5 Myelodysplastic syndrome: n = 1 CML: n = 3	20-year-old CML patient with positive RT-PCR signal in thawed tissue	All CML and AML patients had CT prior to OTC The MDS patient did not have prior CT	11.1% (1/9) CML: 33% (1/3)
Poirot et al. (2007)	6	Histology Fresh ovarian tissue	Prepubertal	OTC patients with leukaemia (NOS)	–	All underwent several courses of CT before OTC	0%
Rosendahl et al. (2010)	26	Histology/immunohistochemistry and PCR (n = 8)	Premenopausal or prepubertal	OTC patients with: ALL: n = 13 (PCR possible: n = 2) AML: n = 7 (PCR possible: n = 1) CML: n = 5 (PCR possible: n = 5) JMML: n = 1	Six patients with positive PCR results but negative histology: CML in complete remission: n = 1 (Age: 13 years) CML chronic phase: n = 4 (Age: 7, 17, 24, 26 years) ALL in complete remission: n = 2 (Age: 4, 9 years) AML in complete remission: n = 1 (Age: 21 years)	NR	23.1% (6/26) CML: 100% (5/5) ALL: 15.4% (2/13) AML: 14.3% (1/7)
Xenotransplantation							
Dolmans et al. (2010)	18	Xenotransplantation to immunodeficient mice	Premenopausal or prepubertal	OTC patients with: CML: n = 6 ALL: n = 12	ALL patients aged 11–21 at OTC. Prior CT: n = 2; PCR (possible in four patients): all positive	Eight patients received chemotherapy before OTC	27.8% (5/18) CML: 0% (0/6) AML: 41.7% (5/12)
Greve et al. (2012)	25	Histology and PCR (n = 7) of ovarian cortex after 20 weeks of xenotransplantation in immunodeficient mice	Premenopausal or Prepubertal	OTC patients with: ALL: n = 11 AML: n = 10	–	18 patients received chemotherapy before OTC	0% (0/25)

Continued

Table VIII *Continued*

First author, year	Sample size	Assessment	Menstrual status or age (years)	Characteristics: Study group	Characteristics: Patients with ovarian metastasis	Oncological therapy: Study group	Ovarian metastasis
Rosendahl et al. (2011a)	7	Xenotransplantation of cryopreserved and thawed ovarian cortex into immunodeficient nude mice. Histology 4 weeks after xenotransplantation	Premenopausal	CML: <i>n</i> = 3 JMML: <i>n</i> = 1 OTC patients with ALL AML or CML	–	NR	0%
Clinical studies Turial et al. (2009)	> 300	Clinical follow-up (retrospective design)	Prepubertal and premenopausal	Girls treated for ALL	Case 1: Diagnosis pre-B-ALL at age of 3 years. Treatment: CoALL 82-protocol. Bone marrow relapse at 7 and 9 years of age, treated with CT. Age 11: ovarian metastases. Case 2: Diagnosis pre-B-ALL at age of 14 years. Treatment: CoALL 06-97 protocol. After 18 months of remission: ovarian metastases	NR	<0.7% (2/>300)
Autopsy Reid and Marsden (1980)	27	Autopsy	<9	Girls with leukaemia: ALL: <i>n</i> = 12 AML: <i>n</i> = 9 AMML: <i>n</i> = 3 Lym → L: <i>n</i> = 3	ALL: <i>n</i> = 6 AML: <i>n</i> = 6 AMML: <i>n</i> = 3 Lym → L: <i>n</i> = 2	NR	62.3% (17/27)
Kyono et al. (2010)	2027	Autopsy	<40	NR	NR	NR	8.4% (171/2027) 7.9% (31/392) Age 0–10: 10.2% (52/511) Age 11–20: 7.8% (34/438) Age 21–30: 7.9% (54/686) Age 31–40

OTC, ovarian tissue cryopreservation; NR, not reported; CML, chronic myeloid leukaemia; AML, acute myeloid leukaemia; ALL, acute lymphoblastic leukaemia; JMML, juvenile myelomonocytic leukaemia; AMML, acute myelomonocytic leukaemia; LYM → L, leukaemic conversion of lymphoma; NOS, not otherwise specified.

Discussion

Principal findings and implications for clinical practice

This review aimed to gain insight into the risk of recurrent oncological disease, which is added to a cancer survivor's natural risk of cancer recurrence, when ovarian tissue autotransplantation is performed.

Great concern

For some oncological diseases, a relatively high risk of reintroduction of malignant disease by means of autotransplantation could be derived from the literature available. In leukaemia, a clear risk of ovarian involvement and disease recurrence after transplantation has been shown by different methods. Therefore, autotransplantation of ovarian tissue should be considered unsafe in survivors of this blood borne malignancy.

Serious reasons for concern

For other tumour types, the drawing of conclusions based on the available literature proved to be more difficult. Almost exclusively based on clinical and autopsy studies describing populations containing patients with different disease stages, we can conclude that it is justified to have serious concerns about oncological recurrence after ovarian tissue autotransplantation in survivors of gastric or colorectal cancer.

Most clinical studies on the prevalence of ovarian metastases in endometrial cancer were based on populations with different tumour stages and suffered from small sample sizes. Despite this, it is clear that ovarian metastases occur in different endometrial cancer stages, including FIGO I. As two studies concerning these low-stage patients reported contradictory results (Zhou *et al.*, 2005; Pan *et al.*, 2011) clinical decision-making will remain difficult in survivors from endometrial cancer.

Less concern

When it comes to cervical cancer, clinical studies suggest that ovarian involvement is not very common in, especially low-stage, cervical carcinoma patients. Nevertheless, data from histological examination of ovarian tissue are scarce. Although clinical data are reassuring when it comes to autotransplantation safety in patients with low-stage disease, the impact of different histological types of cervical cancer should be further evaluated.

Negative results from histological examination and xenotransplantation of ovarian tissue from breast cancer patients suggest a relatively low risk of disease recurrence in breast cancer survivors who have their ovarian tissue autotransplanted. However, information regarding the influence of different histological types (lobular versus ductal carcinoma) on the risk of ovarian involvement remains scarce. Another factor that might influence the risk of oncological relapse in breast cancer survivors is the restoration of a premenopausal hormonal status after autotransplantation. Although the exact impact of hormonal changes is unknown, they might theoretically play a role in patients with hormone-dependent breast tumours (Yaghjian and Colditz, 2011).

Least concern

Results from histological examination and xenotransplantation of ovarian tissue from patients in a fertility preservation programme suggest a low risk of disease recurrence following autotransplantation in lymphoma survivors. Moreover, follow-up data from ovarian tissue

autotransplantation procedures are reassuring. Although safety can never be guaranteed, ovarian tissue autotransplantation can certainly be considered in lymphoma survivors.

Appropriateness of included studies

Follow-up after ovarian tissue autotransplantation

Reports on autotransplantation procedures are, at least theoretically, the 'Golden standard' when trying to estimate the risk of reintroducing malignancy. In clinical practice, however, we observed that oncological follow-up of cancer survivors is still short and not always described comprehensively. Some patients who had their ovarian tissue transplanted had already received chemotherapy before ovarian tissue harvesting, whilst others had not (Donnez *et al.*, 2006). As chemotherapy might influence the presence of viable cancer cells in the ovarian graft, this factor should be kept in mind when interpreting results.

Although difficulties in determining whether an oncological relapse is due to a reintroduction of tumour cells via the transplant will probably always remain, clinical data may give an indication. For instance, a solid tumour near the transplant is more likely to raise suspicion than a tumour at a distant location. Nevertheless, even with signs of oncological relapse in the area of the transplant, it will be difficult to establish whether or not this is a result of reintroduction of tumour cells via the graft.

Histology, PCR and xenotransplantation

For most types of cancer there is no substitute for microscopic examination of the ovarian cortex (Oktay and Buyuk, 2004). When a cancer cell is found, it is difficult to determine whether this cell is viable and has the capacity to recolonize the patient and cause oncological relapse (Rosendahl *et al.*, 2010). PCR is a highly sensitive technique to detect DNA or RNA from metastatic cells. Unfortunately, only a limited number of tumour types have chromosomal aberrations that provide tumour-specific PCR targets (Jadoul *et al.*, 2010). Another limitation of PCR for the analysis of minimal residual disease is that the detection of tumour-specific DNA or RNA does not necessarily mean that viable cancer cells are present in the ovarian cortex.

Different PCR results may be obtained from different parts of the same tissue fragment (Rosendahl *et al.*, 2010). As the tissue fragment that is being analysed for residual malignant cells can no longer be autotransplanted, this examination does not guarantee safety regarding tumour reintroduction. This so-called 'sample bias' also applies to analysis by histology or xenotransplantation. Xenotransplantation provides a better insight in the viability of the cancer cells present in the graft. However, it is unknown to what extent xenotransplantation results are applicable to the human situation since the recipient animals have a compromised immune system and different strains may lead to different results (Meyer and Debatin, 2011). Finally, as the minimal follow-up period of recipient animals needed for detection of tumour cells in the ovarian tissue has never been specified, some xenotransplantation studies may have missed ovarian involvement due to short follow-up.

Clinical studies and autopsy data

Clinical and autopsy studies provided the largest groups of patients from which an incidence of ovarian involvement in various type of malignancies could be determined. Notwithstanding this important strength, results should be interpreted with caution as they highly depend on the

selection criteria of the particular study as well as on the study group characteristics.

It is almost certain that not all factors influencing ovarian metastasis in patients with a certain type of malignancy are known. For instance, in a multivariate analysis, histological tumour type and blood vessel invasion proved to be independent predictors of ovarian involvement in cervical carcinoma (Yamamoto *et al.*, 2001). For some tumour types, such as gastric cancer, most data originated from a single continent. The impact on ovarian involvement in a certain type of malignancy by ethnical, environmental or cultural factors is, however, largely unknown.

Follow-up of a group of patients with a certain malignancy may lead to the diagnosis of ovarian metastases long after the detection of the primary tumour. It is difficult to determine whether the development of ovarian metastases during follow-up indicates that cancer cells would already have been present at the time of ovarian tissue cryopreservation shortly after diagnosis of the malignancy. This remark holds true for both autopsy and clinical studies.

Implications for future research

An important topic for further research is the development of alternative procedures to avoid transmission of cancer cells via autotransplantation, such as *in vitro* maturation of primordial follicles.

As these alternative procedures have not yet been introduced in clinical practice, future research should also focus on the safety aspects of ovarian tissue autotransplantation. Studies aimed at the detection of cancer cells in the ovarian tissue from patients in a fertility preservation programme should be performed, especially for those cancer types for which data are still scarce.

When it comes to clinical studies, many reports provided only very limited information on patient and disease characteristics of their study population. A more comprehensive registration of these data in future studies would provide better possibilities to compare the characteristics of patients from a particular clinical study with a patient seen in clinical practice.

Implications for fertility preservation choices

Several decades may lie between ovarian tissue harvesting and the actual autotransplantation of the ovarian tissue. During this period, new techniques aimed at avoiding the reseeding of the cancer through the transplant may become available. *In vitro* maturation of primordial follicles, xenografting of ovarian tissue, purging malignant cells from ovarian tissue and transplantation of isolated follicles have all been proposed as future applications that could be combined with cryopreservation of ovarian tissue (Schroder *et al.*, 2004; Dolmans *et al.*, 2008; Sonmezer and Oktay, 2010; Grynberg *et al.*, 2012). Although these techniques have not yet resulted in pregnancies in humans, the approaches may provide salient options to girls and adolescents later in life (Nisker *et al.*, 2006; Jeruss and Woodruff, 2009). For these reasons, one should not refrain from ovarian tissue cryopreservation because of uncertainties regarding autotransplantation safety when it comes to young patients. Obviously, in these instances the patient should be counselled extensively about the possibility that also in the future her cryopreserved tissue may not be safe for autotransplantation.

Registration of autotransplantation procedures

The most reliable data regarding autotransplantation safety will be obtained from the follow-up of cancer survivors after ovarian tissue autotransplantation. This implies that data on the follow-up of all autotransplantations performed globally should be available to all experts in the field. In the current situation, data on adverse outcomes of ovarian tissue autotransplantation might be unavailable to other clinicians due to publication bias. In addition, published information reaches other specialists in the field only after a certain delay. These factors could be overcome by an international database, in which information on all procedures, as well as follow-up, would be registered and kept up-to-date.

Conclusion

Based on current literature, it is advisable to refrain from ovarian tissue autotransplantation in survivors of leukaemia. The safety of autotransplantation should be comprehensively discussed with survivors of all other malignant diseases. The most reassuring data regarding autotransplantation safety were found for lymphoma patients.

Acknowledgements

We would like to thank A.H.J. Tillema, information specialist from the Radboud University Nijmegen University Library, for her efforts in optimizing our electronic search strategy.

Authors' roles

R.P., J.R.W. and L.B. initiated this review. L.B. performed a literature search on the subject. L.B. and R.P. independently performed the study selection and data extraction. Inclusion or exclusion was discussed with C.C.M.B. in case of disagreement. Data analysis and interpretation of results were discussed with C.C.M.B., S.E.J.K., L.F.A.G.M., F.E.L. and D.D.M.B. The manuscript was drafted by L.B. and critically revised by all co-authors. All authors gave final approval of the manuscript.

Funding

The work of R.P. was partially financed by KiKa Foundation.

References

- Abe Y, Takeuchi M, Matsuzaki K, Uehara H, Furumoto H, Nishitani H. A case of metastatic malignant melanoma of the ovary with a multilocular cystic appearance on MR imaging. *Jpn J Radiol* 2009;**27**:458–461.
- Aben KK, van Gaal C, van Gils NA, van der Graaf WT, Zielhuis GA. Cancer in adolescents and young adults (15–29 years): a population-based study in the Netherlands 1989–2009. *Acta Oncol* 2012;**51**:922–933.
- Abir R, Feinmesser M, Yaniv I, Fisch B, Cohen IJ, Ben-Haroush A, Meirou D, Felz C, Avigad S. Occasional involvement of the ovary in Ewing sarcoma. *Hum Reprod* 2010;**25**:1708–1712.
- Adachi Y, Sasagawa I, Nakada T, Saitoh M, Mitobe K, Ohta T, Tanaka M. Bilateral ovarian metastasis from left renal cell carcinoma. *Urol Int* 1994;**52**:169–171.
- Akar M, Oktay K. Restoration of ovarian endocrine function by ovarian transplantation. *Trends Endocrinol Metab* 2005;**16**:374–380.

- Akar ME, Carrillo AJ, Jennell JL, Yalcinkaya TM. Robotic-assisted laparoscopic ovarian tissue transplantation. *Fertil Steril* 2011;**95**:1120 e1125–1120 e1128.
- Akushima-Fukawara Y, Yoshihara A, Ishikawa Y, Watanabe N, Hiroi N, Akasaka Y, Sasano H, Ishii T, Yoshino G. Malignant adrenal rest tumor of the retroperitoneum producing adrenocortical steroids. *Endocr Pathol* 2011;**22**:112–117.
- Anagnostou VK, Tiniakos DG, Chorti M, Kiagia M, Tourkantonis I, Alamara C, Syrigos KN. Right sided renal cell carcinoma metastasizing to the contralateral ovary: case report and review of the literature. *Pathol Oncol Res* 2009;**15**:123–127.
- Andersen CY, Rosendahl M, Byskov AG, Loft A, Ottosen C, Dueholm M, Schmidt KL, Andersen AN, Ernst E. Two successful pregnancies following autotransplantation of frozen/thawed ovarian tissue. *Hum Reprod* 2008;**23**:2266–2272.
- Anderson RA, Wallace WH, Baird DT. Ovarian cryopreservation for fertility preservation: indications and outcomes. *Reproduction* 2008;**136**:681–689.
- Aoki Y, Kase H, Kashima K, Yahata T, Tanaka K. Placental site trophoblastic tumor presenting as subaponeurotic metastasis. *Int J Gynecol Cancer* 2005;**15**:385–388.
- Armon PJ. Burkitt's lymphoma of the ovary in association with pregnancy. Two case reports. *Br J Obstet Gynaecol* 1976;**83**:169–172.
- Ayhan A, Guney I, Saygan-Karamursel B, Taskiran C. Ovarian metastasis of primary biliary and gallbladder carcinomas. *Eur J Gynaecol Oncol* 2001;**22**:377–378.
- Ayhan A, Guvenal T, Salman MC, Ozyuncu O, Sakinci M, Basaran M. The role of cytoreductive surgery in nongenital cancers metastatic to the ovaries. *Gynecol Oncol* 2005;**98**:235–241.
- Azem F, Hasson J, Ben-Yosef D, Kossoy N, Cohen T, Almog B, Amit A, Lessing JB, Lifschitz-Mercer B. Histologic evaluation of fresh human ovarian tissue before cryopreservation. *Int J Gynecol Pathol* 2010;**29**:19–23.
- Bahat G, Colak Y, Saka B, Karan MA, Buyukbabani N. Melanoma metastasis to the breast: a diagnostic pitfall. *Cancer Detect Prev* 2009;**32**:458–461.
- Bastings L, Beerendonk CCM, Westphal JR, Braat DDM, Peek R. Cryopreservation and autotransplantation of ovarian tissue in cancer patients: is it safe? *J Adolesc Young Adult Oncol* 2013;**2**:31–34.
- Belagyi T, Zsoldos P, Makay R, Issekutz A, Olah A. Multiorgan resection (including the pancreas) for metastasis of cutaneous malignant melanoma. *JOP* 2006;**7**:234–240.
- Benito V, Segura J, Martinez MS, Arencibia O, Lubrano A. Fibrolamellar hepatocellular carcinoma metastatic to the ovary. *J Obstet Gynaecol* 2012;**32**:200–202.
- Bittinger SE, Nazaretian SP, Gook DA, Parmar C, Harrup RA, Stern CJ. Detection of Hodgkin lymphoma within ovarian tissue. *Fertil Steril* 2011;**95**:803 e803–803 e806.
- Blamey SL, McDermott FT, Pihl E, Hughes ES. Resected ovarian recurrence from colorectal adenocarcinoma: a study of 13 cases. *Dis Colon Rectum* 1981;**24**:272–275.
- Bloch-Marcotte C, Ambrosetti D, Novellas S, Caramella T, Dahman M, Thyss A, Chevallier P. Ovarian metastasis from choroidal melanoma. *Clin Imaging* 2008;**32**:318–320.
- Blumenfeld D, Berman ML, Kerner H, DiSaia PJ. Unusual metastases from a malignant melanoma. A case report. *J Reprod Med* 1991;**36**:688–690.
- Borgmann-Staudt A, Rendtorff R, Reinmuth S, Hohmann C, Keil T, Schuster FR, Holter W, Ehler K, Keslova P, Lawitschka A et al. Fertility after allogeneic haematopoietic stem cell transplantation in childhood and adolescence. *Bone Marrow Transplant* 2012;**47**:271–276.
- Bott-Kothari T, Aron BS, Bejarano P. Malignant thymoma with metastases to the gastrointestinal tract and ovary: a case report and literature review. *Am J Clin Oncol: Cancer Clin Trials* 2000;**23**:140–142.
- Boutis A, Valeri R, Korantzis I, Valoukas D, Andronikidis I, Andreadis C. Delayed malignant melanoma recurrence simulating primary ovarian cancer: case report. *World J Surg Oncol* 2008;**6**:124.
- Bowlby LS, Smith ML. Signet-ring cell carcinoma of the urinary bladder primary presentation as a Krukenberg tumor. *Gynecol Oncol* 1986;**25**:376–381.
- Brogioni S, Viacava P, Tomisti L, Martino E, Macchia E. A special case of bilateral ovarian metastases in a woman with papillary carcinoma of the thyroid. *Exp Clin Endocrinol Diabetes* 2007;**115**:397–400.
- Brown BL, Scharifker DA, Gordon R, Deppe GG, Cohen CJ. Bronchial carcinoid tumor with ovarian metastasis: a light microscopic and ultrastructural study. *Cancer* 1980;**46**:543–546.
- Bullon A Jr, Young RH, Arseneau J. Tubular Krukenberg tumor. A problem in histopathologic diagnosis. *Am J Surg Pathol* 1981;**5**:225–232.
- Bumpers HL, Hassett JM Jr, Penetrante RB, Hoover EL, Holyoke ED. Endocrine organ metastases in subjects with lobular carcinoma of the breast. *Arch Surg* 1993;**128**:1344–1347.
- Buyukkurt S, Altintas A, Gumurdulu D, Zeren H, Guzel B. Mucoepidermoid carcinoma of the parotid gland with ovarian and peritoneal metastasis. *J Obstet Gynaecol Res* 2008;**34**:271–273.
- Byrn JC, Wang JL, Divino CM, Nguyen SQ, Warner RR. Management of goblet cell carcinoid. *J Surg Oncol* 2006;**94**:396–402.
- Chang TC, Changchien CC, Tseng CW, Lai CH, Tseng CJ, Lin SE, Wang CS, Huang KJ, Chou HH, Ma YY et al. Retrograde lymphatic spread: a likely route for metastatic ovarian cancers of gastrointestinal origin. *Gynecol Oncol* 1997;**66**:372–377.
- Chen KT. Appendiceal adenocarcinoid with ovarian metastasis. *Gynecol Oncol* 1990;**38**:286–288.
- Chen MY, Jung SM, Ng KK, Chang TC. Pulmonary papillary serous adenocarcinoma with intraperitoneal and ovarian tumors: identification of primary site. A case report. *Int J Gynecol Cancer* 2006;**16**(Suppl 1):231–235.
- Courbiere B, Prebet T, Mozziconacci MJ, Metzler-Guillemain C, Saia-Magnan J, Gamarre M. Tumor cell contamination in ovarian tissue cryopreserved before gonadotoxic treatment: should we systematically exclude ovarian autograft in a cancer survivor? *Bone Marrow Transplant* 2010;**45**:1247–1248.
- Cutait R, Lesser ML, Enker WE. Prophylactic oophorectomy in surgery for large-bowel cancer. *Dis Colon Rectum* 1983;**26**:6–11.
- de Groot ME, Dukel L, Chadha-Ajwani S, Metselaar HJ, Tilanus HW, Huikeshoven FJ. Massive solitary metastasis of hepatocellular carcinoma in the ovary two years after liver transplantation. *Eur J Obstet Gynecol Reprod Biol* 2000;**90**:109–111.
- Demeestere I, Simon P, Buxant F, Robin V, Fernandez SA, Centner J, Delbaere A, Englert Y. Ovarian function and spontaneous pregnancy after combined heterotopic and orthotopic cryopreserved ovarian tissue transplantation in a patient previously treated with bone marrow transplantation: case report. *Hum Reprod* 2006;**21**:2010–2014.
- Demeestere I, Simon P, Emiliani S, Delbaere A, Englert Y. Fertility preservation: successful transplantation of cryopreserved ovarian tissue in a young patient previously treated for Hodgkin's disease. *Oncologist* 2007;**12**:1437–1442.
- Demeestere I, Simon P, Moffa F, Delbaere A, Englert Y. Birth of a second healthy girl more than 3 years after cryopreserved ovarian graft. *Hum Reprod* 2010;**25**:1590–1591.
- Demirkiran F, Bese T, Arvas M, Yilmaz O, Ilvan S. Ovarian metastasis from malignant thymoma. *Int J Gynecol Obstet* 2009;**105**:176–177.
- Didolkar MS, Fanous N. Adenocarcinoma of the appendix: a clinicopathologic study. *Dis Colon Rectum* 1977;**20**:130–134.
- Dietrich CS 3rd, Desimone CP, Modesitt SC, Depriest PD, Ueland FR, Pavlik EJ, Kryscio R, Cibull M, Huh W, Partridge E et al. Primary appendiceal cancer: gynecologic manifestations and treatment options. *Gynecol Oncol* 2007;**104**:602–606.
- Dittrich R, Mueller A, Binder H, Oppelt PG, Renner SP, Goecke T, Hoffmann I, Beckmann WM. First retransplantation of cryopreserved ovarian tissue following cancer therapy in Germany. *Dtsch Arztebl Int* 2008;**105**:274–278.
- Dittrich R, Mueller A, Maltaris T, Hoffmann I, Magener A, Oppelt PG, Beckmann MW. Hormonal and histologic findings in human cryopreserved ovarian autografts. *Fertil Steril* 2009;**91**(4 Suppl):1503–1506.
- Dittrich R, Lotz L, Keck G, Hoffmann I, Mueller A, Beckmann MW, van der Ven H, Montag M. Live birth after ovarian tissue autotransplantation following overnight transportation before cryopreservation. *Fertil Steril* 2012;**97**:387–390.
- Dolmans MM, Yuan WY, Camboni A, Torre A, Van Langendonck A, Martinez-Madrid B, Donnez J. Development of antral follicles after xenografting of isolated small human preantral follicles. *Reprod Biomed Online* 2008;**16**:705–711.
- Dolmans MM, Donnez J, Camboni A, Demylle D, Amorim C, Van Langendonck A, Pirard C. IVF. outcome in patients with orthotopically transplanted ovarian tissue. *Hum Reprod* 2009;**24**:2778–2787.
- Dolmans MM, Marinescu C, Saussoy P, Van Langendonck A, Amorim C, Donnez J. Reimplantation of cryopreserved ovarian tissue from patients with acute lymphoblastic leukemia is potentially unsafe. *Blood* 2010;**116**:2908–2914.
- Domergue J, Ismail M, Astre C, Saint-Aubert B, Joyeux H, Solassol C, Pujol H. Colorectal carcinoma in patients younger than 40 years of age. Montpellier Cancer Institute experience with 78 patients. *Cancer* 1988;**61**:835–840.
- Donnez J, Dolmans MM. Preservation of fertility in females with hematological malignancy. *Br J Haematol* 2011;**154**:175–184.
- Donnez J, Dolmans MM, Demylle D, Jadoul P, Pirard C, Squifflet J, Martinez-Madrid B, van Langendonck A. Livebirth after orthotopic transplantation of cryopreserved ovarian tissue. *Lancet* 2004;**364**:1405–1410.

- Donnez J, Martinez-Madrid B, Jadoul P, Van Langendonck A, Demille D, Dolmans MM. Ovarian tissue cryopreservation and transplantation: a review. *Hum Reprod Update* 2006;**12**:519–535.
- Donnez J, Squifflet J, Van Eyck AS, Demille D, Jadoul P, Van Langendonck A, Dolmans MM. Restoration of ovarian function in orthotopically transplanted cryopreserved ovarian tissue: a pilot experience. *Reprod Biomed Online* 2008;**16**:694–704.
- Donnez J, Jadoul P, Pirard C, Hutchings G, Demille D, Squifflet J, Smits J, Dolmans MM. Live birth after transplantation of frozen-thawed ovarian tissue after bilateral oophorectomy for benign disease. *Fertil Steril* 2012;**98**:720–725.
- Dunder E, Tel N, Ozalp SS, Isiksoy S, Kabukcuoglu S, Bal C. The significance of local cellular immune response of women 50 years of age and younger with endometrial carcinoma. *Eur J Gynaecol Oncol* 2002;**23**:243–246.
- Dunsmore KP, Lovell MA. Small bowel adenocarcinoma metastatic to the ovaries in a 12-year-old girl. *J Pediatr Hematol Oncol* 1998;**20**:498–501.
- Elhajj M, Mazurka J, Daya D. Desmoplastic small round cell tumor presenting in the ovaries: report of a case and review of the literature. *Int J Gynecol Cancer* 2002;**12**:760–763.
- Eltabbakh GH, Belinson JL, Biscotti CV. Osteosarcoma metastatic to the ovary: a case report and review of the literature. *Int J Gynecol Pathol* 1997;**16**:76–78.
- Epperson JW. Case of the reticulum cell variety of lymphosarcoma involving the female genitalia. *West J Surg Obstet Gynecol* 1950;**58**:701–703.
- Ernst E, Bergholdt S, Jorgensen JS, Andersen CY. The first woman to give birth to two children following transplantation of frozen/thawed ovarian tissue. *Hum Reprod* 2010;**25**:1280–1281.
- Evans-Metcalf ER, Brooks SE, Reale FR, Baker SP. Profile of women 45 years of age and younger with endometrial cancer. *Obstet Gynecol* 1998;**91**:349–354.
- Fang X, Rodabaugh K, Penetrante R, Wong M, Wagner T, Sait S, Mhawech-Fauceglia P. Desmoplastic small round cell tumor (DSRCT) with ovarian involvement in 2 young women. *Appl Immunohistochem Mol Morphol* 2008;**16**:94–99.
- Farhi DC, Nosanchuk J, Silverberg SG. Endometrial adenocarcinoma in women under 25 years of age. *Obstet Gynecol* 1986;**68**:741–745.
- Feigin E, Abir R, Fisch B, Kravarusic D, Steinberg R, Nitke S, Avrahami G, Ben-Haroush A, Freud E. Laparoscopic ovarian tissue preservation in young patients at risk for ovarian failure as a result of chemotherapy/irradiation for primary malignancy. *J Pediatr Surg* 2007;**42**:862–864.
- Fenzl V, Prkacin I, Skrtic A. Malignant melanoma ovarian metastasis mimicking acute tuboovarian abscess. *Eur J Gynaecol Oncol* 2011;**32**:582–584.
- Fichera AP, Petty WM, Park RC, Muir RW. Primary adenocarcinoma of the vermiform appendix in a gynecologic patient. *Am J Obstet Gynecol* 1976;**124**:663–664.
- Finkle HI, Goldman RL. Burkitt's lymphoma—gynecologic considerations. *Obstet Gynecol* 1974;**43**:281–284.
- Fitzgibbons PL, Martin SE, Simmons TJ. Malignant melanoma metastatic to the ovary. *Am J Surg Pathol* 1987;**11**:959–964.
- Forsgren L, Molin K, Rieger A. Adenocarcinoma of the vermiform appendix. *Acta Chir Scand* 1974;**140**:486–490.
- Fossa SD, Schjolseth SA, Miller A. Multiple urothelial tumours with metastases to uterus and left ovary. A case report. *Scand J Urol Nephrol* 1977;**11**:81–84.
- Gadd CB, Hellsten H, Knutson F. Masculinovoblastoma (adrenal-like tumour). A rare virilizing ovarian tumour. *Acta Obstet Gynecol Scand* 1960;**39**:239–258.
- Gamble HA 2nd. Adenocarcinoma of the appendix: an unusual case and review. *Dis Colon Rectum* 1976;**19**:621–625.
- Garcia A, De la Torre J, Castelli J, Gil A, Lopez M. Ovarian metastases caused by cholangiocarcinoma: a rare Krukenberg's tumour simulating a primary neoplasm of the ovary: a two-case study. *Arch Gynecol Obstet* 2004;**270**:281–284.
- Gitsch G, Hanzal E, Jensen D, Hacker NF. Endometrial cancer in premenopausal women 45 years and younger. *Obstet Gynecol* 1995;**85**:504–508.
- Gonzalez MS, Hammond DO. Malignant melanoma in the ovary with ultrastructural confirmation. *Am J Obstet Gynecol* 1983;**147**:722–724.
- Gosnell JE, Maa J, Clark OH, Duh QY. Medullary thyroid carcinoma manifesting as an ovarian mass: case report and review of literature. *Endocr Pract* 2008;**14**:351–357.
- Green LK, Silva EG. Hepatoblastoma in an adult with metastasis to the ovaries. *Am J Clin Pathol* 1989;**92**:110–115.
- Greve T, Clasen-Linde E, Andersen MT, Andersen MK, Sorensen SD, Rosendahl M, Ralfkiaer E, Yding Andersen C. Cryopreserved ovarian cortex from patients with leukemia in complete remission contains no apparent viable malignant cells. *Blood* 2012;**120**:4311–4316.
- Grynberg M, Poulain M, Sebag-Peyrelevede S, le Parco S, Fanchin R, Frydman N. Ovarian tissue and follicle transplantation as an option for fertility preservation. *Fertil Steril* 2012;**97**:1260–1268.
- Gupta S, Padmanabhan A, Khanna S. Malignant hemangiopericytoma of the gallbladder. *J Surg Oncol* 1983;**22**:171–174.
- Gupta D, Deavers MT, Silva EG, Malpica A. Malignant melanoma involving the ovary: a clinicopathologic and immunohistochemical study of 23 cases. *Am J Surg Pathol* 2004;**28**:771–780.
- Habek D, Marton I, Bauman R, Prka M, Bobic MV. Ruptured ovarian metastatic malignant melanoma caused acute abdomen. *Central Eur J Med* 2012;**7**:241–244.
- Hachisuga T, Kawarabayashi T, Hirakawa T, Fukuda K. The effect of being overweight on survival in endometrioid carcinoma of the endometrium at different ages. *Int J Gynecol Cancer* 2000;**10**:228–232.
- Hahn GA. Gynecologic considerations in malignant lymphomas. *Am J Obstet Gynecol* 1958;**75**:673–681; discussion 681–673.
- Halpin TF. Gynecologic implications of Burkitt's tumor. *Obstet Gynecol Surv* 1975;**30**:351–358.
- Hammock L, Ghorab Z, Gomez-Fernandez CR. Metastatic renal cell carcinoma to the ovary: a case report and discussion of differential diagnoses. *Arch Pathol Lab Med* 2003;**127**:e123–e126.
- Hanprasertpong J, Sakolprakrakij S, Geater A. Endometrial cancer in Thai women aged 45 years or younger. *Asian Pac J Cancer Prev* 2008;**9**:58–62.
- Haqqani MT, Williams G. Mucin producing carcinoid tumours of the vermiform appendix. *J Clin Pathol* 1977;**30**:473–480.
- Harris NL, Scully RE. Malignant lymphoma and granulocytic sarcoma of the uterus and vagina. A clinicopathologic analysis of 27 cases. *Cancer* 1984;**53**:2530–2545.
- Hasegawa S, Ohshima S, Kinukawa T, Matsuura O, Takeuchi Y, Hattori R, Murakami S. Adenocarcinoma of the bladder 29 years after ileocystoplasty. *Hinyokika Kyo* 1989;**35**:671–674.
- Hermann GG, Fogh J, Graem N, Hansen OP, Hippe E. Primary hemangiosarcoma of the spleen with angioscintigraphic demonstration of metastases. *Cancer* 1984;**53**:1682–1685.
- Hesketh KT. The management of primary adenocarcinoma of the vermiform appendix. *Gut* 1963;**4**:158–168.
- Himelstein-Braw R, Peters H, Faber M. Influence of irradiation and chemotherapy on the ovaries of children with abdominal tumours. *Br J Cancer* 1977;**36**:269–275.
- Hirono M, Taniyama K, Matsuki K, Nakagami K, Niimoto M, Hattori T. Clinico-pathological studies on ovarian metastasis from gastric cancer. *Jpn J Surg* 1983;**13**:25–31.
- Hirschfield LS, Kahn LB, Winkler B, Bochner RZ, Gibstein AA. Adenocarcinoid of the appendix presenting as bilateral Krukenberg's tumor of the ovaries. Immunohistochemical and ultrastructural studies and literature review. *Arch Pathol Lab Med* 1985;**109**:930–933.
- Householder J, Han A, Edelson MI, Eager JM, Rosenblum NG. Immunohistochemical confirmation of pulmonary papillary adenocarcinoma metastatic to ovaries. *Arch Pathol Lab Med* 2002;**126**:1101–1103.
- Howarth CB, Caces JN, Pratt CB. Breast metastases in children with rhabdomyosarcoma. *Cancer* 1980;**46**:2520–2524.
- Hristov AC, Young RH, Vang R, Yemelyanova AV, Seidman JD, Ronnett BM. Ovarian metastases of appendiceal tumors with goblet cell carcinoidlike and signet ring cell patterns: a report of 30 cases. *Am J Surg Pathol* 2007;**31**:1502–1511.
- Hsiu JG, Kemp GM, Singer GA, Rawls WH, Siddiky MA. Transitional cell carcinoma of the renal pelvis with ovarian metastasis. *Gynecol Oncol* 1991;**41**:178–181.
- Husain S, Thompson D, Thomas L, Donaldson B, Sabbagh R. Adnexal mass: an unusual presentation of small-bowel adenocarcinoma. *J Natl Med Assoc* 2006;**98**:799–802.
- Huser M, Crha I, Hudecek R, Ventruha P, Zakova J, Smardova L, Kral Z. Ovarian tissue cryopreservation—new opportunity to preserve fertility in female cancer patients. *Eur J Gynaecol Oncol* 2007;**28**:249–255.
- Huysentruyt CJ, Vandevijver NM, Jan van Suylen R, Van de Vijver KK. Adenocarcinoma of the fetal lung-type metastatic to the ovary. *Int J Gynecol Pathol* 2010;**29**:339–340.
- Ikeda E, Tsutsumi Y, Yoshida H, Yanagi K. Goblet cell carcinoid of the vermiform appendix with ovarian metastasis mimicking mucinous cystadenocarcinoma. *Acta Pathol Jpn* 1991;**41**:455–460.
- Imachi M, Tsukamoto N, Amagase H, Shigematsu T, Amada S, Nakano H. Metastatic adenocarcinoma to the uterine cervix from gastric cancer. A clinicopathologic analysis of 16 cases. *Cancer* 1993;**71**:3472–3477.
- Insabato L, De Rosa G, Franco R, D'Onofrio V, Di Vizio D. Ovarian metastasis from renal cell carcinoma: a report of three cases. *Int J Surg Pathol* 2003;**11**:309–312.

- Irving JA, Young RH. Lung carcinoma metastatic to the ovary: a clinicopathologic study of 32 cases emphasizing their morphologic spectrum and problems in differential diagnosis. *Am J Surg Pathol* 2005;**29**:997–1006.
- Ishii Y, Itoh N, Takahashi A, Masumori N, Ikeda T, Tsukamoto T. Bladder cancer discovered by ovarian metastasis: cytokeratin expression is useful when making differential diagnosis. *Int J Urol* 2005;**12**:104–107.
- Jadoul P, Dolmans MM, Donnez J. Fertility preservation in girls during childhood: is it feasible, efficient and safe and to whom should it be proposed? *Hum Reprod Update* 2010;**16**:617–630.
- Jain V, Gupta K, Kudva R, Rodrigues GS. A case of ovarian metastasis of gall bladder carcinoma simulating primary ovarian neoplasm: diagnostic pitfalls and review of literature. *Int J Gynecol Cancer* 2006;**16**(Suppl 1):319–321.
- Janse F, Donnez J, Anckaert E, de Jong FH, Fauser BC, Dolmans MM. Limited value of ovarian function markers following orthotopic transplantation of ovarian tissue after gonadotoxic treatment. *J Clin Endocrinol Metab* 2011;**96**:1136–1144.
- Jeremic K, Berisavac M, Argirovic R, Gojnic M, Boskovic V, Milenkovic V, Mostic T. Solitary ovarian metastasis from cutaneous melanoma—case report. *Eur J Gynaecol Oncol* 2006;**27**:443–444.
- Jeruss JS, Woodruff TK. Preservation of fertility in patients with cancer. *N Engl J Med* 2009;**360**:902–911.
- Jindal G, Rastogi R, Kachhawa S, Meena GL. CT findings of primary extra-intestinal gastrointestinal stromal tumor of greater omentum with extensive peritoneal and bilateral ovarian metastases. *Indian J Cancer* 2011;**48**:135–137.
- Kaku T, Matsuo K, Tsukamoto N, Shimamoto T, Sugihara K, Tsuruchi N, To N, Kamura T, Saito T, Imachi M et al. Endometrial carcinoma in women aged 40 years or younger: a Japanese experience. *Int J Gynecol Cancer* 1993;**3**:147–153.
- Kashani M, Levy M. Primary adenocarcinoma of the appendix with bilateral Krukenberg ovarian tumors. *J Surg Oncol* 1983;**22**:101–105.
- Khalifa MA, Hansen CH, Moore JL Jr, Rusnock EJ, Lage JM. Endometrial stromal sarcoma with focal smooth muscle differentiation: recurrence after 17 years: a follow-up report with discussion of the nomenclature. *Int J Gynecol Pathol* 1996;**15**:171–176.
- Khunamornpong S, Siriaunkgul S, Suprasert P, Pojchamarnwiputh S, Na Chiangmai W, Young RH. Intrahepatic cholangiocarcinoma metastatic to the ovary: a report of 16 cases of an underemphasized form of secondary tumor in the ovary that may mimic primary neoplasia. *Am J Surg Pathol* 2007;**31**:1788–1799.
- Khunamornpong S, Lerwill MF, Siriaunkgul S, Suprasert P, Pojchamarnwiputh S, Chiangmai WN, Young RH. Carcinoma of extrahepatic bile ducts and gallbladder metastatic to the ovary: a report of 16 cases. *Int J Gynecol Pathol* 2008;**27**:366–379.
- Kim SS. Ovarian tissue banking for cancer patients. To do or not to do? *Hum Reprod* 2003;**18**:1759–1761.
- Kim SS. Assessment of long term endocrine function after transplantation of frozen-thawed human ovarian tissue to the heterotopic site: 10 year longitudinal follow-up study. *J Assist Reprod Genet* 2012;**29**:489–493.
- Kim NK, Kim HK, Park BJ, Kim MS, Kim YI, Heo DS, Bang YJ. Risk factors for ovarian metastasis following curative resection of gastric adenocarcinoma. *Cancer* 1999;**85**:1490–1499.
- Kim SS, Radford J, Harris M, Varley J, Rutherford AJ, Lieberman B, Shalet S, Gosden R. Ovarian tissue harvested from lymphoma patients to preserve fertility may be safe for autotransplantation. *Hum Reprod* 2001;**16**:2056–2060.
- Kim SS, Hwang IT, Lee HC. Heterotopic autotransplantation of cryobanked human ovarian tissue as a strategy to restore ovarian function. *Fertil Steril* 2004;**82**:930–932.
- Kim MJ, Chung HH, Kim JW, Park NH, Song YS, Kang SB. Uterine corpus involvement as well as histologic type is an independent predictor of ovarian metastasis in uterine cervical cancer. *J Gynecol Oncol* 2008;**19**:181–184.
- Kim SS, Lee WS, Chung MK, Lee HC, Lee HH, Hill D. Long-term ovarian function and fertility after heterotopic autotransplantation of cryobanked human ovarian tissue: 8-year experience in cancer patients. *Fertil Steril* 2009;**91**:2349–2354.
- Kodama J, Hasengaowa, Kusumoto T, Seki N, Matsuo T, Nakamura K, Hongo A, Hiramatsu Y. Versican expression in human cervical cancer. *Eur J Cancer* 2007;**43**:1460–1466.
- Kolp LA, Hubayter Z. Autotransplantation of cryopreserved ovarian tissue: a procedure with promise, risks, and a need for a registry. *Fertil Steril* 2011;**95**:1879–1886.
- Konishi H, Isetani K, Satoh T, Fukuda S, Kodama T, Kashima K. A case of metastatic chondrosarcoma of the stomach. *J Gastroenterol* 1994;**29**:495–500.
- Konje JC, Otolurin EO, Odukoya OA, Ladipo OA, Ogunniyi J. Burkitts lymphoma of the ovary in Nigerian adults—a 27-year review. *Afr J Med Med Sci* 1989;**18**:301–305.
- Kumar Y, Chahal A, Garg M, Bhutani A. Occult gallbladder carcinoma presenting as a primary ovarian tumor in two women: two case reports and a review of the literature. *J Med Case Reports* 2010;**4**:202.
- Kyono K, Doshida M, Toya M, Sato Y, Akahira J, Sasano H. Potential indications for ovarian autotransplantation based on the analysis of 5,571 autopsy findings of females under the age of 40 in Japan. *Fertil Steril* 2010;**93**:2429–2430.
- La Rosa S, Marando A, Ghezzi F, Colombo P, Finzi G, Capella C. Cushing's Syndrome due to a Pancreatic neuroendocrine tumor metastatic to the ovaries: a clinicopathological description of a case. *Endocr Pathol* 2011;**22**:118–124.
- Lan C, Li Y, He J, Liu J. Placental site trophoblastic tumor: lymphatic spread and possible target markers. *Gynecol Oncol* 2010;**116**:430–437.
- Landoni F, Zanagnolo V, Lovato-Diaz L, Maneo A, Rossi R, Gadducci A, Cosio S, Maggino T, Sartori E, Tisi C et al. Ovarian metastases in early-stage cervical cancer (IA2-IIA): a multicenter retrospective study of 1965 patients (a Cooperative Task Force study). *Int J Gynecol Cancer* 2007;**17**:623–628.
- Larsen EC, Muller J, Schmiegelow K, Rechnitzer C, Andersen AN. Reduced ovarian function in long-term survivors of radiation- and chemotherapy-treated childhood cancer. *J Clin Endocrinol Metab* 2003;**88**:5307–5314.
- Lashgari M, Behmaram B, Hoffman JS, Garcia J. Primary biliary carcinoma with metastasis to the ovary. *Gynecol Oncol* 1992;**47**:272–274.
- Lawrenz B, Jauckus J, Kupka MS, Strowitzki T, von Wolff M. Fertility preservation in >1,000 patients: patient's characteristics, spectrum, efficacy and risks of applied preservation techniques. *Arch Gynecol Obstet* 2011;**283**:651–656.
- Lecca U, Medda F, Marcello C. Ovarian metastasis in breast cancer. *Eur J Gynaecol Oncol* 1980;**1**:168–174.
- Lee TS, Jung JY, Kim JW, Park NH, Song YS, Kang SB, Lee HP. Feasibility of ovarian preservation in patients with early stage endometrial carcinoma. *Gynecol Oncol* 2007;**104**:52–57.
- Lee SJ, Bae JH, Lee AW, Tong SY, Park YG, Park JS. Clinical characteristics of metastatic tumors to the ovaries. *J Korean Med Sci* 2009;**24**:114–119.
- Lee JH, Park S, Park HS, Park BW. Clinicopathological features of infiltrating lobular carcinomas comparing with infiltrating ductal carcinomas: a case control study. *World J Surg Oncol* 2010a;**8**:34.
- Lee M, Jung YW, Kim SW, Kim SH, Kim YT. Metastasis to the ovaries from transitional cell carcinoma of the bladder and renal pelvis: a report of two cases. *J Gynecol Oncol* 2010b;**21**:59–61.
- Lee JM, Park KM, Lee SY, Choi J, Hwang DW, Lee YJ. Metastasis of hepatocellular carcinoma to the ovary: a case report and review of the literature. *Gut Liver* 2011;**5**:543–547.
- Lerwill M, Young R. Metastatic tumors of the ovary. In: Kurman R, Ellenson L, Ronnett B (eds). *Blaustein's Pathology of the Female Genital Tract*. Berlin: Springer Science+Business Media, 2011.
- Lesnick G, Miller D. Adenocarcinoma of the appendix. *Cancer* 1949;**2**:18–24.
- Liang R, Chiu E, Loke SL. Non-Hodgkin's lymphomas involving the female genital tract. *Hematol Oncol* 1990;**8**:295–299.
- Liu FS, Ho ES, Lu F, Chang CY. Solitary metastasis of renal cell carcinoma to the ovaries: a case report. *Zhonghua Yi Xue Za Zhi (Taipei)* 1992;**50**:165–168.
- Logani S, Baloch ZW, Snyder PJ, Weinstein R, LiVolsi VA. Cystic ovarian metastasis from papillary thyroid carcinoma: a case report. *Thyroid* 2001;**11**:1073–1075.
- Loke TK, Lo SS, Chan CS. Case report: Krukenberg tumours arising from a primary duodenojejunal adenocarcinoma. *Clin Radiol* 1997;**52**:154–155.
- Longacre TA, O'Hanlan K, Hendrickson MR. Adenoid cystic carcinoma of the submandibular gland with symptomatic ovarian metastases. *Int J Gynecol Pathol* 1996;**15**:349–355.
- Low JJ, Chew SH, Chew SP, Han CC, Tay EH, Ho TH. A rare case of metastatic ovarian carcinoma originating from primary intrahepatic cholangiocarcinoma. Case report. *Eur J Gynaecol Oncol* 2003;**24**:85–88.
- MacKeigan JM, Ferguson JA. Prophylactic oophorectomy and colorectal cancer in premenopausal patients. *Dis Colon Rectum* 1979;**22**:401–405.
- Maekawa H, Sato K, Komatsu Y, Orita H, Sakurada M. Jejunal cancer detected after a resection of bilateral ovarian metastasis: report of a case. *Surg Today* 2010;**40**:1084–1087.
- Malviya VK, Bansal M, Chahinian P, Deppe G, Lauersen N, Gordon RE. Small cell anaplastic lung cancer presenting as an ovarian metastasis. *Int J Gynaecol Obstet* 1982;**20**:487–493.

- Mandai M, Konishi I, Tsuruta Y, Suginami N, Kusakari T, Iwasaki T, Fujii S. Krukenberg tumor from an occult appendiceal adenocarcinoid: a case report and review of the literature. *Eur J Obstet Gynecol Reprod Biol* 2001;**97**:90–95.
- Martinelli G, Tapparelli E, Merz R, Aldovini D, Zumiani G. Case of bilateral ovarian metastasis from regressed melanoma. *Eur J Gynaecol Oncol* 1984;**5**:150–153.
- McBroom JW, Parker MF, Krivak TC, Rose GS, Crothers B. Primary appendiceal malignancy mimicking advanced stage ovarian carcinoma: a case series. *Gynecol Oncol* 2000;**78**(3 Pt 1):388–390.
- McCarville MB, Hill DA, Miller BE, Pratt CB. Secondary ovarian neoplasms in children: imaging features with histopathologic correlation. *Pediatr Radiol* 2001;**31**:358–364.
- Meirow D. Fertility preservation in cancer patients using stored ovarian tissue: clinical aspects. *Curr Opin Endocrinol Diabetes Obes* 2008;**15**:536–547.
- Meirow D, Ben Yehuda D, Prus D, Poliack A, Schenker JG, Rachmilewitz EA, Lewin A. Ovarian tissue banking in patients with Hodgkin's disease: is it safe? *Fertil Steril* 1998;**69**:996–998.
- Meirow D, Levron J, Eldar-Geva T, Hardan I, Fridman E, Zalel Y, Schiff E, Dor J. Pregnancy after transplantation of cryopreserved ovarian tissue in a patient with ovarian failure after chemotherapy. *N Engl J Med* 2005;**353**:318–321.
- Meirow D, Baum M, Yaron R, Levron J, Hardan I, Schiff E, Nagler A, Yehuda DB, Raanani H, Hourvitz A et al. Ovarian tissue cryopreservation in hematologic malignancy: ten years' experience. *Leuk Lymphoma* 2007a;**48**:1569–1576.
- Meirow D, Levron J, Eldar-Geva T, Hardan I, Fridman E, Yemini Z, Dor J. Monitoring the ovaries after autotransplantation of cryopreserved ovarian tissue: endocrine studies, in vitro fertilization cycles, and live birth. *Fertil Steril* 2007b;**87**:418 e417–418 e415.
- Meirow D, Hardan I, Dor J, Fridman E, Elizur S, Ra'anani H, Slyusarevsky E, Amariglio N, Schiff E, Rechavi G et al. Searching for evidence of disease and malignant cell contamination in ovarian tissue stored from hematologic cancer patients. *Hum Reprod* 2008;**23**:1007–1013.
- Merino MJ, Edmonds P, LiVolsi V. Appendiceal carcinoma metastatic to the ovaries and mimicking primary ovarian tumors. *Int J Gynecol Pathol* 1985;**4**:110–120.
- Meyer WH, Yu GW, Milvenan ES, Jeffs RD, Kaizer H, Leventhal BG. Ovarian involvement in neuroblastoma. *Med Pediatr Oncol* 1979;**7**:49–54.
- Meyer LH, Debatin KM. Diversity of human leukemia xenograft mouse models: implications for disease biology. *Cancer Res* 2011;**71**:7141–7144.
- Milicevic S, Bozanovic T, Vilendacic Z, Lazovic G, Kastratovic Kotlica B, Atanackovic J, Bajcetic M. Solitary ovarian mass: a case of metastatic malignant melanoma. *Eur J Gynaecol Oncol* 2008;**29**:93–94.
- Milingos D, Doumplis D, Savage P, Seckl M, Lindsay I, Smith JR. Placental site trophoblastic tumor with an ovarian metastasis. *Int J Gynecol Cancer* 2007;**17**:925–927.
- Miller RT, Sarikaya H, Jenison EL. Adenocarcinoid tumor of appendix presenting as unilateral Krukenberg tumor. *J Surg Oncol* 1988;**37**:65–71.
- Mills M, Rindfuss RR, McDonald P, te Velde E. Why do people postpone parenthood? Reasons and social policy incentives. *Hum Reprod Update* 2011;**17**:848–860.
- Miyagui T, Luchemback L, Teixeira GH, de Azevedo KM. Meningeal carcinomatosis as the initial manifestation of a gallbladder adenocarcinoma associated with a Krukenberg tumor. *Rev Hosp Clin Fac Med Sao Paulo* 2003;**58**:169–172.
- Miyauchi J, Kiyotani C, Shioda Y, Kumagai M, Honna T, Matsuoka K, Masaki H, Aiba M, Hata J, Tsunematsu Y. Unusual chromaffin cell differentiation of a neuroblastoma after chemotherapy and radiotherapy: report of an autopsy case with immunohistochemical evaluations. *Am J Surg Pathol* 2004;**28**:548–553.
- Moayedoddin B, Booya F, Wermers RA, Lloyd RV, Rubin J, Thompson GB, Fatourech V. Spectrum of malignant somatostatin-producing neuroendocrine tumors. *Endocr Pract* 2006;**12**:394–400.
- Moher D, Liberati A, Tetzlaff J, Altman DG. Preferred reporting items for systematic reviews and meta-analyses: the PRISMA statement. *PLoS Med* 2009;**6**:e1000097.
- Montag M, Liebenthron J, van der Ven H. http://www.fertiprotekt.de/admin/upload/office/register_2011_website.ppt#258,9,Folie.
- Montero A, Allende H, Tallada N, Cajal SR, Margarit C, Viladomiu L. Fine needle aspiration cytology of massive bilateral ovarian metastasis of fibrolamellar hepatocellular carcinoma [10]. *Acta Cytol* 2007;**51**:682–683.
- Monterroso V, Jaffe ES, Merino MJ, Medeiros LJ. Malignant lymphomas involving the ovary. A clinicopathologic analysis of 39 cases. *Am J Surg Pathol* 1993;**17**:154–170.
- Morgan S, Anderson RA, Gourley C, Wallace WH, Spears N. How do chemotherapeutic agents damage the ovary? *Hum Reprod Update* 2012;**18**:525–535.
- Morice P, Juncker L, Rey A, El-Hassan J, Haie-Meder C, Castaigne D. Ovarian transposition for patients with cervical carcinoma treated by radiosurgical combination. *Fertil Steril* 2000;**74**:743–748.
- Morice P, Haie-Meder C, Pautier P, Lhomme C, Castaigne D. Ovarian metastasis on transposed ovary in patients treated for squamous cell carcinoma of the uterine cervix: report of two cases and surgical implications. *Gynecol Oncol* 2001;**83**:605–607.
- Moselhi M, Spencer J, Lane G. Malignant melanoma metastatic to the ovary: presentation and radiological characteristics. *Gynecol Oncol* 1998;**69**:165–168.
- Moshfeghi DM, Wilson MW, Haik BG, Hill DA, Rodriguez-Galindo C, Pratt CB. Retinoblastoma metastatic to the ovary in a patient with Waardenburg syndrome. *Am J Ophthalmol* 2002;**133**:716–718.
- Muller A, Keller K, Wacker J, Dittrich R, Keck G, Montag M, Van der Ven H, Wachter D, Beckmann MW, Distler W. Retransplantation of cryopreserved ovarian tissue: the first live birth in Germany. *Dtsch Arztebl Int* 2012;**109**:8–13.
- Murphy DJ, Hickling DJ, Pathak UN. Metastatic malignant melanoma of the ovary. Case report. *Eur J Gynaecol Oncol* 1994;**15**:119–120.
- Nakanishi T, Wakai K, Ishikawa H, Nawa A, Suzuki Y, Nakamura S, Kuzuya K. A comparison of ovarian metastasis between squamous cell carcinoma and adenocarcinoma of the uterine cervix. *Gynecol Oncol* 2001;**82**:504–509.
- Nakano J, Shimizu T, Hirota T, Muto M. An unusual female melanoma patient with late metastases to both skin and ovaries. *J Dermatol* 1998;**25**:126–128.
- Natsume N, Aoki Y, Kase H, Kashima K, Sugaya S, Tanaka K. Ovarian metastasis in stage IB and II cervical adenocarcinoma. *Gynecol Oncol* 1999;**74**:255–258.
- Nelson GA, Dockerty MB, Pratt JH, Remine WH. Malignant lymphoma involving the ovaries. *Am J Obstet Gynecol* 1958;**76**:861–871.
- Nelson BE, Carcangiu ML, Chambers JT. Intraabdominal hemorrhage with pulmonary large cell carcinoma metastatic to the ovary. *Gynecol Oncol* 1992;**47**:377–381.
- Nisker J, Baylis F, McLeod C. Choice in fertility preservation in girls and adolescent women with cancer. *Cancer* 2006;**107**(7 Suppl):1686–1689.
- Niwa Y, Kawai M, Kotani M, Shibata D, Wakahara Y, Kakihara M, Arii Y. Endometrial carcinoma in women under 40 years of age: Incidence of ovarian carcinoma and ovarian metastasis. *Int J Clin Oncol* 2000;**5**:109–115.
- Nugent SL, Dim DC, Bridge JA, Ioffe OB. Clear cell sarcoma of soft tissue metastatic to the ovaries: a heretofore unreported occurrence. *Int J Gynecol Pathol* 2009;**28**:234–238.
- Oberg KC, Wells K, Seraj IM, Garberoglio CA, Akin MR. ACTH-secreting islet cell tumor of the pancreas presenting as bilateral ovarian tumors and Cushing's syndrome. *Int J Gynecol Pathol* 2002;**21**:276–280.
- Oktay K. Spontaneous conceptions and live birth after heterotopic ovarian transplantation: is there a germline stem cell connection? *Hum Reprod* 2006;**21**:1345–1348.
- Oktay K, Buyuk E. Ovarian transplantation in humans: indications, techniques and the risk of reseeded cancer. *Eur J Obstet Gynecol Reprod Biol* 2004;**113**(Suppl 1):S45–S47.
- Oktay K, Oktem O. Ovarian cryopreservation and transplantation for fertility preservation for medical indications: report of an ongoing experience. *Fertil Steril* 2010;**93**:762–768.
- Oktay K, Buyuk E, Vecek L, Zaninovic N, Xu K, Takeuchi T, Opsahl M, Rosenwaks Z. Embryo development after heterotopic transplantation of cryopreserved ovarian tissue. *Lancet* 2004;**363**:837–840.
- Oktay K, Turkcuoglu I, Rodriguez-Wallberg KA. Four spontaneous pregnancies and three live births following subcutaneous transplantation of frozen banked ovarian tissue: what is the explanation? *Fertil Steril* 2011;**95**:e807–e808 e810.
- Oliva E, Musulen E, Prat J, Young RH. Transitional cell carcinoma of the renal pelvis with symptomatic ovarian metastases. *Int J Surg Pathol* 1995;**2**:231–236.
- Olsson B, Ljungberg O. Adenocarcinoid of the vermiform appendix. *Virchows Arch A Pathol Anat Histol* 1980;**386**:201–210.
- Oortman EH, Elliott JP. Hepatocellular carcinoma metastatic to the ovary: a case report. *Am J Obstet Gynecol* 1983;**146**:715–717.
- Osborne BM, Robboy SJ. Lymphomas or leukemia presenting as ovarian tumors. An analysis of 42 cases. *Cancer* 1983;**52**:1933–1943.
- Ota S, Ushijima K, Fujiyoshi N, Fujimoto T, Hayashi R, Murakami F, Komai K, Fujiyoshi K, Hori D, Kamura T. Desmoplastic small round cell tumor in the ovary: Report of two cases and literature review. *J Obstet Gynaecol Res* 2010;**36**:430–434.
- Pahisa J, Martinez-Roman S, Martinez-Zamora MA, Torne A, Caparros X, Sanjuan A, Lejarcegui JA. Laparoscopic ovarian transposition in patients with early cervical cancer. *Int J Gynecol Cancer* 2008;**18**:584–589.
- Pan Z, Wang X, Zhang X, Chen X, Xie X. Retrospective analysis on coexisting ovarian cancer in 976 patients with clinical stage I endometrial carcinoma. *J Obstet Gynaecol Res* 2011;**37**:352–358.

- Paone JF, Bixler TJ 2nd, Imbembo AL. Primary mucinous adenocarcinoma of the appendix with bilateral Krukenberg ovarian tumors. *Johns Hopkins Med J* 1978; **143**:43–47.
- Parente JT, Silberblatt W, Stone M. Infrequency of metastasis to ovaries in stage I carcinoma of the cervix. *Am J Obstet Gynecol* 1964;**90**:1362.
- Parker LP, Duong JL, Wharton JT, Malpica A, Silva EG, Deavers MT. Desmoplastic small round cell tumor: Report of a case presenting as a primary ovarian neoplasm. *Eur J Gynaecol Oncol* 2002;**23**:199–202.
- Pearson CM, Fitzgerald PJ. Carcinoid tumors; a re-emphasis of their malignant nature; review of 140 cases. *Cancer* 1949;**2**:1005–1026, illust.
- Pecorelli S. Revised FIGO staging for carcinoma of the vulva, cervix, and endometrium. *Int J Gynaecol Obstet* 2009;**105**:103–104.
- Petru E, Pickel H, Heydarfadaei M, Lahousen M, Haas J, Schaidt H, Tamussino K. Nongenital cancers metastatic to the ovary. *Gynecol Oncol* 1992;**44**:83–86.
- Pitluk H, Poticha SM. Carcinoma of the colon and rectum in patients less than 40 years of age. *Surg Gynecol Obstet* 1983;**157**:335–337.
- Piura B, Kedar I, Ariad S, Meirovitz M, Yanai-Inbar I. Malignant melanoma metastatic to the ovary. *Gynecol Oncol* 1998;**68**:201–205.
- Poirot CJ, Martelli H, Genestie C, Golmard JL, Valteau-Couanet D, Helardot P, Pacquement H, Sauvart F, Tabone MD, Philippe-Chomette P et al. Feasibility of ovarian tissue cryopreservation for prepubertal females with cancer. *Pediatr Blood Cancer* 2007;**49**:74–78.
- Powell ED, Macdonald DB, Elkeilani AM, Asmis TR. A case of appendiceal adenocarcinoma with clinical benefit from FOLFOX and bevacizumab. *Case Rep Oncol* 2009;**2**:111–115.
- Pudasaini S, Lakhey M, Hirachand S, Akhter J, Thapa B. A study of ovarian cyst in a tertiary hospital of Kathmandu valley. *Nepal Med Coll J* 2011;**13**:39–41.
- Pusioli T, Franceschetti I, Scialpi M, Piscioi I, Sassi C, Parolari AM. Incidental necrotizing paratubal granuloma associated with multiple neoplasms. *J Gynecol Surg* 2011;**27**:29–32.
- Qizilbash AH. Primary adenocarcinoma of the appendix. A clinicopathological study of 11 cases. *Arch Pathol* 1975;**99**:556–562.
- Quinn MA, Kneale BJ, Fortune DW. Endometrial carcinoma in premenopausal women: a clinicopathological study. *Gynecol Oncol* 1985;**20**:298–306.
- Quint EH, Smith YR. Ovarian surgery in premenarchal girls. *J Pediatr Adolesc Gynecol* 1999;**12**:27–29.
- Radford JA, Lieberman BA, Brison DR, Smith AR, Critchlow JD, Russell SA, Watson AJ, Clayton JA, Harris M, Gosden RG et al. Orthotopic reimplantation of cryopreserved ovarian cortical strips after high-dose chemotherapy for Hodgkin's lymphoma. *Lancet* 2001;**357**:1172–1175.
- Reid H, Marsden HB. Gonadal infiltration in children with leukemia and lymphoma. *J Clin Pathol* 1980;**33**:722–729.
- Remadi S, McGee WV, Egger JF, Ismail A. Ovarian metastatic melanoma. A diagnostic pitfall in histopathologic examination. *Arch Anat Cytol Pathol* 1997;**45**:43–46.
- Revel A, Revel-Vilk S, Aizenman E, Porat-Katz A, Safran A, Ben-Meir A, Weintraub M, Shapira M, Achaiche H, Laufer N. At what age can human oocytes be obtained? *Fertil Steril* 2009;**92**:458–463.
- Rey-Caballero VE, Lopez-Gonzalez B, Garcia-Benitez JL, Boix-Fos A, Diaz-Lagama AM. Solitary ovarian metastasis from ocular melanoma. *Am J Obstet Gynecol* 2004;**191**:368–369.
- Robboy SJ, Scully RE, Norris HJ. Carcinoid metastatic to the ovary. A clinicopathologic analysis of 35 cases. *Cancer* 1974;**33**:798–811.
- Roberts WC. A unique heart disease associated with a unique cancer: carcinoid heart disease. *Am J Cardiol* 1997;**80**:251–256.
- Roley KM, Reza Hafez G, Buchler DA. The consequences of unsuspected secondary ovarian neoplasia: a clinical presentation of four case histories. *Gynecol Oncol* 1990;**36**:277–280.
- Rosas-Urbe A, Luna MA. Primary signet ring cell carcinoma of the urinary bladder. Report of two cases. *Arch Pathol* 1969;**88**:294–297.
- Rosendahl M, Loft A, Byskov AG, Ziebe S, Schmidt KT, Andersen AN, Ottosen C, Andersen CY. Biochemical pregnancy after fertilization of an oocyte aspirated from a heterotopic autotransplant of cryopreserved ovarian tissue: case report. *Hum Reprod* 2006;**21**:2006–2009.
- Rosendahl M, Andersen MT, Ralfkiaer E, Kjeldsen L, Andersen MK, Andersen CY. Evidence of residual disease in cryopreserved ovarian cortex from female patients with leukemia. *Fertil Steril* 2010;**94**:2186–2190.
- Rosendahl M, Schmidt KT, Ernst E, Rasmussen PE, Loft A, Byskov AG, Andersen AN, Andersen CY. Cryopreservation of ovarian tissue for a decade in Denmark: a view of the technique. *Reprod Biomed Online* 2011a;**22**:162–171.
- Rosendahl M, Timmermans Wielenga V, Nedergaard L, Kristensen SG, Ernst E, Rasmussen PE, Anderson M, Schmidt KT, Andersen CY. Cryopreservation of ovarian tissue for fertility preservation: no evidence of malignant cell contamination in ovarian tissue from patients with breast cancer. *Fertil Steril* 2011b;**95**:2158–2161.
- Rotmensch J, Woodruff JD. Lymphoma of the ovary: report of twenty new cases and update of previous series. *Am J Obstet Gynecol* 1982;**143**:870–875.
- Sanchez M, Novella-Maestre E, Teruel J, Ortiz E, Pellicer A. The valencia programme for fertility preservation. *Clin Transl Oncol* 2008;**10**:433–438.
- Sanchez-Serrano M, Novella-Maestre E, Rosello-Sastre E, Camarasa N, Teruel J, Pellicer A. Malignant cells are not found in ovarian cortex from breast cancer patients undergoing ovarian cortex cryopreservation. *Hum Reprod* 2009;**24**:2238–2243.
- Sanchez-Serrano M, Crespo J, Mirabet V, Cobo AC, Escriba MJ, Simon C, Pellicer A. Twins born after transplantation of ovarian cortical tissue and oocyte vitrification. *Fertil Steril* 2010;**93**:268 e211–268 e263.
- Santeusano G, Ventura L, Mauriello A, Carosi M, Spagnoli LG, Maturo P, Terranova L, Romanini C. Isolated ovarian metastasis from a spindle cell malignant melanoma of the choroid 14 years after enucleation: prognostic implication of the keratin immunophenotype. *Appl Immunohistochem Mol Morphol* 2000;**8**:329–333.
- Sbitti Y, Fadoukhair Z, Oukabli M, Essaidi I, Kharmoum S, HMR, Kadiri H, Albouzi A, Ichou M, Errihani H. Diagnostic challenge for ovarian malignant melanoma in premenopausal women: Primary or metastatic? *World J Surg Oncol* 2011;**9**:65.
- Schmidt KL, Andersen CY, Loft A, Byskov AG, Ernst E, Andersen AN. Follow-up of ovarian function post-chemotherapy following ovarian cryopreservation and transplantation. *Hum Reprod* 2005;**20**:3539–3546.
- Schmidt KT, Rosendahl M, Ernst E, Loft A, Andersen AN, Dueholm M, Ottosen C, Andersen CY. Autotransplantation of cryopreserved ovarian tissue in 12 women with chemotherapy-induced premature ovarian failure: the Danish experience. *Fertil Steril* 2011;**95**:695–701.
- Schmidt KL, Yding Andersen C, Starup J, Loft A, Byskov AG, Nyboe Andersen A. Orthotopic autotransplantation of cryopreserved ovarian tissue to a woman cured of cancer—follicular growth, steroid production and oocyte retrieval. *Reprod Biomed Online* 2004;**8**:448–453.
- Schroder CP, Timmer-Bosscha H, Wijchman JG, de Leij LF, Hollema H, Heineman MJ, de Vries EG. An in vitro model for purging of tumour cells from ovarian tissue. *Hum Reprod* 2004;**19**:1069–1075.
- Seshadri T, Gook D, Lade S, Spencer A, Grigg A, Tiedemann K, McKendrick J, Mitchell P, Stern C, Seymour JF. Lack of evidence of disease contamination in ovarian tissue harvested for cryopreservation from patients with Hodgkin lymphoma and analysis of factors predictive of oocyte yield. *Br J Cancer* 2006;**94**:1007–1010.
- Shaw JM, Bowles J, Koopman P, Wood EC, Trounson AO. Fresh and cryopreserved ovarian tissue samples from donors with lymphoma transmit the cancer to graft recipients. *Hum Reprod* 1996;**11**:1668–1673.
- Shet T, Parage M, Maheshwari A, Nair R, Gupta S, Tongaonkar H, Chinoy R. Epithelioid trophoblastic tumor of uterus presenting as an ovarian mass: a diagnostic and therapeutic dilemma. *Indian J Pathol Microbiol* 2008;**51**:242–244.
- Shuhaila A, Rohaizak M, Phang KS, Mahdy ZA. Maternal melanoma with placental metastasis. *Singapore Med J* 2008;**49**:e71–e72.
- Shuster M, Mendoza-Divino E, Joselson H. Carcinoid tumor metastasizing to the ovaries. *Obstet Gynecol* 1970;**36**:515–519.
- Silber S, Kagawa N, Kuwayama M, Gosden R. Duration of fertility after fresh and frozen ovary transplantation. *Fertil Steril* 2010;**94**:2191–2196.
- Silveira E, Palhares FA, De Oliveira Filho JA, Alberti O Jr, Alberti VN, Silveira MI. Peritonitis following rupture of metastatic malignant melanoma of the ovary. *Gynecol Oncol* 1977;**5**:305–307.
- Singh S, Gupta P, Khanna R, Khanna AK. Simultaneous breast and ovarian metastasis from gallbladder carcinoma. *Hepatobiliary Pancreatic Dis Int* 2010;**9**:553–554.
- Skinner MA, Schlatter MG, Heifetz SA, Grosfeld JL. Ovarian neoplasms in children. *Arch Surg* 1993;**128**:849–853; discussion 853–844.
- Soliman OM, el-Bolkainy N, Mansour A, Sherif M. Ovarian metastases from carcinoma of the bilateral urinary bladder. *Int Surg* 1976;**61**:364–365.
- Somjee S, Kurkure PA, Chinoy RF, Deshpande RK, Advani SH. Metastatic ovarian neuroblastoma: a case report. *Pediatr Hematol Oncol* 1999;**16**:459–462.

- Sonmezer M, Oktay K. Fertility preservation in female patients. *Hum Reprod Update* 2004;**10**:251–266.
- Sonmezer M, Oktay K. Orthotopic and heterotopic ovarian tissue transplantation. *Best Pract Res Clin Obstet Gynaecol* 2010;**24**:113–126.
- Sonmezer M, Shamonki MI, Oktay K. Ovarian tissue cryopreservation: benefits and risks. *Cell Tissue Res* 2005;**322**:125–132.
- Spatz A, Zimmermann U, Bachollet B, Pautier P, Michel G, Duvalard P. Malignant blue nevus of the vulva with late ovarian metastasis. *Am J Dermatopathol* 1998;**20**:408–412.
- Spencer JR, Eriksen B, Garnett JE. Metastatic renal tumor presenting as ovarian clear cell carcinoma. *Urology* 1993;**41**:582–584.
- Stern CJ, Toledo MG, Hale LG, Gook DA, Edgar DH. The first Australian experience of heterotopic grafting of cryopreserved ovarian tissue: evidence of establishment of normal ovarian function. *Aust N Z J Obstet Gynaecol* 2011;**51**:268–275.
- Stippel DL, Kasper HU, Schleimer K, Tox U, Bangard C, Holscher AH, Beckurts KT. Successful use of sirolimus in a patient with bulky ovarian metastasis of hepatocellular carcinoma after liver transplantation. *Transplant Proc* 2005;**37**:2185–2187.
- Sty JR, Kun LE, Casper JT. Bone scintigraphy in neuroblastoma with ovarian metastasis. *Wis Med J* 1980;**79**:28–29.
- Subbuswamy SG, Gibbs NM, Ross CF, Morson BC. Goblet cell carcinoid of the appendix. *Cancer* 1974;**34**:338–344.
- Sukumvanich P, Einstein M, Wagner B, Gucalp R, Goldberg GL. Recurrent small cell lung cancer presenting as bilateral adnexal masses. *Gynecol Oncol* 2005;**96**:232–234.
- Sullivan HC, Shulman SC, Olson T, Ricketts R, Oskouei S, Shehata BM. Unusual presentation of metastatic Ewing sarcoma to the ovary in a 13 year-old: a case report and review. *Fetal Pediatr Pathol* 2012;**31**:159–163.
- Tan A, Lau PH. Sonography of primary adenocarcinoma of the appendix with pathological correlation. *Am J Gastroenterol* 1983;**78**:488–492.
- Timofeev J, Galgano MT, Stoler MH, Lachance JA, Modesitt SC, Jazaeri AA. Appendiceal pathology at the time of oophorectomy for ovarian neoplasms. *Obstet Gynecol* 2010;**116**:1348–1353.
- Tjalma WA, Schatteman E, Goovaerts G, Verkinderen L, Van-den Borre F, Keersmaekers G. Adenocarcinoid of the appendix presenting as a disseminated ovarian carcinoma: report of a case. *Surg Today* 2000;**30**:78–81.
- Tripathi R, Sharma B, Chaturvedi KU, Khurana N, Mala YM. Granulocytic sarcoma of the female genital tract: report of a case with an unusual presentation. *Gynecol Obstet Invest* 2005;**59**:189–191.
- Tsuruchi N, Kubota H, Tsukamoto N, Kurano A. Primary jejunal adenocarcinoma masquerading as a primary ovarian malignancy. *Gynecol Oncol* 1995;**58**:129–132.
- Tural S, Karabul N, Gutjahr P, Engel V, Bierschock S, Schier F. Ovarian tumours: late extramedullary recurrence of acute leukaemia. *Eur J Pediatr Surg* 2009;**19**:184–186.
- Variakojis D, Archer FL, Feldman SA, Moody RA. Rapidly progressing adenoid cystic carcinoma. *Arch Otolaryngol* 1970;**92**:90–93.
- Vasiljevic M, Stanojevic D, Djukic M, Hajric A. Leiomyosarcoma of the uterine corpus with ovarian metastases in a 28-year-old woman: case report. *Eur J Gynaecol Oncol* 2008;**29**:98–100.
- Walsh C, Holschneider C, Hoang Y, Tieu K, Karlan B, Cass I. Coexisting ovarian malignancy in young women with endometrial cancer. *Obstet Gynecol* 2005;**106**:693–699.
- Wilson R. Primary carcinoma of the appendix. *Am J Surg* 1962;**104**:238–249.
- Winfield HL, De Las Casas LE, Greenfield WW, Santin AD, McKenney JK. Low-grade fibromyxoid sarcoma presenting clinically as a primary ovarian neoplasm: a case report. *Int J Gynecol Pathol* 2007;**26**:173–176.
- Woodruff JD, Noli C, Novak ER. Lymphoma of the ovary. A study of 35 cases from the Ovarian Tumor Registry of the American Gynecological Society. *Am J Obstet Gynecol* 1963;**85**:912–918.
- Wysocki A, Lejman W, Bobrzynski A. Abdominal malignancies missed during laparoscopic cholecystectomy. *Surg Endosc* 2001;**15**:959–961.
- Xue WC, Guan XY, Ngan HY, Shen DH, Khoo US, Cheung AN. Malignant placental site trophoblastic tumor: a cytogenetic study using comparative genomic hybridization and chromosome in situ hybridization. *Cancer* 2002;**94**:2288–2294.
- Yaghjian L, Colditz GA. Estrogens in the breast tissue: a systematic review. *Cancer Causes Control* 2011;**22**:529–540.
- Yamamoto R, Okamoto K, Yukiharu T, Kaneuchi M, Negishi H, Sakuragi N, Fujimoto S. A study of risk factors for ovarian metastases in stage Ib-IIIb cervical carcinoma and analysis of ovarian function after a transposition. *Gynecol Oncol* 2001;**82**:312–316.
- Yamazawa K, Seki K, Matsui H, Kihara M, Sekiya S. Prognostic factors in young women with endometrial carcinoma: a report of 20 cases and review of literature. *Int J Gynecol Cancer* 2000;**10**:212–222.
- Yamazawa K, Matsui H, Ishikura H, Seki K, Mitsuhashi A, Sekiya S. Significance of perivascular lymphocytic infiltrates on survival of patients with invasive cervical cancer. *J Immunother* 2003;**26**:149–155.
- Yanai H, Matsuura H, Sonobe H, Shiozaki S, Kawabata K. Perivascular epithelioid cell tumor of the jejunum. *Pathol Res Pract* 2003;**199**:47–50.
- Yilmaz A, Rush DS, Soslow RA. Endometrial stromal sarcomas with unusual histologic features: a report of 24 primary and metastatic tumors emphasizing fibroblastic and smooth muscle differentiation. *Am J Surg Pathol* 2002;**26**:1142–1150.
- Yook JH, Oh ST, Kim BS. Clinical prognostic factors for ovarian metastasis in women with gastric cancer. *Hepatogastroenterology* 2007;**54**:955–959.
- Yoshida A, Shigematsu T, Mori H, Yoshida H, Fukunishi R. Non-invasive thymoma with widespread blood-borne metastasis. *Virchows Arch A Pathol Anat Histol* 1981;**390**:121–126.
- Young RH, Scully RE. Ovarian metastases from cancer of the lung: problems in interpretation—a report of seven cases. *Gynecologic Oncology* 1985;**21**:337–350.
- Young RH, Scully RE. Alveolar rhabdomyosarcoma metastatic to the ovary. A report of two cases and a discussion of the differential diagnosis of small cell malignant tumors of the ovary. *Cancer* 1989;**64**:899–904.
- Young RH, Scully RE. Sarcomas metastatic to the ovary: a report of 21 cases. *Int J Gynecol Pathol* 1990;**9**:231–252.
- Young RH, Scully RE. Malignant melanoma metastatic to the ovary. A clinicopathologic analysis of 20 cases. *Am J Surg Pathol* 1991;**15**:849–860.
- Young RH, Hart WR. Renal cell carcinoma metastatic to the ovary: a report of three cases emphasizing possible confusion with ovarian clear cell adenocarcinoma. *Int J Gynecol Pathol* 1992;**11**:96–104.
- Young RH, Eichhorn JH, Dickersin GR, Scully RE. Ovarian involvement by the intra-abdominal desmoplastic small round cell tumor with divergent differentiation: a report of three cases. *Hum Pathol* 1992a;**23**:454–464.
- Young RH, Gersell DJ, Clement PB, Scully RE. Hepatocellular carcinoma metastatic to the ovary: a report of three cases discovered during life with discussion of the differential diagnosis of hepatoid tumors of the ovary. *Hum Pathol* 1992b;**23**:574–580.
- Young RH, Kozakewich HP, Scully RE. Metastatic ovarian tumors in children: a report of 14 cases and review of the literature. *Int J Gynecol Pathol* 1993;**12**:8–19.
- Young RH, Jackson A, Wells M. Ovarian metastasis from thyroid carcinoma 12 years after partial thyroidectomy mimicking struma ovarii: report of a case. *Int J Gynecol Pathol* 1994;**13**:181–185.
- Yu L, Li X, Yang W. Pulmonary blastoma metastatic to the ovary. *Int J Gynecol Pathol* 2009;**28**:59–62.
- Zaloudek C, Miller TR, Stern JL. Desmoplastic small cell tumor of the ovary: a unique polyphenotypic tumor with an unfavorable prognosis. *Int J Gynecol Pathol* 1995;**14**:260–265.
- Zhou FZ, Chen YN, Zhang GN. Ovarian metastasis in patient with endometrial carcinoma. *Chin J Cancer Res* 2005;**17**:230–234.
- Ziegler JL, Miller DG. Lymphosarcoma resembling the Burkitt tumor in a Connecticut girl. *J Am Med Assoc* 1966;**198**:1071–1073.