

# Stent distortion after sutureless aortic valve implantation: a new complication seen with a novel surgical technique

Felix Fleissner<sup>a,\*</sup>, Ulrich Molitoris<sup>b</sup>, Malakh Shrestha<sup>a</sup> and Andreas Martens<sup>a</sup>

<sup>a</sup> Department of Cardiothoracic, Transplantation and Vascular Surgery, Hannover Medical School, Hannover, Germany

<sup>b</sup> Department of Anaesthesiology, Hannover Medical School, Hannover, Germany

\* Corresponding author. Division of Cardiothoracic, Transplantation and Vascular Surgery, Hannover Medical School, Hannover, Germany. Tel: +49-511-5322184; fax: +49-511-5329833; e-mail: fleissner.felix@mh-hannover.de (F. Fleissner).

Received 5 August 2014; received in revised form 7 November 2014; accepted 25 November 2014

## Abstract

In recent years, sutureless aortic valves have grown in popularity. As these valves do not need to be anchored with sutures, shorter cardiac ischaemia and extracorporeal circulation times can potentially be achieved. In addition, the absence of a sewing ring in these valves results in a greater effective orifice area for any given size. Postoperative outcome may be improved using sutureless valves especially when combined with minimally invasive surgical techniques. However, sutureless aortic valves present unique surgical risks. We report 2 cases of delayed distortion of a sutureless aortic valve stent resulting in paravalvular leakage and increased transvalvular gradients. One patient underwent a reoperation with an aortic valve replacement using a standard biological aortic valve, the other patient was treated with balloon dilatation of the aortic valve stent.

**Keywords:** Biological aortic valve replacement • Sutureless valves • Balloon dilatation

## INTRODUCTION

Aortic valve replacement has been the gold standard for the treatment of symptomatic aortic valve stenosis for decades. However, a significant part of the cardiac ischaemia time during open repair is taken up by the placement and tying of sutures. With the introduction of sutureless valves [1], it has been postulated that cardiac ischaemia and extracorporeal circulation times can be reduced significantly and postoperative outcome may be improved [2]. They usually provide a greater effective orifice area and lower transvalvular gradients for any given size due to the absence of a sewing ring [2], resulting in better valve haemodynamics and possibly preventing patient-prosthesis mismatch in selected cases [3]. As a result, sutureless aortic valves are being increasingly implanted in elderly patients with small aortic annuli [3]. However, sutureless valves have an increased risk of paravalvular leakage (PVL). We report on 2 cases in which PVL was caused by delayed distortion of the sutureless aortic valve stent.

## CASE DESCRIPTION

### Case 1

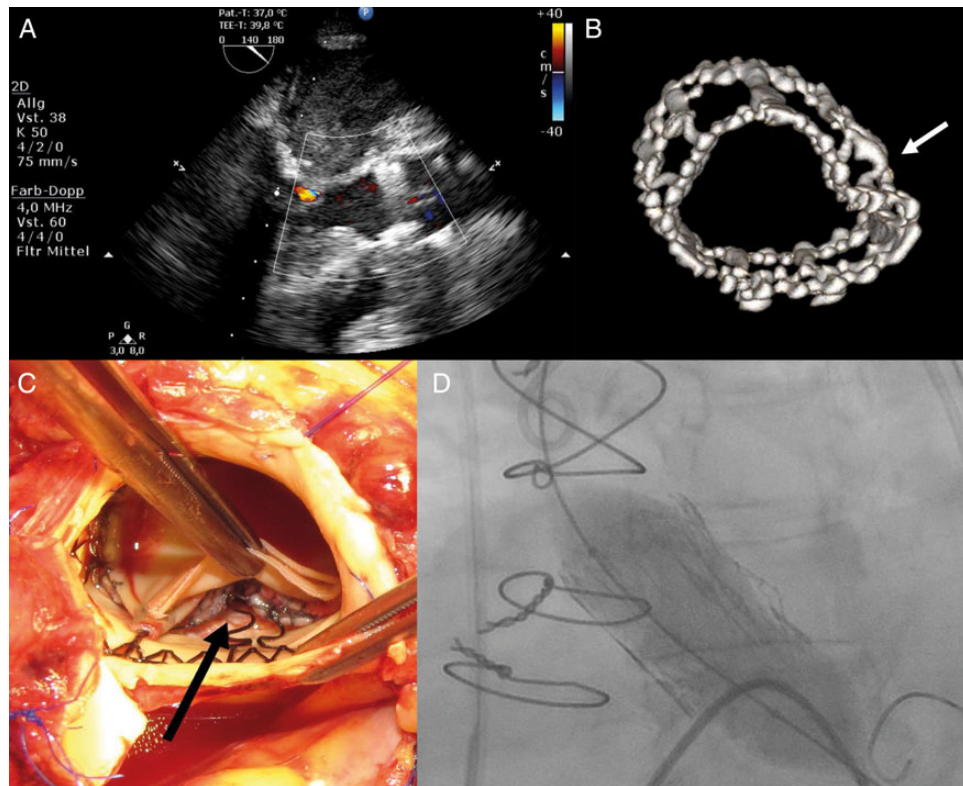
The first patient was a 75-year old female presenting in New York Heart Association-Classification (NYHA) class III with severe aortic valve stenosis with an aortic annulus diameter of 21 mm [aortic valve area (AVA) 0.70 cm<sup>2</sup>]. (For subsequent information about Case 1, see [Supplementary material](#)). The operation was performed via right anterolateral thoracotomy. Aortic annulus

diameter was measured to be 21 mm. The patient received a Perceval S sutureless aortic valve size M (21 mm ≤ aortic annulus diameter <23 mm). Per routine, the prosthesis was checked visually after crimping, after deployment and after post-dilatation according to the manufacturer's protocol. Each sinus of the aortic annulus was checked individually for correct stent alignment and symmetric positioning. A water test was performed to rule out significant transvalvular or PVL. The intraoperative control echocardiography showed normal valve function. The early postoperative course was uneventful.


The patient was readmitted to the intensive care unit on the third postoperative day (POD) due to respiratory failure and low cardiac output syndrome. Transoesophageal echocardiography (TOE) showed a transvalvular gradient of 50/24 mmHg (max/mean) and a moderate-to-severe trans- and paravalvular aortic insufficiency (AI). The patient was reoperated immediately. On inspection, the aortic valve stent was seen to have inwardly kinked at the non-coronary sinus (Fig. 1) resulting in insufficient alignment. The sutureless valve was replaced using a conventional biological aortic valve prosthesis (SJM Trifecta, size 21 mm). Postoperative transthoracic echocardiography (TTE) showed normal aortic valve function [transvalvular gradient 26/14 mmHg (max/mean); no AI]. The postoperative course was prolonged due to pneumonia, respiratory failure and renal insufficiency.

### Case 2

The second patient was an 81-year old female presenting in NYHA class III with a calcified aortic valve with an aortic annulus



**Figure 1:** (A) Intraoperative TOE showing a patent valve, fully expanded in the correct position. (B) CT scan of a Perceval S sutureless valve showing postoperative valve distortion. A 3D reconstruction: the arrow marks the stent kinking at the non-coronary sinus. (C) Operative site of the first patient after aortotomy. The stent distortion after sutureless aortic valve implantation is clearly seen (arrow). (D) Balloon dilatation of the bioprosthetic sutureless valve. CT: computed tomography.



**Figure 2:** (A and B) Perceval S sizer, Size M: (A) the body of the sizer that has to pass into the LVOT has a diameter of 21 mm, (B) the cone-shaped tip has a diameter of ~20 mm. (C) Perceval S sutureless aortic valve, Size M: explanted valve from Case 1. The proximal ring of the valve has a diameter of 26 mm.

diameter of 19 mm (AVA of 0.66 cm<sup>2</sup>) and good left ventricular function. (For subsequent information about Case 2, see [Supplementary material](#)). The operation was performed via upper hemi-sternotomy. The aortic valve annulus size was 19 mm and the patient received a Perceval S sutureless aortic valve size S (19 mm ≤ aortic annulus diameter < 21 mm). Routine valve dilatation was performed. Correct positioning of the valve was confirmed as described for Case 1. Intraoperative control TOE showed a minor PVL (AI 0-I, non-coronary sinus) and a transvalvular gradient of 24/12 mmHg (max/mean). The postoperative course was uneventful. Unexpectedly, routine TTE on POD 8 showed a

transvalvular gradient of 42/25 mmHg (max/mean). TOE confirmed this finding and showed a moderate trans- and paravalvular AI. Computed tomography (CT) revealed a stent distortion at the non-coronary sinus.

We decided to perform an interventional balloon dilatation of the bioprosthesis. Invasive pressure measurement before dilatation showed a gradient of 50/32 mmHg (max/mean). The valve was dilated using a 22 × 40 mm Nucleus balloon (pfm medical, Cologne, Germany). Subsequent echocardiography revealed an AVA of 1.3 cm<sup>2</sup>, a transvalvular gradient of 25/12 mmHg (max/mean) and no PVL.

## DISCUSSION

Sutureless valves represent a major technical advance in aortic valve surgery [1]. The broader use of sutureless aortic valves in recent years has led to improved outcomes especially in elderly patients with small aortic roots [2]. Significant PVL is a dreaded complication after sutureless valve implantation that usually is caused by incomplete decalcification or undersizing [4, 5].

The cases presented here have identified a so far unreported problem that may occur in patients receiving these novel devices. Despite uneventful implantation, careful valve inspection and intraoperative TOE control, delayed stent distortion within the first days after surgery may result in PVL and increased transvalvular gradients. Until now, we have not identified other patients with this problem. We estimate that delayed stent distortion has to be anticipated in 1–2% of all patients treated with this valve type.

We believe that relative oversizing is the reason for this complication in patients in which the aortic annulus has a size that corresponds to the lower size range of the implanted sutureless valve. Under non-beating heart conditions during valve implantation, the flexible stent of the sutureless valve seems to be able to maintain a correct position within the aortic annulus even if oversized. With additional forces acting on the stent during the postoperative course under beating heart conditions, the oversized stent might bend inward in a delayed fashion during postoperative course.

In addition, the valve sizers used have a cone-shaped tip (–1 mm) and therefore may fit into a slightly smaller annulus (Fig. 2). In both our cases, the corresponding sizer had a tight fit but could be advanced through the aortic annulus into the left ventricle. This might inadvertently have resulted in an additional oversizing. Both relative under- and oversizing may result in PVL and poor valvular performance. Additional decalcification may be a feasible option to implant the larger sized valve. If sizing is unclear, the implantation of a different valve model should be considered.

In summary, correct sizing in sutureless aortic valve implantation is crucial. Intra- and postoperative echocardiography controls are

essential. If elevated gradients or a significant PVL is detected, we propose a high-resolution CT scan to rule out delayed stent distortion of the prosthesis. Subsequent interventional correction is feasible and should be considered in high-risk patients.

As with every new surgical technique, unforeseen complications can occur. With more of these novel valves implanted, the cardiac surgery society has to be aware of the described problem and how it may be prevented and treated.

## SUPPLEMENTARY MATERIAL

Supplementary material is available at *ICVTS* online.

## ACKNOWLEDGEMENT

We thank Julian Widder (Department of Angiology and Cardiology) for performing the balloon valvuloplasty.

**Conflict of interest:** none declared.

## REFERENCES

- [1] Flameng W, Herregods MC, Hermans H, Van der Mieren G, Vercalsteren M, Poortmans G *et al.* Effect of sutureless implantation of the Perceval S aortic valve bioprosthesis on intraoperative and early postoperative outcomes. *J Thorac Cardiovasc Surg* 2011;142:1453–7.
- [2] Santarpino G, Pfeiffer S, Concistre G, Grossmann I, Hinzmann M, Fischlein T. The Perceval S aortic valve has the potential of shortening surgical time: does it also result in improved outcome? *Ann Thorac Surg* 2013;96:77–81.
- [3] Bonderman D, Graf A, Kammerlander AA, Kocher A, Laufer G, Lang IM *et al.* Factors determining patient-prosthesis mismatch after aortic valve replacement—a prospective cohort study. *PLoS One* 2013;8:e81940.
- [4] Miceli A, Santarpino G, Pfeiffer S, Murzi M, Gilmanov D, Concistre G *et al.* Minimally invasive aortic valve replacement with Perceval S sutureless valve: early outcomes and one-year survival from two European centers. *J Thorac Cardiovasc Surg* 2014;148:2838–43.
- [5] Folliguet TA, Laborde F, Zannis K, Ghorayeb G, Haverich A, Shrestha M. Sutureless perceval aortic valve replacement: results of two European centers. *Ann Thorac Surg* 2012;93:1483–8.