Interactive CardioVascular and Thoracic Surgery 22 (2016) 208–215
doi:10.1093/icvts/ivv315 Advance Access publication 18 November 2015



Cite this article as: Cantinotti M, Giordano R, Volpicelli G, Kutty S, Murzi B, Assanta N *et al*. Lung ultrasound in adult and paediatric cardiac surgery: is it time for routine use? Interact CardioVasc Thorac Surg 2016;22:208–15.

# Lung ultrasound in adult and paediatric cardiac surgery: is it time for routine use?

**Massimiliano Cantinotti[a], Raffaele Giordano[a,*], Giovanni Volpicelli[b], Shelby Kutty[c], Bruno Murzi[a], Nadia Assanta[a] and Luna Gargani[d]**

[a] Fondazione G. Monasterio CNR - Regione Toscana, Massa and Pisa, Italy
[b] Emergency Medicine, San Luigi Gonzaga University Hospital, Turin, Italy
[c] University of Nebraska College of Medicine, Children's Hospital and Medical Center, Omaha, NE, USA
[d] Institute of Clinical Physiology, National Research Council, Pisa, Italy

* Corresponding author. Fondazione G. Monasterio CNR-Regione Toscana, Ospedale del Cuore, via Aurelia Sud, 54100 Massa, Italy. Tel. +39-0585493622; fax: +39-0585493616; e-mail: raf_jordan@inwind.it (R. Giordano).

Received 24 July 2015; received in revised form 2 October 2015; accepted 9 October 2015

## Summary

Respiratory complications are common causes of morbidity and the need of repeated X-ray examinations after cardiac surgery. Ultrasound of the chest, including the lung parenchyma, has been recently introduced as a new tool to detect many pulmonary abnormalities. Despite this, the use of lung ultrasound (LUS) in adult and congenital cardiac surgery remains limited. In particular, lung ultrasound has been mainly used in the evaluation of pleural effusion (PLE), but no consensus exists on methods to quantify the volume of the effusion. Usefulness of LUS for the assessment of diaphragmatic motion in children has also been highlighted, but no clear recommendation exists regarding its routine use. Accuracy of LUS in detecting pulmonary congestion after adult cardiac surgery has been demonstrated, whereas studies in children are still scarce, and data on pneumothorax and lung consolidations are limited in the paediatric population. There are methodological and practicality issues regarding diagnostic protocols (i.e. image views and their sequential order) and instrumentation (transducers and their setting) used in different studies. It also remains unclear which practitioner—the cardiologist, intensivist, pulmonologist or the radiologist, should perform the examination. Cost analysis pertaining to extensive clinical application of lung ultrasound in cardiac surgery has never been performed. Guidelines and recommendations are warranted for a systematic and extensive use of this technique in cardiac surgery at different ages, as it could serve as a useful, versatile tool that could potentially decrease time, radiation exposure and costs.

**Keywords:** Lung ultrasound • Children • Cardiac surgery

## INTRODUCTION

In recent years, lung ultrasound (LUS) has been gaining consensus as a non-invasive, radiation-free tool for the diagnosis of various acute and chronic pulmonary diseases [1–9]. There is increasing evidence to support the use of LUS in the emergency department and intensive care unit (ICU) [4, 10–15].

LUS is a relatively easy technique when compared with other sonographic applications, and requires a limited period of training [16–18]. It allows bedside detection of PLE, pneumothorax, interstitial pulmonary oedema and lung consolidations. The examination can be performed alone or in combination with standard echocardiography. The use of LUS may help optimize resource utilization, allowing an integrated evaluation of both the heart and lungs in a single examination, thus reducing cost and time.

Pulmonary complications are frequent in cardiac surgery, representing an important cause of morbidity, prolongation of hospital stay and need for repeated examinations [19–21]. Despite this, the use of LUS in cardiac surgery—both in the adult and paediatric population—is not widespread, and is usually limited to few conditions such as evaluation of PLE and, more recently, of diaphragm excursion [19, 22–25]. The 2012 International evidence-based recommendations for point-of-care LUS have established evidence-based and expert consensus recommendations, and have introduced the role of LUS in the neonatal and paediatric populations [1]. However, standardized diagnostic protocols, including the imaging views to be employed and their sequential order, the type of transducers and system settings to be used are still not universally accepted. Another important issue pertains to who should perform the examinations (the cardiologist, the anaesthesiologist or the radiologist). The purpose of this paper is to review the existing scientific literature about applications of LUS in cardiac surgery, with special attention to the paediatric population.

## METHODOLOGICAL ISSUES

Different diagnostic protocols and instruments have been employed for LUS examinations. There is variability about the views and their sequential order and although an initial standardization has been

**Table 1:** Proposed methods to divide each hemithorax during lung ultrasound examination in intensive care patients

| Author | Division of each hemithorax |
|---|---|
| Volpicelli *et al.* [1] | Four areas delineated by the parasternal, anterior axillary and posterior axillary lines, and by a horizontal line passing approximately in the second–third inter-costal space |
| Lichtenstein [11] | Six areas: anterior upper half, anterior lower half (supine patient); lateral upper half, lateral lower half (semirecumbent patient); posterolateral upper half, posterolateral lower half |
| Cattarossi[a] [8] | Three major areas (anterior, lateral and posterior) delineated by the parasternal, anterior axillary and posterior axillary line |
| Picano *et al.* [9] | Twenty-eight scanning sites delineated by parasternal, mid-clavicular, anterior axillary and midaxillary lines, from the second to the fifth (on the left side to the fourth) inter-costal space |

[a]Children.

proposed for the assessment in the adult patient [1], a proper protocol for the neonatal and paediatric population about measurements, quantitation techniques and position of the patient is still lacking. Both hemithoraxes may be divided in scanning areas, and different scanning schemes have been suggested (Table 1). A checklist for reporting has been proposed, although a universally accepted standardized format is not available yet [26]. LUS can be performed using any commercially available 2D echocardiographic platform and various types of transducers (phased array, linear array, convex, microconvex) [5]. The convex and microconvex probes are the most universal probes for LUS, owing to their scanning frequencies, which allow both a reasonable visualization of the pleural line and sub-pleural space, but also a good overview of deeper zones, such as the costophrenic angles. Higher-frequency probes, like linear probes, allow a more detailed evaluation of the pleural line and sub-pleural space, especially when assessing pneumothorax. Phased-array probes, characterized by lower frequencies, are appropriate to detect PLE. However, they are less accurate in the dynamic and static evaluation of the pleural line or when a detailed examination of the subpleural space is needed [5]. Higher frequencies (10 MHz or more) are also effective to study neonatal and paediatric patients, given the small chest size of a neonate or a small child [27–29]. The system setting (gain, grey scale) is another relevant and poorly investigated component that could potentially affect image quality, although the basic clinical information of the LUS examination does not seem to be significantly affected by setting changes.

## LUNG ULTRASOUND IN SPECIFIC PATHOLOGICAL CONDITIONS

### Lung involvement in cardiac surgery

Postoperative pulmonary issues are common after cardiac surgery, and have a high incidence especially in the first postoperative week. Some pulmonary complications may be prolonged for weeks or months after the operation, causing significant morbidity and necessitating repeated examinations with high costs, especially in neonates and children [20, 21, 30, 31].

Many of the commonest pulmonary complications after cardiac surgery are related to the surgery itself, but also to complications that may affect the haemodynamic condition, including PLE, impairment of diaphragmatic mobility and pneumothorax. Cardiopulmonary bypass *per se* and, to a lesser extent, also anaesthetic procedures are responsible for postoperative pulmonary dysfunction, by inducing an inflammatory response that may lead to interstitial pulmonary oedema [30, 32]. This inflammatory response is even more relevant in children where other factors contributing to pulmonary dysfunction may coexist, including primary pulmonary hypertension and congenital heart defects [33].

### Pleural effusion

PLE is a common complication after cardiac surgery at all ages. PLEs may have diverse aetiology and characteristics (serous, blood, blood serum, chylous). Substantial PLE may cause compression and atelectasis of the pulmonary parenchyma. A tissue-like patterned lung floating in the pleural space often showing hyperechogenic punctiform and branchiform images, corresponding to air bronchograms, may be observed within and at the margins of the effusion [34, 35].

Use of sonography for the diagnostic evaluation of PLE as well as for guidance of thoracentesis has been known for many years, and is the most established application of LUS [1, 36–38]. On LUS, PLE appears often as an anechoic space between the parietal and visceral pleura [1] (Fig. 1) The lung behind the effusion shows different degrees of aeration, up to the complete loss of alveolar air due to mechanical compression. Very often, this consolidative phenomenon is gradually manifested, as the lung shows a gradual restoration of aeration when the probe is moved away from the fluid collection. This characteristic of the consolidated lung may allow reliable differentiation between compressive atelectasis and pneumonia. In the bedside assessment of effusion on critically ill patients, LUS shows a better sensitivity and reliability than chest radiography (CXR), which is highly dependent on the necessity of the upright view [39]. Bedside CXR rarely detects small effusions and can also miss effusions of up to 500 ml [40]. On the other hand, the sensitivity and specificity of LUS for the detection of PLE are as high as 93%, compared with computed tomography (CT) [41]. Fibrinous septations are even better visualized by LUS than CT, as indicated by the British Thoracic Society guidelines [37]. In ventilated patients with adult respiratory distress syndrome, the detection rate of PLE by LUS was high, when compared with CT. LUS can diagnose effusion, evaluate its volume and also indicate the most appropriate site for thoracentesis [42]. However, there is no perfect consensus about how PLE should be measured and quantified by LUS. As summarized in Table 2, various formulas have been proposed for the estimation of pleural volumes [23, 24, 40, 43–45]. These formulas significantly vary, both in the approach to measurements and the projections employed. Furthermore, these formulas may be inadequate for infants and children. LUS may also offer clues to identify the nature of the effusion [1, 46]. Visualization of internal echoes is highly suggestive of an exudate or a haemothorax [47, 48]. However, an anechoic effusion may either be a transudate or an exudate.

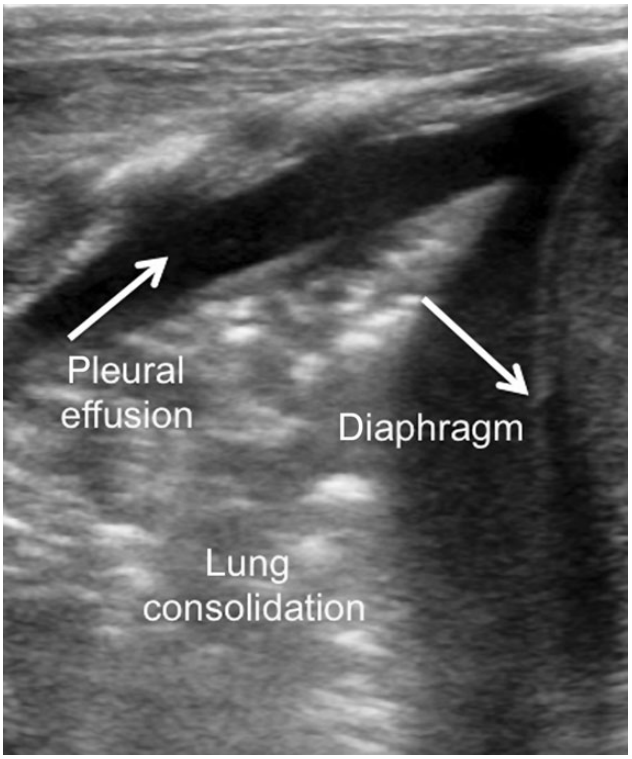


**Figure 1:** Sonographic appearance of pleural effusion and coexisting lung consolidation.

## Lung consolidations

An accurate aetiological diagnosis of lung opacities on bedside CXR in critically ill patients is a frequent challenge [49]. LUS helps in differentiating PLE from atelectasis, consolidation, mass or an elevated hemidiaphragm. These conditions are often hardly distinguished on a chest X-ray, especially when the radiological examination is performed at the patient's bedside. Consolidation of the lung may be the result of various processes: for example, an infection, an infarction due to pulmonary embolism, primary or metastatic cancer, compressive or obstructive atelectasis or a contusion from thoracic trauma (Figs 2 and 3). Additional features on LUS may help determine the aetiology of the consolidation. These include quality of the deep margins of the consolidation, the presence of air or fluid bronchogram(s) or the vascular pattern within the consolidation [35, 50, 51]. However, it must be said that LUS is only indicative, and to date no consensus has been reached on the exact LUS signs that may allow a reliable differential diagnosis. The integration of LUS with the clinical data and the other diagnostic tools still remains the most accurate strategy.

## Pneumothorax

Pneumothorax is a common complication in cardiac surgery. Chest tube removal represents a common situation that may cause the occurrence of pneumothorax. Indeed, routine CXR has been advocated for the safe exclusion of post-procedural pneumothorax after tube removal. Because most of these post-procedural pnemothoraxes are small, it has been suggested that routine radiography after chest tube removal may not be necessary in all patients, unless there is a strong clinical suspicion of significant pneumothorax [52]. There is increasing awareness on the excessive use of radiography and its impact in terms of radiation exposure and healthcare costs [53]. Moreover, CXR has low sensitivity for the diagnosis of post-procedural pneumothorax [54]. LUS revealed an optimal diagnostic accuracy, with superior sensitivity and similar specificity to CXR, for the detection of pneumothorax in the emergency department [4, 55]; however, its use in cardiac surgery remains extremely limited, and only one paper reporting on a few paediatric clinical cases can be found in the recent literature [56]. The LUS pattern of pneumothorax includes the absence of lung sliding and pulse (Fig. 4), absence of B-lines and evidence of the 'lung point' [1]. Lung point has a reported diagnostic specificity of 100%, but a low sensitivity. The sonographic technique for pneumothorax is easy to acquire and may be performed in a few seconds at the bedside, even in the extreme emergency situations [17, 57]. Any commercially available transducer can be employed; however, the analysis of superficial lung sliding and the lung point are better studied by the use of a linear transducer with higher frequencies (5–10 MHz). LUS showed also a good reliability in the classification of pneumothorax size, which is superior to CXR, when compared with CT scan, which may guide the decision of treatment [58].

## Diaphragmatic motion anomalies

Diaphragmatic paralysis with concomitant atelectasis is another possible complication, which occurs more frequently in the setting of infant and paediatric cardiac surgery [30]. The reported incidence rate of diaphragmatic paralysis in paediatric cardiac surgery ranges from 0.3 to 12.8%. The clinical consequences of diaphragmatic paralysis may be dramatic, and include respiratory insufficiency, pulmonary infections, prolongation of hospital stay and even death [22, 59].

Diagnosis of diaphragmatic dysfunction is often difficult (especially in older children and adults), and requires a high index of suspicion. Paralysis may be suspected by an elevated hemidiaphragm on CXR. However, its confirmation requires dynamic assessment of diaphragm mobility. The study of diaphragm mobility can be performed by different imaging modalities, including ultrasound, sonomicrometry, electromyography, nuclear magnetic resonance or video-fluoroscopy.

LUS can be reliably employed to evaluate diaphragmatic paralysis [60]. LUS has shown diagnostic accuracy similar to fluoroscopy in paediatric patients, with the advantage of quick bedside diagnosis along with the easy possibility to repeat the test at the clinician's convenience, still maintaining contained costs and reduced patient discomfort [61, 62].

Epelman *et al.* have described their experience in a large heterogenous cohort of 278 children aged from 3 days to 17 years, including 135 patients post-cardiac surgery. They proposed a specific protocol for the evaluation of diaphragmatic mobility by LUS consisting of various steps [22]. First, a comparative imaging of both hemidiaphragms is recommended by placing the transducer in an oblique transverse subxiphoid plane in the midline. Then the transducer is moved in each subcostal region, and left and right hemidiaphragms are imaged separately in the coronal plane. Finally, the movement of each hemidiaphragm is evaluated using M-mode. Diaphragmatic motion can be classified as normal, decreased, absent or paradoxical, with absent and paradoxical motion indicating diaphragmatic paralysis (Table 3) [22]. It has to be noted that cut-off values in normal subjects should be established for an effective comparative determination of abnormal diaphragmatic motion. Furthermore, new studies possibly comparing the

**Table 2:** Methods for quantification of pleural effusion by lung ultrasound

| Author | Subjects | Position | Projections/views | Transducer | Breath cycle | Formula |
|---|---|---|---|---|---|---|
| Remérand *et al*. [24], France | 58 patients (45 males)<br>58 ± 17 years | Supine | *Transverse views* positioning the transducer in each IS. The transducer was slipped between the patient's back and mattress. The lower and upper IS where PE was detected were drawn on the patient's skin<br>*PE length* measured in para-vertebral regions between the apical and caudal limits.<br>*Cross-sectional* area measured at the mid-length of PE | Cardiac<br>5 MHz<br>3.5 MHz | EE | PEV (ml) = ACT ($cm^2$) × LCT (mm) |
| Usta [43], Germany | 135 patients (90 males)<br>60 (45–67) years<br>BMI 28.17 ± 2.8 $kg/m^2$ | Sitting | The transducer was moved in a *cranial direction in the mid-scapular line*.<br>PE diameter: maximal distance between mid-height of the diaphragm and visceral pleura | Cardiac<br>S5-1, 2.5 MHz | EE | PEV (ml)sw = D (mm) × 16 |
| Balik *et al*. [40], Czech Republic | 81 (47 males)<br>m. ventilated patients<br>60 ± 15 years | Supine | The transducer was moved in the *cranial direction in the posterior axillary line*<br>PE diameter: maximal distance between parietal and visceral pleura at the lung base | 2.5 MHz | EE | PEV (ml) = 20 × Sep (mm) |
| Eibenberger [44], Austria | 51 patients (21 males)<br>28–82 years | Sitting | Latero-dorsal wall of the chest<br>PE diameter: the maximal perpendicular distance between the posterior wall of the lung and the posterior chest wall | 3.5 MHz curved;<br>6.5 MHz annular | EE | D (mm) PEV (ml)<br>0 0–90<br>10 50–300<br>20 150–310<br>30 160–660<br>40 490–1670<br>50 650–1840<br>>60 950–251 |
| Vignon *et al*. [23], France | 97 patients (61 males)<br>age 59 ± 20 years | Supine | From the base to the apex of the chest, along the *dorso-lateral part of the chest wall*, as far as possible posterior between the mattress and the patient's back without lifting the hemithorax.<br>PE diameter: the maximal distance from the leading edge of the dependent surface of the lung to the trailing edge of the posterior chest wall, on transverse views of pleural spaces.<br>Measurements were made at the base and at the apex of the pleural space | 2–5-MHz broadband | EE, EI[a] | D > 45 mm at the RTB<br>D > 50 mm at the LTB base predicted a PEV ≥ 800 ml sensitivity of 94% and 100 and specificity of 76 and 67%, respectively |

ACT: pleural effusion cross-sectional area; EE: end-expiration; EI: end-inspiration; IS: inter-costal space; LCT: pleural effusion length; LTB: left thoracic base; m.: mechanical; PEV: pleural effusion volume; RTB: right thoracic base; Sep: separation; V: volume; D: diameter; PE: pleural effusion; BMI: body mass index.
[a]Typically, the inter-pleural distance was greater at end-expiration in ventilated patients and on inspiration in spontaneously breathing patients.

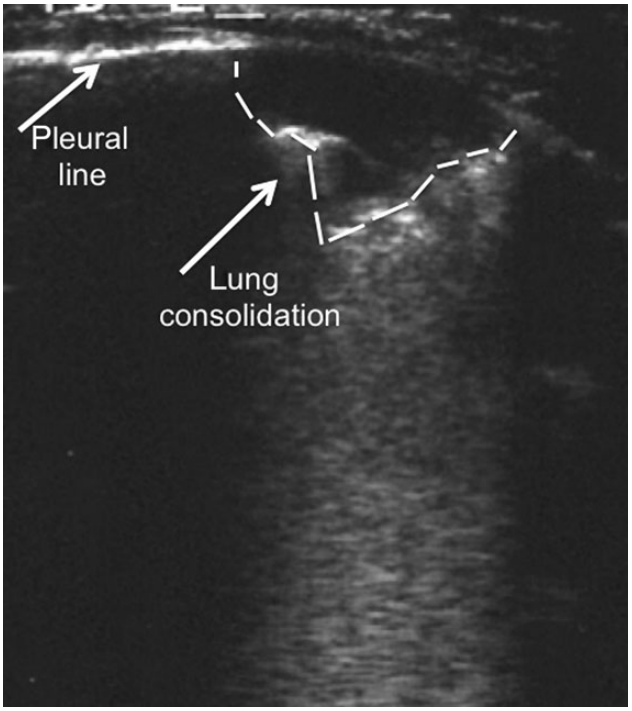


**Figure 2:** Sonographic appearance of a subpleural lung consolidation.

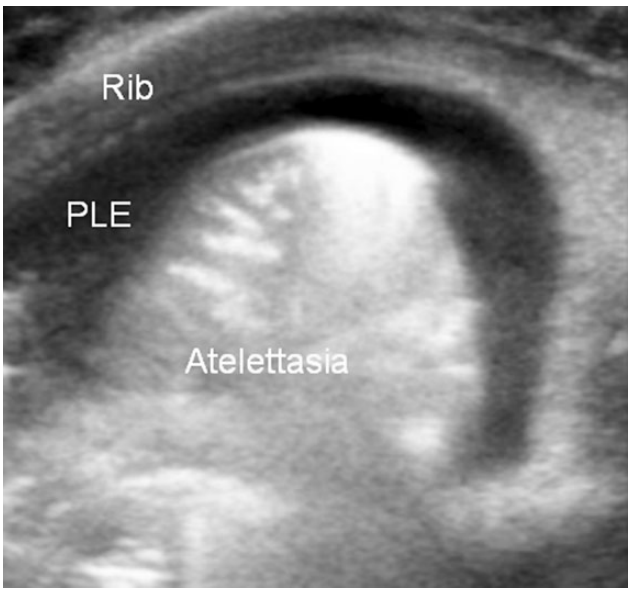


**Figure 3:** Posterior view of right lung atelectasis involving the whole lung (from base to apex) in a 1-month old female baby after surgical relief of aortic stenosis and aortic coarctation. A mild PLE is also present. PLE: pleural effusion.

diagnostic accuracy of LUS with fluoroscopy, which is nowadays the most employed technique, are needed.

## Pulmonary congestion

Pulmonary congestion after cardiac surgery may be related to haemodynamic impairment, acute lung injury or both [30]. LUS has been proposed as a reliable tool for the assessment of pulmonary congestion due to heart failure [5, 63] Detection and semi-quantification of B-lines allow for the detection and grading of pulmonary congestion, thereby adding key diagnostic and prognostic information in the setting of heart failure [64]. B-lines may also be helpful in the emergency department to differentiate cardiogenic from non-cardiogenic dyspnoea [65–67] (Fig. 5).

Significant correlations were found between the number of B-lines on LUS and lung water quantified by the indicator dilution method, pulmonary capillary wedge pressure and radiological lung water score in 20 adult patients (mean age, 63 years) studied before, immediately after and 24 h following cardiac surgery [68]. However, as expected, in the general adult critically ill population, B-lines seem to be more correlated with extravascular lung water than with pulmonary capillary wedge pressure [69]. There are no published studies on LUS to assess pulmonary congestion in the paediatric population.

## FUTURE PERSPECTIVES AND LIMITATIONS

LUS is gaining consensus as a non-invasive, radiation-free diagnostic tool for the diagnosis of several forms of pulmonary pathology; however, its use in cardiac surgery remains still not well established. This is quite surprising considering that pulmonary complications—including PLE, pneumothorax, pulmonary oedema, consolidation and diaphragmatic paralysis—are common in patients undergoing cardiac surgery. These complications represent a major cause of morbidity, requiring serial diagnostic testing, prolonged hospitalization and added cost.

Chest CT is the gold standard for non-invasive lung imaging, but it cannot be performed on a routine basis, due to its costs, the non-negligible radiation burden and the risks linked to transportation of critically ill patients to the radiology department [70]. Limitations of bedside CXR are also significant, since it is often not possible to obtain high-quality films in the ICU and, more generally, in the critically ill, which impairs the sensitivity and specificity of conventional radiology for the identification of lung conditions [71].

Thus, a systematic use of LUS has been hampered by limited knowledge of its potentialities, indications and technique. Currently, LUS is mainly used for evaluating PLE. To assess other pulmonary conditions, like pneumothorax, pulmonary congestion and consolidations, clinicians still tend to rely primarily on other imaging techniques, like CXR and CT. Moreover, there are controversies regarding who should perform and interpret LUS examinations: the cardiologist, the intensivist, the radiologist or the pulmonologist. While LUS can be performed by anyone with imaging expertise, it has been demonstrated that it produces more beneficial results when performed as a point-of-care tool by any clinician directly dealing with patient care [2, 5].

There is additional practical and methodological debate pertaining to the lack of clear guidelines regarding the protocols to be adopted (essential imaging views and their sequential order, format for reporting), and the instruments to be employed. In particular, there is limited knowledge about transducer selection for different ages and body sizes, and system settings. Although there is evidence that LUS could assist in the diagnosis of some pulmonary pathology, and may reduce time and costs [72], a systematic cost analysis of its application in cardiac surgery has never been performed. The development of LUS programmes would require a combination of dedicated personnel, adequate instrumentation (transducers and ultrasound systems) and training protocols.

For instance, even if the utility of LUS in the diagnosis of PLE as well as in the guidance of thoracentesis is well proved, there is no

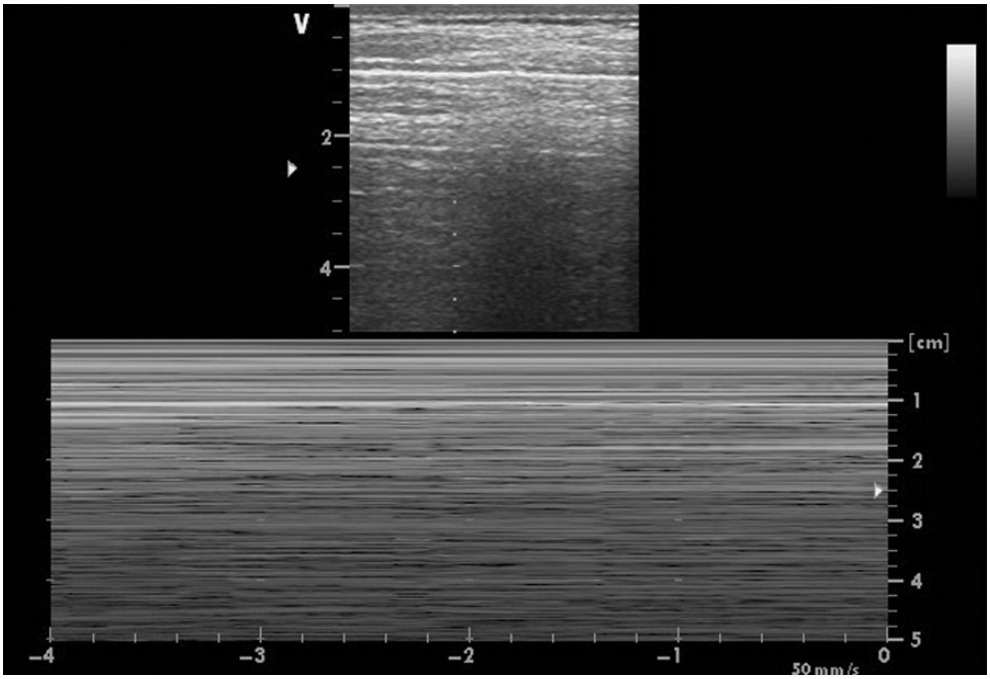


**Figure 4:** M-mode tracing of a pneumothorax: the parallel horizontal lines above and below the pleural resembling a 'barcode' indicate the absence of lung sliding (this characteristic pattern is also known as 'Stratosphere sign').

**Table 3:** Criteria for definition of diaphragmatic motion on M-mode lung ultrasound in children (Urvoas *et al*. [60])

| Diaphragmatic motion | Ultrasound criteria |
|---|---|
| Normal | Diaphragmatic motion is towards the transducer in inspiration, the excursion is >4 mm and the difference of excursion between the hemidiaphragms is <50% |
| Decreased | The excursion is ≤4 mm and the difference of amplitude between the hemidiaphragms is >50% |
| Absent | The tracing shows a flat line |
| Paradoxical | Diaphragmatic motion is away from the transducer in inspiration |

[a]In mechanically ventilated patients, the ventilator should be temporarily disconnected for a correct evaluation of diaphragmatic motion.

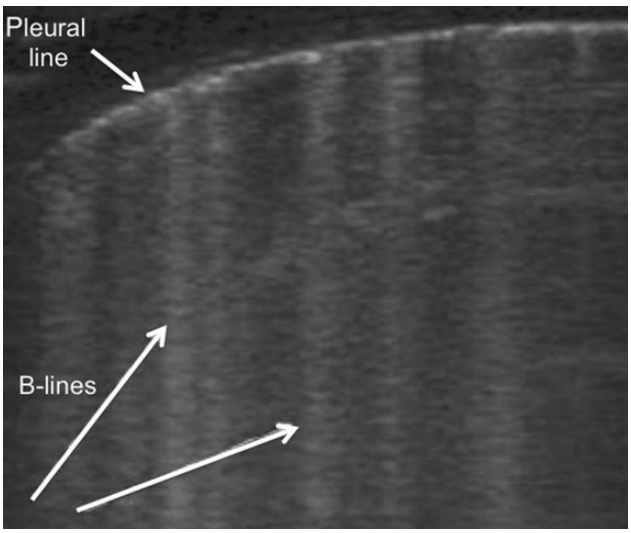


**Figure 5:** Sonographic B-lines: the sign of pulmonary interstitial syndrome.

agreement on the most reliable technique to be used to quantify the volume of effusion, as several formulae have been published [23, 24]. Some formulae may be very complicated for routine use and others allow only a suboptimal semi-quantification. All have been derived from experience with adults and may even be less reliable in children.

Data on the usefulness of LUS to study the diaphragmatic function in adults and children are promising but are still insufficient to conclude its applicability in clinical practice [22, 73, 74]. Further studies are needed in order to fully validate the technique, particularly in the setting of post-cardiac surgery.

The accuracy of LUS in the evaluation of pulmonary congestion is largely evidence based, and has been also shown in a small series of adults after cardiac surgery [68]. However, studies including paediatric patients are needed to confirm these findings and extend the use of LUS in this new setting. The need to reduce the routine use of CXR for the evaluation of pneumothorax after chest tube removal is a topic of debate with regard to excessive and unnecessary utilization of resources and costs [52, 75]. The possibility of replacing CXR with LUS in the setting of adult and paediatric cardiac surgery has not been explored yet.

Despite the proven diagnostic power of LUS and its influence on decision-making and therapeutic management, there are still significant barriers to the widespread use of this tool. Operator dependency may be considered a significant limitation. Several studies have been performed by experts in the field, and this may limit the generalization of results. The development of official, validated training ultrasound programmes is mandatory to implement the proper use of LUS in many different settings, including adult and paediatric post-cardiac surgery [71, 76]. The possibility

of a structured, worldwide standardized training, with basic and advanced modules, will likely accelerate the diffusion and implementation of this new imaging tool, which should not be restricted to a few experts' hands, but become part of established medical education curriculum. Physicians should start interpreting point-of-care echos as an extension of their senses [75].

## CONCLUSIONS

LUS represents a still largely underestimated and underutilized diagnostic tool for several common pulmonary complications after cardiac surgery. Implementation of LUS in clinical practice may help to reduce excessive and unnecessary radiology tools, thereby decreasing radiation exposure, time and costs. Up to now the use of LUS in cardiac surgery has been mainly limited to the evaluation of PLE and more recently to the assessment of diaphragmatic mobility in children. Other pulmonary conditions such as pulmonary oedema, consolidations and pneumothorax are rarely evaluated. Owing to the novelty of LUS, there is still a knowledge gap relative to its potentialities and limitations in different conditions. Guidelines and recommendations are warranted in the future to implement and rationalize the systematic use of LUS in cardiac surgery in both adult and paediatric patients. Training programmes are also necessary to create a team of qualified operators in LUS in all ICUs. In the near future, point-of-care sonographic applications should hopefully become part of the standard training of all intensivists.

**Conflict of interest:** none declared.

## REFERENCES

[1] Volpicelli G, Elbarbary M, Blaivas M, Lichtenstein DA, Mathis G, Kirkpatrick AW *et al*. International Liaison Committee on Lung Ultrasound (ILC-LUS) for International Consensus Conference on Lung Ultrasound (ICC-LUS). International evidence-based recommendations for point-of-care lung ultrasound. Intensive Care Med 2012;38:577–91.
[2] Moore CL, Copel JA. Point-of-care ultrasonography. N Engl J Med 2011; 364:749–57.
[3] Gargani L. Lung ultrasound: a new tool for the cardiologist. Cardiovasc Ultrasound 2011;9:6.
[4] Bouhemad B, Zhang M, Lu Q, Rouby JJ. Clinical review: bedside lung ultrasound in critical care practice. Crit Care 2007;11:205.
[5] Gargani L, Volpicelli G. How I do it: lLung ultrasound. Cardiovasc Ultrasound 2014;12:25.
[6] Lichtenstein DA. Ultrasound in the management of thoracic disease. Crit Care Med 2007;35(5 Suppl.):S250–61.
[7] Smargiassi A, Inchingolo R, Soldati G, Copetti R, Marchetti G, Zanforlin A *et al*. The role of chest ultrasonography in the management of respiratory diseases: document II. Multidiscip Respir Med 2013;8:55.
[8] Cattarossi L. Lung ultrasound: its role in neonatology and pediatrics. Early Hum Dev 2013;89(Suppl. 1):S17–9.
[9] Picano E, Frassi F, Agricola E, Gligorova S, Gargani L, Mottola G. Ultrasound lung comets: a clinically useful sign of extravascular lung water. J Am Soc Echocardiogr 2006;19:356–63.
[10] Peris A, Tutino L, Zagli G, Batacchi S, Cianchi G, Spina R *et al*. The use of point-of-care bedside lung ultrasound significantly reduces the number of radiographs and computed tomography scans in critically ill patients. Anesth Analg 2010;111:687–92.
[11] Lichtenstein DA, Mezière GA. Relevance of lung ultrasound in the diagnosis of acute respiratory failure: the BLUE protocol. Chest 2008;134:117–25.
[12] Volpicelli G, Lamorte A, Tullio M, Cardinale L, Giraudo M, Stefanone V *et al*. Point-of-care multiorgan ultrasonography for the evaluation of undifferentiated hypotension in the emergency department. Intensive Care Med 2013;39:1290–8.
[13] Volpicelli G, Caramello V, Cardinale L, Mussa A, Bar F, Frascisco MF *et al*. Bedside ultrasound of the lung for the monitoring of acute decompensated heart failure. Am J Emerg Med 2008;26:585–91.
[14] Volpicelli G, Frascisco M. Lung ultrasound in the evaluation of patients with pleuritic pain in the emergency department. J Emerg Med 2008;34: 179–86.
[15] Volpicelli G, Cardinale L, Berchialla P, Mussa A, Bar F, Frascisco MF. A comparison of different diagnostic tests in the bedside evaluation of pleuritic pain in the ED. Am J Emerg Med 2012;30:317–24.
[16] Bedetti G, Gargani L, Corbisiero A, Frassi F, Poggianti E, Mottola G *et al*. Evaluation of ultrasound lung comets by hand-held echocardiography. Cardiovasc Ultrasound 2006;4:34.
[17] Noble VE, Lamhaut L, Capp R, Bosson N, Liteplo A, Marx JS *et al*. Evaluation of a thoracic ultrasound training module for the detection of pneumothorax and pulmonary edema by prehospital physician care providers. BMC Med Educ 2009;9:3.
[18] Begot E, Grumann A, Duvoid T, Dalmay F, Pichon N, François B *et al*. Ultrasonographic identification and semiquantitative assessment of unloculated pleural effusions in critically ill patients by residents after a focused training. Intensive Care Med 2014;40:1475–80.
[19] Joho-Arreola AL, Bauersfeld U, Stauffer UG, Baenziger O, Bernet V. Incidence and treatment of diaphragmatic paralysis after cardiac surgery in children. Eur J Cardiothorac Surg 2005;27:53–7.
[20] Ng CS, Wan S, Yim AP, Arifi AA. Pulmonary dysfunction after cardiac surgery. Chest 2002;121:1269–77.
[21] Weissman C. Pulmonary complications after cardiac surgery. Semin Cardiothorac Vasc Anesth 2004;8:185–211.
[22] Epelman M, Navarro OM, Daneman A, Miller SF. M-mode sonography of diaphragmatic motion: description of technique and experience in 278 pediatric patients. Pediatr Radiol 2005;35:661–7.
[23] Vignon P, Chastagner C, Berkane V, Chardac E, François B, Normand S *et al*. Quantitative assessment of pleural effusion in critically ill patients by means of ultrasonography. Crit Care Med 2005;33:1757–63.
[24] Remérand F, Dellamonica J, Mao Z, Ferrari F, Bouhemad B, Jianxin Y *et al*. Multiplane ultrasound approach to quantify pleural effusion at the bedside. Intensive Care Med 2010;36:656–64.
[25] Akay T, Ozkan S, Gultekin B, Uguz E, Varan B, Sezgin A *et al*. Diaphragmatic paralysis after cardiac surgery in children: incidence, prognosis and surgical management. Pediatr Surg Int 2006;22:341–6.
[26] Tutino L, Cianchi G, Barbani F, Batacchi S, Cammelli R, Peris A *et al*. Time needed to achieve completeness and accuracy in bedside lung ultrasound reporting in intensive care unit. Scand J Trauma Resusc Emerg Med 2010; 18:44.
[27] Copetti R, Cattarossi L. Ultrasound diagnosis of pneumonia in children. Radiol Med 2008;113:190–8.
[28] Copetti R, Soldati G, Copetti P. Chest sonography: a useful tool to differentiate acute cardiogenic pulmonary edema from acute respiratory distress syndrome. Cardiovasc Ultrasound 2008;6:16.
[29] Shah VP, Tunik MG, Tsung JW. Prospective evaluation of point-of-care ultrasonography for the diagnosis of pneumonia in children and young adults. JAMA Pediatr 2013;167:119–25.
[30] Apostolakis E, Filos KS, Koletsis E, Dougenis D. Lung dysfunction following cardiopulmonary bypass. J Card Surg 2010;25:47–55.
[31] Milot J, Perron J, Lacasse Y, Létourneau L, Cartier PC, Maltais F *et al*. Incidence and predictors of ARDS after cardiac surgery. Chest 2001;119:884–8.
[32] Miller BE, Levy JH. The inflammatory response to cardiopulmonary bypass. J Cardiothorac Vasc Anesth 1997;11:355–66.
[33] Chowdhury UK, Airan B, Sharma R, Bhan A, Kothari SS, Saxena A *et al*. Original article univentricular repair in children under 2 years of age: early and midterm results. Heart Lung Circ 2001;10:3–13.
[34] Weinberg B, Diakoumakis EE, Kass EG, Seife B, Zvi ZB. The air bronchogram: sonographic demonstration. AJR Am J Roentgenol 1986;147:593–5.
[35] Lichtenstein D, Mezière G, Seitz J. The dynamic air bronchogram. A lung ultrasound sign of alveolar consolidation ruling out atelectasis. Chest 2009;135:1421–5.
[36] Longo D, Fauci A, Kasper D, Hauser S, Jameson J, Loscalzo J. Harrison's Principles of Internal Medicine. USA: The McGraw-Hill Companies, Inc., 2008.
[37] Maskell N, Butland R. BTS guidelines for the investigation of a unilateral pleural effusion in adults. Thorax 2003;58(Suppl. 2):ii8–17.
[38] Gryminski J, Krakówka P, Lypacewicz G. The diagnosis of pleural effusion by ultrasonic and radiologic techniques. Chest 1976;70:33–7.
[39] Kocijancic I, Vidmar K, Ivanovi-Herceg Z. Chest sonography versus lateral decubitus radiography in the diagnosis of small pleural effusions. J Clin Ultrasound 2003;31:69–74.

[40] Balik M, Plasil P, Waldauf P, Pazout J, Fric M, Otahal M *et al*. Ultrasound estimation of volume of pleural fluid in mechanically ventilated patients. Intensive Care Med 2006;32:318–21.
[41] Lichtenstein D, Goldstein I, Mourgeon E, Cluzel P, Grenier P, Rouby JJ. Comparative diagnostic performances of auscultation, chest radiography, and lung ultrasonography in acute respiratory distress syndrome. Anesthesiology 2004;100:9–15.
[42] Sachdeva A, Shepherd RW, Lee HJ. Thoracentesis and thoracic ultrasound: state of the art in 2013. Clin Chest Med 2013;34:1–9.
[43] Usta E, Mustafi M, Ziemer G. Ultrasound estimation of volume of postoperative pleural effusion in cardiac surgery patients. Interact CardioVasc Thorac Surg 2010;10:204–7.
[44] Eibenberger K, Dock W, Ammann M. Quantification of pleural effusions: sonography versus radiography. Radiology 1994;191:681–4.
[45] Lorenz J, Börner N, Nikolaus HP. Sonographic volumetry of pleural effusions. Ultraschall Med 1988;9:212–5.
[46] Sajadieh H, Afzali F, Sajadieh V, Sajadieh A. Ultrasound as an alternative to aspiration for determining the nature of pleural effusion, especially in older people. Ann N Y Acad Sci 2004;1019:585–92.
[47] Chian CF, Su WL, Soh LH, Yan HC, Perng WC, Wu CP. Echogenic swirling pattern as a predictor of malignant pleural effusions in patients with malignancies. Chest 2004;126:129–34.
[48] Yang PC, Luh KT, Chang DB, Wu HD, Yu CJ, Kuo SH. Value of sonography in determining the nature of pleural effusion: analysis of 320 cases. AJR Am J Roentgenol 1992;159:29–33.
[49] Wiener MD, Garay SM, Leitman BS, Wiener DN, Ravin CE. Imaging of the intensive care unit patient. Clin Chest Med 1991;12:169–98.
[50] Mathis G, Blank W, Reissig A, Lechleitner P, Reuss J, Schuler A *et al*. Thoracic ultrasound for diagnosing pulmonary embolism: a prospective multicenter study of 352 patients. Chest 2005;128:1531–8.
[51] Görg C, Seifart U, Görg K, Zugmaier G. Color doppler sonographic mapping of pulmonary lesions. J Ultrasound Med 2003;22:1033–9.
[52] Eisenberg RL, Khabbaz KR. Are chest radiographs routinely indicated after chest tube removal following cardiac surgery? AJR Am J Roentgenol 2011; 197:122–4.
[53] Picano E, Vañó E, Rehani MM, Cuocolo A, Mont L, Bodi V *et al*. The appropriate and justified use of medical radiation in cardiovascular imaging: a position document of the ESC associations of cardiovascular imaging, percutaneous cardiovascular interventions and electrophysiology. Eur Heart J 2014;35:665–72.
[54] Reissig A, Kroegel C. Accuracy of transthoracic sonography in excluding post-interventional pneumothorax and hydropneumothorax. Comparison to chest radiography. Eur J Radiol 2005;53:463–70.
[55] Volpicelli G. Sonographic diagnosis of pneumothorax. Intensive Care Med 2011;37:224–32.
[56] Vitale V, Ricci Z, Cogo P. Lung ultrasonography and pediatric cardiac surgery: first experience with a new tool for postoperative lung complications. Ann Thorac Surg 2014;97:e121–4.
[57] Volpicelli G. Usefulness of emergency ultrasound in nontraumatic cardiac arrest. Am J Emerg Med 2011;29:216–23.
[58] Volpicelli G, Boero E, Sverzellati N, Cardinale L, Busso M, Boccuzzi F *et al*. Semi-quantification of pneumothorax volume by lung ultrasound. Intensive Care Med 2014;40:1460–7.
[59] Yi LC, Nascimento OA, Jardim JR. Reliability of an analysis method for measuring diaphragm excursion by means of direct visualization with videofluoroscopy. Arch Bronconeumol 2011;47:310–4.
[60] Urvoas E, Pariente D, Fausser C, Lipsich J, Taleb R, Devictor D. Diaphragmatic paralysis in children: diagnosis by TM-mode ultrasound. Pediatr Radiol 1994;24:564–8.
[61] Sanchez de Toledo J, Munoz R, Landsittel D, Shiderly D, Yoshida M, Komarlu R *et al*. Diagnosis of abnormal diaphragm motion after cardiothoracic surgery: ultrasound performed by a cardiac intensivist vs. fluoroscopy. Congenit Heart Dis 2010;5:565–72.
[62] Ferrari G, De Filippi G, Elia F, Panero F, Volpicelli G, Aprà F. Diaphragm ultrasound as a new index of discontinuation from mechanical ventilation. Crit Ultrasound J 2014;6:8.
[63] Volpicelli G, Melniker LA, Cardinale L, Lamorte A, Frascisco MF. Lung ultrasound in diagnosing and monitoring pulmonary interstitial fluid. Radiol Med 2013;118:196–205.
[64] Mebazaa A, Yilmaz MB, Levy P, Ponikowski P, Peacock WF, Laribi S *et al*. Recommendations on pre-hospital & hospital management of acute heart failure: a consensus paper from the Heart Failure Association of the European Society of Cardiology, the European Society of Emergency Medicine and the Society of Academic Emergency Medicine. Eur J Heart Fail 2015;17:544–58.
[65] Lichtenstei D, Mezière GA. Lung ultrasound sign allowing bedside distinction between pulmonary edema and COPD: the comet-tail artifact. Intensive Care Med 1998;24:1331–4.
[66] Gargani L, Frassi F, Soldati G, Tesorio P, Gheorghiade M, Picano E. Ultrasound lung comets for the differential diagnosis of acute cardiogenic dyspnoea: a comparison with natriuretic peptides. Eur J Heart Fail 2008;10:70–7.
[67] Cardinale L, Volpicelli G, Binello F, Garofalo G, Priola SM, Veltri A *et al*. Clinical application of lung ultrasound in patients with acute dyspnea: differential diagnosis between cardiogenic and pulmonary causes. Radiol Med 2009;114:1053–64.
[68] Agricola E, Bove T, Oppizzi M, Marino G, Zangrillo A, Margonato A *et al*. Ultrasound comet-tail images': a marker of pulmonary edema: a comparative study with wedge pressure and extravascular lung water. Chest 2005; 127:1690–5.
[69] Volpicelli G, Skurzak S, Boero E, Carpinteri G, Tengattini M, Stefanone V *et al*. Lung Ultrasound predicts well extravascular lung water but is of limited usefulness in the prediction of wedge pressure. Anesthesiology 2014;121:320–7.
[70] Gargani L, Picano E. The risk of cumulative radiation exposure in chest imaging and the advantage of bedside ultrasound. Crit Ultrasound J 2015;7:4.
[71] Georgopoulos D, Xirouchaki N, Volpicelli G. Lung ultrasound in the intensive care unit: let's move forward. Intensive Care Med 2014;40:1592–4.
[72] Bateman K, Downey DG, Teare T. Thoracic ultrasound for pleural effusion: delays and cost associated with departmental scanning. Respir Med 2010; 104:612–4.
[73] Baria MR, Shahgholi L, Sorenson EJ, Harper CJ, Lim KG, Strommen JA *et al*. B-Mode ultrasound assessment of diaphragm structure and function in patients with COPD. Chest 2014;146:680–5.
[74] Boon AJ, Harper CJ, Ghahfarokhi LS, Strommen JA, Watson JC, Sorenson EJ. Two-dimensional ultrasound imaging of the diaphragm: quantitative values in normal subjects. Muscle Nerve 2013;47:884–9.
[75] Sepehripour AH, Farid S, Shah R. Is routine chest radiography indicated following chest drain removal after cardiothoracic surgery? Interact Cardiovasc Thorac Surg 2012;14:834–8.
[76] Cantinotti M, Giordano R, Assanta N, Murzi B, Gargani L. Chest ultrasound: a new, easy, and radiation-free tool to detect retrosternal clot after pediatric cardiac surgery. J Cardiothorac Vasc Anesth 2015;29:e59–60.