

Case report - Pulmonary

Successful treatment of an aggressive non-Hodgkin's lymphoma associated with acute respiratory insufficiency using extracorporeal membrane oxygenation

Anas Aboud^{a,*}, Gernot Marx^b, Herbert Sayer^c, Jan F. Gummert^a^aDepartment of Cardiothoracic Surgery, Friedrich Schiller University, Jena, Germany^bDepartments of Anaesthesiology and Intensive Medicine, Friedrich Schiller University, Jena, Germany^cDepartment of Internal Medicine II (Oncology/Hematology), Friedrich Schiller University, Jena, Germany

Received 1 June 2007; received in revised form 27 October 2007; accepted 30 October 2007

Abstract

Non-Hodgkin's lymphoma initially presenting as a solid huge mediastinal mass does not frequently occur. Although nowadays many patients with high-grade (aggressive) malignant lymphoma can be cured using a combination of immuno- and chemotherapy, rapid progression and acute complications caused by the tumor mass itself may necessitate additional invasive treatment. We report a case of successful extracorporeal membrane oxygenation treatment in a 43-year-old woman with acute respiratory insufficiency due to a huge mediastinal non-Hodgkin's tumor.

© 2008 Published by European Association for Cardio-Thoracic Surgery. All rights reserved.

Keywords: Aggressive non-Hodgkin's lymphoma; Extracorporeal membrane oxygenation (ECMO); Immunochemotherapy

1. Introduction

Mediastinal tumors arise from a wide variety of benign and malignant etiologies challenging the clinician diagnostically and therapeutically. 25–49% of these masses are malignant [1]. Non-Hodgkin's lymphomas as a solitary mediastinal tumor do not frequently occur [2]. The CHOP chemotherapy is regarded as the gold standard for initial treatment of aggressive lymphomas [3]. These tumors can be complicated by airway stenosis due to bulky mediastinal manifestation. The imminent respiratory failure due to compression or infiltration of central airways represents a respiratory emergency requiring rapid intervention [4].

2. Case report

A 43-year-old woman presented with progressive dyspnoea and recurrent pain in the right hip. The X-ray of the right hip revealed a femur fracture. A huge mediastinal tumor was found in the routine chest X-ray. The CT-scan revealed a large tumor mass in the upper mediastinum and left hemi-thorax with external compression of the central airways, mainly the left main bronchus (Fig. 1). A CT-guided needle biopsy revealed numerous lymphocytes and monoclonal lymphatic proliferation corresponded to a high-grade non-Hodgkin's lymphoma. After increasing of the respiratory symptoms a bronchoscopic stent in the blocked left

main bronchus was placed unsuccessfully. The left main bronchus collapsed after these attempts and it could not be reopened again. Despite subsequently instituted invasive ventilation (airway pressure release ventilation, P_{peak} 30 mbar, PEEP 10 mbar, T_{insp} 1.8 s, T_{exp} 2.3 s, FiO_2 1.0), hypoxia aggravated (pO_2 5.17 kPa, pCO_2 5.0 kPa, HbO_2 60–70%). As it was impossible to oxygenate the patient (pO_2 of 7 kPa) over more than 2 h, veno-venous ECMO was implanted. We used a centrifugal Bio-Medicus pump from Medtronic and a diffusion membrane oxygenator Quadrox D from Maquet. Cannulation was performed at: left femoral vein for outflow [^{17}F percutaneous venous cannula, 16 cm] and right femoral vein for inflow [^{21}F percutaneous venous cannula, 50 cm]. Systemic anticoagulation was achieved using intravenous heparin aimed at an activated clotting time of 180 s. The inflow cannula was positioned more adjacent to the right atrium than the outflow cannula to achieve optimal oxygenation. With extracorporeal oxygenation (blood flow 4.0 l/min, O_2 flow 3.0 l/min, FiO_2 0.5) and the following ventilation parameters (P_{peak} 19 mbar, PEEP 5 mbar, T_{insp} 2 s, T_{exp} 2 s, FiO_2 0.35) hypoxia could be reversed effectively (pO_2 16 kPa, pCO_2 4.01 kPa, HbO_2 97%). Lymphoma-specific therapy was initiated immediately after institution of ECMO therapy. The patient was treated with adjuvant chemotherapy regimen CHOP (C: cyclophosphamide, H: doxorubicin, O: vincristine, P: prednisolone). The patient also received the CD-20 antibody rituximab (MabThera®) three days after the chemotherapy was started. Six days after admission the patient was successfully weaned from ECMO. Under the immuno-chemotherapy the

*Corresponding author. Erlanger Allee 101, 07740 Jena, Germany. Tel.: +49/3641/9322901; fax: +49/3641/9322902.

E-mail address: Anas.Aboud@med.uni-jena.de (A. Aboud).

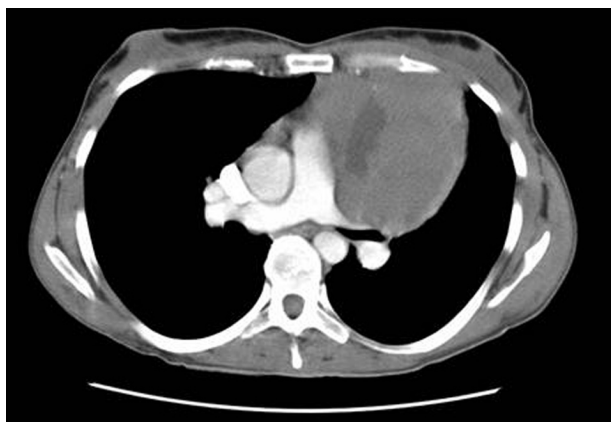


Fig. 1. The tumor in the upper mediastinum in the CT-scan (external compression of the central airways mainly the left bronchus).

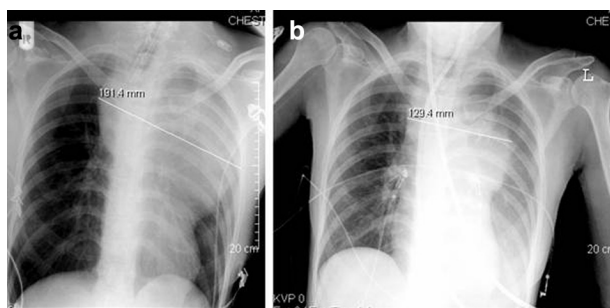


Fig. 2. (a, b) The differences in the size of the tumor before and after Immunotherapy.

tumor mass could be reduced (Fig. 2a, b). The left main bronchus was reopened again and the left lung could be ventilated. Eight days after ECMO explantation, the patient was extubated and breathed spontaneously with $\text{PaO}_2/\text{FiO}_2$ -quotients of more than 300 (pO_2 11.5 kPa, pCO_2 5.2 kPa, HbO_2 97%). After 36 day of intensive care treatment, the patient was discharged for pulmonary rehabilitation and continuation of immunotherapy. Spirometry performed six months later showed a normal respiratory status.

3. Discussion

The presence of thoracic and mediastinal involvement in patients with lymphoma are not unusual [2]. On the other hand, the incidence of non-Hodgkin's lymphoma as a solitary first event mediastinal tumor is rare [1]. The main modalities used in the treatment of non-Hodgkin's lymphoma are irradiation and chemotherapy and nowadays a combination of immuno- and chemotherapy [3, 5].

The severe airway stenosis due to extraluminal compression is an uncommon event affecting approximately 5% of

the patients presenting with non-Hodgkin's lymphomas [6]. Generally, patients with airways' obstruction have mild hypoxia and, rarely, they present with a severe respiratory difficulty needing urgent intervention. Bronchoscopic stenting is still the treatment of choice in these conditions [6].

Our patient presented with severe hypoxia after unsuccessful bronchoscopic stenting therapy and occlusion of the left main bronchus by a huge mediastinal lymphoma, requiring emergent intervention. We decided to use the venovenous ECMO because sufficient oxygenation could not be achieved by aggressive ventilation. Two case reports in the literature describe the ECMO therapy under such conditions [7, 8]. The early use of ECMO in both cases was useful in supporting the pulmonary function when adequate oxygenation could not be accomplished by conventional techniques. The ECMO therapy was followed by surgical extirpation of the tumor [7] or by a combination of chemotherapy and radiation therapy [8]. Both patients could be weaned from the ECMO and survived hospital treatment. We describe the first case with a combination of immunotherapy and chemotherapy. We could remove the ECMO after six days under the immunotherapy (R-CHOP) and decreasing of the tumor mass. The left lung was again ventilated and the patient breathed spontaneously.

In our opinion, ECMO support in life-threatening hypoxia due to tumor related compression of the trachea or bronchus is a lifesaving therapeutic intervention and allows institution of urgent chemotherapy treatment to reverse the life-threatening bronchial-compression. However, such an aggressive interdisciplinary treatment strategy is only justified in patients with neoplasms highly susceptible for chemotherapy or radiation.

References

- [1] Cohen AJ, Thompson L, Edwards FH, Bellamy RF. Primary cysts and tumors of the mediastinum. *Ann Thorac Surg* 1991;51:378–384.
- [2] Duwe BV, Sterman DH, Musani AI. Tumors of the mediastinum. *Chest* 2005;128:2893–2909.
- [3] Fisher RI, Gaynor ER, Dahlborg S, Oken MM, Grogan TM, Mize EM, Glick JH, Coltman CA Jr, Miller TP. Comparison of a standard regimen (CHOP) with three intensive chemotherapy regimens for advanced non-Hodgkin's lymphoma. *N Engl J Med* 1993;328:1002–1006.
- [4] Witt C, Dinges S, Schmidt B, Ewert R, Budach V, Baumann G. Temporary tracheobronchial stenting in malignant stenoses. *Eur J Cancer* 1997;33:204–208.
- [5] Hsu PK, Hsu HS, Li AF, Wang LS, Huang BS, Huang MH, Hsu WH. Non-Hodgkin's lymphoma presenting as a large chest wall mass. *Ann Thorac Surg* 2006;81:1214–1218.
- [6] Schmidt B, Massenkeil G, John M, Arnold R, Witt C. Temporary tracheobronchial stenting in malignant lymphoma. *Ann Thorac Surg* 1999;67:1448–1450.
- [7] Takeda S, Mivoshi S, Omori K, Okumura M, Matsuda H. Surgical rescue for life-threatening hypoxemia caused by a mediastinal tumor. *Ann Thorac Surg* 2000;70:340–341.
- [8] Stewart AS, Smythe WR, Aukburg S, Kaiser LR, Fox KR, Bavaria JE. Severe acute extrinsic airway compression by mediastinal tumor successfully managed with extracorporeal membrane oxygenation. *ASAIO J* 1998;44:219–221.