

## Long-Term Efficacy of a Single Session of RFA for Benign Thyroid Nodules: A Longitudinal 5-Year Observational Study

Maurilio Deandrea,<sup>1</sup> Pierpaolo Trimboli,<sup>2</sup> Francesca Garino,<sup>1</sup> Alberto Mormile,<sup>1</sup> Gabriella Magliona,<sup>1</sup> Maria Josefina Ramunni,<sup>1</sup> Luca Giovanella,<sup>2</sup> and Piero Paolo Limone<sup>1</sup>

<sup>1</sup>Endocrinology, Diabetes and Metabolism Department and Center for Thyroid Diseases, A.O. Ordine Mauriziano, 10010 Turin, Italy; and <sup>2</sup>Department of Nuclear Medicine and Thyroid Center, Oncology Institute of Southern Switzerland, 6900 Lugano, Switzerland

**ORCID numbers:** 0000-0001-9217-8815 (M. Deandrea).

**Context:** Radiofrequency ablation (RFA) of benign thyroid nodules has been gaining consensus. However, no solid information on its long-term efficacy is available.

**Objective:** To analyze the long-term results of single-session RFA.

**Design:** Retrospective longitudinal observational study.

**Setting:** Primary care center.

**Patients or Other Participants:** Adult outpatients who underwent a single-session RFA and post-treatment follow-up of least 3 years.

**Intervention:** Ultrasound-guided RFA was performed after local anesthesia by “moving-shot” technique. RFA was performed with a median power of 55W and a median time of 14 minutes with an internally cooled 18-gauge electrode with an active 10-mm tip.

**Main Outcome Measures:** Objective (trend of nodule volume) and subjective (compressive and cosmetic concerns) response to RFA were evaluated. Continuous variables were analyzed by the Wilcoxon and ANOVA test and their correlations by using the Spearman test. Categorical variables were compared by Pearson  $\chi^2$  test.

**Results:** Two hundred and fifteen patients were included. An early significant reduction of nodule volume was found at 1 year, lasting up to 5 years. A 67% nodule shrinkage was observed at the end of the observation period. The best response was recorded in nodules below 10 mL (79% reduction early and 81% at 5 years). Patients’ symptoms were significantly reduced.

**Conclusions:** This study, by demonstrating a durable shrinkage of benign thyroid nodules treated by RFA with an improvement of subjective symptoms, establishes the reliability of RFA as alternative to surgery in the management of thyroid nodules, thus representing a remarkable novelty for clinical practice. (*J Clin Endocrinol Metab* 104: 3751–3756, 2019)

**S**urgery has traditionally been the only treatment of benign thyroid lesions causing neck compressive symptoms. Indeed, this strategy rapidly resolves

local symptoms and discomfort. However, thyroid surgical interventions lead to a nonnegligible rate (7% to 19%) of mild to severe complications, depending

on the extent of the operation (lobectomy vs total thyroidectomy) (1).

Therefore, several nonsurgical therapies for benign thyroid nodules have been proposed; these techniques have shown encouraging results and are being adopted worldwide (2–22). Percutaneous ethanol injection is considered the treatment of choice for recurrent cystic nodules (3–5) but is not as effective for solid lesions. For the latter type of lesion, laser and radiofrequency have been used, with excellent results (6–20); the efficacy and the safety of high-intensity focused ultrasounds and microwave therapy are unproven (21, 22). Therefore, laser thermal ablation and radiofrequency ablation (RFA) are the most widely used nonsurgical treatments of benign solid thyroid nodules, but few data are available on their long-term efficacy.

For laser thermal ablation, some studies have reported outcomes at 3 to 5 years, with a volume reduction of up to 50% (19, 20, 23). RFA was introduced after laser ablation; most published articles have reported the results at 6 to 12 months, showing a volume reduction of about 50% to 85% (6–17). Few studies have evaluated long-term results; those published have had a 2- to 4-year follow-up, although they differ in terms of number of treatment sessions, baseline ultrasound features, and final volume shrinkage. Therefore, although data in the literature show that RFA rapidly shrink nodules, the long-term persistence of the shrinkage must be confirmed in a larger series. Thus, we sought to evaluate the long-term effects of a single RFA session on both volume reduction and improvement in clinical symptoms in a large number of benign thyroid nodules, followed for >3 years after the procedure, in a region where goiter is endemic.

## Materials and Methods

### Institutional guidelines for RFA and patient selection

RFA is currently used at the Department of Endocrinology, Diabetes and Metabolism of the Mauriziano Hospital of Turin, Italy, to treat benign thyroid nodules. According to our protocols, thyroid nodules are eligible for RFA if they are responsible for local compressive symptoms, their ultrasound pattern is solid or mixed (with a solid portion >70%), and they are benign (Bethesda class II) at two consecutive cytological assessments performed  $\geq 3$  months apart.

In May 2018, we retrospectively searched our database for patients who would be eligible for the study and selected the period from 2011 to 2015 in order to include only cases with more than a 3-year follow-up in our analysis. The patients were included if they were >18 years of age, had normal thyroid function, and had undergone a single RFA procedure. The local ethical committee approved the study.

### Preablation assessment

All patients were evaluated by clinical and ultrasound examination and by laboratory blood analysis.

The ultrasound scans and color Doppler scans were obtained in real time with a commercially available ultrasound system (Esaote Mylab 70, Genoa, Italy) equipped with a linear transducer operating at 7.5 to 10 MHz for the morphological study and 4.7 MHz for the ultrasound evaluation with color Doppler imaging. Three orthogonal diameters of each nodule (the largest diameter and two other perpendicular diameters) and the proportion of solid component were measured before RFA. The volume of each nodule was calculated according to the following formula:

$$V = D1 \times D2 \times D3 \times 0.525,$$

where V is volume, D3 is the largest diameter, D1 and D2 are the two other perpendicular diameters, and 0.525 is the ellipsoid volume.

Nodule vascularity was classified by using a three-point scale, with 0, 1, and 2 representing, respectively, no Doppler signals, peripheral Doppler signals, and intranodular Doppler signals.

Laboratory examinations comprised measurements of serum thyrotropin (normal range, 0.35 to 3.6 mIU/L), free T4 (normal range, 8 to 15 pg/mL), and calcitonin (normal range, 0 to 10 pg/mL), concentrations, antithyroid antibodies titers (negative < 20 IU/mL), and platelet count and blood coagulation tests (including prothrombin time and activated partial thromboplastin time).

Before RFA, patients were asked to rate pressure symptoms and cosmetic grading score, as previously reported (24–26).

### Procedure

RFA was performed on an outpatient basis. Informed consent was obtained from all patients. The patients were treated with 2% lidocaine for local anesthesia at the puncture site. Under ultrasound guidance, we performed RFA using the trans-isthmus approach and the “moving-shot” technique, as previously described by Baek *et al.* (10). We used an RFA system (RFA needle tube system, RF Medical, Seoul, Korea, or VIVA STARmed®, Seoul, Korea) and an internally cooled 18-gauge electrode with an active 10-mm tip (13). During the procedure, we sought to preserve important surrounding structures in order to prevent major complications, such as nerve injury (27). Ablation began with 40 W of radiofrequency power. If a transient hyperechoic zone appeared at the electrode tip within 5 seconds, RFA power was increased. If the patient did not tolerate pain during ablation, the power was reduced or turned off for several seconds. The ablation procedure was terminated when all conceptual units had become transient hyperechoic zones. Complications during and after the procedure were evaluated according to clinical signs and symptoms. Each nodule underwent a single treatment session and was followed up over time.

### Follow-up and evaluation of objective response to treatment

For follow-up, patients underwent periodical ultrasound examinations and thyroid function tests. The difference in nodule volume vs baseline was calculated and expressed as a percentage, according to the following formula:

$$(\text{initial volume} - \text{final volume}) \times 100 / \text{initial volume}.$$

Regrowth and recurrence were defined as an increase in nodule volume >50% compared with the previous findings on

ultrasound examination (16). All recurrent nodules were re-evaluated by means of biopsy.

### Evaluation of subjective response to treatment

Data on the subjective response to RFA were systematically collected during each visit from basal evaluation until the last control visit. Compressive symptoms were evaluated by a 0- to 10-point scale, where 0 indicates the absence of compression and 10, an important compression that causes serious symptoms and affects the patient's quality of life. Cosmetic concerns were evaluated on a 4-point scale as follows: 1, nodule not visible and not palpable; 2, nodule palpable but not visible; 3, nodule palpable and visible from nearby; 4, nodule palpable and visible from a distance (13).

### Evaluation of complications

Complications were assessed by using the reporting standards of interventional societies (24–26).

### Statistical analysis

Continuous variables are expressed as median with interquartile range, as nonparametric. Statistical differences in continuous variables were evaluated by the Wilcoxon test for coupled samples and by the ANOVA test for comparisons of several groups. The correlations between the variables were verified with the Spearman test and expressed with 95% CIs. Categorical variables (scores) were compared with the Pearson  $\chi^2$  test. Bilateral  $P$  values  $< 0.05$  were considered to indicate statistically significant differences. The analysis was performed by using Analyze-it software, version 4.60.1 (Leeds, United Kingdom).

## Results

A total of 290 patients were initially identified by our search during the period 2011 to 2015; according to our selection criteria, 75 patients were excluded because they underwent more than one treatment session or were lost at follow-up. Therefore, the final series included 215 benign nodules in 215 patients (182 women and 33 men; median age, 66 years; age range, 60 to 88 years) treated by single-session RFA and followed up for  $\geq 3$  years. Before RFA treatment, all patients had normal thyroid function [median TSH level, 1.2 mIU/L (25% to 75%

percentile, 0.73 to 1.78 mIU/L), median free T4, 10 pg/mL (25% to 75% percentile, 8.2 to 13.7 pg/mL)], and AbTPO titers were negative in 76% of patient. The baseline characteristics of the thyroid nodules and the initial cosmetic and symptom scores of the patients are summarized in Table 1. During RFA treatment, the median power was 55 W, and the median duration of treatment was 14 minutes.

When we analyzed the trend of nodule volume after RFA, we found significant shrinkage in the whole observation period ( $P < 0.0001$ ). Specifically, the median volume observed 6 months after the procedure was significantly lower than that at baseline. Further progressive volume reduction was seen at 1 year, as well as at the 2-year follow-up. Nodule volume recorded at 3 and 4 years did not significantly differ from that at 1 and 2 years. An additional small but statistically significant reduction was observed at 5 years ( $P = 0.0089$ ). The changes in nodule volume at each ultrasound evaluation are shown in Fig. 1. The percentage of nodule reduction is reported in Table 2. When we analyzed nodule volume reduction according to baseline size, the best response occurred in nodules with a volume  $< 10$  mL; these nodules showed an early reduction of 82%, and that decreased size remained stable over time. Nodules with a volume of 10 to 20 mL and nodules  $> 20$  mL showed a reduction of 75% and 65%, respectively (Table 2).

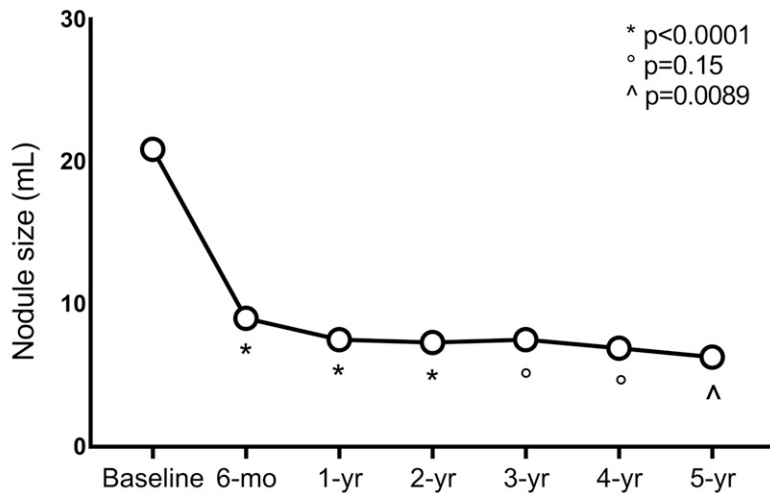
Both compressive local symptoms and cosmetic concerns improved after RFA. As shown in Fig. 2A, the former were significantly reduced at 1 year and remained stable at 5 years ( $P < 0.001$ ). Similarly (Fig. 2B), the latter improved at 1-year follow-up and persisted at 5 years ( $P < 0.0001$ ). Twelve months after RFA, no patient had a symptom score  $> 5$ , and only 9% of them had substantial discomfort (*i.e.*, a score of 3 or 4).

No major complications occurred. During the RFA procedure, one patient had hypotension. Just after treatment, 12 cases of cutaneous edema were recorded (however, these cases disappeared within 6 hours), as were four cases of superficial hematoma (which

**Table 1. Baseline Features of Thyroid Nodules Included in the Study**

Feature	Data
Median nodule volume (range), mL	20.9 (15–33)
No. of nodules with median volume $< 10$ mL	14
No. of nodules with median volume 10–20 mL	82
No. of nodules with median volume $> 20$ mL	119
Median compressive symptoms score (from 0 to 10) (25%–75% percentile)	5 (2–6)
Median cosmetic score (from 1 to 4) (25%–75%)	3 (2–4)
Median energy delivered (25%–75% percentile), W	55 (50–65)
Median duration of treatment (25%–75% percentile), min	14 (12–19)
Median duration of follow-up after RFA (25%–75% percentile), mo	35 (24–60)

Compressive and cosmetic scoring evaluation is described in the text.



Number of values	215	206	197	154	117	84	71
Minimum	3.5	0.4	0.4	0.3	0	0	0.5
25% Percentile	15	5.5	4.5	3.9	3.25	3.1	4.1
Median	20.9	9	7.5	7.3	7.5	6.9	6.3
75% Percentile	33.2	15.55	13.9	13.63	13.35	12.78	11.8
Maximum	310	161	242	214	96	93.7	113

**Figure 1.** Volumetric trend of thyroid nodules after RFA. Circles represent the median value of the group. Symbols representing P values are indicated under each circle. Number of values indicates the number of patients observed at each ultrasound evaluation. Median, minimum/maximum, and 25%/75% percentiles are reported for each time from baseline to the last control.

disappeared within three days) and two cases of muscle hematoma (which disappeared within 7 days). The day after RFA, 18 patients had some pain, 2 had a mild fever and 1 had a cough.

A subgroup of nine nodules (4.1%), despite an initial shrinkage, regrew after the first 12 months of follow-up, and their volume was larger than at baseline (median increase, 4.55%). Our retrospective evaluation of these nine cases showed that the regrowth occurred in the undertreated peripheral portion of the nodules. Biopsy confirmed a benign lesion in each case.

**Discussion**

Many reports with short- or medium-term follow-up have shown the efficacy of RFA in reducing the volume of benign

compressive thyroid nodules and in improving cosmetic and/or compressive symptoms (6–20). Nevertheless, data on the long-term persistence of nodule shrinkage are incomplete and partially limited by some bias, such as the variability of the baseline volume, ultrasound structure, and/or the number of treatment sessions carried out to obtain an optimal volume reduction (16). In most studies, more than one treatment session was performed (16), with the aim of obtaining the greatest shrinkage possible. In our clinical practice, the objective of RFA is generally to obtain a relieve symptoms, and in most cases a single treatment session is enough to achieve that goal.

No data have previously been reported on the long-term effects on shrinkage induced by a single RFA treatment session in a large series, or on clinical benefit for the treated patients. Indeed, we performed the current study to shed light on this issue.

Accordingly, we selected only patients who underwent a follow-up of ≥3 years, including a large number of patients with a clinical evaluation up to 5 years after treatment.

Our results confirm an overall volume reduction of ~70%, which became significant starting from the sixth month and progressively continued up to the second year. Thereafter, the shrinkage remained stable until the fifth year of the observation period, together with improvements in the compressive symptoms and of the cosmetic score. Volume reduction was better in smaller nodules than in larger nodules; these data agree with our previous findings (28) and may suggest that the treatment efficacy is progressively reduced along with the volume increase, possibly as a consequence of a reduced deposition of energy inside the nodule. Recently, we confirmed this observation in an Italian multicenter study

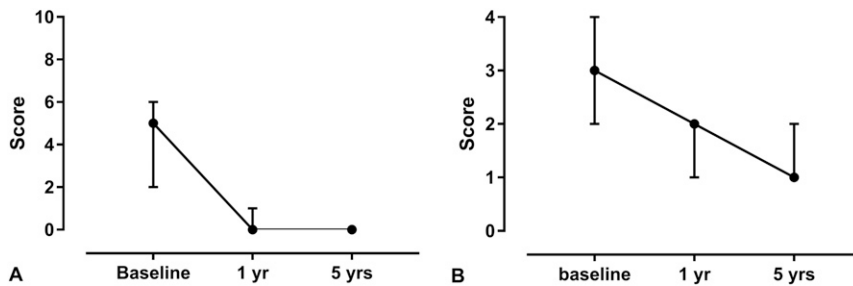
**Table 2. Percentage of Volume Reduction Recorded for All Nodules According to Baseline Size**

Variable	6 mo	1 y	2 y	3 y	4 y	5 y
All nodules	56.2 <sup>a</sup>	63 <sup>a</sup>	67.4 <sup>a</sup>	66.7	66.9	66.9
<10 mL	79 <sup>a</sup>	78	76.8	76.8	75	81.8
≥10 and <20 mL	59 <sup>a</sup>	66.7 <sup>a</sup>	74.2 <sup>a</sup>	74.2	70	74.5
≥20 mL	54.5 <sup>a</sup>	60.9 <sup>a</sup>	62.4 <sup>b</sup>	62.4	62	65.3

The rate of reduction was calculated with respect to the baseline volume. All values are expressed as median percentages.

<sup>a</sup>P < 0.001 for the comparison of median volume reduction recorded for each time with previous control.

<sup>b</sup>P < 0.01 for the comparison of median volume reduction recorded for each time with previous control.



**Figure 2.** Trend of (A) compressive symptoms and (B) cosmetic disturbances after RFA. Circles represent the median value of the group. Bars represent the interquartile ranges.

that included a large number of nodules treated with a single RFA session (29). The efficacy of RFA was similar to that previously reported after one session of RFA on mainly solid medium-sized nodules followed by a shorter period (30, 31) and is slightly better than that obtained with a single session of laser ablation in nodules with similar volume and ultrasound features (19, 20, 32, 33). The most important observation of the current study, which may have implications for clinical practice, is that the shrinkage remained stable up to 5 years, as previously reported in patients treated with laser ablation who underwent a 3- to 5-year follow-up (19, 20, 33). A further finding of our study is the very low rate of recurrence, as well as its early presentation (within the first year after RFA), which might prompt us to perform a second RFA or a surgical excision, according to the patient's preference. None of the recurrent nodules, which were subsequently operated on, was malignant at histological examination. This confirms that an accurate preablation cytological evaluation on two separate specimens prevents the risk of treating cancerous lesions.

Strengths and limitations of the study must be taken into account. All included patients had a follow-up of  $\geq 3$  years. However, not all patients underwent the scheduled clinical control visits, so the patients showed a progressive reduction over time, in particular after the third year. This may be due to many factors—concurrent nonthyroidal health problems, complete resolution of compressive symptoms inducing the patients to skip the periodic visits, follow-up carried out at other centers, other nonclinical causes (*i.e.*, change of address or long distances between city of residence and our hospital)—and might be considered a potential limitation of the study. Furthermore, this is a retrospective study and nodule size was not independently reviewed. In addition, the cosmetic and symptom scores were subjective and not validated parameters. Finally, we enrolled patients with symptomatic goiter from an endemic area in which increasing numbers of patients are declining surgery; these data should be confirmed in other countries and populations. Nevertheless, we believe that the sample is adequately representative of the treated population as a whole and that it allowed us to perform a statistical

analysis, which is enough to describe the 5-year course of thyroid nodules treated with a single session of RFA. Finally, the minor and transient side effects described confirmed the safety of this therapeutic approach.

## Conclusions

The current study provides strong evidence of a long-lasting shrinkage in a large series of benign thyroid nodules after a single RFA session, along with a significant improvement in compressive symptoms and in aesthetic discomfort. The procedure was well tolerated and safe.

In addition, we observed an extremely low rate of regrowth of treated nodules, with preserved thyroid function. From a clinical standpoint, based on this long-term finding, we can conclude that a single session of RFA represents a good alternative to surgery for treated patients with symptomatic benign thyroid nodules. This study represents a considerable innovation in clinical practice.

## Acknowledgments

**Correspondence and Reprint Requests:** Maurilio Deandrea, MD, Endocrinology, Diabetes and Metabolism Department and Center for Thyroid Diseases, A.O. Ordine Mauriziano, Largo Turati 62, 10010 Turin, Italy. E-mail: [mdeandrea@mauriziano.it](mailto:mdeandrea@mauriziano.it).

**Disclosure Summary:** The authors have nothing to disclose.

## References

- Hegedüs L, Bonnema SJ, Bencedbaek FN. Management of simple nodular goiter: current status and future perspectives. *Endocr Rev*. 2003;24(1):102–132.
- Hegedüs L. Therapy: a new nonsurgical therapy option for benign thyroid nodules? *Nat Rev Endocrinol*. 2009;5(9):476–478.
- Guglielmi R, Pacella CM, Bianchini A, Bizzarri G, Rinaldi R, Graziano FM, Petrucci L, Toscano V, Palma E, Poggi M, Papini E. Percutaneous ethanol injection treatment in benign thyroid lesions: role and efficacy. *Thyroid*. 2004;14(2):125–131.
- Sung JY, Kim YS, Choi H, Lee JH, Baek JH. Optimum first-line treatment technique for benign cystic thyroid nodules: ethanol ablation or radiofrequency ablation? *AJR Am J Roentgenol*. 2011;196(2):W210–W214.
- Kim JH, Lee HK, Lee JH, Ahn IM, Choi CG. Efficacy of sonographically guided percutaneous ethanol injection for treatment of thyroid cysts versus solid thyroid nodules. *AJR Am J Roentgenol*. 2003;180(6):1723–1726.
- Lee JH, Kim YS, Lee D, Choi H, Yoo H, Baek JH. Radiofrequency ablation (RFA) of benign thyroid nodules in patients with incompletely resolved clinical problems after ethanol ablation (EA). *World J Surg*. 2010;34(7):1488–1493.
- Baek JH, Moon WJ, Kim YS, Lee JH, Lee D. Radiofrequency ablation for the treatment of autonomously functioning thyroid nodules. *World J Surg*. 2009;33(9):1971–1977.

8. Baek JH, Jeong HJ, Kim YS, Kwak MS, Lee D. Radiofrequency ablation for an autonomously functioning thyroid nodule. *Thyroid*. 2008;**18**(6):675–676.
9. Deandrea M, Limone P, Basso E, Mormile A, Ragazzoni F, Gamarra E, Spiezia S, Faggiano A, Colao A, Molinari F, Garberoglio R. US-guided percutaneous radiofrequency thermal ablation for the treatment of solid benign hyperfunctioning or compressive thyroid nodules. *Ultrasound Med Biol*. 2008;**34**(5):784–791.
10. Jeong WK, Baek JH, Rhim H, Kim YS, Kwak MS, Jeong HJ, Lee D. Radiofrequency ablation of benign thyroid nodules: safety and imaging follow-up in 236 patients. *Eur Radiol*. 2008;**18**(6):1244–1250.
11. Kim YS, Rhim H, Tae K, Park DW, Kim ST. Radiofrequency ablation of benign cold thyroid nodules: initial clinical experience. *Thyroid*. 2006;**16**(4):361–367.
12. Spiezia S, Garberoglio R, Milone F, Ramundo V, Caiazza C, Assanti AP, Deandrea M, Limone PP, Macchia PE, Lombardi G, Colao A, Faggiano A. Thyroid nodules and related symptoms are stably controlled two years after radiofrequency thermal ablation. *Thyroid*. 2009;**19**(3):219–225.
13. Baek JH, Kim YS, Lee D, Huh JY, Lee JH. Benign predominantly solid thyroid nodules: prospective study of efficacy of sonographically guided radiofrequency ablation versus control condition. *AJR Am J Roentgenol*. 2010;**194**(4):1137–1142.
14. Jang SW, Baek JH, Kim JK, Sung JY, Choi H, Lim HK, Park JW, Lee HY, Park S, Lee JH. How to manage the patients with unsatisfactory results after ethanol ablation for thyroid nodules: role of radiofrequency ablation. *Eur J Radiol*. 2012;**81**(5):905–910.
15. Spiezia S, Garberoglio R, Di Somma C, Deandrea M, Basso E, Limone PP, Milone F, Ramundo V, Macchia PE, Biondi B, Lombardi G, Colao A, Faggiano A. Efficacy and safety of radiofrequency thermal ablation in the treatment of thyroid nodules with pressure symptoms in elderly patients. *J Am Geriatr Soc*. 2007;**55**(9):1478–1479.
16. Lim HK, Lee JH, Ha EJ, Sung JY, Kim JK, Baek JH. Radiofrequency ablation of benign non-functioning thyroid nodules: 4-year follow-up results for 111 patients. *Eur Radiol*. 2013;**23**(4):1044–1049.
17. Jung SL, Baek JH, Lee JH, Shong YK, Sung JY, Kim KS, Lee D, Kim JH, Baek SM, Sim JS, Na DG. Efficacy and safety of radiofrequency ablation for benign thyroid nodules: a prospective multicenter study. *Korean J Radiol*. 2018;**19**(1):167–174.
18. Pacella CM, Bizzarri G, Guglielmi R, Anelli V, Bianchini A, Crescenzi A, Pacella S, Papini E. Thyroid tissue: US-guided percutaneous interstitial laser ablation—a feasibility study. *Radiology*. 2000;**217**(3):673–677.
19. Valcavi R, Riganti F, Bertani A, Formisano D, Pacella CM. Percutaneous laser ablation of cold benign thyroid nodules: a 3-year follow-up study in 122 patients. *Thyroid*. 2010;**20**(11):1253–1261.
20. Døssing H, Bennedbaek FN, Hegedüs L. Long-term outcome following interstitial laser photocoagulation of benign cold thyroid nodules. *Eur J Endocrinol*. 2011;**165**(1):123–128.
21. Trimboli P, Bini F, Marinozzi F, Baek JH, Giovannella L. High-intensity focused ultrasound (HIFU) therapy for benign thyroid nodules without anesthesia or sedation. *Endocrine*. 2018;**61**(2):210–215.
22. Lang BHH, Woo YC, Chiu KW. Two-year efficacy of single-session high-intensity focused ultrasound (HIFU) ablation of benign thyroid nodules. *Eur Radiol*. 2018;**19**:93–101.
23. Papini E, Rago T, Gambelunghe G, Valcavi R, Bizzarri G, Vitti P, De Feo P, Riganti F, Misischi I, Di Stasio E, Pacella CM. Long-term efficacy of ultrasound-guided laser ablation for benign solid thyroid nodules. Results of a three-year multicenter prospective randomized trial. *J Clin Endocrinol Metab*. 2014;**99**(10):3653–3659.
24. Moon WJ, Baek JH, Jung SL, Kim DW, Kim EK, Kim JY, Kwak JY, Lee JH, Lee JH, Lee YH, Na DG, Park JS, Park SW; Korean Society of Radiology. Ultrasonography and the ultrasound-based management of thyroid nodules: consensus statement and recommendations. *Korean J Radiol*. 2011;**12**(1):1–14.
25. Goldberg SN, Charboneau JW, Dodd GD III, Dupuy DE, Gervais DA, Gillams AR, Kane RA, Lee FT, Jr, Livraghi T, McGahan JP, Rhim H, Silverman SG, Solbiati L, Vogl TJ, Wood BJ; International Working Group on Image-Guided Tumor Ablation. Image-guided tumor ablation: proposal for standardization of terms and reporting criteria. *Radiology*. 2003;**228**(2):335–345.
26. Sacks D, McClenny TE, Cardella JF, Lewis CA. Society of Interventional Radiology clinical practice guidelines. *J Vasc Interv Radiol*. 2003;**14**(9 Pt 2):S199–S202.
27. Ha EJ, Baek JH, Lee JH, Kim JK, Shong YK. Clinical significance of vagus nerve variation in radiofrequency ablation of thyroid nodules. *Eur Radiol*. 2011;**21**(10):2151–2157.
28. Limone P, Mormile A, Deandrea M, Garino F, Gamarra E, Ragazzoni F. Mini-invasive techniques for the treatment of thyroid nodules: critical issues. In: *Lombardi CP, Bellantone R. Minimally Invasive Therapies for Endocrine Neck Diseases*, 9th ed. Karger; 2016:105–119.
29. Deandrea M, Garino F, Mormile A, Garberoglio R, Rossetto R, Bonelli N, Spiezia S, De Santis M, Monti S, Deiana MG, Toscano V, Cugini C, El Dalati G, Limone PP. Radiofrequency ablation for benign thyroid nodules according to different US features: an Italian multicentre prospective study. *Eur J Endocrinol*. 2019;**180**(1):79–87.
30. Deandrea M, Sung JY, Limone P, Mormile A, Garino F, Ragazzoni F, Kim KS, Lee D, Baek JH. Efficacy and safety of radiofrequency ablation versus observation for nonfunctioning benign thyroid nodules: a randomized controlled international collaborative trial. *Thyroid*. 2015;**25**(8):890–896.
31. Cesareo R, Pasqualini V, Simeoni C, Sacchi M, Saralli E, Campagna G, Gianni R. Prospective study of effectiveness of ultrasound-guided radiofrequency ablation versus control group in patients affected by benign thyroid nodules. *J Clin Endocrinol Metab*. 2015;**100**(2):460–466.
32. Baek JH, Lee JH, Valcavi R, Pacella CM, Rhim H, Na DG. Thermal ablation for benign thyroid nodules: radiofrequency and laser. *Korean J Radiol*. 2011;**12**(5):525–540.
33. Mauri G, Cova L, Monaco CG, Sconfienza LM, Corbetta S, Benedini S, Ambrogio F, Milani V, Baroli A, Ierace T, Solbiati L. Benign thyroid nodules treatment using percutaneous laser ablation (PLA) and radiofrequency ablation (RFA). *Int J Hyperthermia*. 2016;**15**:1–5.