

EXTENSIVE CLINICAL EXPERIENCE

Autoimmune Polyendocrinopathy-Candidiasis-Ectodermal Dystrophy

Jaakko Perheentupa

The Hospital for Children and Adolescents, Helsinki University Hospital, FIN-00029 Helsinki, Finland

Context: Autoimmune polyendocrinopathy-candidiasis-ectodermal dystrophy is known as a rare hereditary disease with classic triad of mucocutaneous candidiasis, hypoparathyroidism, and adrenocortical failure, two of which, diagnostic dyad, are required for the diagnosis. Evidently many patients suffer unrecognized because the condition is more variable and complex.

Objective: The objective of the study was to describe the variability of autoimmune polyendocrinopathy-candidiasis-ectodermal dystrophy for promoting recognition and adequate follow-up of patients.

Setting: The Finnish series of patients is the largest internationally.

Patients: The study population was all 91 known Finnish patients.

Results: Besides the classical triad, a dozen autoimmune endocrine and other components occurred variably, several of them dangerous.

The initial manifestation appeared within the age range of 0.2–18 yr, mucocutaneous candidiasis being part of it in 60% of the patients, hypoparathyroidism in 32%, and adrenocortical failure in 5%. But 23% of the patients had one to six other components before the diagnostic dyad: hepatitis, keratoconjunctivitis, chronic diarrhea, periodic rash with fever. The dyad appeared 0.2–20 yr later. Prevalence of most components increased with age, diabetes mellitus, hypothyroidism, and testicular failure becoming common toward middle age. Tubulointerstitial nephritis occurred in 9% of the patients, apparent mineralocorticoid excess in 9%, asplenia in 19% of adults, and oral or esophageal squamous cell carcinoma in 10% of patients older than 25 yr.

Conclusions: Any child or young adult with one of the many disease components should be examined for others and consideration of *AIRE* mutation assay. (*J Clin Endocrinol Metab* 91: 2843–2850, 2006)

AUTOIMMUNE POLYENDOCRINOPATHY-candidiasis-ectodermal dystrophy (APECED), also called autoimmune polyendocrine syndrome type I, is a rare autosomal recessive disease (OMIM 240300) with a complex picture discovered over decades (1–5). Chronic mucocutaneous candidiasis (MC), hypoparathyroidism (HP), and adrenocortical failure (AF) are its most common components, the classic triad. APECED has become of great theoretical interest because mutations of a previously unknown gene, *AIRE* (21q22.3), were shown to be its cause (6). At least 58 such mutations are known. APECED appears to occur worldwide, but is relatively common only in Iranian Jews, Sardinians, and Finns.

APECED belongs to the Finnish Heritage of Disease (7), and I have personally studied most of the 91 known Finnish patients and over four decades familiarized myself with the course of the disease in all of them. Various clinical, immunological, and genetic studies of this population have been

reported (4–6, 8–22). With regard to the *AIRE* genotype, they are a relatively uniform series, almost all being homozygotes or heterozygotes for mutation R257X. Because this Finmajor mutation appears also to be the most common one worldwide, the Finnish phenotype is of wider interest. What follows is a detailed description of it. Emphasis will be on the following: 1) wide variation of the clinical picture and course, even among patients with identical *AIRE* genotype, indeed between siblings; 2) less common disease components may dominate the picture, even over many years; and 3) kidney disease, apparent mineralocorticoid excess, asplenia, and oral or esophageal cancer are common but of unclear cause. On therapy, only some observations will be presented.

Patients and Methods

This overview of the Finnish APECED phenotype is based on my personal clinical experience with most and knowledge of all the known 91 patients (Table 1). I have studied 82 of them for up to 40 yr, following up 56 of them personally (those living in the south of the country) and 26 in cooperation with colleagues, most of whom trained with me. Also, my experience has provided the substance of guidelines for therapy, which I provided to all the clinicians who look after these patients.

All 91 patients but two fulfilled the classic diagnostic dyad, presence of at least two of MC, HP, and AF. Of the two exceptions (see no. 2 and 12 in Fig. 2), one was confirmed by mutation assay, and the other was based on unquestionable diagnosis of his sister (no. 13) and the facts that all three of his disease components were part of the APECED spectrum and his oral squamous cell cancer is a known complication of APECED.

The investigation was conducted in accordance with the Declaration of Helsinki and was formally approved by our ethics committee. All patients or guardians gave informed consent.

First Published Online May 9, 2006

Abbreviations: Abs, Autoantibodies; AF, adrenocortical failure; AME, apparent mineralocorticoid excess; APECED, autoimmune polyendocrinopathy-candidiasis-ectodermal dystrophy; DM, diabetes mellitus; HP, hypoparathyroidism; HT, hypothyroidism; MC, mucocutaneous candidiasis, chronic/recurrent; OF, ovarian failure; PA, pernicious anemia; PRA, plasma renin activity; TF, testicular failure; TIN, tubulointerstitial nephritis.

JCEM is published monthly by The Endocrine Society (<http://www.endo-society.org>), the foremost professional society serving the endocrine community.

TABLE 1. Basic demographics of the 91 patients

Female/male (n)	46/45 ^a
Age at onset of first component (yr)	0.2–18.0 (3.3) ^b
Age at diagnosis (yr)	0.6–45.2 (7.5)
Age at last follow-up (n = 65) (yr)	4.7–60.0 (32.9)
Age at death (n = 26) (yr)	6.8–63.0 (34.0)
<i>AIRE</i> mutation searched for	80/91 (88%)
R257X homozygote (genotype 1)	62/80 (77%)
R257X mixed heterozygote	15/80 (17%)
With L323SfsX51 (genotype 2)	6/80
With X546Cext59 (genotype 3)	4/80
With C311Y (genotype 4)	2/80
With K83E (genotype 5)	1/80
With M388lfsX36 (genotype 6)	1/80
With n.f. (genotype 7)	1/80
L323SfsX51; X546Cext59 (genotype 8)	1/80
n.f.	2/80

n.f., None found in the coding region of *AIRE*. This is the case with some 10% of the *AIRE* genes of APECED patients (23).

^a Seventy-five sibships: one of four, one of three, and 11 of two affected siblings. Number by decade of life, starting with the first (age < 10 yr), 4, 21, 18, 22, 16, 7, 3.

^b Range (median).

All the patients had been followed up at hospitals, and their lifetime clinical documents were available. I perused them collecting data on a Microsoft Access database (Microsoft, Redmond, WA).

Results

Patients as a group

The clinical picture seemed to vary between siblings as much as between other patients. The patients with mixed heterozygosity or those with undetected mutations or non-assayed genotype did not seem to differ clinically from the R257X homozygotes. Hence, all 91 patients were analyzed together.

The initial manifestation included MC in 55 and HP in 29 of the 91 patients, but many other components were variably part of it (Table 2). In fact 10 of the 91 patients had from one to three other components for 0.1–14 yr (median 1.7 yr) before any of the triad components. And with MC, 21 patients had from one to six other components for 0.2–25 yr (2.2 yr) before HP and AF. These other components included keratoconjunctivitis in 10 patients, chronic diarrhea in six, periodic rash with fever (and arthralgia in two patients) in six, and hepatitis in four patients.

The prevalence of most components increased with age (Table 3). However, the time courses differed markedly. The incidence of diabetes mellitus (DM), hypothyroidism (HT) (Fig. 1), and testicular failure (TF) peaked late relative to the others. In contrast, no new cases of keratoconjunctivitis and hepatitis appeared beyond the age of 16 yr.

Patient demographics

The clinical picture and course varied widely (Tables 1 and 2 and Fig. 2). The first sign of APECED was observed at age 0.2–18 yr. The diagnostic dyad was evident in 11 patients only at the age of 15–35 yr and in one not by the latest observation at 45 yr (no. 12 in Fig. 2). In 12 patients less common components dominated the picture until the age of 13–45 yr with candidiasis but neither HP nor AF present (no. 7, 12, and 14).

TABLE 2. First component and first endocrine component in the series of 91 patients

Component	No. of patients (%)
First component	
Part of the classical triad ^a	89
Nontriad ^b	11
Candidiasis with or followed by nontriad component(s) ^c	23
Candidiasis	60 (47) ^d
HP	32 (24)
AF	5 (2)
Keratoconjunctivitis	9 (4)
Chronic diarrhea ^e	5 (5)
Periodic rash with fever	4 (3)
Severe obstipation	4 (2)
Alopecia	3 (1)
Hepatitis	1 (–)
PA	1 (–)
Vitiligo	1 (1)
First endocrine component	
HP ^f	68 (64)
AF ^f	33 (29)
GH deficiency	1 (1)
HT	1 (1)
DM	1 (1)

^a Candidiasis (MC), HP, and AF.

^b Interval to the appearance of the first triad component was 0.1–14 yr (median 1.7 yr).

^c Interval to the appearance of HP or AF was 0.2–25 yr (2.2 yr).

^d When more than one component appeared together, all were counted (first number); for cases with the component appearing alone, the number is given in *parentheses*.

^e In some cases, diarrhea may have resulted from hypocalcemia of HP.

^f HP and AF appeared together in four patients.

The number varied from one to five (median two) for endocrine components and from two to 10 (five) for all disease components (excluding asplenia and dental, nail, and tympanic membrane dystrophies). Six adults (five men) remained with HP as the only endocrinopathy at age beyond 28 yr, besides MC (e.g. no. 11), two patients had alopecia and one pernicious anemia (PA). Similarly, six (all male) had AF as the only endocrine component at age beyond 32 yr; besides MC four of them had alopecia and two PA. The *AIRE* genotype, known for four of those HP patients and all the AF patients, was homozygosity for R257X.

Classic triad

MC occurred in all adult patients, at least periodically. In one case it appeared only during a febrile disease in the fourth decade of life (Table 3). In some, MC was observed in the nails before the mouth, and in two adults only nail infection was recorded, although it was assumed to be secondary to oral infection. In fact, one of the two (no. 12 in Fig. 2) developed oral cancer. Esophageal MC was diagnosed in 14 patients, usually associated with substernal pain, particularly on swallowing, but not always with oral MC at the same time. Several patients required esophageal stricture dilatation. A 39-yr-old woman with AF, HP, and ovarian failure (OF) and frequent recurrence of oral and intestinal MC developed long-lasting watery diarrhea with heavy growth of *Candida albicans* in stool culture. It persisted de-

TABLE 3. Prevalence^a (percent) of the diagnostic dyad^b and the most common disease components by age (birthdays) with age ranges at their appearance in the series of 91 patients

	Age (yr)										Age range (median) at appearance (yr)
	1	2	5	10	15	20	30	40	50		
Diagnostic dyad	0	0	21	70	85	94	97	99	99	99	2.2–35 (7.0)
Classic triad											
Candidiasis	17	30	48	83	93	96	98	100	100	100	0.2–31 (5.4)
HP	0	6	34	65	77	83	85	87	88	88	1.6–43 (6.0)
Adrenal failure	0	0	8	40	63	72	78	81	84	84	3.5–41 (10.0)
All three	0	0	3	25	50	56	64	71	76	76	3.5–43 (11.3)
Other endocrine disorders											
OF					35	53	60	69			–36
TF						8	12	28			–37
DM	0	0	2	3	7	10	13	23	33	33	4.1–58 (23.5)
HT	0	0	1	1	1	4	14	21	31	31	4.7–45 (26.5)
Skin disorders											
Alopecia	0	0	5	16	29	33	39	39	39	39	2.5–30 (10.3)
Vitiligo	1	1	2	9	17	20	27	31			0.7–45 (12.7)
Rash with fever	3	7	10	12	13	14	14	15			0.7–31 (2.8)
Gastrointestinal disorders											
PA	0	0	0	3	10	16	20	28	31	31	6.1–48 (17.2)
Severe obstipation	1	1	8	10	14	18	21	26			1.0–31 (13.0)
Chronic diarrhea ^c	0	0	8	13	16	17	22	22	22	22	2.5–27 (6.6)
Hepatitis	1	2	5	12	16	18	18	18	18	18	0.7–16 (8.0)
Eye disorders											
Keratoconjunctivitis	0	5	11	18	20	21	22	22	22	22	1.3–16 (5.4)

In a subgroup of 68 patients, the prevalence of enamel hypoplasia of permanent teeth was 77% (5).

^a Estimated from the observed incidence rates over the age intervals, assuming that all patients live until the age of 50 yr.

^b At least two of candidiasis, HP, and AF.

^c Does not include the diarrhea associated with hypocalcemia.

spite oral medication with amphotericin B and fluconazole but was cured for 2.5 yr (so far) by 2-wk iv amphotericin B therapy. A girl 12.9 yr old developed febrile genital candida infection. No deep infection was ascertained *in vivo*, but a 30-yr-old patient (no. 5 in Fig. 2) was at autopsy found to

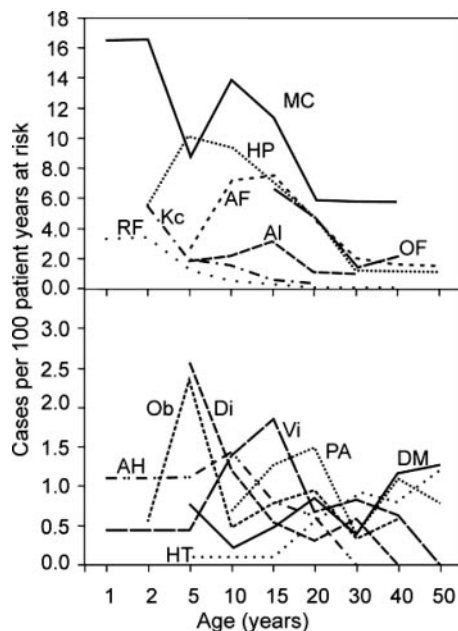


FIG. 1. Incidence rates (new cases in the preceding age interval divided by the number of person-years at risk and multiplied by 100) of 14 components of APECED according to age in 91 patients (46 females in case of ovarian failure). AH, autoimmune hepatitis; Al, alopecia; Di, chronic diarrhea; Kc, keratoconjunctivitis; Ob, severe obstipation; RF, rash with fever; Vi, vitiligo.

have *Candida* abscesses in the pericardium and small intestine, with necrotizing inflammation of the colon and mesenterium. Four males and two females developed squamous cell carcinoma of the mouth (24, 25) or esophagus (n = 1) at the age of 29–44 yr, meaning 10.5% of patients over 25 yr (Rautemaa, R., J. Hietanen, S. Niissalo, S. Pirinen, and J. Perheentupa, manuscript submitted). The males were smokers. Because of transplanted kidney, the youngest patient remained on immunosuppressive medication from age 23 yr. This very malignant neoplasm is presumably induced by chronic candidiasis. That notion is supported by the fact that no other malignancies occurred in our series. Hence, oral and esophageal candidiasis must be strictly controlled. The conazole-type systemic drugs should not be used in prevention because resistance may develop (Rautemaa, R., M. Richardson, P. Koukila-Kähkölä, M. Pfaller, M., H. Saxén, and J. Perheentupa, manuscript submitted). Another type of immune defect was observed in a boy (no. 2 in Fig. 2), whose severe susceptibility to pneumococcal pneumonias was due to defective antibody response to polysaccharide antigens.

HP was the only component with a distinct gender difference, appearing earlier and in a significantly larger proportion of females (98%) than males (71%) (21). No antibodies associated with HP could be confirmed (21), in contrast to a recent report (26), not even autoantibodies (Abs) to Ca²⁺ sensing receptor. AF (or its therapy) appeared to reduce susceptibility to HP: none of the 12 patients who had AF as the first endocrinopathy (or, in one case, second after HT) had HP by the mean age of 33.4 yr. In many of the patients, target calcemia was difficult to maintain, presumably in part due to variation in calcium intake and absorption. Evidently, loss of Mg²⁺ was associated with HP, and even severe man-

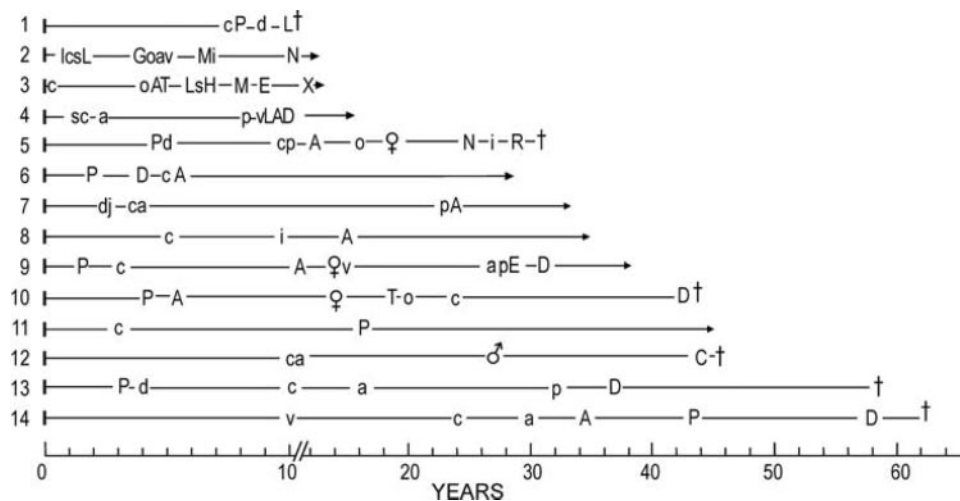


FIG. 2. Disease histories of 14 patients with APECED, selected to demonstrate the variability of the clinical picture and course. The lines start at birth and end at death (\dagger) or at age of the last observation (*arrowhead*). Age at appearance of disease component is indicated by symbol of the disease: A, adrenocortical failure; a, alopecia; C, carcinoma, oral squamocellular; c, candidiasis, mucocutaneous; D, diabetes mellitus; d, diarrhea, chronic; E, exocrine pancreatic failure; G, GH deficiency; H, hemolytic anemia, autoimmune; i, iridocyclitis; I, infections, exceptionally persisting/recurrent respiratory; j, arthralgia with fever; k, keratoconjunctivitis; L, hepatitis; M, mineralocorticoid excess, apparent; N, nephritis, tubulointerstitial; o, obstipation, severe; P, hypoparathyroidism; p, pernicious anemia; R, rheumatoid arthritis; s, periodic rash with fever; T, hypothyroidism; v, vitiligo; X, kidney transplantation; ♀, OF; ♂, TF. Patients no. 12 and 13 were brother and sister. Numbers 4 and 6–11 had *AIRE* genotype 1 (Table 1), no. 2 and 14 genotype 2, and no. 3 genotype 7. The others died before availability of DNA analysis.

ifestation of magnesium deficiency, nonhypocalcemic convulsion, was not rare. Hence, I recommend a Ca^{2+} preparation containing Mg^{2+} and a small dose of cholecalciferol.

AF developed variably: deficiencies of cortisol and aldosterone appeared often years apart, either way. One patient (no. 7 in Fig. 2) had cortisol deficiency since age 23 yr but no salt loss by present age of 33 yr. When Ab assay indicated adrenalitis (10, 24), its progress was easily monitored with a 2-h ACTH stimulation test, plasma renin activity (PRA), and salt restriction test (9, 10). This Ab positivity led sooner or later to AF, except in two patients whose Abs disappeared. AF was associated with HLA-DRB1*03 (18).

Other endocrinopathies

DM (type 1 in all but two of 17 of 91 patients) became prevalent toward middle age. As in the general population, HLA-DRB1*15-DQB1*0602 appeared to protect against type 1 DM (18). Interestingly, whereas the prevalence of the isolated type 1 DM internationally is highest in Finland (27), so is also the prevalence of type 1 DM in APECED patients (Table 3) (25).

High-titer antithyroid Abs were frequent, but HT became common only relatively late. Yet in a boy (no. 3 in Fig. 2), it appeared at age 4 yr as the first endocrinopathy. Hyperthyroidism occurred once: a 26-yr-old female was mildly hyperthyroid with absence of thyroïdal radioiodide uptake indicating acute autoimmune thyroiditis, which progressed to HT in 2 months.

GH deficiency (25, 28) was diagnosed in five patients, at age 5–15.4 yr.

Of patients with OF, 12 of 23 had absence or early interruption of spontaneous pubertal development. OF appeared

associated with AF: all the patients with OF had AF; only one developed AF after OF. Steroid cell and steroid side-chain-cleavage enzyme Abs in female patients are good predictors of ovarian failure (10, 25).

Of the 12 non-OV and 23 OV patients over 16 yr of age, six and 11, respectively, were living in a steady pair relation. Four and one of them, respectively, had given birth to a child, the latter at the age of 33, shortly before her ovaries started to fail. Four of the 11 other OV persons had resorted to ovum donation. Two were successful, another aborted at midpregnancy and lost her uterus, and the fourth gave up after several attempts.

Male hypogonadism was heterogeneous: of the seven cases, three had azoospermia evidently with otherwise normal sexual function, three others had primary testicular atrophy, and one was hypogonadotropic. Five of the seven had AF; the other two were azoospermic (29), one of them with a history of mumps orchitis.

Skin diseases

Alopecia was in 11 of 32 cases present before the diagnostic dyad. It usually appeared as patchy loss of hair, often followed by some regrowth, but became universal in 22 patients. It was strongly associated with HLA-DRB1*04-DQB1*0302 (18). Although our social security pays fully for good-quality wigs, to some females alopecia was more distressing than AF, HP, OF, and keratoconjunctivitis.

Vitiligo was variable in extent, from spots to almost universal. It was the first component in one of 23 cases and appeared before the diagnostic dyad in five.

Periods of maculopapular, morbilliform, or urticarial rash of fleeting character, usually with fever and in two patients with arthralgia, occurred in 13 patients, continuing for 0.2–1.2 yr (Table 4). Of these 13, five, 0.7–1.2 yr old, had plasma

TABLE 4. Unusual, less known, and possible components and complications of APECED in the series of 91 patients

Periodic rash with fever (14%), appearing at age 0.7–31 yr and lasting for 0.1–1.2 yr ^a
Asplenia (9% at age 5–15 yr, 19% at age > 17 yr) ^b
Squamous cell carcinoma of mouth or esophagus (10.5% at age > 25 yr)
Hypokalemia or AME (15%) appearing at 5–28 (median, 14) yr ^c
TIN (9%), evident by 10–21 yr ^d
Chronic iridocyclitis (8%) appearing at 6–27 yr
Dry eye (11%) evident by 6–48 yr ^e
Exocrine pancreatic insufficiency (4%) by 4–28 yr ^f
Following conditions, each in one case ^g
Case 1, Autoimmune hemolytic anemia (at 6 yr) (25)
Case 2, Bronchitis obliterans organizing pneumonia (at 9 yr)
Case 3, Fulminant RA (at 28 yr)
Case 4, Hypoplastic anemia (at 30 yr)
Case 5, Sjögren syndrome (at 51 yr) (25)
Case 5, Amyotrophic lateral sclerosis (at 52 yr)

^a Proportion of patients observed with the component.

^b By sonography of 11 children and 43 adult patients.

^c Of eight (three male) patients with AME, six had AF, five HP, five OF, two DM, two HT, three active or inactive hepatitis, two PA, four TIN; of the six (four male) others, all had AF, six HP, two OF, one DM, one HT, four AH, four PA, one TIN.

^d Of eight (two male) patients, six had HP, six AF, five OF, two HT, one DM, and one PA.

^e One of these patients is no. 5 in next group.

^f Of five (three male) patients, four had AF, four had periodic rash with fever, three had HP, two had autoimmune hepatitis. DM, OF, HT, PA, and TIN each affected one patient.

^g Other components for case 1, see no. 3 in Fig. 2; case 2, OF, hepatitis; case 3, see no. 5 in Fig. 2; case 4, HP, AF, OF, DM, TIN; and case 5, HP, AF.

IgG levels of 24–51 g/liter (normal range up to 17 g/liter). One of those five patients had a recurrence, at the age of 9.7–9.9 yr. A skin biopsy was performed in four cases: two had lymphoplasmacytic vasculitis (25), the others no specific pathology. This may be another autoimmune component.

Gastrointestinal

Hepatitis was of variable severity. Fulminant necrotizing disease killed three of 16 of the patients within a few weeks at age 10–15 yr (5, 25). In the youngest of these, the immediate cause of death was sepsis with *Listeria monocytogenes*, which developed during her strong immunosuppressive medication. Several others survived with years of azathioprine medication. In nine others asymptomatic elevation of plasma alanine aminotransferase up to 2-fold the upper normal range subsided over some months without immunosuppression.

Pernicious anemia was almost always preceded by supranormal plasma levels of antiparietal cell or intrinsic factor blocking Abs or both.

Chronic diarrhea was of variable etiology and duration. In some cases diarrhea heralded the appearance of HP and then signaled hypocalcemia in patients with HP. Exocrine pancreas failed (30) in five of the 16 patients, and one had defective bile acid reabsorption. In five cases diarrhea alternated with obstipation, presumably due to autoimmune intestinal endocrine dysfunction (30). Intestinal candidiasis (25) caused severe diarrhea, even in absence of clear oral infection. Another patient had multiple periods of severe

diarrhea with intestinal *Clostridium difficile* infection. Severe obstipation probably contributed to death of a girl (Table 5).

Ocular disease

Bilateral keratoconjunctivitis was an early component (Fig. 1). Ten patients were blind, probably because of insufficient intensity of early therapy. Three of them received corneal transplants, with slight improvement of vision (19).

Cortical lenticular opacities, ascribed to HP or its therapy, were present in 10 of 52 appropriately examined patients (16). Six patients had chronic iridocyclitis (Table 4), two had optic atrophy, and two retinal degeneration (16). Eleven needed therapy for dry eyes (16) (Table 4).

Other

Hypokalemia with arterial hypertension was a varying long-term (3–10 yr) problem in 14 patients (Table 4), which can be divided into two subgroups. The first one of eight patients manifested apparent mineralocorticoid excess (AME), with suppressed PRA and subnormal plasma aldosterone levels in absence of mineralocorticoid medication. Two of them had neither AF nor circulating adrenocortical Abs. These two and two others of this subgroup had tubulointerstitial nephritis (TIN). Two others (with AF and without TIN) later developed need of mineralocorticoid substitution. The second subgroup of six patients all had AF with salt loss necessitating mineralocorticoid substitution. However, they were very sensitive to it so that even a very small dose (0.025 mg fludrocortisone acetate every 1–5 d) caused hypokalemia with PRA suppression. The problem could be managed by searching for each patient a suitable combination of K-sparing diuretic, slow-release KCl, and fludrocortisone acetate. However, their balance remained unstable, and it was often necessary to readjust the medication. Sometimes the mineralocorticoid was better discontinued. Thus, some of the individual patients shifted between the two subgroups. Elevated basal cortisol levels of early adrenalitis (9) are an unlikely cause of AME. We found no clear evidence of stimulated endogenous mineralocorticoid secretion. TIN may have caused the AME in some cases. But apparently in most cases the problem was caused by consumption of salted licorice (31). It turned out to be very difficult to stop, especially at teenage. In many cases the amount consumed appeared small. These patients might be exceptionally sensitive to licorice or have an unusual craving for it. Glycyrrhizic acid assay was not available.

TIN affected the total eight patients (Table 4). Four of them developed terminal renal failure at the age of 10 (with AME), 19, 20, and 29 yr. The three youngest of those four received a kidney transplant, which functioned well at the latest observation 0.5, 16, and 21 yr postoperatively. The oldest of the four had severe distal tubular acidosis with K⁺ loss (base excess around –20 mmol/liter); she died at the age of 30 yr (no. 5 in Fig. 2), and autopsy revealed nephrocalcinosis with TIN. She and the second oldest of the four had experienced long periods of severe hypercalcemia due to unsatisfactory follow-up. Of note is that the two youngest of the eight TIN patients (as already mentioned in the preceding paragraph) had no HP: the 10-yr-old boy with kidney transplant and a

TABLE 5. Causes of death

No. of cases	Cause (patients' characteristics ^a)
2	Accident (7F dPp; 17M ALP 1)
3	Fulminant hepatitis (10M LPd; 13F AakLP 1, <i>Listeria</i> sepsis; 15F AakLoPp)
4	Oral/esophageal squamous cell carcinoma (34M AkPp 1; 36F AGP 1; 42M AaDPT 1; 45M aG)
4	Unclear cause, death occurred before the complexity of APECED was known (6F DdP; 12F adkP; 54M Pp; 59F aDdP), Addisonian crisis possible
7	Loners unexpectedly found dead or moribund at home ^b (24M AkP 5; 26M AakP 4; 35M ADP 1; 42F AEGP 1; 43F AEDoPGT 1; 46M AGkLPT 1; 62M AaDkP 2)
6	Diverse <i>Campylobacter</i> sepsis, severe coprostasis and negligence of medication (19F AgoP 1); septicemia after replacement surgery of hip joint destroyed by fulminant rheumatoid arthritis (25) (29F AdGNPpR); pulmonary embolism after air travel (32F AaDkoPT 4); acute alcohol intoxication (43M AaEGP 1); amyotrophic lateral sclerosis (54F AoP 1); Parkinson's disease (66M AGP)

A, AF; a, alopecia, universal; D, DM; d, diarrhea, chronic; E, alcoholism, chronic; G, hypogonadism; k, keratoconjunctivitis; L, hepatitis; N, nephritis, tubulointerstitial; o, obstipation, severe; P, HP; p, PA; R, rheumatoid arthritis; T, HT; M, male; F, female.

^a Age in years, sex (M/F), main disease components and complications, *AIRE* genotype number (Table 1), if known. All had mucocutaneous candidiasis.

^b No clear cause of the sudden death was identified at autopsy.

12-yr-old nonuremic boy with distal tubular acidosis both had AME (no. 2 and 3 in Fig. 2).

APECED may cause great psychosocial burden. The persistent risk of developing new, possibly life-threatening, disease components, and the often disfiguring superficial disease components can be a source of continuous distress. Oral candidiasis requires strict control, sometimes continuous medication. HP, AF, and DM and their treatments influence each other. Patients with two of these components and, particularly those with all three, are prone to metabolic imbalance and big fluctuations in wellness. Teenage patients often deny their disease and neglect therapy, sometimes with life-threatening consequences. Depression and suicidal thoughts are not infrequent. Peer group support has proved valuable; our patients established their own association, and meetings and mutual contacts have had positive influence on those who joined the group. Professional psychosocial support should also be readily available.

Discussion

The *AIRE* mutation R257X enriched in the small population (5.5 million) of Finland has generated the internationally largest series of patients with APECED. Our national public health service has allowed us to centralize their management. Hence, I am able to present longitudinal data demonstrating the variable evolution of this complex disease over a lifetime. The prevalence of the disease components increases with age; thus, only age-specific prevalence figures have full meaning. Apparently only the Finnish series is large enough for useful estimation of such figures, even up to the age of 50 yr (Table 3).

My most striking finding is the wide variation of the clinical picture and course of APECED. Little is known about the basis of this variation. It was not clearly less between affected siblings than between other patients. In a study of 127 patients, half of them Finnish, the only observed association between *AIRE* genotype and APECED phenotype was higher prevalence of candidiasis in patients homozygous or heterozygous for the Finmajor mutation R257X than in those with other mutations (18). AF and MC showed the same

human leukocyte antigen associations and type 1 DM the same negative human leukocyte antigen correlation that are known for these diseases in non-APECED patients. But most of the phenotypic variation of APECED remains unexplained.

For safety of the patients, early diagnosis of APECED and ongoing regular surveillance are critical. The surveillance must include accessibility of an expert when something new arises. With regard to early diagnosis, it is most important to know the variability of the early clinical picture. The classic diagnostic dyad allows early recognition of only a minority of new cases. Its presence is diagnostic, but its absence is of no diagnostic value. The well-known and useful hallmark of APECED, chronic oral candidiasis, when present after the newborn period, should bring APECED into mind. However, it was present at the first manifestation in less than two thirds of the Finnish patients, despite being associated with the predominant Finnish mutation (18). It may be much less common elsewhere. Of 24 Iranian Jewish patients, who have their own unique mutation, candidiasis was observed in only four (32). According to the Finnish phenotype hepatitis, keratoconjunctivitis, periodic rash with fever, chronic diarrhea, severe obstipation, alopecia, and vitiligo should be recognized as potential early components of APECED. The same holds for apparently isolated hypoparathyroidism or adrenocortical failure, especially in children, but even anyone under 30 yr of age. Observing one of these diseases calls for scrutiny for other components of APECED, including the visible oral, ophthalmic, and dermal features. Search for *AIRE* mutations should be considered, particularly if more than one component is present.

In Finland, availability of an assay for our three commonest *AIRE* mutations allows quite reliable recognition of new cases. Our two youngest patients, sisters, are good examples. They received the diagnosis of APECED at the age of 0.6 and 2.3 yr. They had oral candidiasis from age 0.2 and 1.4 yr, and hence, their parents took them to see a pediatrician. The message about early features of APECED had reached the pediatrician, who referred them to their university hospital as suspected cases of APECED. Both were found to be ho-

mozygous for R257X. The hospital followed them up and diagnosed HP at a presymptomatic stage at the age of 2.7 and 6.0 yr, respectively. The family was informed of how the disease may evolve and the importance of lifelong ongoing surveillance.

Our patient group has willingly participated in research of their disease in cooperation with domestic and foreign research groups. This led to discovery of the *AIRE* gene (6), development of the mutation assay, and extensive ongoing research on the molecular biology of *AIRE*. Similarly, much has been learned of the immunology of APECED. So far these other recent advances of basic research on APECED have not much helped the clinician. Certain Abs (22) may be helpful when the assays are available. Combined analysis for Abs against steroid 21-hydroxylase, side-chain cleavage enzyme, and aromatic L-amino acid decarboxylase has been suggested to identify patients with APECED (22), but this approach is likely to give false negatives in young children. Presence of circulating antiinterferon Abs at a very early stage appears promising (33).

Tubulointerstitial nephritis of an APECED patient was recently reported, with detection of antiproximal tubular Abs (34). I now report on TIN affecting 9% of our patients (Table 4). Because TIN belongs to the most dangerous components, its autoimmune origin should be rapidly confirmed and ways for early detection and prevention searched for. In our series asplenia (35) was also relatively common, and there was a suggestion of increasing prevalence with age (Table 4). Hence, autoimmune origin appears likely, even for this component. Presently only hepatitis and, perhaps, intestinal dysfunction and keratoconjunctivitis (30) can be repelled with immunosuppressive medication. With regard to the other components, the risks of immunosuppression seem to outweigh its potential benefits.

With all the intense APECED-related basic research going on in research centers globally, the clinician remains optimistic that new ways of limiting the autodestruction caused by this nasty disease will become available.

Acknowledgments

Received December 7, 2005. Accepted May 1, 2006.

Address all correspondence and requests for reprints to: Jaakko Perheentupa, Merikatu 3A2, FIN-00140 Helsinki, Finland. E-mail: jaakko.perheentupa@saunalahti.fi.

The author has no conflicts of interest.

References

1. Thorpe E, Handley H 1929 Chronic tetany and chronic mycelial stomatitis in a child aged four and one-half years. *Am J Dis Child* 28:328–338
2. Whitaker J, Landing BH, Esselborn VM, Williams RR 1956 The syndrome of familial juvenile hypoadrenocorticism, hypoparathyroidism and superficial moniliasis. *J Clin Endocrinol Metab* 16:1374–1387
3. Neufeld M, Maclaren NK, Blizzard RM 1981 Two types of autoimmune Addison's disease with different polyglandular autoimmune syndromes. *Medicine* 60:355–362
4. Perheentupa J 1980 Autoimmune polyendocrinopathy-candidiasis-ectodermal dystrophy (APECED). In: Eriksson AW, Forsius HR, Nevanlinna HR, Workman PL, Norio RK, eds. Population structure and genetic disorders. London: Academic Press; 583–588
5. Ahonen P, Myllärniemi S, Sipilä I, Perheentupa J 1990 Clinical variation of autoimmune polyendocrinopathy-candidiasis-ectodermal dystrophy (APECED) in a series of 68 patients. *N Engl J Med* 322:1829–1836
6. The Finnish-German APECED Consortium 1997 An autoimmune disease, APECED, caused by mutations in a novel gene featuring two PHD-type zinc-finger domains. *Nat Genet* 17:399–403
7. Norio R 2003 The Finnish disease heritage III: the individual diseases. *Hum Genet* 112:470–526
8. Myllärniemi S, Perheentupa J 1978 Oral findings in the autoimmune polyendocrinopathy-candidiasis syndrome (APECED) and other forms of hypoparathyroidism. *Oral Surg* 45:721–729
9. Leisti S, Ahonen P, Perheentupa J 1983 The diagnosis and staging of hypocortisolism in progressing autoimmune adrenalitis. *Pediatr Res* 17:861–867
10. Ahonen P, Miettinen A, Perheentupa J 1987 Adrenal and steroidal cell antibodies in patients with autoimmune polyglandular disease type I and risk of adrenocortical and ovarian failure. *J Clin Endocrinol Metab* 64:494–500
11. Uibo R, Aavik E, Peterson P, Perheentupa J, Krohn KJE 1994 Autoantibodies to cytochrome P450 enzymes P450_{scc}, P450_{c17}, and P450_{c21} in autoimmune polyglandular disease types I and II and in isolated Addison's disease. *J Clin Endocrinol Metab* 78:323–328
12. Uibo R, Perheentupa J, Ovod V, Krohn KJE 1995 Characterization of adrenal autoantigens recognized by sera from patients with autoimmune polyglandular syndrome type I. *J Autoimmun* 7:399–411
13. Tuomi T, Björnsen P, Falorni A, Partanen J, Perheentupa J, Lernmark Å, Miettinen A 1996 Antibodies to glutamic acid and decarboxylase and insulin-dependent diabetes in patients with APS1. *J Clin Endocrinol Metab* 81:1488–1494
14. Peterson P, Perheentupa J, Krohn KJ 1996 Detection of candidate antigens in autoimmune polyglandular syndrome type I. *Clin Diagn Lab Immunol* 3:290–294
15. Gylling M, Tuomi T, Björnsen P, Kontiainen S, Partanen J, Christie MR, Knip M, Perheentupa J, Miettinen A 2000 β -Cell autoantibodies, human leukocyte antigen II alleles, and type 1 diabetes in autoimmune polyendocrinopathy-candidiasis-ectodermal dystrophy. *J Clin Endocrinol Metab* 85:4434–4440
16. Merenmies L, Tarkkanen A 2000 Chronic bilateral keratitis in autoimmune polyendocrinopathy-candidiasis-ectodermal dystrophy. *Acta Ophthalmol Scand* 78:532–535
17. Obermayer-Straub P, Perheentupa J, Braun S, Kayser A, Barut A, Loges S, Harms A, Dalekos G, Strassburg CP, Manns MP 2001 Hepatic auto-antigens in patients with autoimmune polyendocrinopathy-candidiasis-ectodermal dystrophy. *Gastroenterology* 121:668–677
18. Halonen M, Eskelin P, Myhre AG, Perheentupa J, Husebye ES, Kampe O, Rorsman F, Peltonen L, Ulmanen I, Partanen J 2002 *AIRE* mutations and human leukocyte antigen genotypes as determinants of the autoimmune polyendocrinopathy-candidiasis-ectodermal dystrophy phenotype. *J Clin Endocrinol Metab* 87:2568–2574
19. Tarkkanen A, Merenmies L 2001 Corneal pathology and outcome of keratoplasty in autoimmune-candidiasis-ectodermal dystrophy. *Acta Ophthalmol Scand* 79:204–207
20. Perheentupa J 2002 APS-I/APECED: the clinical disease and therapy. In: Eisenbarth GS, ed. Autoimmune polyendocrine syndromes. *Endocrinol Metab Clin North Am* 31:295–320
21. Gylling M, Kääriäinen E, Väisänen R, Kerosuo L, Solin M-L, Halme L, Saari S, Kampe O, Perheentupa J, Miettinen A 2003 The hypoparathyroidism of autoimmune polyendocrinopathy-candidiasis-ectodermal dystrophy (APECED). Protective effect of male sex. *J Clin Endocrinol Metab* 88:4602–4608
22. Söderbergh A, Myhre AG, Ekwall O, Gebre-Medhin G, Hedstrand H, Landgren E, Miettinen A, Eskelin P, Halonen M, Tuomi T, Gustafsson J, Husebye E, Perheentupa J, Gylling M, Manns MP, Rorsman F, Kampe O, Nilsson T 2004 Prevalence and clinical associations of ten defined autoantibodies in autoimmune polyendocrine syndrome type I. *J Clin Endocrinol Metab* 89:544–547
23. Ilmarinen T, Eskelin P, Halonen M, Ruppell T, Kilpikari R, Torres GD, Kangas H, Ulmanen I 2005 Functional analysis of SAND mutations in *AIRE* supports dominant inheritance of the G228W mutation. *Hum Mutat* 26:322–331
24. Richman RA, Rosenthal IM, Solomon LM, Karachorlu KV 1975 Candidiasis and multiple endocrinopathy. With oral squamous cell carcinoma complications. *Arch Dermatol* 111:625–627
25. Betterle C, Greggio NA, Volpato M 1998 Autoimmune polyglandular syndrome type I. *J Clin Endocrinol Metab* 83:1049–1055
26. Li Y, Song Y-H, Rais N, Connor E, Schatz D, Muir A, Maclaren N 1996 Autoantibodies to the extracellular domain of the calcium sensing receptor in patients with acquired hypoparathyroidism. *J Clin Invest* 97:910–914
27. Karvonen M, Viik-Kajander M, Moltchanova E, Libman I, LaPorte R, Tuomilehto J, for the Diabetes Mondiale Project Group 2000 Incidence of childhood type 1 diabetes worldwide. *Diabetes Care* 23:1516–1526
28. Franzese A, Valerio G, Di Maio S 1999 Growth hormone insufficiency in a girl with the autoimmune polyendocrinopathy-candidiasis-ectodermal dystrophy. *J Endocrinol Invest* 22:66–69
29. Tsatsoulis A, Shalet SM 1991 Antispermatogenic antibodies in the polyglandular autoimmune syndrome type I: response to cyclical steroid therapy. *Clin Endocrinol (Oxf)* 35:299–303
30. Ward L, Paquette J, Seidman E, Huot C, Alvarez F, Crock P, Delvin E, Kampe

- O, Deal C 1999 Severe autoimmune polyendocrinopathy-candidiasis-ectodermal dystrophy in an adolescent girl with a novel AIRE mutation: response to immunosuppressive therapy. *J Clin Endocrinol Metab* 84:844–852
31. Stewart PM, Wallace AM, Valentino R, Burt D, Shakleton CHL, Edwards CLW 1987 Mineralocorticoid activity of liquorice: 11 β -hydroxysteroid dehydrogenase deficiency comes of age. *Lancet* 2:821–823
32. Zlotogora J, Shapiro MS 1992 Polyglandular autoimmune syndrome type I among Iranian Jews. *J Med Genet* 29:302–306
33. Meager A, Visvalingam K, Peterson P, Möll K, Murumägi A, Krohn K, Eskelin P, Perheentupa J, Husebye E, Kadota Y, Willcox N, Anti-interferon autoantibodies in autoimmune polyendocrinopathy syndrome type 1. *PLoS Med*, in press
34. Ulinski T, Perrin L, Morris M, Houang M, Cabrol S, Grapin C, Chabbert-Buffet N, Bensman A, Deschênes G, Giurgea I 2006 Autoimmune polyendocrinopathy-candidiasis-ectodermal dystrophy syndrome with renal failure: impact of posttransplant immunosuppression on disease activity. *J Clin Endocrinol Metab* 91:192–195
35. Friedman TC, Thomas PM, Fleischer TA, Feuillan P, Parker RJ, Cassorla F 1991 Frequent occurrence of asplenism and cholelithiasis in patients with autoimmune polyendocrine disease type I. *Am J Med* 91:625–630

JCEM is published monthly by The Endocrine Society (<http://www.endo-society.org>), the foremost professional society serving the endocrine community.