

Approach to the Patient with Possible Cushing's Syndrome

Marco Boscaro and Giorgio Arnaldi

Division of Endocrinology, Polytechnic University of Marche, 60126 Ancona, Italy

Clinical decision making for patients with suspect hypercortisolism involves a complex diagnostic assessment. Cushing's syndrome remains one of the most challenging endocrine pathologies. Most clinical features overlap with those of common diseases found in the general population, and some patients have an atypical clinical presentation with only isolated symptoms. Recently, several studies have suggested that the prevalence of Cushing's syndrome is higher than previously thought. Therefore, efficient screening tests are needed to identify the few uncovered patients also among unselected high-risk ambulatory patients with disorders potentially related to cortisol excess. The recommended diagnostic tests are 24-h urinary free cortisol, 1-mg overnight dexamethasone suppression test, and late-night salivary cortisol. Once the diagnosis of Cushing's syndrome is established, the next step is the measurement of plasma ACTH. Then, dynamic test and appropriate imaging procedures are the most useful noninvasive investigations for the differential diagnosis. Patients with Cushing's disease are generally responsive to the CRH test and to high-dose glucocorticoid feedback. Bilateral inferior petrosal sinus sampling is considered the gold standard for establishing the origin of ACTH secretion, and it is recommended in patients with ACTH-dependent Cushing's syndrome whose clinical, biochemical, or radiological studies are discordant or equivocal. The present clinical case shows that even if rare, the ectopic ACTH secretion should be considered also in those cases where the pretest probability is low. The management of Cushing's syndrome depends on the exact knowledge of its various causes, paying attention to the many potential diagnostic pitfalls. The choice of test, the modality of specimen collection (blood, urine, and saliva), the quality of measurement (assay methodology and standardization), and close dialogue among endocrinologists, chemical pathologists, and neuroradiologists are key factors for optimal care of patients. (*J Clin Endocrinol Metab* 94: 3121–3131, 2009)

A 46-yr-old woman was referred to our department with suspected hypercortisolism. She had a 10-yr history of mild arterial hypertension that had worsened in the last few months in concomitance with oligomenorrhea, sleep disturbance, and mood disorder. She had a recent history of fatigue, an 8-kg weight increase in 1 yr, and no history of alcohol drinking or drugs except for antihypertensive agents (ramipril and nifedipine).

Her physical examination showed a weight of 68 kg with body mass index of 29 kg/m². Morning orthostatic blood pressure was 140/100 mm Hg despite therapy. A

central distribution of fat with a cervical fat pad and moon facies was associated with easy bruising. No hirsutism or acne was observed.

Plasma biochemistry requested by her family doctor were as follows: glycemia 108 mg/dl, triglycerides 180 mg/dl, cholesterol 210 mg/dl, sodium 140mEq/liter, and potassium 3.6 mEq/liter. Hematological parameters such as renal and liver function were normal. Morning plasma cortisol was normal (18 μg/dl, normal range 5–20 μg/dl), whereas 24-h urinary free cortisol was slightly elevated (268 μg/24 h, normal range 10–150 μg/24 h).

ISSN Print 0021-972X ISSN Online 1945-7197

Printed in U.S.A.

Copyright © 2009 by The Endocrine Society

doi: 10.1210/jc.2009-0612 Received March 19, 2009. Accepted May 13, 2009.

Abbreviations: AIMAH, ACTH-independent macronodular adrenal hyperplasia; BIPSS, bilateral inferior petrosal sinus sampling; BMD, bone mineral density; CT, computed tomography; DST, dexamethasone suppression test; HDDST, high-dose dexamethasone suppression test; MRI, magnetic resonance imaging; PET, positron emission tomography; PPNAD, primary pigmented nodular adrenocortical disease; UFC, urinary free cortisol.

TABLE 1. Causes of Cushing's syndrome (data based on the authors' patient population; n = 423)

Diagnosis	Patient (%)
ACTH-dependent	
Pituitary-dependent Cushing's syndrome (Cushing disease)	65
Ectopic ACTH syndrome (<i>i.e.</i> bronchial, thymic, pancreatic carcinoids, medullary thyroid carcinoma, etc.)	7
Ectopic CRH syndrome	<1
ACTH-independent	
Adrenal adenoma	18
Adrenal carcinoma	6
PPNAD (including the Carney complex)	1
AIMAH (aberrant expression of ectopic and eutopic membrane receptors: gastric inhibitory polypeptide, catecholamines, or LH/human chorionic gonadotropin, vasopressin, and serotonin)	3

Background

Chronic glucocorticoid excess, whatever its causes, is accompanied by a wide range of signs and symptoms known as Cushing's syndrome. This condition most commonly arises from iatrogenic causes when glucocorticoids have been used as antiinflammatory and/or immunosuppressive treatment. The pathogenetic mechanisms of endogenous Cushing's syndrome can be divided into ACTH dependent and ACTH independent (Table 1). The most common form (80%) is caused by ACTH-secreting pituitary adenoma, which is termed Cushing's disease from Harvey Cushing who in 1932 first described the presence of basophilic pituitary adenomas as a cause of the disease. The remaining 20% of ACTH-dependent forms are due to extrapituitary tumors (ectopic ACTH secretion). Cushing's syndrome can be ACTH independent when it results from cortisol excess by adrenocortical tumors, either benign or malignant, or by bilateral primary micro- and macronodular adrenocortical hyperplasia.

Although there is little epidemiological data on the incidence of Cushing's syndrome, this is an uncommon disorder with an estimated annual incidence of 2.3 million/yr (1). Cushing's disease occurs predominantly in women (female to male ratio ranging from 3:1 to 10:1) (2). It is interesting to note that over the last few years, screening studies have indicated a significant rise in the prevalence of Cushing's syndrome. In tertiary endocrine referral centers, the prevalence rate among patients with uncontrolled diabetes mellitus or osteoporosis can be as high as 5% (3–6). The impact of these data on the management of patients with common disorders in the general population, such as obesity, hypertension, diabetes, and menstrual irregularities, is very important, and an optimal

TABLE 2. Signs and symptoms of Cushing's syndrome (data based on the authors' patient population; n = 423)

Sign/symptom	Frequency (%)
Truncal obesity	97
Moon face	89
Hypertension	76
Skin atrophy and bruising	75
Diabetes or glucose intolerance	70
Gonadal dysfunction	69
Muscle weakness	68
Hirsutism, acne	56
Mood disorders	55
Osteoporosis	40
Edema	15
Polydipsia/polyuria	10
Fungal infection	8

screening strategy to be used in these cases is essential. The evaluation of a patient with suspected hypercortisolism is often complex, confusing, and expensive.

Clinical Consideration: Recognize and Confirm Cushing's Syndrome

The clinical manifestations of Cushing's syndrome are variable and differ widely in severity depending on the degree and duration of hypercortisolism and probably on glucocorticoid receptor sensitivity (7) (Table 2). The classical phenotype, including cardiovascular, metabolic, dermatological, musculoskeletal, and psychiatric manifestations, is generally familiar to the clinician, but in many cases, the clinical picture is much less clear and can be deceptive. Moreover, some patients may have only isolated symptoms and with an atypical presentation including mild and cyclic hypercortisolism (8).

Truncal obesity is the most common manifestation and is often the initial symptom in patients. The weight gain can be minimal, and sequential photographs of the patient over many years can be extremely helpful in demonstrating progression to a typical moon facies. The clinical suspicion arises in the presence of central obesity with face and supraclavicular fat accumulation, a cervical fat pad, thinned skin, purple striae, proximal muscle weakness, fatigue, hypertension, impaired glucose metabolism and diabetes, acne, hirsutism, and menstrual irregularities. Muscular atrophy and easy bruising are particularly helpful stigmata in adult patients. Osteoporosis, fractures, and neuropsychological disturbances including depression, emotional irritability, sleep disturbances, and cognitive deficits are also frequently observed (9–11).

Our patient presents some clinical features such as fatigue, weight increase mainly affecting the face, neck, and abdo-

men, easy bruising, poor control of hypertension, menstrual irregularities, and mood changes strongly suggestive of hypercortisolism.

But many of these symptoms such as obesity, hypertension, menstrual irregularities, and mood disorders are extremely common in the general population, and on the contrary, Cushing's syndrome is an uncommon disease. Moreover, with the decline in estrogen levels, women often report sleeping difficulties and mood changes, central fat mass increase, hypertension, and metabolic disturbances determining a metabolic syndrome (12). It should be remembered that the metabolic syndrome presents many signs and symptoms common to Cushing's syndrome. It is therefore reasonable to consider that the premenopausal condition could itself be associated with weight gain and other disorders, and it could be a confounding factor in the evaluation of our 46-yr-old patient.

On the other hand, it should also be considered that several patients with Cushing's syndrome are misdiagnosed for a long time and are treated in cardiological, diabetological, rheumatological, psychiatric, or other clinics before the correct diagnosis is achieved.

In approaching this patient, evaluation should begin with a careful case history and a thorough physical examination. She has no history of alcohol or exogenous glucocorticoid drugs (oral, parenteral, inhaled, or topical). Easy bruising, facial plethora, and proximal myopathy are the most sensitive clinical features of Cushing's syndrome. For the above reasons and due to the presence of multiple and progressive features of hypercortisolism, this patient should be screened for Cushing's syndrome. According to the Endocrine Society Guidelines, patients with unusual features for age (*e.g.* hypertension or osteoporosis), patients with adrenal incidentaloma and children with decreasing height and increasing weight are other potential patients who should be screened for the disease (10). In our opinion, patients with pituitary incidentaloma, or with metabolic syndrome particularly if they are young, obese women with polycystic ovary syndrome, and males with hypogonadotropic hypogonadism should be added to this list. If recent data on the increasing prevalence of Cushing's syndrome will be confirmed in larger population-based studies, a widespread screening for hypercortisolism would be recommended also in patients with single common disorders potentially cortisol related, such as hypertension, diabetes, and osteoporosis even in the absence of evident clinical features (3–6).

For the initial laboratory testing, Endocrine Society Guidelines recommends one of the following tests: at least two measurements of 24-h urinary free cortisol (UFC) or late-night salivary cortisol, 1-mg overnight dexamethasone suppression test (DST), or longer low-dose DST (10).

The purpose of these tests is to demonstrate the excess of cortisol secretion and the impairment of physiological feedback of the hypothalamus-pituitary-adrenal axis.

Because morning serum cortisol is not elevated in many patients with Cushing's syndrome, it is not surprising that this value in our patient is normal, and it is not recommended in the evaluation of suspected patients.

Although the pretest probability of disease is high in our patient, is the slight elevation of UFC sufficient to diagnose hypercortisolism? The 24-h UFC value, giving an integrated index of free (unbound) cortisol that circulates in the blood, can be extremely variable, and only a UFC value 4-fold greater than normal can be diagnostic for Cushing's syndrome.

Owing to the possibility of inaccurate urine collection, patients should provide a complete 24-h urine collection with an appropriate measurement of total volume and urinary creatinine levels. Patients should be instructed not to drink an excessive amount of water. In fact, some studies, in contrast to another, showed that high fluid intake seems to increase UFC (13–15). Finally, renal function should be verified before testing to avoid false-negative results. False-positive values of UFC can be seen in several conditions, such as severe obesity, depression, anxiety, and alcoholism, all of which are also known as pseudo-Cushing condition. Although in this state the UFC values are less elevated than in Cushing's syndrome, many patients show an overlap of clinical and biochemical features (10, 16–23).

Unfortunately, many of the commercially available antibody-based immunoassays for UFC measurement can give falsely high cortisol values due to cross-reactivity with cortisol metabolites (24). The increasing use in clinical practice of HPLC and of tandem mass spectrometry, allowing the separation of different cortisol metabolites, may overcome these problems despite the fact that some drugs (carbamazepine and fenofibrate) can cause false-positive values (25–28).

In our case, suspected hypercortisolism was confirmed by a second collection of 24-h UFC (310 $\mu\text{g}/24\text{ h}$, normal range 10–150 $\mu\text{g}/24\text{ h}$) and failure to suppress the level of cortisol after 1 mg DST (11.9 $\mu\text{g}/\text{dl}$) plus an elevated midnight salivary cortisol (460 and 580 ng/dl, normal range <150 ng/dl).

The overnight 1-mg DST test can be carried out in inpatients or outpatients and is considered easy to perform and low cost. To enhance its sensitivity, the original post-dexamethasone serum cortisol cutoff of 5 $\mu\text{g}/\text{dl}$ (138 nmol/liter) was reduced to 50 nmol/liter, and recently, this value was confirmed (9, 10). At this cutoff level, the sensitivity is high, especially in patients with mild hypercortisolism, but the specificity can be reduced.

False-positive results with an apparent lack of cortisol suppression might be determined by different interfering conditions: reduced dexamethasone absorption, substances, and drugs enhancing CYP3A4 hepatic dexamethasone metabolism (alcohol, barbiturates, phenytoin, carbamazepine, rifampicin *etc.*), liver and renal failure, and pseudo-Cushing state. Finally, estrogen treatment increasing cortisol binding globulin might give false-positive results, and also there are cases where healthy individuals fail to suppress cortisol (10, 29, 30). Conversely, there is no cutoff that identifies all patients with Cushing's syndrome considering that 8% of cases showed a suppression less than 2 $\mu\text{g}/\text{dl}$ despite the presence of disease (31). To evaluate false-positive and -negative results, experts have suggested simultaneous measurements of both cortisol and dexamethasone, but the cost of a routine dexamethasone assay could become high.

Several studies have validated late-night salivary cortisol determination as a useful screening test for hypercortisolism (10, 23, 32–34). Cortisol in saliva is in equilibrium with free plasma cortisol, is independent of salivary flow rate, and stable at room or refrigerator temperatures. For these reasons, the measurement of cortisol in saliva has some advantages: it is easy to perform at home, and it is a noninvasive test. However, there are several conditions that can cause false-positive results such as poor diabetic control, obesity, depression, stress, shift work, and behavior (variable bedtime, licorice, cigarettes, and chewing tobacco). Following the recent recommendation of The Endocrine Society, two measurements of nighttime salivary cortisol are recommended to screen patients with suspected hypercortisolism despite some limitations. In fact, using various assays to measure cortisol in the saliva, a strict standardization of both collection and analysis methods is necessary, and normal reference ranges and diagnostic cutoff should be validated in each laboratory before being applied to a large population (35, 36).

Finally, salivary cortisol is particularly useful in investigating patients with cyclical Cushing's syndrome where multiple determinations are needed and in pediatric patients.

Our patient showed a high pretest probability of Cushing's syndrome, and the hormonal evaluation showed concordant positive results confirming the diagnosis. However, not all cases are like our patient, and there are some with equivocal clinical and hormonal results. In these cases, following the recommendation of The Endocrine Society, we suggest further evaluation and follow-up (time as additional diagnostic tool).

Several tests have been extensively used, but none have proven fully capable of identifying all cases of Cushing's syndrome. In particular, distinguishing Cushing's syn-

drome from a pseudo-Cushing state is a major clinical challenge for the endocrinologist (10, 16). Frequently overlapping clinical and biochemical findings from the screening evaluation require additional tests, all of which, however, suffer from a variety of limitations: the dexamethasone-suppressed CRH stimulation test has shown a variable performance in different studies (17–21); the desmopressin test is not fully validated for clinical use, and its evaluation requires a larger experience (10, 18); and sleeping and awake midnight serum cortisol, despite its ability to distinguish subjects with hypercortisolism from those with pseudo-Cushing (9, 10), is uncomfortable and requires overnight hospitalization as well as 48 h hospitalization before sleeping midnight serum cortisol sampling to avoid false positives. Finally, even late-night salivary cortisol has limitations, related to the assay methodology and to the risk of false positives (10).

Clinical Consideration: Identifying the Cause of Cushing's Syndrome

We now know that our patient really has Cushing's syndrome, and the next step is to determine whether she has an ACTH-dependent or ACTH-independent disease. This distinction is made by measuring plasma ACTH levels, and the development of two-site immunometric assays has improved the specificity and the ability to measure low-normal ACTH concentrations (37, 38). In adrenal-dependent forms, circulating plasma ACTH is suppressed (<10 pg/ml), whereas it is normal or increased in ACTH-dependent forms. It should be noted that there is significant overlap in circulating ACTH levels in patients with either a pituitary or an ectopic tumor despite the fact that ACTH levels are generally higher in the latter. Moreover, some patients with pituitary disease can show ACTH levels in the low-normal range, and conversely, some patients with adrenal forms can present ACTH levels that are not fully suppressed. To improve the sensitivity of this test, we suggest measuring plasma ACTH levels at least two times before further evaluation. Because some patients with adrenal Cushing may show unsuppressed ACTH, for ACTH levels between 10 and 20 pg/ml, a CRH stimulation test is suggested; a blunted ACTH response is observed in adrenal Cushing, whereas a brisk rise in ACTH is observed in pituitary forms (2, 9, 11). Because ACTH is rapidly degraded by plasma protease, blood should be collected in pre-chilled EDTA tubes, and plasma should be rapidly centrifuged and stored to avoid falsely low values (37).

Once ACTH-independent Cushing's syndrome is confirmed, an adrenal computed tomography (CT) or magnetic resonance imaging (MRI) should be performed to identify the type of adrenal lesion (mono- or bilateral).

However, because of the high prevalence of adrenal incidentaloma in the general population (up to 5%), an abnormal CT/MRI is not conclusive for a diagnosis of primary adrenal disease (39). In unilateral tumors, the remainder of the adrenal gland and the contralateral adrenal are either normal or atrophic due to low circulating ACTH levels. The adenoma is usually small (but variable in size) with smooth borders, homogeneous, lower than water density on CT (<10 HU without contrast), and isointense to liver on T₂-weighted MRI with high lipid content on chemical shift MRI image. On the contrary, adrenal carcinoma is often larger than 6 cm in diameter, irregular with unclear margins, with a density of more than 10 Hounsfield units, inhomogeneous due to necrosis and hemorrhage, with intermediate increased intensity on T₂-weighted MRI.

Bilateral adrenal hyperplasia causing hypercortisolism represents approximately 10–15% of all adrenal causes of Cushing's syndrome, with heterogeneous conditions and includes primary pigmented nodular adrenocortical disease (PPNAD) and ACTH-independent macronodular adrenal hyperplasia (AIMAH).

PPNAD is a rare disease characterized by small to normal-sized adrenal glands containing multiple small cortical pigmented nodules. PPNAD may be sporadic or associated with Carney complex, an autosomal dominant, multiple neoplasia syndrome that consists of spotty skin pigmentation, myxomas, and other nonendocrine and endocrine tumors. Usually, the adrenal size is normal at CT/MRI, and the nodules do not normally exceed 5 mm, but in older patients, they may be 1–2 cm in diameter. Patients with PPNAD are usually children and young adults and respond to dexamethasone with a paradoxical increase in glucocorticoid secretion during a 6-d Liddle test (40).

AIMAH is a complex and heterogeneous condition where the adrenal glands in most cases can be enlarged bilaterally with the presence of multiple nodules up to 5 cm in diameter. In other cases, the glands are diffusely enlarged without macroscopic nodules or, occasionally, an asymmetric enlargement of adrenal macronodular is present mimicking a unilateral lesion. Patients with AIMAH are usually diagnosed in the 60th decade of life or later. Hypercortisolism in these patients may be mediated by aberrantly expressed G protein-coupled receptors in adrenal cortex. These include ectopic membrane receptors for gastric inhibitory polypeptide, catecholamines, or LH/human chorionic gonadotropin and also eutopic membrane receptors showing altered expression and activity, such as vasopressin and serotonin (41). Subclinical hypercortisolism has also been reported to occur in these patients. Considering that up to 10% of adrenal incidenta-

loma are bilateral (39), it is probable that diagnosis of AIMAH will be increased.

Returning to our patient, plasma ACTH levels were high on two consecutive days (110 and 98 pg/ml, normal range 10–80 pg/ml) supporting the diagnosis of ACTH-dependent Cushing's syndrome. The subsequent evaluation to search for ACTH-secreting tumors showed that the patient did not respond to human CRH test (only a slight maximal increase of ACTH and cortisol was observed, 30 and 10%, respectively, over baseline) but an overnight high-dose dexamethasone suppression test (HDDST) showed an 82% of suppression of serum cortisol (from 25.6 to 4.6 μg/dl). Moreover, pituitary MRI with and without gadolinium showed no lesion. Because there are many potential diagnostic pitfalls and no test or imaging that *per se* is 100% diagnostic, there are several comments in evaluating these functional and imaging results. Patients with Cushing's disease are generally responsive to CRH stimulation and to high-dose glucocorticoid feedback (9, 11, 42, 43).

Although the CRH test is considered the most reliable dynamic noninvasive test for the differential diagnosis of ACTH-dependent Cushing's syndrome, this test cannot make a 100% differentiation between pituitary and ectopic causes. From literature data, the sensitivity and specificity using ACTH criteria is approximately 90% (9, 11, 42). Unfortunately, there is yet no consensus on the criteria for interpreting the test as positive. Variability in interpretation depends on the type of CRH used (usually ovine in the United States and human in Europe), the weight-based (1 μg/kg) or the 100-μg fixed dose, and the wide range of response parameters (increase above baseline in peak ACTH, 30–50%, *vs.* peak cortisol, 14–20%) (9, 11, 42).

Although the HDDST showed a relatively high sensitivity in identifying patients with Cushing's disease, its specificity is low and in clinical practice has little diagnostic utility whatever the protocol and the cutoff of cortisol suppression used. In accord with other authors, we do not recommend the routine use of HDDST alone in the differential diagnosis of Cushing's syndrome (42, 44, 45).

A pituitary MRI with gadolinium should be performed in all patients with ACTH-dependent Cushing's syndrome, but this technique fails to identify the tumor in up to 50% of patients. Given the high prevalence of pituitary adenoma in the general population (up to 10%), an abnormal pituitary MRI alone cannot be used to establish the diagnosis (42). Following the opinion of a consensus statement, the presence of a pituitary lesion greater than 6 mm in a patient with a classical presentation and concordant dynamic results may provide a definite diagnosis of Cushing's disease without need for further invasive evaluation (9).

TABLE 3. Causes of ectopic ACTH secretion from literature data (Refs. 54–58)

Localization	Frequency, % (No.)			
	Aniszewski et al., 2001 (54)	Ilias et al., 2005 (55)	Isidori et al., 2005 (56)	Salgado et al., 2006 (57)
Bronchial carcinoid	25% (26/106)	40% (35/90)	34% (12/35)	40% (10/25)
Pancreatic carcinoid	16% (17/106)	1% (1/90)	8% (3/35)	12% (3/25)
Small-cell lung cancer ^a	11% (12/106)	3% (3/90)	6% (2/35)	ND
Thymic carcinoid	5% (5/106)	5% (5/90)	6% (2/35)	16% (4/25)
Unknown/occult	7% (7/106)	19% (17/90)	14% (5/35)	8% (2/25)
Other	36% (39/106)	32% (27/90)	32% (11/35)	24% (6/25)

ND, Not done.

^a Generally, this aggressive cancer is evident and is often recognized in patients with overt hypercortisolism. These patients are probably not referred to an endocrine expert center.

On the contrary, bilateral inferior petrosal sinus sampling (BIPSS), considered the gold standard for establishing the origin of ACTH secretion, is recommended in patients with ACTH-dependent Cushing's syndrome whose clinical, biochemical, or radiological studies are discordant or equivocal (9, 11, 42). Moreover, in our opinion, BIPSS should also be performed in all patients with negative MRI. A ratio of central to peripheral ACTH of more than 2 in the basal state or more than 3 after CRH stimulation is consistent with Cushing's disease. However, this invasive and costly technique has technical difficulties and related risks, and it should be performed only in an experienced center. Technical problems and anomalous venous drainage may result in false-negative results (46). Recently, the measurement of ACTH normalized for prolactin has been proposed to verify the correct sampling during BIPSS and to avoid false-negative results (47). Moreover, BIPSS should be performed in the presence of consistent hypercortisolism to avoid false-positive results due to inadequate suppression of normal adrenocorticotroph cells (*i.e.* previous pituitary- or adrenal-directed medical treatment, pseudo-Cushing state, or cyclical hypercortisolism). Caveats for false-positive results include the inactive phase of cyclic ectopic ACTH secretion and rare cases of CRH-secreting tumors (48–50).

Finally, the use of BIPSS appears of limited usefulness in identifying the localization of adenoma within the pituitary (17, 42, 51).

Given these potential diagnostic pitfalls, we and other physicians suggest the importance of using multiple hormonal test and imaging data and combining all the results together for the differential diagnosis of a patient with Cushing's syndrome (42, 43). With this in mind, in particular cases, the desmopressin test might be useful although when used alone had shown a limited usefulness in distinguishing the source of ACTH hypersecretion (52, 53).

When BIPSS does not show a central gradient and the diagnosis of Cushing's disease has been excluded, a CT

and/or MRI scan of the neck/chest and, if negative, of the abdomen and pelvis should be performed to identify the ectopic source of ACTH secretion that is associated with a variety of endocrine and nonendocrine tumors (54–57) (Table 3). Although the most likely site of the nonpituitary ACTH-secreting tumors is the thorax, the localization of these tumors is often challenging and extremely difficult; imaging correctly identifies the tumor at first investigation in only 65% of cases (55). It is of note that there is not a single imaging technique with an optimal accuracy, and in up to 30% of cases, the tumor remains occult for a long time after diagnosis of Cushing's syndrome. The combinations of CT/MRI, with complementary imaging tools, including [¹¹¹In]pentreotide scintigraphy, positron emission tomography (PET), and PET/CT should be employed and eventually repeated during the follow-up, because a single negative finding does not exclude the diagnosis (55, 56, 58–61).

A Clinical Consideration: Is It Necessary to Evaluate Comorbidities and Complications before Treatment?

The high morbidity and mortality rate observed in Cushing's syndrome seems to be mainly caused by cardiovascular complications and comorbidities such as central obesity, hypertension, diabetes, dyslipidemia, and a hypercoagulate state (62). Clinical management should be particularly careful in identifying global cardiovascular risk and aim at controlling all comorbidities. Extending the indications of the Consensus Statement (9), we suggest carrying out an echocardiography and Doppler ultrasonography of the epiaortic vessels in all patients at diagnosis. Global cardiovascular risk could be better quantified performing an oral glucose tolerance test to avoid underestimation of diabetes mellitus. Treatment of hypertension and diabetes makes use of conventional drugs, but the best results can be obtained by controlling hypercortisolism. Lastly, patients with active disease should un-

dergo preventive antithrombotic treatment (best with heparin) especially during diagnostic BIPPS and surgery. This should also be considered as an antiplatelets therapy in all patients.

Considering that a cure is often difficult to achieve and that cardiovascular risk seems to persist even during disease remission, care and control of all cardiovascular risk factors should be one of the primary goals during the diagnosis and follow-up of these patients.

Because osteoporosis and fractures are common complications of Cushing's syndrome, bone mineral density (BMD) and radiological evaluation and bone metabolism assessment should also be included in the diagnostic approach (9, 63). It should be remembered that although BMD is a predictive factor for fractures, patients with hypercortisolism are at risk for fractures even at normal densitometric values. We also suggest the use of specific treatments (anabolic or antiresorptive therapy) that may induce a more rapid improvement in BMD.

Controversies and Unanswered Questions

The diagnosis and differential diagnosis of Cushing's syndrome is often difficult, complex, and expensive. Most clinical features overlap with those of common diseases found in the general population, and some patients have an atypical clinical presentation with only isolated symptoms. Recently, several studies have suggested that the prevalence of Cushing's syndrome is higher than previously thought. Therefore, efficient screening tests are needed to identify the few uncovered patients also among unselected high-risk ambulatory patients with disorders potentially related to cortisol excess. If we do not look out for the presence of Cushing's syndrome, we will never find it, but most patients initially suspected for hypercortisolism will not have the disease. This situation imposes the most sensitive testing and a strict standardization of assay methods. Moreover, it should be necessary to identify normal reference ranges and cutoff levels to better establish the threshold of abnormal hormone secretion and related clinical consequences. A recent metaanalysis showed that commonly used tests, when combined, are highly accurate in diagnosing Cushing's syndrome. However, no test alone has a 100% diagnostic accuracy. UFC and overnight DST have been shown to be the most effective in the diagnosis of Cushing's syndrome (23).

Moreover, we must not forget that the cutoff values that we identify are always arbitrary and depend on the assay method used. Cutoffs pose a particularly important problem that adds to the already difficult distinction between Cushing and pseudo-Cushing or in certain conditions such as those of patients with adrenal incidentaloma.

In many cases, in fact, the results present a gray area that often leads to misinterpretation of the data. In this last situation, we should ask ourselves whether it isn't the case to talk of mild Cushing rather than subclinical Cushing. Thus, it is difficult to clearly distinguish subjects with normal cortisol secretion and mild hypercortisolism; above all, in the presence of organ complications that are potentially cortisol correlated. In these cases, we should consider perhaps modifying the threshold levels of cortisol during the tests as occurs, for example, for different targets of cholesterol levels in patients with previous cardiovascular accidents.

In all these conditions, we have assumed that abnormal cortisol secretion could be the cause of organ complication; conversely, if hypercortisolism is not the cause but is a consequence of other conditions (*i.e.* pseudo-Cushing states), can we then consider that this is an adaptive physiological state safe and free of organ damage risk (64, 65)?

There are many diagnostic pitfalls in distinguishing between Cushing's disease, the most common cause, and ectopic ACTH secretion responsible for 5–10% of cases. Although the pretest probability of pituitary ACTH-secreting tumor is high, there are no clear clinical features to differentiate the two forms. Generally, in ectopic ACTH secretion, there is a male prevalence and hypercortisolism is severe, resulting in a syndrome of apparent mineralocorticoid excess (hypertension, hypokalemia, edema, and metabolic alkalosis) due to an inhibition of 11 β -hydroxysteroid dehydrogenase type 2 activity.

Given the high prevalence of adrenal and pituitary incidentaloma, the imaging procedures should not be performed unless the diagnosis of hypercortisolism is unequivocal and the differentiation between ACTH-dependent and ACTH-independent causes has been established. The finding of direct or indirect signs of pituitary lesion on MRI scan could be a confounding factor in a patient with ectopic ACTH-secreting tumor. For this reason, abnormal pituitary imaging without BIPSS might give false-positive results, and the patient could undergo incorrect transsphenoidal pituitary surgery. The hormonal rather than radiological evaluation should be the diagnostic key for correct diagnosis considering that pituitary MRI is normal in half of the patients. In addition, caveats should be required also in the interpretation of adrenal imaging, considering that adrenal bilateral enlargement (diffuse or nodular) is often present in ACTH-dependent Cushing's syndrome, especially in ectopic ACTH secretion.

It should be noted that the presence of an ACTH-secreting pituitary macroadenoma could lead to a paradoxical diagnostic gap. In fact, in these patients, re-

sponses to both CRH stimulus and HDSST test are more frequently negative (66), whereas the desmopressin test, at least in our experience, is often positive.

Conversely, an accurate evaluation of dynamic endocrine data may help to reduce the amount of BIPSS performed in patients with Cushing’s disease even with no evidence of pituitary adenoma at MRI. However, in our experience, we prefer to perform BIPSS in all patients with negative pituitary MRI, when an experienced team is present.

Returning to the Patient

A woman with mild to moderate hypercortisolism, slightly elevated plasma ACTH, and normokalemia has at least a 95% likelihood of having Cushing’s disease (47). Given a discordant dynamic test (lack of response to CRH test despite cortisol suppression after HDSST), BIPSS was performed, excluding a pituitary source of ACTH hypersecretion. Chest CT scan was normal, whereas abdominal CT scan showed only a diffuse bilateral adrenal hyperplasia, highly suggesting an occult ectopic ACTH-secreting tumor. Unfortunately, a whole-body scintigraphy with [¹¹¹In]pentreotide was also negative. Thyroid sonography and calcitonin levels were normal. Meanwhile, to

control hypercortisolism, a treatment with ketoconazole and octreotide was started, reaching a good control of the clinical picture. In this patient, initially classified as having occult ACTH-secreting tumors, a subsequent thoracic CT scan showed a 0.6-cm bronchial carcinoid after repeated imaging work-ups over 24 months. Surgery was curative.

In conclusion, although the pretest probability of Cushing’s disease was high, the cause of Cushing’s syndrome in our patient was an ACTH-secreting bronchial carcinoid, confirming that differential diagnosis is difficult and challenging.

Conclusion

Clinical decision making for patients with suspect hypercortisolism involves a complex diagnostic assessment. Cushing’s syndrome remains one of the most challenging endocrine pathologies. A simplified flow chart is provided in Fig. 1. The present clinical case shows that even if rare, the ectopic ACTH secretion should be considered also in those cases where the pretest probability is low. Although in many patients the localization of ACTH-secreting non-pituitary tumor is lacking, an imaging reevaluation during a follow-up may give a correct diagnosis.

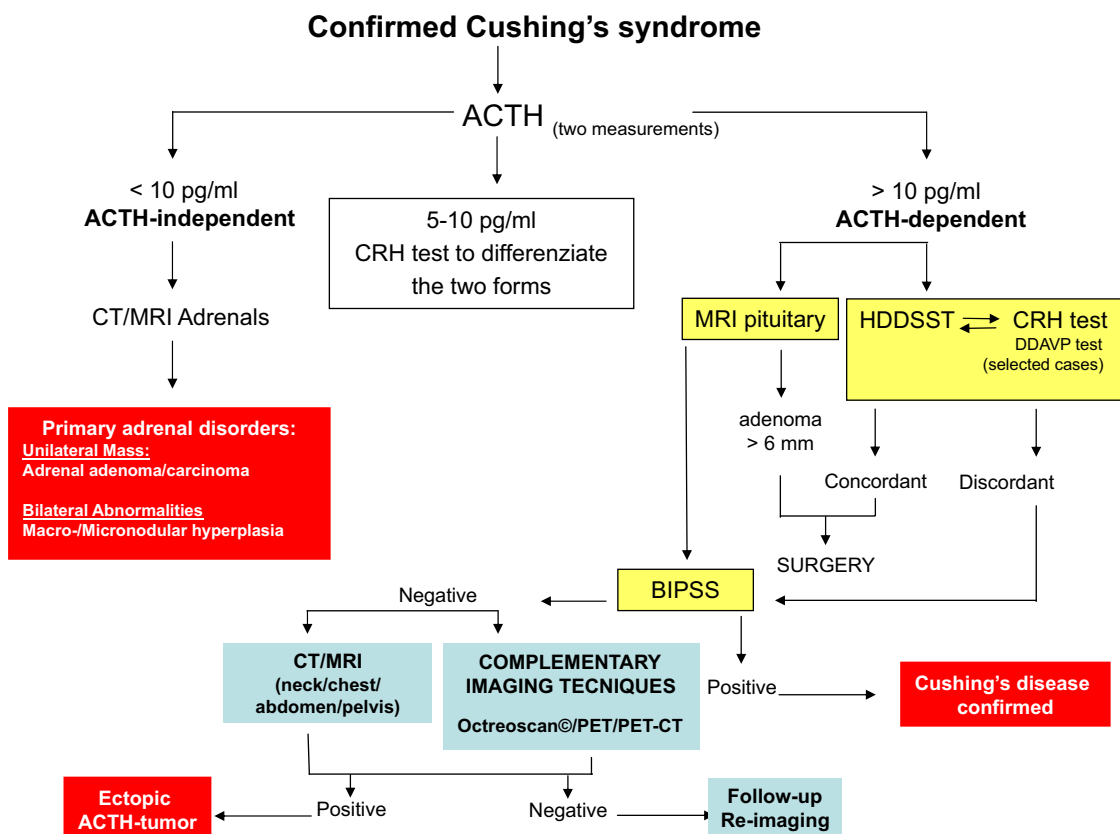


FIG. 1. Clinical decision-making flow chart.

The management of Cushing's syndrome depends on the exact knowledge of its various causes, paying attention to the many potential diagnostic pitfalls. The choice of test, the modality of specimen collection (blood, urine, and saliva), the quality of measurement (assay methodology and standardization) and close dialogue among endocrinologists, chemical pathologists, and neuroendocrinologists are key factors for optimal care of patients.

If the recent data of the increasing prevalence of Cushing's syndrome is confirmed in larger population-based studies, a widespread screening for hypercortisolism would be recommended also in unselected high-risk ambulatory patients with disorders potentially related to cortisol excess.

Acknowledgments

Address all correspondence and requests for reprints to: Marco Boscaro, M.D., Division of Endocrinology, Polytechnic University of Marche, 60126 Ancona, Italy. E-mail: m.boscaro@univpm.it.

Disclosure Summary: The authors have nothing to disclose.

References

- Lindholm J, Juul S, Jørgensen JO, Astrup J, Bjerre P, Feldt-Rasmussen U, Hagen C, Jørgensen J, Kosteljanetz M, Kristensen L, Laurberg P, Schmidt K, Weeke J 2001 Incidence and late prognosis of Cushing's syndrome: a population-based study. *J Clin Endocrinol Metab* 86:117–123
- Pecori Giralardi F, Moro M, Cavagnini F; Study Group on the Hypothalamo-Pituitary-Adrenal Axis of the Italian Society of Endocrinology 2003 Gender-related differences in the presentation and course of Cushing's disease. *J Clin Endocrinol Metab* 88:1554–1558
- Catargi B, Rigalleau V, Poussin A, Ronci-Chaix N, Bex V, Vergnot V, Gin H, Roger P, Tabarin A 2003 Occult Cushing's syndrome in type-2 diabetes. *J Clin Endocrinol Metab* 88:5808–5813
- Chiodini I, Torlontano M, Scillitani A, Arosio M, Bacci S, Di Lembo S, Epaminonda P, Augello G, Enrini R, Ambrosi B, Adda G, Trischitta V 2005 Association of subclinical hypercortisolism with type 2 diabetes mellitus: a case-control study in hospitalized patients. *Eur J Endocrinol* 153:837–844
- Chiodini I, Mascia ML, Muscarella S, Battista C, Minisola S, Arosio M, Santini SA, Guglielmi G, Carnevale V, Scillitani A 2007 Subclinical hypercortisolism among outpatients referred for osteoporosis. *Ann Intern Med* 147:541–548
- Reimondo G, Pia A, Allasino B, Tassone F, Bovio S, Borretta G, Angeli A, Terzolo M 2007 Screening of Cushing's syndrome in adult patients with newly diagnosed diabetes mellitus. *Clin Endocrinol (Oxf)* 67:225–229
- van Rossum EF, Lamberts SW 2004 Polymorphisms in the glucocorticoid receptor gene and their associations with metabolic parameters and body composition. *Recent Prog Horm Res* 59:333–357
- Boscaro M, Barzon L, Sonino N 2000 The diagnosis of Cushing's syndrome: atypical presentations and laboratory shortcomings. *Arch Intern Med* 160:3045–3053
- Arnaldi G, Angeli A, Atkinson AB, Bertagna X, Cavagnini F, Chrousos GP, Fava GA, Findling JW, Gaillard RC, Grossman AB, Kola B, Lacroix A, Mancini T, Mantero F, Newell-Price J, Nieman LK, Sonino N, Vance ML, Giustina A, Boscaro M 2003 Diagnosis and complications of Cushing's syndrome: a consensus statement. *J Clin Endocrinol Metab* 88:5593–5602
- Nieman LK, Biller BM, Findling JW, Newell-Price J, Savage MO, Stewart PM, Montori VM 2008 The diagnosis of Cushing's syndrome: an Endocrine Society Clinical Practice Guideline. *J Clin Endocrinol Metab* 93:1526–1540
- Newell-Price J, Bertagna X, Grossman AB, Nieman LK 2006 Cushing's syndrome. *Lancet* 367:1605–1617
- Martin KA, Manson JE 2008 Approach to the patient with menopausal symptoms. *J Clin Endocrinol Metab* 93:4567–4575
- Mericq MV, Cutler Jr GB 1998 High fluid intake increases urine free cortisol excretion in normal subjects. *J Clin Endocrinol Metab* 83:682–684
- Fenske M 2004 How much "urinary free cortisol" is really cortisol during water diuresis in healthy individuals? *Clin Chem* 50:1102–1104
- Putignano P, A Dubini, F Cavagnini 2000 Urinary free cortisol is unrelated to physiological changes in urine volume in healthy women. *Clin Chem* 46:879
- Newell-Price J, Trainer P, Besser M, Grossman A 1998 The diagnosis and differential diagnosis of Cushing's syndrome and pseudo-Cushing's states. *Endocr Rev* 19:647–672
- Yanovski JA, Cutler Jr GB, Chrousos GP, Nieman LK 1993 Corticotropin-releasing hormone stimulation following low-dose dexamethasone administration. A new test to distinguish Cushing's syndrome from pseudo-Cushing's states. *JAMA* 269:2232–2238
- Pecori Giralardi F, Pivonello R, Ambrogio AG, De Martino MC, De Martin M, Scacchi M, Colao A, Toja PM, Lombardi G, Cavagnini F 2007 The dexamethasone-suppressed corticotropin-releasing hormone stimulation test and the desmopressin test to distinguish Cushing's syndrome from pseudo-Cushing's states. *Clin Endocrinol (Oxf)* 66:251–257
- Gatta B, Chabre O, Cortet C, Martinie M, Corcuff JB, Roger P, Tabarin A 2007 Reevaluation of the combined dexamethasone suppression-corticotropin-releasing hormone test for differentiation of mild Cushing's disease from pseudo-Cushing's syndrome. *J Clin Endocrinol Metab* 92:4290–4293
- Erickson D, Natt N, Nippoldt T, Young Jr WF, Carpenter PC, Petterson T, Christianson T 2007 Dexamethasone-suppressed corticotropin-releasing hormone stimulation test for diagnosis of mild hypercortisolism. *J Clin Endocrinol Metab* 92:2972–2976
- Nieman L 2007 The dexamethasone-suppressed corticotropin-releasing hormone test for the diagnosis of Cushing's syndrome: what have we learned in 14 years? *J Clin Endocrinol Metab* 92:2876–2878
- Arnaldi G, Tirabassi G, Papa R, Furlani G, Trementino L, Cardinaletti M, Faloia E, Boscaro M 2009 Human corticotropin releasing hormone test performance in the differential diagnosis between Cushing's disease and pseudo-Cushing state is enhanced by combined ACTH and cortisol analysis. *Eur J Endocrinol* 160:891–898
- Elamin MB, Murad MH, Mullan R, Erickson D, Harris K, Nadeem S, Ennis R, Erwin PJ, Montori VM 2008 Accuracy of diagnostic tests for Cushing's syndrome: a systematic review and metaanalysis. *J Clin Endocrinol Metab* 93:1553–1562
- Murphy BE 2000 How much "UFC" is really cortisol? *Clin Chem* 46(6 Pt 1):793–794
- Turpeinen U, Markkanen H, Välimäki M, Stenman UH 1997 Determination of urinary free cortisol by HPLC. *Clin Chem* 43(8 Pt 1):1386–1391
- Lin CL, Wu TJ, Machacek DA, Jiang NS, Kao PC 1997 Urinary free cortisol and cortisone determined by high performance liquid chromatography in the diagnosis of Cushing's syndrome. *J Clin Endocrinol Metab* 82:151–155
- Meikle AW, Findling J, Kushnir MM, Rockwood AL, Nelson GJ, Terry AH 2003 Pseudo-Cushing syndrome caused by fenofibrate

- interference with urinary cortisol assayed by high-performance liquid chromatography. *J Clin Endocrinol Metab* 88:3521–3524
28. Wood L, Ducroq DH, Fraser HL, Gillingwater S, Evans C, Pickett AJ, Rees DW, John R, Turkes A 2008 Measurement of urinary free cortisol by tandem mass spectrometry and comparison with results obtained by gas chromatography-mass spectrometry and two commercial immunoassays. *Ann Clin Biochem* 45(Pt 4):380–388
 29. Huizenga NA, Koper JW, de Lange P, Pols HA, Stolk RP, Grobbee DE, de Jong FH, Lamberts SW 1998 Interperson variability but intraperson stability of baseline plasma cortisol concentrations, and its relation to feedback sensitivity of the hypothalamo-pituitary-adrenal axis to a low dose of dexamethasone in elderly individuals. *J Clin Endocrinol Metab* 83:47–54
 30. Klose M, Lange M, Rasmussen AK, Skakkebaek NE, Hilsted L, Haug E, Andersen M, Feldt-Rasmussen U 2007 Factors influencing the adrenocorticotropin test: role of contemporary cortisol assays, body composition, and oral contraceptive agents. *J Clin Endocrinol Metab* 92:1326–1333
 31. Findling JW, Raff H, Aron DC 2004 The low-dose dexamethasone suppression test: a reevaluation in patients with Cushing's syndrome. *J Clin Endocrinol Metab* 89:1222–1226
 32. Nunes ML, Vattaut S, Corcuff JB, Rault A, Loiseau H, Gatta B, Valli N, Letenneur L, Tabarin A 2009 Late-night salivary cortisol for diagnosis of overt and subclinical Cushing's syndrome in hospitalized and ambulatory patients. *J Clin Endocrinol Metab* 94:456–462
 33. Restituto P, Galofré JC, Gil MJ, Mugueta C, Santos S, Monreal JI, Varo N 2008 Advantage of salivary cortisol measurements in the diagnosis of glucocorticoid related disorders. *Clin Biochem* 41:688–692
 34. Kidambi S, Raff H, Findling JW 2007 Limitations of nocturnal salivary cortisol and urine free cortisol in the diagnosis of mild Cushing's syndrome. *Eur J Endocrinol* 157:725–731
 35. Baid SK, Sinaii N, Wade M, Rubino D, Nieman LK 2007 Radioimmunoassay and tandem mass spectrometry measurement of bedtime salivary cortisol levels: a comparison of assays to establish hypercortisolism. *J Clin Endocrinol Metab* 92:3102–3107
 36. Gröschl M 2008 Current status of salivary hormone analysis. *Clin Chem* 54:1759–1769
 37. Talbot JA, Kane JW, White A 2003 Analytical and clinical aspects of adrenocorticotrophin determination. *Ann Clin Biochem* 40(Pt 5):453–471
 38. Lindsay JR, Shanmugam VK, Oldfield EH, Remaley AT, Nieman LK 2006 A comparison of immunometric and radioimmunoassay measurement of ACTH for the differential diagnosis of Cushing's syndrome. *J Endocrinol Invest* 29:983–988
 39. Mantero F, Terzolo M, Arnaldi G, Osella G, Masini AM, Ali A, Giovagnetti M, Opocher G, Angeli A; Study Group on Adrenal Tumors of the Italian Society of Endocrinology 2000 A survey on adrenal incidentaloma in Italy. *J Clin Endocrinol Metab* 85:637–644
 40. Stratakis CA, Sarlis N, Kirschner LS, Carney JA, Doppman JL, Nieman LK, Chrousos GP, Papanicolaou DA 1999 Paradoxical response to dexamethasone in the diagnosis of primary pigmented nodular adrenocortical disease. *Ann Intern Med* 131:585–591
 41. Lacroix A, Bourdeau I 2005 Bilateral adrenal Cushing's syndrome: macronodular adrenal hyperplasia and primary pigmented nodular adrenocortical disease. *Endocrinol Metab Clin North Am* 34:441–458, x
 42. Lindsay JR, Nieman LK 2005 Differential diagnosis and imaging in Cushing's syndrome. *Endocrinol Metab Clin North Am* 34:403–421, x
 43. Testa RM, Albiger N, Occhi G, Sanguin F, Scanarini M, Berlucchi S, Gardiman MP, Carollo C, Mantero F, Scaroni C 2007 The usefulness of combined biochemical tests in the diagnosis of Cushing's disease with negative pituitary magnetic resonance imaging. *Eur J Endocrinol* 156:241–248
 44. Aron DC, Raff H, Findling JW 1997 Effectiveness *versus* efficacy: the limited value in clinical practice of high dose dexamethasone suppression testing in the differential diagnosis of adrenocorticotropin-dependent Cushing's syndrome. *J Clin Endocrinol Metab* 82:1780–1785
 45. Findling JW, Raff H 2006 Cushing's syndrome: important issues in diagnosis and management. *J Clin Endocrinol Metab* 91:3746–3753
 46. Swearingen B, Katznelson L, Miller K, Grinspoon S, Waltman A, Dorer DJ, Klibanski A, Biller BM 2004 Diagnostic errors after inferior petrosal sinus sampling. *J Clin Endocrinol Metab* 89:3752–3763
 47. Findling JW, Kehoe ME, Raff H 2004 Identification of patients with Cushing's disease with negative pituitary adrenocorticotropin gradients during inferior petrosal sinus sampling: prolactin as an index of pituitary venous effluent. *J Clin Endocrinol Metab* 89:6005–6009
 48. Barman P, Lethagen A, Ivancev K, Johansson L, Sundin A 2008 Dual bronchial carcinoids and Cushing's syndrome with a paradoxical response to dexamethasone and a false positive outcome of inferior petrosal sinus sampling. *Eur J Endocrinol* 159:483–488
 49. Young J, Deneux C, Grino M, Oliver C, Chanson P, Schaison G 1998 Pitfall of petrosal sinus sampling in a Cushing's syndrome secondary to ectopic adrenocorticotropin-corticotropin releasing hormone (ACTH-CRH) secretion. *J Clin Endocrinol Metab* 83:305–308
 50. Arnaldi G, Mancini T, Kola B, Appolloni G, Freddi S, Concettoni C, Bearzi I, Masini A, Boscaro M, Mantero F 2003 Cyclical Cushing's syndrome in a patient with a bronchial neuroendocrine tumor (typical carcinoid) expressing ghrelin and growth hormone secretagogue receptors. *J Clin Endocrinol Metab* 88:5834–5840
 51. Lefournier V, Martinie M, Vasdev A, Bessou P, Passagia JG, Labat-Moleur F, Sturm N, Bosson JL, Bachelot I, Chabre O 2003 Accuracy of bilateral inferior petrosal or cavernous sinuses sampling in predicting the lateralization of Cushing's disease pituitary microadenoma: influence of catheter position and anatomy of venous drainage. *J Clin Endocrinol Metab* 88:196–203
 52. Castinetti F, Morange I, Dufour H, Jaquet P, Conte-Devolx B, Girard N, Brue T 2007 Desmopressin test during petrosal sinus sampling: a valuable tool to discriminate pituitary or ectopic ACTH-dependent Cushing's syndrome. *Eur J Endocrinol* 157:271–277
 53. Tsagarakis S, Vassiliadi D, Kaskarelis IS, Komminos J, Souvatzoglou E, Thalassinou N 2007 The application of the combined corticotropin-releasing hormone plus desmopressin stimulation during petrosal sinus sampling is both sensitive and specific in differentiating patients with Cushing's disease from patients with the occult ectopic adrenocorticotropin syndrome. *J Clin Endocrinol Metab* 92:2080–2086
 54. Aniszewski JP, Young Jr WF, Thompson GB, Grant CS, van Heerden JA 2001 Cushing syndrome due to ectopic adrenocorticotropin hormone secretion. *World J Surg* 25:934–940
 55. Ilias I, Torpy DJ, Pacak K, Mullen N, Wesley RA, Nieman LK 2005 Cushing's syndrome due to ectopic corticotropin secretion: twenty years' experience at the National Institutes of Health. *J Clin Endocrinol Metab* 90:4955–4962
 56. Isidori AM, Kaltsas GA, Pozza C, Frajese V, Newell-Price J, Reznick RH, Jenkins PJ, Monson JP, Grossman AB, Besser GM 2006 The ectopic adrenocorticotropin syndrome: clinical features, diagnosis, management, and long-term follow-up. *J Clin Endocrinol Metab* 91:371–377
 57. Salgado LR, Fragoso MC, Knoepfelmacher M, Machado MC, Domenice S, Pereira MA, de Mendonça BB 2006 Ectopic ACTH syndrome: our experience with 25 cases. *Eur J Endocrinol* 155:725–733
 58. Tsagarakis S, Christoforaki M, Giannopoulou H, Rondogianni F, Housianakou I, Malagari C, Rontogianni D, Bellenis I, Thalassinou N 2003 A reappraisal of the utility of somatostatin receptor scintigraphy in patients with ectopic adrenocorticotropin Cushing's syndrome. *J Clin Endocrinol Metab* 88:4754–4758
 59. Sookur PA, Sahdev A, Rockall AG, Isidori AM, Monson JP, Grossman AB, Reznick RH 2009 Imaging in covert ectopic ACTH secretion: a CT pictorial review. *Eur Radiol* 19:1069–1078

60. Pacak K, Ilias I, Chen CC, Carrasquillo JA, Whatley M, Nieman LK 2004 The role of [¹⁸F]fluorodeoxyglucose positron emission tomography and [¹¹¹In]diethylenetriaminepentaacetate-D-Phe-pentetreotide scintigraphy in the localization of ectopic adrenocorticotropin-secreting tumors causing Cushing's syndrome. *J Clin Endocrinol Metab* 89:2214–2221
61. Waintrop C, Tenenbaum F, Coulot J, Vignaux O, Blanchet C, Legmann P, Richard B, Bertagna X 2006 Image in endocrinology: localization of an occult adrenocorticotropin-secreting carcinoid tumor with somatostatin receptor scintigraphy using single-photon emission computed tomography/computed tomographic image scanning. *J Clin Endocrinol Metab* 91:3271–3272
62. Pivonello R, Faggiano A, Lombardi G, Colao A 2005 The metabolic syndrome and cardiovascular risk in Cushing's syndrome. *Endocrinol Metab Clin North Am* 34:327–339, viii
63. Mancini T, Doga M, Mazziotti G, Giustina A 2004 Cushing's syndrome and bone. *Pituitary* 7:249–252
64. Kim JH, Kim JW, Ko YH, Choi CU, Na JO, Kim EJ, Rha SW, Park CG, Seo HS, Oh DJ 7 March 2009 Coronary endothelial dysfunction associated with a depressive mood in patients with atypical angina but angiographically normal coronary artery. *Int J Cardiol* 10.1016/j.ijcard.2009.02.004
65. Chrousos GP 2000 The role of stress and the hypothalamic-pituitary-adrenal axis in the pathogenesis of the metabolic syndrome: neuroendocrine and target tissue-related causes. *Int J Obes Relat Metab Disord* 24(Suppl 2):S50–S55
66. Woo YS, Isidori AM, Wat WZ, Kaltsas GA, Afshar F, Sabin I, Jenkins PJ, Monson JP, Besser GM, Grossman AB 2005 Clinical and biochemical characteristics of adrenocorticotropin-secreting macroadenomas. *J Clin Endocrinol Metab* 90:4963–4969