

Case Report

Long-Term Use of Temozolomide as Safe and Effective Therapy for an Aggressive Corticotroph Adenoma in a Very Old Patient

Maria Chiara Decaroli,^{1,2} Anna Ansaloni,² Maria Laura Monzani,^{1,2} Marco Losa,³ Elena Zunarelli,⁴ Vincenzo Rochira,^{1,2} and Bruno Madeo²

¹Unit of Endocrinology, Department of Biomedical, Metabolic and Neural Sciences, University of Modena and Reggio Emilia, Modena, Italy; ²Unit of Endocrinology, Department of Medical Specialties, Ospedale Civile di Baggiovara, Azienda Ospedaliero-Universitaria of Modena, Modena, Italy; ³Department of Neurosurgery, IRCCS San Raffaele Scientific Institute, Vita-Salute San Raffaele University, Milan, Italy; ⁴Anatomic Pathology Unit, Department of Morphological Sciences, University of Modena and Reggio Emilia, Azienda Ospedaliero-Universitaria di Modena, Italy.

ORCID numbers: 0000-0002-9727-1135 (M. C. Decaroli); 0000-0001-9345-5896 (A. Ansaloni); 0000-0001-8586-5457 (M. L. Monzani); 0000-0001-7810-8247 (M. Losa); 0000-0002-2028-1570 (E. Zunarelli); 0000-0001-8169-0696 (V. Rochira); 0000-0003-2881-982X (B. Madeo).

Received: 6 November 2020; Editorial Decision: 1 April 2021; First Published Online: 10 April 2021; Corrected and Typeset: 28 June 2021.

Abstract

Background: Temozolomide (TMZ) is safe and effective in the treatment of aggressive pituitary adenomas (PAs). However, the optimal duration of TMZ therapy is still unknown. Moreover, data about administration of TMZ in elderly (≥ 65 years) people to treat aggressive PAs are scarce. We report the case of the oldest female patient undergoing the longest TMZ protocol described so far to treat an aggressive, initially silent corticotroph PA.

Case report: The patient initially underwent partial surgical removal of the PA. Subsequent treatment with cabergoline was applied, but it was unsuccessful in controlling the growth of the residual tumor. Pasireotide and external radiation also showed to be ineffective; therefore, treatment with TMZ was started at the standard dose of 200 mg/m²/day for 5 days every 4 weeks for a total of 47 cycles. At the time of treatment's beginning, the patient was 83 years old. Radiological follow-up documented a progressive, remarkable reduction of the adenoma and the last imaging, after 39 cycles of TMZ, showed an intrasellar lesion with large areas of cystic degeneration. The patient also developed adrenal deficiency managed with glucocorticoid replacement. No major side effects were observed throughout the treatment, with exception of nausea, well controlled with anti-emetic medication. TMZ therapy was discontinued after 47 cycles; hormonal and imaging follow-up investigations documented sustained functional and dimensional response.

Conclusions: Our case supports the long-term use of TMZ, confirming its safety and efficacy also for elderly patients.

Key Words: temozolomide, aggressive pituitary adenoma, old age, long-term treatment, case report

Pituitary adenomas (PAs) are the most common tumors of the hypothalamic-pituitary region [1]. The majority of PAs follows a benign clinical behavior, remaining quiescent for long time or having very slow, noninvasive expansion; however, some of them may have an aggressive progression [2,3]. The last European Society of Endocrinology guidelines define as aggressive PAs those pituitary tumors showing resistance and/or recurrence after optimal standard therapies coupled with radiologically documented invasion, regardless of their histological features such as mitotic count, MIB-1 labeling index or p53 protein expression [3,4].

Temozolomide (TMZ) is a second-generation alkylating agent administered orally and readily crossing the blood-brain barrier. TMZ is rapidly converted to its active metabolite that carries out a cytotoxic action through methylation of DNA at the O⁶ position of guanine, leading to mismatching at the following cycle of DNA replication and, finally, to cellular apoptosis [2,5]. O(6)-methylguanine-DNA methyltransferase (MGMT) is a DNA-repairing protein able to remove alkylating adducts induced by TMZ; thus, its high expression is considered as predictor of resistance to TMZ [6,7].

TMZ is the first-line treatment for gliomas and it is effective also against advanced melanomas and malignant neuroendocrine tumors [8-10]. Since 2006 TMZ has been successfully used in the treatment of aggressive PAs and carcinomas [7,8], particularly toward corticotroph adenomas, prolactinomas, and nonfunctioning tumors [9,11]. However, evidence through properly designed studies regarding the optimal duration of TMZ treatment to reach the best clinical response are still scarce [4,6]. Most of the case-series available so far report short-term therapy (≤ 12 months) protocols, but relapse of disease after TMZ withdrawal and subsequent failure of a second course of treatment have been often described [4,6,12,13]. Recent data about long-term protocols of therapy (> 12 months) are encouraging, showing a trend toward longer overall survival and progression-free survival in patients receiving extended treatment in association with good toxicity tolerance [4,6,11,14].

The experience of TMZ administration in elderly people (≥ 65 years) for treatment of aggressive PAs is limited. Nevertheless, recent studies have shown that TMZ can lead to a good tumor control also in aging people with a

similar clinical response in elderly than the one observed in younger patients [3,15].

To the best of our knowledge, the longest protocol of TMZ therapy reported in literature so far for the treatment of an aggressive PA lasted 45 cycles [11], and the oldest patient undergoing a long-term TMZ protocol was a 73-year-old female at the time of starting TMZ [4].

Here we report the case of a female patient with an aggressive PA who was 83 years old at the beginning of TMZ and was treated with 47 cycles of therapy, achieving an excellent clinical response without major side effects.

Case Report

We report the case of a 78-year-old female who was initially evaluated by the neurosurgeon specialist in mid-2011 because of progressive visual disturbances and headache. Her clinical history was characterized by previous cholecystectomy, bilateral hip replacement surgery, nodular goiter, pharmacologically controlled mild hypertension (also reported in the family anamnesis), liver steatosis, and class II obesity (body mass index 36.2 kg/m²). At clinical evaluation, no elements suggestive of cortisol hypersecretion were detected. The computerized visual field detected bitemporal hemianopsia. Magnetic resonance imaging (MRI) showed an intra- and suprasellar lesion causing optic chiasm involvement (Fig. 1A). Presurgery laboratory pituitary function evaluation showed normal levels of thyroid-stimulating hormone (TSH), free thyroxine, prolactin (PRL), growth hormone (GH), and morning cortisol, while insulin-like growth factor 1 (IGF-1) levels were low (7.6 nmol/L – 10^o centile per age; reference range 7.1-26.7 nmol/L) and adrenocorticotrophic hormone (ACTH) levels were normal to high, according to laboratory reference range (Table 1).

The patient underwent trans-sphenoidal surgery in November 2011; only partial removal was possible because of the very hard consistency. Immunohistochemistry showed strong and diffuse immunoreactivity for ACTH antibody (Fig. 2), whereas TSH, GH, PRL, and follicle-stimulating hormone (FSH) immunoreactions were negative. Crooke's cells were absent. Mitotic index was low ($< 1/10$ high power fields), as well as MIB-1 labeling index ($< 3\%$). p53 protein expression was not detected. MGMT was unmethylated (average percentage of methylation: 5%).

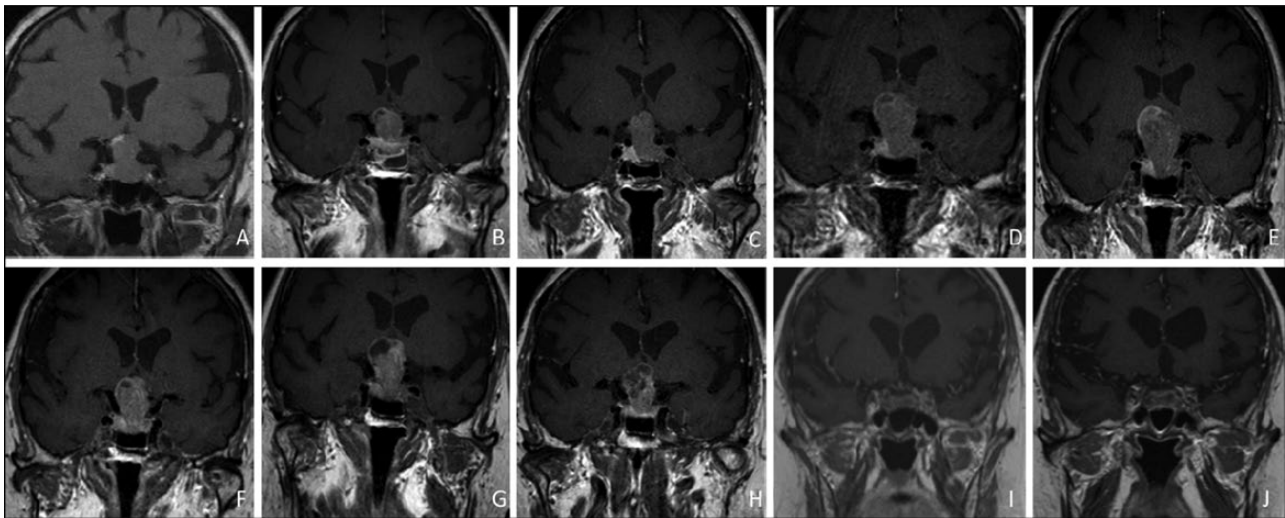


Figure 1. Radiological modifications of the PA on coronal T1 weighted MRI images. (A) First MRI evaluation showing a sellar lesion with suprasellar extension and optical chiasm involvement. (B) Macroresidual of tumor after surgery. (C) Regrowth of tumor mass 5 months after surgery. (D) Enlargement of tumor mass after 8 months of cabergoline treatment. (E) Further tumor enlargement despite 5 months of therapy with pasireotide. (F) Apparent minimal reduction of tumor mass one month after finishing external radiotherapy (total dose 54 Gy). (G) Volumetric increase >50% of the macroadenoma 10 months after external radiotherapy, with further compression of the anterior wall of third ventricle and of the hypothalamus. (H) Initial shrinkage of tumor mass after 3 cycles of TMZ. (I) Remarkable tumor reduction with cystic degeneration after 39 cycles of TMZ. (J) Sustained response without modifications of the minimal residual lesion 4 months after TMZ withdrawn.

Table 1. Trends of ACTH, cortisol, and first-line diagnostic tests according to ongoing treatment

Months after diagnosis	Ongoing treatment	ACTH (n.v. 1-11 pmol/L)	Morning cortisol (n.v. 184.9-623.5 nmol/L)	Cortisol after dexamethasone suppression (n.v. <50 nmol/L)
7	Before surgery	10	264.9	n.a.
13	After surgery	14	303.5	n.a.
24	After 8 months of cabergoline 1mg/week	27	386.3	212.4 (overnight 1 mg dexamethasone suppression test) 344.9 (2 days low dose dexamethasone suppression test)
40	After 14 months of pasireotide 1,2 mg/day	24	413.9	n.a.
55	10 months after external RT	13	397.3	n.a.
90	31 st cycle of TMZ	7	171.1	n.a.
110	4 months after TMZ withdrawn	2	546.3 ^a	n.a.

Reference range for the serum cortisol after dexamethasone suppression tests was <50 nmol/L.

Abbreviations: n.a., not available; n.v., normal values.

^aGlucocorticoids replacement therapy ongoing.

The patient arrived at our attention after the surgery; MRI confirmed a residual macroadenoma in the sellar region with the longest cranium-caudal diameter of 20 mm (Figs. 1B and 3), and the computerized visual field showed progression of bitemporal hemianopsia. The patient refused a second operation mainly because of the high anesthesiology risk (American Society of Anesthesiologists risk class 3).

Postoperative glucocorticoids were gradually withdrawn, subsequent laboratory investigations showed normal levels of serum cortisol and 24-h urinary free cortisol (the latter unreliable result because of partial incontinence), although

in presence of slightly increased ACTH levels (Table 1). Diagnosis of nonfunctioning corticotroph PA (ie, silent, corticotroph adenoma) was therefore made based on the previously discussed findings, the absence of Cushing disease signs and symptoms, and the ACTH immunoreactivity at the histological evaluation (although overnight 1 mg dexamethasone suppression test should had been performed for completeness) [16,17]. After a negative imaging with ¹¹¹In-pentetreotide (Octreoscan), Cabergoline treatment at the dose of 1 mg/week was started.

During the follow-up, serial MRI imaging showed an increase in the tumor size (longest diameter: 31 mm, March

2013) (Figs. 1D and 3). Further laboratory exams recorded progressively increased ACTH levels, abnormal cortisol circadian rhythm with midnight serum levels >193.1 nmol/L and positive tests for Cushing's disease (serum cortisol 212.4 nmol/L and 344.9 nmol/L after overnight 1 mg dexamethasone suppression test and 2 days low-dose dexamethasone suppression test, respectively) (Table 1). Consequently, diagnosis of ACTH-secreting PA was made, notwithstanding the absence of overt signs and symptoms of hypercortisolism. Cabergoline was withdrawn and, despite previous negative Octreoscan imaging, treatment with Pasireotide 1.2 mg/day was administered for 16 months, without a significant control of cortisol and ACTH levels (Table 1). Moreover, MRI documented further enlargement

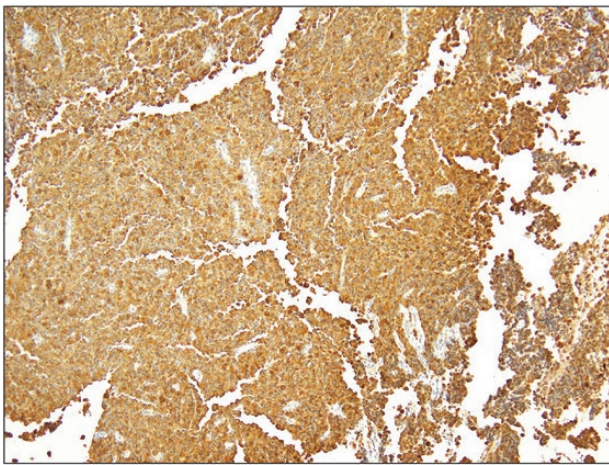


Figure 2. Histopathology of PA showing diffuse and strong immunohistochemical expression of ACTH.

of the tumor (longest diameter 33 mm) (Figs. 1E and 3). Central hypothyroidism was diagnosed and the patient developed diabetes mellitus secondary to Pasireotide, which led to treatment withdrawal.

In February 2015, radiotherapy thorough fractionated external beam radiation was delivered in 30 fractions with a total dose of 54 Gy. Despite an initial minimal size reduction (Figs. 1F and 3), the 10-month follow-up MRI documented a $>50\%$ volumetric increase of the macroadenoma (Figs. 1G and 3), with further compression of the anterior wall of third ventricle and of the hypothalamus.

Taking in consideration the failure of surgery, previous medical therapies, and RT, and that the rare transition from silent to functioning corticotroph PA is linked to higher aggressiveness [18], we started treatment with TMZ in February 2016, when the patient was 83-year-old. Oral TMZ at the standard dose of $200 \text{ mg/m}^2/\text{day}$ (total 390 mg/day) was administered for 5 days every 4 weeks, according to the standard regimen [6]. The patient experienced notable nausea and vomiting after the first TMZ administration, however regular medication with anti-emetic at each monthly-cycle of TMZ therapy kept the symptoms under control for the whole treatment duration. The patient did not report any other significant side effects beside occasional mild headache and fatigue. The monthly blood investigations did not detect any sign of myelotoxicity. During the treatment, cortisol serum levels progressively decreased until below the normal range and were associated with inappropriate normal ACTH levels (Table 1). In addition, the patient developed signs (mild hyponatremia) and symptoms (hypotension) of hypocortisolism. Therefore, a

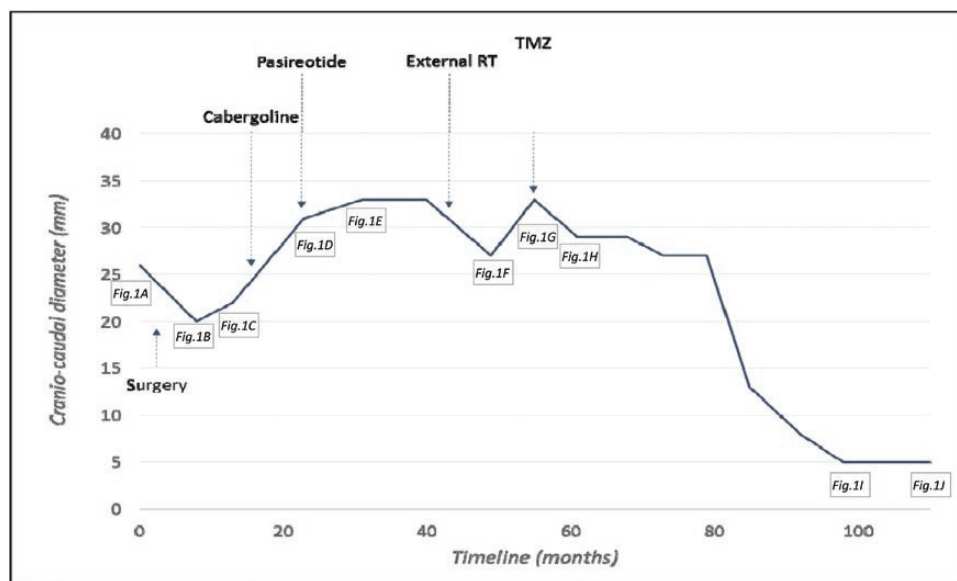


Figure 3. Dimensional modifications of the cranio-caudal diameter of PA during time together with timing of therapies. References to corresponding MRI images of Figure 1 are reported.

replacement therapy with glucocorticoids was implemented even without a prior ACTH-stimulating test confirming central hypocortisolism. MRI follow-up documented a progressive, remarkable reduction of the adenoma, with the most significant shrinkage starting from the 27th cycle of therapy (Figs. 1H and 3), while the MRI performed after 39 cycles of TMZ found that the lesion was limited to the sellar region and presented with large areas of cystic degeneration (Fig. 1I). We did not observe clinical improvement of visual field because of the irreversible damage to the optic chiasm.

TMZ treatment was stopped after 47 cycles (106 months after the first diagnosis) when the patient was 87 years old, in consideration of the excellent clinical outcome, the difficulty of management due to the concomitant COVID-19 emergency and, most of all, the patient's desire. The MRI performed 4 months after TMZ withdrawal showed a sustained response without size modifications of the minimal residual lesion (Figs. 1J and 3). The hormonal assessment documented serum cortisol levels well compensated by glucocorticoid replacement therapy, in association with normal-to-low ACTH levels (Table 1).

The patient provided written informed consent for the publication of this clinical case report and the accompanying images. The study is complying with the specific requirements of the local ethics committee.

Discussion

To the best of our knowledge, this is the first case of a patient > 80-year-old undergoing TMZ for the treatment of an aggressive PA reported in the literature, and, with the longest TMZ protocol (47 cycles) described to date. We observed an excellent clinical and radiological response to the treatment and an optimal long-term tolerability profile without major side effects. With the awareness that it is not possible to make general statements from a single case, we think that some interesting considerations could be drawn.

The absence of severe toxicity is in line with the literature showing a low prevalence of side effects, mainly mild and related to myelotoxicity, during TMZ treatment [7,8,13,19]. We cannot exclude that a very prolonged duration of treatment with an alkylating agent such as TMZ could increase the risk of developing side effects, mainly concerning myelotoxicity. However, we think it is worthy to emphasize the high tolerability of TMZ in our case not only because of the long treatment duration, but also considering the age of the patient. According to our experience, and considering the increasing life expectancy and the general improvement of health status of the last decades, we

are confident in proposing TMZ treatment of aggressive PA also for elderly patients.

Very aggressive PAs show continuous growth and relapses after traditional therapies. Thus, not only a reduction in size, but also the achievement of disease stability can be considered a positive clinical outcome, because it prevents the onset of further local spread and complications. By this definition, TMZ has demonstrated to be an extremely effective therapy, showing response rates up to 70–80% if control and improvement of disease are considered together [6,8,19]. Our case confirms the clinical importance of obtaining disease stability: the control of the tumor size, achieved in the first two years of TMZ treatment, allowed preventing further visual loss for the patient and other possible local complications that would have been difficult to manage otherwise, encouraging the prolongation of TMZ protocol.

Furthermore, starting from the 27th cycle of therapy, we recorded an extensive and rapid tumor shrinkage, up to the point that the last MRI performed during TMZ treatment described only a sub-centimetric, almost cystic and completely intra-sellar tumor residue (Figs. 1I and 3). According to the data reported in literature, PAs achieving a significant dimensional reduction during TMZ treatment usually show the first radiological signs of shrinkage quite early, on average already after 3–9 cycles [4,8]. Consequently, the latest European Society of Endocrinology (ESE) guidelines recommend a first evaluation of TMZ treatment response after 3 cycles and its withdrawal if radiological progression is documented [3]. Our experience suggests that some patients may obtain a significant response to treatment later than after 3 cycles of TMZ and encourages perseverance by both the clinician and the patient when no severe side effects occur. In fact, in our patient we obtained tumor shrinkage much later than described in literature, but, once detected, it was quick and of a considerable amount. One could argue that the delayed tumor shrinkage could be due to previous external RT treatment rather than to TMZ. Since the time window necessary in significantly reducing PAs size after external RT is not known and the effects of radiation treatments usually last for many years [20], this hypothesis cannot be completely excluded. However, according to the few data derived from studies on stereotactic radiosurgery (acknowledging the difference between the two radiotherapy methods), the median time to the earliest volume reduction after radiation treatment is 6–9 months [21], while the 10-months post RT MRI imaging in our patient documented a 67% volumetric increase of the lesion compared to the previous one (Figs. 2 and 3F). Although an initial, small volumetric increase can occur

within 6 to 12 months after radiation therapy (RT) likely because of induced intratumor edema, it is very rare in the setting of PAs and, in any case, dimensionally <15% [21]. Considering the previous discussion, we think that the PA was resistant to RT, and we link the good clinical outcome of our patient more to the salvage therapy with TMZ rather than to RT. To support the importance of TMZ treatment, we underline that the MRI imaging pattern of tumor shrinkage was strongly correlated to typical TMZ effects, including tumor necrosis, hemorrhage, and cystic degeneration (Fig. 1) [22]. However, we cannot rule out the possibility that the delayed effects of RT and the long-term TMZ therapy have reinforced each other thus leading to the tumor reduction. Although the median time between RT and TMZ reported in literature widely varies, it is usually very long, ranging from 39 to 64 months [4,8]. In our case, the shorter-than-usual interval between the previous radiation treatment and the following TMZ may have helped in enhancing the TMZ effect. A recent ESE survey documented that TMZ therapy given concomitantly with RT can increase the rate of response if compared with TMZ in monotherapy [19]. This supports our presumption that, although a PA shows a radiation-resistant behavior, a shorter latency between RT and TMZ may allow their mutual reinforcement, which, on the other hand, can be lost with a years-long interval in between the 2 treatments.

Our data are in line with the growing evidence that a long-term therapy with TMZ is more effective in controlling disease progression compared to short-term protocols [4,6,11,13], and it should be applied whenever possible. Furthermore, it is documented that resumption of TMZ therapy in case of disease progression after a first withdrawal is often unsuccessful in blocking the tumor growth;—likewise for other salvage treatment trialed so far [4,7].

Thanks to its action of DNA repairing, a high expression of MGMT is considered as being a proxy indicator of resistance to TMZ treatment [6,7]. The degree of expression of MGMT was proposed to be estimated through the assessment of methylation status of MGMT gene, assuming an inverse relation between the methylation of the gene and the synthesis of the protein. [9]. In our case, we obtained an excellent clinical outcome despite a very low MGMT methylation. Anyhow, the MGMT methylation is not always able to predict responsiveness to TMZ, probably because of the lack of direct relationship between gene methylation and expression and/or the inaccuracy of methods used to estimate methylation [2,4,9]. Overall, the expression of MGMT assessed directly by immunohistochemistry methods is considered a good indicator of response to TMZ therapy [7].

Finally, the latency observed in the literature between the diagnosis of PA and the beginning of TMZ therapy ranges from 6 to 10 years [11,13,14]. In our case, we started TMZ about 4 years after the first diagnosis; thus, we cannot exclude that an earlier utilization of TMZ could also have contributed to our excellent radiological response.

Overall, we are aware that our clinical management could appear somehow imperfect, since eventually a second operation by an experienced neurosurgeon could have been more effective or even conclusive. However, we must highlight that the patient categorically refused a second surgery and/or any other invasive intervention. Therefore, we aimed to be minimally invasive, but, at the same time, we tried ensuring the patient the best treatment possible in a setting of real-life clinical practice.

In conclusion, our case reinforces the pertinence and advisability of long-term TMZ protocols when well-tolerated, supports the evidence of its safety for elderly patients to improve expectancy and quality of life, and raises the question whether a shorter latency between traditional therapies (especially RT) and TMZ could lead to a better management of aggressive PAs.

Acknowledgments

The authors thank Dr. Laura Cremonini for having proofread and edited the manuscript.

Additional Information

Correspondence: Bruno Madeo, Unit of Endocrinology, Department of Medical Specialties, Ospedale Civile di Baggiovara, Azienda Ospedaliero-Universitaria of Modena (Italy), Via Giardini, 1355–41126 Modena, Italy. Email: bruno.madeo@unimore.it.

Disclosures: The authors have nothing to disclose.

Data Availability: All data generated or analyzed during this study are included in the case report.

References

- McNeill KA. Epidemiology of Brain Tumors. *Neurol Clin.* 2016;34(4):981-998.
- McCormack AI, Wass JA, Grossman AB. Aggressive pituitary tumours: the role of temozolomide and the assessment of MGMT status. *Eur J Clin Invest.* 2011;41(10):1133-1148.
- Raverot G, Burman P, McCormack A, et al; European Society of Endocrinology. European Society of Endocrinology Clinical Practice Guidelines for the management of aggressive pituitary tumours and carcinomas. *Eur J Endocrinol.* 2018;178(1):G1-G24.
- Lizzul L, Lombardi G, Barbot M, et al. Long-course temozolomide in aggressive pituitary adenoma: real-life experience in two tertiary care centers and review of the literature. *Pituitary.* 2020;23(4):359-366.

5. Liu JK, Patel J, Eloy JA. The role of temozolomide in the treatment of aggressive pituitary tumors. *J Clin Neurosci*. 2015;22(6):923-929.
6. Syro LV, Rotondo F, Ortiz LD, Kovacs K. 65 years of the double helix: treatment of pituitary tumors with temozolomide: an update. *Endocr Relat Cancer*. 2018;25(8):T159-T169.
7. Bengtsson D, Schröder HD, Andersen M, et al. Long-term outcome and MGMT as a predictive marker in 24 patients with atypical pituitary adenomas and pituitary carcinomas given treatment with temozolomide. *J Clin Endocrinol Metab*. 2015;100(4):1689-1698.
8. Losa M, Bogazzi F, Cannavo S, et al. Temozolomide therapy in patients with aggressive pituitary adenomas or carcinomas. *J Neurooncol*. 2016;126(3):519-525.
9. Chen C, Yin S, Zhang S, et al. Treatment of aggressive prolactinoma with temozolomide: a case report and review of literature up to date. *Medicine (Baltimore)*. 2017;96(47):e8733.
10. Tatar Z, Thivat E, Planchat E, et al. Temozolomide and unusual indications: review of literature. *Cancer Treat Rev*. 2013;39(2):125-135.
11. Ji Y, Vogel RI, Lou E. Temozolomide treatment of pituitary carcinomas and atypical adenomas: systematic review of case reports. *Neurooncol Pract*. 2016;3(3):188-195.
12. Campderá M, Palacios N, Aller J, et al. Temozolomide for aggressive ACTH pituitary tumors: failure of a second course of treatment. *Pituitary*. 2016;19(2):158-166.
13. Lasolle H, Cortet C, Castinetti F, et al. Temozolomide treatment can improve overall survival in aggressive pituitary tumors and pituitary carcinomas. *Eur J Endocrinol*. 2017;176(6):769-777.
14. Elbelt U, Schläffer SM, Buchfelder M, et al. Efficacy of temozolomide therapy in patients with aggressive pituitary adenomas and carcinomas: a German survey. *J Clin Endocrinol Metab*. 2020;105(3):dgz211.
15. Tatsi C, Stratakis CA. Aggressive pituitary tumors in the young and elderly. *Rev Endocr Metab Disord*. 2020;21(2):213-223.
16. Raverot G, Wierinckx A, Jouanneau E, et al. Clinical, hormonal and molecular characterization of pituitary ACTH adenomas without (silent corticotroph adenomas) and with Cushing's disease. *Eur J Endocrinol*. 2010;163(1):35-43.
17. Scheithauer BW, Jaap AJ, Horvath E, et al. Clinically silent corticotroph tumors of the pituitary gland. *Neurosurgery*. 2000;47(3):723-729; discussion 729.
18. Righi A, Faustini-Fustini M, Morandi L, et al. The changing faces of corticotroph cell adenomas: the role of prohormone convertase 1/3. *Endocrine*. 2017;56(2):286-297.
19. McCormack A, Dekkers OM, Petersenn S, et al.; ESE survey collaborators. Treatment of aggressive pituitary tumours and carcinomas: results of a European Society of Endocrinology (ESE) survey 2016. *Eur J Endocrinol*. 2018;178(3):265-276.
20. Bonneville J-F. *The pituitary gland after radiation therapy*. In: Bonneville J-F, Bonneville F, Cattin F, Nagi S, *MRI of the Pituitary Gland*. 1st ed. Springer International; 2016:205-209.
21. Mak HK, Lai SW, Qian W, et al. Effective time window in reducing pituitary adenoma size by gamma knife radiosurgery. *Pituitary*. 2015;18(4):509-517.
22. Syro LV, Ortiz LD, Scheithauer BW, et al. Treatment of pituitary neoplasms with temozolomide: a review. *Cancer*. 2011;117(3):454-462.