

11. Roberts M, Butterworth AE, Kimani G, et al. Immunity after treatment of human schistosomiasis: association between cellular responses and resistance to reinfection. *Infect Immun* 1993;61:4984–93.
12. Steel C, Nutman TB. Regulation of IL-5 in onchocerciasis. A critical role of IL-2. *J Immunol* 1993;150:5511–8.
13. Steel C, Guinea A, Ottesen EA. Evidence for protective immunity to bancroftian filariasis in the Cook Islands. *J Infect Dis* 1996;174:598–605.
14. Wong MM, Guest MF. Filarial antibodies and eosinophilia in human subjects in an endemic area. *Trans R Soc Trop Med Hyg* 1969;63:796–800.
15. Horii Y, Nakanishi H, Mori A, et al. Eosinophil hyporesponse of jirds induced by microfilariae of *Brugia pahangi*. *Am J Trop Hyg* 1989;41:183–8.
16. Elson LH, Calvopina MH, Paredes WY, et al. Immunity to onchocerciasis: putative immune persons produce a Th1-like response to *Onchocerca volvulus*. *J Infect Dis* 1995;171:652–8.

Foodborne Outbreaks of Human Toxoplasmosis

Won-Young Choi, Ho-Woo Nam, No-Hoon Kwak,
Won Huh, Yang-Ree Kim, Moon-Won Kang,
Seung-Yull Cho, and J. P. Dubey

Departments of Parasitology, Ophthalmology, and Internal Medicine,
School of Medicine, Catholic University of Korea, Seoul; Parasite
Biology and Epidemiology Laboratory, Livestock and Poultry Sciences
Institute, Agricultural Research Service, US Department of Agriculture,
Beltsville, Maryland

Two outbreaks of acute toxoplasmosis involving 8 adult patients in Korea were linked to eating uncooked pork. In the first outbreak, 3 patients developed unilateral chorioretinitis within 3 months of eating a meal consisting of raw spleen and liver of a wild pig. In the second outbreak, 5 of 11 soldiers who ate a meal consisting of raw liver of a domestic pig developed lymphadenopathy. All 8 patients had high levels of IgG *Toxoplasma gondii* antibodies ($\geq 1:1024$) in the Sabin-Feldman dye test, modified agglutination test incorporating mercaptoethanol, and latex agglutination test. *T. gondii* IgM antibodies persisted in these patients for several months. Most patients had a favorable response to anti-*T. gondii* chemotherapy with pyrimethamine and sulfanomides.

Infections by the protozoan parasite *Toxoplasma gondii* are widely prevalent in humans and animals worldwide [1, 2]. Toxoplasmosis is generally asymptomatic except in immunocompromised adults and congenitally infected children. Humans acquire *T. gondii* infection postnatally mainly by ingesting food and water contaminated with oocysts passed in feces of infected cats or by ingesting tissue cysts in undercooked infected meat. Oocyst-induced infections are generally more severe than tissue cyst-induced infections [1]. In two well-documented outbreaks linked to ingestion or inhalation of oocysts, >90% of adults became ill [3, 4]. There is overwhelming epidemiologic evidence that in some countries, such as France, the ingestion of tissue cysts in infected meat is the major source of infection [5]. However, there are few reports of outbreaks of *T. gondii* infections linked to ingestion of infected meat [1]. These reports include small outbreaks (in humans) thought to be due to the ingestion of beef [6, 7], lamb [8, 9], or venison [10]. We report two outbreaks of clinical toxoplasmosis, considered to be due to the ingestion of raw pork, involving either eyes or lymph nodes in humans in Korea.

Patients and Methods

Patients. In the first outbreak, only 3 male Korean merchants (46, 48, and 42 years old; patients A1, A2, and A3, respectively) became ill of the 6 (4 men, 2 women) who feasted on 27 September 1994 on raw boar viscera and pork at a farm house near Kimchon City, Kyongsangbuk Do, Korea, in a belief of its special nutritional value. Two months later, patient A1 suddenly felt a gleam in his left eye, followed by a gradual loss of vision to total blindness in 1 month. The right eye was unaffected and he had no other symptoms. Patients A2 and A3 experienced unilateral visual loss at almost the same time. All 3 patients were treated together with unidentified antibiotics and steroids at a local eye clinic.

Four months later, the 3 patients were transferred to the Department of Ophthalmology, Kangnam St. Mary's Hospital, Catholic Medical Center, Seoul, because vision was not restored. A presumptive diagnosis of toxoplasmic chorioretinitis was based on fundic examination. Serologic examination for *T. gondii* (table 1) supported results of the fundus examination. Results of other hematologic and biochemical tests were within normal ranges (data not shown).

Further enquiry into this episode revealed that the 2 unaffected women did not eat raw boar meat at all and the unaffected man ate only a small amount of raw boar meat because he was diabetic. The 3 affected patients (A1–A3) had previous experiences of getting together every January of 1991, 1992, and 1993 for similar feasts. Patient A1 said that the boar meats eaten before January 1993 were not fresh but partly frozen. Freezing kills tissue cysts in meat [1]. In the case of the late September 1994 episode, they hunted the boar themselves and ate the boar meat at the feast.

In the second outbreak, 5 soldiers (patients B1–B5) in a squadron of the Republic of Korea Marine Corps, located at Kangwha Gun, Kyunggi Do, Korea, experienced sudden, indolent, multiple enlarged lymph nodes within 1 week beginning 31 January 1995.

Received 21 August 1996; revised 10 December 1996.

Grant support: Korea Science and Engineering Foundation (KOSEF-961-0716-101-1).

Reprints or correspondence: Dr. J. P. Dubey, USDA, ARS, LPSI, PBEL, Bldg. 1001, 10300 Baltimore Ave., Beltsville, MD 20705-2350.

The Journal of Infectious Diseases 1997;175:1280–2

© 1997 by The University of Chicago. All rights reserved.

0022-1899/97/7505-0043\$01.00

Table 1. Levels of anti-*Toxoplasma gondii* antibodies in various tests in Korean patients.

Patient	Date (month-day in 1995)*	LAT	ELISA (IgG)	Differential agglutination		Dye test	ELISA (IgM)
				FF	AF†		
A1	1-20	4096	1.18	1600	1600	4096	8.1
	2-3	2048	1.11	1600	1600	2048	5.8
A2	1-20	4096	1.14	1600	1600	2048	9.9
	2-3	4096	1.09	1600	800	2048	8.6
A3	2-3	1024	0.99	800	800	2048	4.9
	4-1	512	0.90	400	800	1024	6.2
B1	3-21	4096	1.10	1600	800	4096	8.2
	7-30	256	0.95	800	400	2048	6.2
B2	3-21	8192	1.09	1600	1600	4096	5.6
	7-30	512	0.88	400	400	1024	3.2
B3	3-21	8192	1.04	3200	1600	2048	9.7
	7-30	1024	1.08	800	800	2048	8.7
B4	3-21	4096	0.99	1600	800	2048	11.1
	7-30	512	0.91	800	800	2048	8.1
B5	3-21	8192	1.04	3200	1600	2048	6.8
	7-30	256	0.94	800	400	512	4.9

NOTE. LAT, latex agglutination test; FF, formalin-fixed antigen; AF, acetone-fixed antigen.

* Days blood was collected for serology; first date = initial examination; second date = during or after drug treatment.

† Titers of >1:1000 are highly indicative of recently acquired infection.

They were all in their early 20s. Naval surgeons suspected toxoplasmic lymphadenitis because all 5 patients had eaten raw liver and uncooked meat from a domestic pig. The pig had been reared in the yard of their military compound. Further inquiry revealed that 11 soldiers (B1–B5 and 6 others) participated in a New Year's party on 1 January 1995 and together ate raw pork. Serum samples from all 11 soldiers were examined for *T. gondii* antibodies.

Histopathologic examination. Of the 5 clinical cases in the second outbreak, 1 patient volunteered a biopsy of a mass at his anterior chest wall.

Serologic examination. Sera from patients were initially tested for *T. gondii* antibodies in Korea using a commercially available latex agglutination test (LAT, Toxotest; Eiken Chemical, Tokyo) and an ELISA using crude *T. gondii* tachyzoite lysate [11]. Two-fold dilutions of serum were examined, starting at a 1:32 dilution in LAT. About 1 year later, all sera were reexamined in the United States for *T. gondii* antibodies by the differential agglutination test, using whole formalin- or acetone-fixed tachyzoites as described [12, 13]. This test measures only IgG antibodies, because the mercaptoethanol used in the test destroys specific and nonspecific IgM antibodies. The acetone-fixed antigen detects IgG antibodies directed against tachyzoites during acute toxoplasmosis, and the test is very useful in differentiating acute from chronic infection [13]. The test was done at the Beltsville site using antigen prepared at the Institute of Puericulture (Paris) as described [12].

The Sabin-Feldman dye test and IgM ELISA were done in the laboratory of J. S. Remington (Palo Alto Medical Foundation, Palo Alto, CA) [2]. For the dye test, sera were diluted 2-fold, starting at a 1:16 dilution. Although titers of >1:1000 may suggest recently acquired infection, such titers are not uncommon in the general population. For the IgM ELISA, an OD of 0.1–1.6 is considered negative, 1.7–1.9 is equivocal, and ≥ 2.0 is positive.

Treatment. Beginning 24 January 1995, patient A1 was treated with pyrimethamine alone (25 mg/day, Daraprim; Burroughs Wellcome, Tuckahoe, NY) daily for 4 weeks because of his drug sensitivity to sulfonamides. Patients A2 and A3 were treated with sulfonamide (500 mg/day) and pyrimethamine (25 mg/day, Fansidar F; Hoffmann-La Roche, Basel, Switzerland) daily for 4 weeks.

In the second outbreak, after the presumptive diagnosis of toxoplasmosis was supported by serologic examination, the 5 patients were treated with sulfonamide-pyrimethamine for 1 month, except for 1 who developed Steven-Johnson syndrome after 7 days. Chemotherapy was immediately stopped in this patient and corticosteroid treatment was initiated.

Results

All 8 patients with symptoms of toxoplasmosis had high levels of antibodies detected by multiple tests (table 1). Antibody levels had decreased in all 8 patients in the second blood sample collected after chemotherapy.

Initial ophthalmic examination revealed vision of 20/40 for the left eye of patient A1. He had focal chorioretinitis (figure 1) with moderate vitreous haziness. In patients A2 and A3, initial visual acuity in the affected eye was 20/400 and 20/300, respectively, with severe vitreous haziness. In patient A1, vision improved after 10 days of chemotherapy, and visual acuity returned to 20/20 after 3 months; there was a persistent localized scar. Due to macular scarring, patients A2 and A3 remained blind even after chemotherapy.

All 5 patients with lymphadenopathy (second outbreak) had high levels of *T. gondii* antibodies; the 6 soldiers without

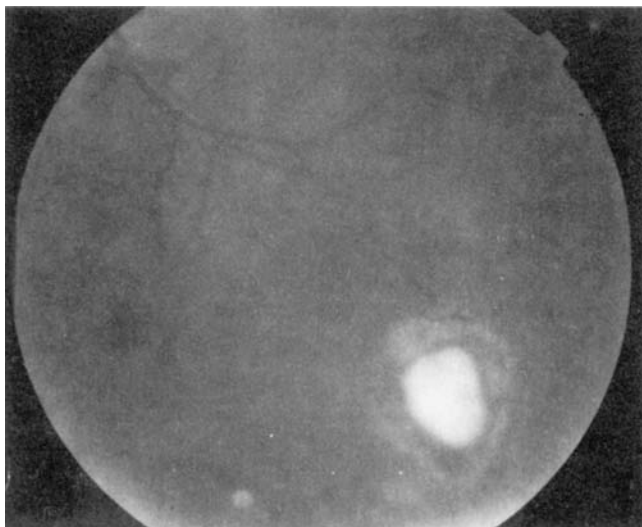


Figure 1. Fundus of subject A1, 15 days before start of treatment with pyrimethamine, showing focal demarcated lesion of chorioretinitis with vitreous haziness.

lymphadenopathy who were tested had no *T. gondii* antibodies. Except for the lymphadenopathy, subjects B1–B5 did not manifest other clinical symptoms. In each, 1–4 lymph nodes were palpable (1–2.5 cm long). These enlarged lymph nodes were found in the posterior neck, subclavicular area, right axilla, and left anterior chest (biopsied) in B1; neck and right axilla in B2; submandibular area and right axilla in B3; posterior neck and right axilla in B4; and neck in B5. Histologic sections of the lymph node biopsy material showed lesions consistent with toxoplasmic lymphadenitis with secondary germinal centers [1] dominated with methyl green pyronin–positive cells. Hematologic and biochemical tests were normal.

Discussion

Two observations in this report are important. First, patients developed uniform symptoms in each episode. All 3 patients in the first outbreak had unilateral chorioretinitis and all 5 patients in the second outbreak had lymphadenopathy. Second, infections were linked to eating undercooked pork. In food animals, *T. gondii* is more prevalent in pigs, sheep, and goats than in beef cattle or chickens [1]. Tissue cysts of *T. gondii* are found in visceral tissues as well as muscles and neural tissues of domestic animals [1]. In the present report, circumstantial evidence identified pigs as the source of infection.

Until recently, toxoplasmic chorioretinitis in humans was generally considered to be largely congenitally acquired. However, evidence is accumulating that chorioretinitis may be frequent in patients with acquired toxoplasmosis [9, 14, 15].

Acknowledgments

We thank Se-Hun Chang and Sah-Jin Bae, Naval Surgeons, who treated soldiers in the second outbreak; Nam-Seok Lee for his technical help; and J. S. Remington for the dye test, IgM ELISA, and advice.

References

- Dubey JP, Beattie CP. Toxoplasmosis of animals and man. Boca Raton, FL: CRC Press, 1988.
- Remington JS, McLeod R, Desmonts G. Toxoplasmosis. In: Remington JS, Klein JO, eds. Infectious diseases of the fetus and newborn infant. 4th ed. Philadelphia: WB Saunders, 1995:140–67.
- Benenson MW, Takafuji ET, Lemon SM, Greenop RL, Sulzer AJ. Oocyst transmitted toxoplasmosis associated with ingestion of contaminated water. *N Engl J Med* 1982;307:666–9.
- Teutsch SM, Juranek DD, Sulzer A, Dubey JP, Sikes RK. Epidemic toxoplasmosis associated with infected cats. *N Engl J Med* 1979;300:695–9.
- Desmonts G, Couvreur J, Alison F, Baudelot J, Gerbeaux J, Lelong M. Étude épidémiologique sur la toxoplasmose: de l'influence de la cuisson des viandes de boucherie sur la fréquence de l'infection humaine. *Rev Fr Etud Clin Biol* 1965;10:952–8.
- Kean BH, Kimball AC, Christenson WN. An epidemic of acute toxoplasmosis. *JAMA* 1969;208:1002–4.
- Lord WG, Boni F, Bodek A, Hilberg RW, Rosini R, Clark FB. Toxoplasmosis—Pennsylvania. *Morbidity Mortality* 1975;24:285–6.
- Fertig A, Selwyn S, Tibble MJK. Tetracycline treatment in a food-borne outbreak of toxoplasmosis. *Br Med J* 1977;1:1064.
- Masur H, Lempert JA, Cherubini TD. Outbreak of toxoplasmosis in a family and documentation of acquired retinochoroiditis. *Am J Med* 1978;64:396–402.
- Sacks JJ, Delgado DG, Lobel HO, Parker RL. Toxoplasmosis infection associated with eating undercooked venison. *Am J Epidemiol* 1983;118:832–8.
- Choi WY, Nam HW, Youn JH, et al. Detection of antibodies in serum and cerebrospinal fluid to *Toxoplasma gondii* by indirect latex agglutination test and enzyme-linked immunosorbent assay. *Korean J Parasitol* 1992;30:83–90.
- Desmonts G, Remington JS. Direct agglutination test for diagnosis of *Toxoplasma* infection: method for increasing sensitivity and specificity. *J Clin Microbiol* 1980;11:562–8.
- Thulliez P, Remington JS, Santoro F, Ovlaque G, Sharma S, Desmonts G. Une nouvelle réaction d'agglutination pour le diagnostic du stade évolutif de la toxoplasmose acquise. *Pathol Biol* 1986;34:173–7.
- Bell A, Gill R, Isaac-Renton J, et al. Outbreak of toxoplasmosis associated with municipal drinking water—British Columbia. *Can Commun Dis Rep* 1995;21:161–3.
- Glasner PD, Silveira C, Kruszon-Moran D, et al. An unusually high prevalence of ocular toxoplasmosis in southern Brazil. *Am J Ophthalmol* 1991;114:136–44.