

¹⁸F-Fluorodeoxyglucose Positron Emission Tomography to Evaluate Cervical Node Metastases in Patients With Head and Neck Squamous Cell Carcinoma: A Meta-analysis

Panayiotis A. Kyzas, Evangelos Evangelou, Despina Denaxa-Kyza, John P. A. Ioannidis

Downloaded from <https://academic.oup.com/jnci/article/100/10/712/900767> by guest on 24 April 2024

Background	Positron emission tomography using ¹⁸ F-fluorodeoxyglucose (¹⁸ F-FDG PET) has been proposed to enhance preoperative assessment of cervical lymph node status in patients with head and neck squamous cell carcinoma (HNSCC). Management is most controversial for patients with a clinically negative (cN0) neck. We aimed to assess the diagnostic accuracy of ¹⁸ F-FDG PET in detecting lymph node metastases in patients with HNSCC.
Methods	We performed a meta-analysis of all available studies of the diagnostic performance of ¹⁸ F-FDG PET in patients with HNSCC. We determined sensitivities and specificities across studies, calculated positive and negative likelihood ratios (LR+ and LR-), and constructed summary receiver operating characteristic curves using hierarchical regression models. We also compared the performance of ¹⁸ F-FDG PET with that of conventional diagnostic methods (ie, computed tomography, magnetic resonance imaging, and ultrasound with fine-needle aspiration) by analyzing studies that had also used these diagnostic methods on the same patients.
Results	Across 32 studies (1236 patients), ¹⁸ F-FDG PET sensitivity was 79% (95% confidence interval [CI] = 72% to 85%) and specificity was 86% (95% CI = 83% to 89%). For cN0 patients, sensitivity of ¹⁸ F-FDG PET was only 50% (95% CI = 37% to 63%), whereas specificity was 87% (95% CI = 76% to 93%). Overall, LR+ was 5.84 (95% CI = 4.59 to 7.42) and LR- was 0.24 (95% CI = 0.17 to 0.33). In studies in which both ¹⁸ F-FDG PET and conventional diagnostic tests were performed, sensitivity and specificity of ¹⁸ F-FDG PET were 80% and 86%, respectively, and of conventional diagnostic tests were 75% and 79%, respectively.
Conclusion	¹⁸ F-FDG PET has good diagnostic performance in the overall pretreatment evaluation of patients with HNSCC but still does not detect disease in half of the patients with metastasis and cN0.

J Natl Cancer Inst 2008;100:712–720

The presence of cervical lymph node metastasis is an important prognostic factor in patients with head and neck squamous cell carcinoma (HNSCC). However, the management of patients without neck metastases, as determined from physical examination (ie, clinically negative neck, cN0), remains controversial (1,2). These patients usually undergo elective neck treatment (ie, elective neck dissection or radiotherapy) when the risk of occult cervical lymph node metastases is expected to be greater than 15%–20% (1–4). The probability of occult metastatic disease is estimated based on tumor stage, location, and histological characteristics. However, both the morbidity and the cost of the elective neck treatment are high because the majority of treated patients do not harbor cervical lymph node metastases. Thus, imaging techniques are often used to enhance the preoperative assessment of cervical lymph node status (5,6). Computed tomography (CT) and magnetic resonance imaging (MRI) are similar to each other in rates of detection of cervical lymph node metastases and may detect some occult nodal metastases that are missed by physical examination

(5–8). However, the overall diagnostic accuracy of CT and MRI for detecting metastases in the cN0 neck is insufficient (5,9); sensitivities range from 14% to 80% for CT and from 29% to 85% for MRI (5,10,11), and specificities range from 80% to 100% for

Affiliations of authors: Clinical and Molecular Epidemiology Unit, Department of Hygiene and Epidemiology, University of Ioannina School of Medicine, Ioannina, Greece (PAK, DDK, EE, JPAI); Department of Oral and Maxillofacial Surgery, Ninewells Hospital, NHS Tayside, Scotland, UK (PAK); Biomedical Research Institute, Foundation for Research and Technology-Hellas, Ioannina, Greece (JPAI); Institute for Clinical Research and Health Policy Studies, Department of Medicine, Tufts Medical Center, Boston, MA (JPAI).

Correspondence to: John P. A. Ioannidis, MD, Clinical and Molecular Epidemiology Unit, Department of Hygiene and Epidemiology, University of Ioannina School of Medicine, Ioannina 45110, Greece (e-mail: jioannid@cc.uoi.gr).

See “Notes” following “References.”

DOI: 10.1093/jnci/djn125

© The Author 2008. Published by Oxford University Press. All rights reserved. For permissions, please email: journals.permissions@oxfordjournals.org.

both CT and MRI (5,10,11), using pathology as the reference standard.

Positron emission tomography with the use of the radiolabeled glucose analogue ^{18}F -fluorodeoxyglucose (^{18}F -FDG PET) is increasingly being applied in the diagnosis, grading, staging, and assessment of treatment response in a variety of malignancies (12,13). It has been suggested that ^{18}F -FDG PET might be more accurate than CT and/or MRI in identifying cervical lymph node metastases in HNSCC (14,15) because it is considered to be a more sensitive technique (14). However, results from previous studies are controversial because single studies are inconclusive due to limited sample size and the use of a variety of methods for determining the performance of ^{18}F -FDG PET. Here, we undertook a meta-analysis of all available studies to address the diagnostic performance of ^{18}F -FDG PET in evaluating lymph node metastasis in patients with HNSCC and to compare its performance against standard diagnostic tools (ie, CT, MRI, and ultrasound with fine-needle aspiration [USFNA]).

Materials and Methods

Identification and Eligibility of Relevant Studies

We searched for studies evaluating ^{18}F -FDG PET as a diagnostic tool for detecting lymph node metastasis at the initial staging before surgical treatment in patients with HNSCC. We considered all relevant studies that included at least five patients with HNSCC (13) and had included both patients with and without cancerous lymph node infiltration according to histopathologic examination. Articles were identified with a MEDLINE search (last update July 31, 2007). We used a search algorithm that was based on a combination of the terms: 1) PET OR ^{18}F -FDG PET OR positron emission tomography OR fluorodeoxyglucose and 2) oral cancer OR head and neck cancer OR laryngeal cancer OR lymph node OR metastasis OR neck OR cervical, aiming for maximum sensitivity. References of the retrieved articles were also screened for additional studies. Investigators of eligible studies were contacted and asked to supplement additional data when key information relevant to the meta-analysis was missing. Among reports that pertained to overlapping patient cohorts, we retained only the largest study to avoid duplication of information. We had no language restrictions.

We created three major study groups according to the clinical node staging of the patients' population in each study. The first group included studies of patients who had clinically positive cervical lymph nodes (cN1, cN2, and cN3), for which neck dissection is considered as the treatment of choice. The second group included studies of patients who had clinically negative cervical lymph nodes (cN0). Finally, the third group included studies with mixed patient populations (both cN0 and cN positive). For each study, we recorded in detail the criteria applied to give the patient a neck dissection, especially in the studies with cN0 population and elective neck dissections, to exclude verification bias. We excluded studies with verification bias, that is, those that performed histopathologic examinations only on subsets of patients based on positive ^{18}F -FDG PET results. Studies using ^{18}F -FDG PET for the evaluation of recurrence after treatment were excluded. Also, stud-

CONTEXT AND CAVEATS

Prior knowledge

Knowing whether or not cancer has spread to lymph nodes in the neck is important for the prognosis and treatment of patients with head and neck squamous cell carcinoma (HNSCC). Positron emission tomography using ^{18}F -fluorodeoxyglucose (^{18}F -FDG PET) has been proposed as a diagnostic method for this assessment.

Study design

Meta-analysis of studies reporting the diagnostic performance of ^{18}F -FDG PET to detect lymph node metastasis in the necks of patients with HNSCC. Sensitivity and specificity of ^{18}F -FDG PET were compared with those of other diagnostic methods, including computed tomography and magnetic resonance imaging.

Contributions

^{18}F -FDG PET performed well in sensitivity and specificity analyses overall and was comparable to or slightly better than the other diagnostic methods compared. However, ^{18}F -FDG PET detected only half of the neck metastases in HNSCC patients with metastases who were clinically diagnosed as lymph node negative.

Implications

^{18}F -FDG PET has limited diagnostic performance in the evaluation of neck metastasis in patients with HNSCC, and its routine use in pretreatment evaluation of these patients is not supported.

Limitations

Few HNSCC patients who had been clinically diagnosed as node negative were available for the analysis. In many studies, the interpretation of the ^{18}F -FDG PET scans was qualitative and not blinded.

ies for which the elective treatment was radiotherapy (thus with no availability of histologic lymph node specimens) were excluded. Studies in which patients received chemotherapy or radiotherapy before neck dissection were also excluded.

Data Extraction

Two investigators (PAK and DDK) extracted data from eligible studies independently and resolved controversies by discussion. A third investigator (JPAI) settled any remaining discrepancies. We extracted data on characteristics of studies and patients, measurements performed, and results. For each report, we recorded the author names, journal, year of publication, country of origin, number of eligible patients, inclusion and exclusion criteria, number of patients analyzed, reasons for exclusions from the analysis, levels of cervical lymph nodes examined and evaluated (if applicable), number of lymph nodes (if applicable), study design for recruitment of case patients (prospective, retrospective, or unclear), Union International Contre le Cancer clinical stage of HNSCC, location of the primary tumor, technical characteristics and protocol of ^{18}F -FDG PET, definition of positive ^{18}F -FDG PET test (qualitative or quantitative methods), and number of experts who assessed and interpreted the results of ^{18}F -FDG PET. We also recorded whether there was any mention of blinding of ^{18}F -FDG PET measurements to the histopathologic and clinical results and/or to other diagnostic methods used (eg, CT and/or MRI) and vice versa.

For each study, we recorded the number of true-positive, false-positive, true-negative, and false-negative findings for ^{18}F -FDG PET in diagnosing cancerous lymph node infiltration using the histopathologic evaluation of the surgically removed lymph nodes as the reference standard. We used all available information, including findings per patient, per neck side, and per lymph node level. Neck dissection could be performed either unilaterally (one side of the neck) or bilaterally (both sides of the neck). The neck is usually divided into six lymph node levels (I–VI) (16); however, other classifications were also acceptable. This information was also recorded for the other diagnostic methods (CT, MRI, CT/MRI, and USFNA) and was used for comparison with ^{18}F -FDG PET in the eligible studies.

Statistical Analysis

Data on the diagnostic performance of ^{18}F -FDG PET were combined quantitatively across eligible studies. We combined sensitivities and specificities across studies using a hierarchical regression model (17). A fully Bayesian approach to model fitting was taken. This model allows more between- and within-study variability than do fixed-effect approaches, by allowing both test stringency and test accuracy to vary across studies (17). Uniform distributions were used as prior information for the specification of the unknown parameters of the hierarchical model. The inverse gamma prior was chosen for the between-study variance parameters. Different prior ranges that cover all plausible values were chosen for sensitivity analyses. Goodness-of-fit measures were computed for each diagnostic method to evaluate model fitting.

The aim was to obtain the overall diagnostic accuracy of ^{18}F -FDG PET for all the combined studies. The main analysis addressed the diagnosis of lymph node metastases per patient; secondary analyses incorporated the side of the neck and anatomic lymph node levels.

The hierarchical regression model allows the calculation at the same time of the summary sensitivity (true positives) and specificity ($1 - \text{false positives}$), taking into account the interdependence of these metrics. Moreover, the summary receiver operating characteristic (SROC) curve can be derived from the estimation of the parameters of the model. The SROC curve shows the summary trade-off between sensitivity and specificity across the included studies and the summary likelihood ratios. Likelihood ratios are also metrics that combine both sensitivity and specificity in their calculation. Positive likelihood ratio (LR+) is defined as the ratio of sensitivity over ($1 - \text{specificity}$), whereas negative likelihood ratio (LR−) is defined as the ratio of ($1 - \text{sensitivity}$) over specificity. When there is absolutely no discriminating ability for a diagnostic test, both likelihood ratios equal 1. The discriminating ability is better with higher LR+ and lower LR−. Although there is no absolute cutoff, a good diagnostic test may have LR+ greater than 5.0 and LR− less than 0.2.

We used the summary estimates of sensitivity and specificity obtained in the meta-analysis specifically for cN0 patients to calculate the negative predictive value (NPV, ie, the probability that a patient does not have metastasis when the test is negative) when the prevalence of node metastasis in the population is assumed to be 10%, 20%, 30%, 40%, 50%, 60%, 70%, and 80%.

Subgroup analyses were also performed according to clinical N stage (cN positive, cN0, mixed), definition of ^{18}F -FDG PET posi-

tivity (quantitative, qualitative, and unclear), type of study (prospective or retrospective), and blinding (yes vs no or not reported). For studies that included both cN0 and cN-positive patients, the relevant subsets of patients were included in the summary calculations for each N-stage subgroup when the data could be split into such subsets.

We also compared the performance of ^{18}F -FDG PET against conventional diagnostic methods (CT, MRI, CT/MRI, and USFNA) using the same hierarchical regression method (17). One analysis included data regardless of the type of compared conventional modality; if two or more different conventional diagnostic methods had been used separately in the same patient, a positive result was claimed when at least one of the conventional tests had given a positive reading. Another set of analyses evaluated each conventional diagnostic test separately. In these comparative analyses, the summary diagnostic performance of ^{18}F -FDG PET was estimated in each of the studies that had also collected data on the performance of the specific compared method(s). Finally, a comparative analysis was performed that included only patients with cN0 stage for whom both PET and a conventional imaging technique had been performed.

Analyses were conducted in with WinBUGS software version 1.4 and Intercooled Stata version 8.2 (Stata Corp, College Station, TX).

Results

Eligible Studies

The electronic search yielded 704 articles; 603 were excluded upfront by reading the “Abstract” because they did not present any diagnostic information. We screened in full-text 101 articles and rejected 66; 35 studies (18–52) were eligible for meta-analysis (Table 1). Reasons for exclusion are listed in Figure 1. Of the 35 studies, data on patients (primary analysis) were available in 32, data on neck sides in 10, and data on lymph node levels in 14.

A total of 1901 patients were enrolled in the eligible studies, and of those, 1236 were analyzed for the diagnostic accuracy of ^{18}F -FDG PET to detect lymph node metastases on the patient level (Table 2). Seven studies (278 patients) enrolled only patients with cN0, three studies enrolled only patients with cN+, and the remaining studies enrolled mixed (both cN0 and cN+) patient populations. We were able to extract subgroup data (for cN0 and cN+) from three of the studies with mixed populations. Thus, 10 studies (311 patients) of cN0 patients and 19 studies (798 patients) with mixed patient populations were considered for analysis (Table 2). Among the latter subgroup, the percentage of cN0 patients was less than 50% in the majority of the studies providing such information (5 of 8 [62.5%]). Thirteen studies stated that they were prospective. The evaluation of ^{18}F -FDG PET results was stated to have been done in a blinded fashion in only five studies. Another five studies stated explicitly that evaluation was not blinded, whereas the others did not comment on this design aspect. In 19 studies, ^{18}F -FDG PET positivity was stated to have been assessed in a qualitative manner, whereas in 8 studies it was stated to have been assessed by quantitative methods using standardized uptake values (Table 1). Information about the technical characteristics of ^{18}F -FDG PET, inclusion and exclusion

Table 1. Characteristics of the studies included in the meta-analysis*

Author/y (reference)	No. of patients (No. analyzed)	Rationale for neck dissection†	Lymph node status, percentage N0	Design	Blinding	¹⁸ F-FDG PET positivity	No. of assessors	Other methods used
Pohar/2007 (18)	25 (25)	Standard treatment	0	Retro	No	QL	1	CT
Roh/2007 (19)	167 (104)	Standard treatment	40.4	Unclear	NR	QL	1	CT/MRI
Krabbe/2007 (20)	38 (38)	Standard treatment	100	Retro	NR	QL	1	CT, MRI, USFNA
Troost/2007 (21)	10 (10)	NR	70	Unclear	Yes	QN	2	CT, MRI, USFNA
Schoder/2006 (22)	31 (31)	Standard treatment	100	Prosp	No	QL	2	CT, MRI
Jeong/2006 (23)	56 (47)	Preoperative CT	42.5	Prosp	Yes	QN	2	CT, PET/CT
Hafidh/2006 (24)	48 (32)	Standard treatment	31.3	Prosp	NR	QN	1	CT, MRI
Wensing/2006 (25)	30 (28)	Standard treatment	100	Prosp	NR	QL	3	US/FNA
Ke/2006 (26)	20 (20)	Information could not be assessed	35	Unclear	Unclear	Unclear	Unclear	CT, PET/CT
Ng/2006 (27)	134 (134)	Standard treatment	100	Prosp	Yes	QL	3	CT/MRI
Schwartz/2005 (28)	63 (20)	Standard treatment	0	Prosp	No	QL	2	CT, PET/CT
Zanation/2005 (29)	102 (87)	Standard treatment	NR	Retro	NR	QL	NR	PET/CT
Jones/2005 (30)	112 (42)	Standard treatment	NR	Retro	NR	NR	NR	CT, MRI
Brouwer/2004 (31)	15 (15)	Standard treatment	100	Unclear	Yes	QL	1	CT, MRI, USFNA
Bruschini/2003 (32)	22 (22)	Standard treatment	Unclear	Unclear	NR	QN	NR	CT
Wax/2003 (33)	15 (15)	Standard treatment	0	Retro	NR	NR	NR	Only PET
Popper/2002 (34)	115 (56)	Unclear	Unclear	Retro	Unclear	QL	Unclear	CT/MRI
Hlawitschka/2002 (35)	38 (38)	Standard treatment	68.4	Prosp	NR	QN	NR	CT, MRI, US
Hannah/2002 (36)	48 (41)	Standard treatment	Unclear	Prosp	Yes	QL	2	CT
Hyde/2003 (37)	19 (18)	Standard treatment	100	Prosp	NR	NR	NR	CT, MRI
Kresnik/2001 (38)	54 (24)	Unclear	Unclear	Retro	No	QL	1	CT, MRI, US
Stokkel/2000 (39)	54 (54)	Standard treatment	Unclear	Prosp	NR	QL	NR	CT, US, USFNA
Stuckensen/2000 (40)	106 (106)	Standard treatment	Unclear	Prosp	NR	QN	NR	CT, MRI, US,
Nowak/1999 (41)	71 (62)	Standard treatment	Unclear	Retro	NR	QL	NR	CT/MRI
Kau/1999 (42)	70 (70)	Standard treatment	50	Prosp	Yes	QL	2	CT, MRI
Hanasono/1999 (43)	133 (8)	Standard treatment	Unclear	Retro	No	QL	1	CT, MRI
Adams/1998 (44)	60 (60)	Standard treatment	Unclear	Prosp	NR	QN	NR	CT, MRI, US
Paulus/1998 (45)	38 (25)	Standard treatment	Unclear	Retro	NR	QL	NR	CT
Myers/1998 (46)	14 (14)	Standard treatment	100	Unclear	NR	QL	1	CT
Wong/1997 (47)	54 (16)	Standard treatment	50	Prosp	NR	NR	NR	CT/MRI
Laubenbacher/1995 (48)	22 (17)	Standard treatment	11.8	Unclear	NR	QN	NR	MRI
Braams/1995 (49)	12 (12)	Standard treatment	50	Prosp	NR	QL	2	MRI
McGuirt/1995 (50)	45 (45)	Standard treatment	70	Prosp	NR	QL	NR	CT
Rege/1994 (51)	60 (19)	Standard treatment	42.1	Unclear	NR	QL	3	MRI
Moya/2000 (52)	30 (12)	Standard treatment	58.3	Unclear	NR	QL	NR	Only PET

* ¹⁸F-FDG PET=positron emission tomography using ¹⁸F-fluorodeoxyglucose; Retro = retrospective; QL = qualitative; CT = computed tomography; NR = not reported; MRI = magnetic resonance imaging; USFNA = ultrasound-guided fine-needle aspiration; QN = quantitative; Prosp = prospective.

† For N0 patients, “standard treatment” is assumed when the decision for neck dissection is based on the characteristics of the primary tumor (ie, location, tumor stage, histological differentiation), and it was the standard treatment protocol of the department.

criteria, and specific location of the primary tumors are reported in Supplementary Table 1 (available online).

Diagnostic Accuracy of ¹⁸F-FDG PET

When considering all 32 studies with data on lymph node metastases per patient (18–34,36–38,40,41,43–52), ¹⁸F-FDG PET sensitivity was 79% (95% confidence interval [CI] = 72% to 85%) on a patient basis (Table 2) and specificity was 86% (95% CI = 83% to 89%). However, in studies enrolling cN0 patients only, sensitivity was only 50% (95% CI = 37% to 63%); specificity remained high (87%, 95% CI = 76% to 93%). Studies clearly stating that ¹⁸F-FDG PET interpretation was done in a blinded fashion yielded lower results for sensitivity (72%, 95% CI = 51% to 87%); however, specificity estimates were again similar to the overall result (86%, 95% CI = 76%

to 92%) (Table 2). The design of the study and the type of assessment of ¹⁸F-FDG PET positivity did not statistically significantly influence the reported diagnostic accuracy of the test (Table 2).

Likelihood ratio syntheses gave an overall LR+ of 5.84 (95% CI = 4.59 to 7.42) and LR– of 0.24 (95% CI = 0.17 to 0.33). Results were similar when analyses were performed on the basis of neck side and lymph node level, but data were more limited (Supplementary Tables 2 and 3, available online). SROC curves show the overall very good, but not excellent, diagnostic performance for ¹⁸F-FDG PET for all studies combined (Figure 2) and the considerably worse performance in studies enrolling cN0 patients only (Figure 3).

Assuming a prevalence of node metastasis of 10%, 20%, 30%, 40%, 50%, 60%, 70%, and 80% in cN0 patients, NPVs were 0.94, 0.87, 0.80, 0.72, 0.64, 0.53, 0.43, and 0.30, respectively.

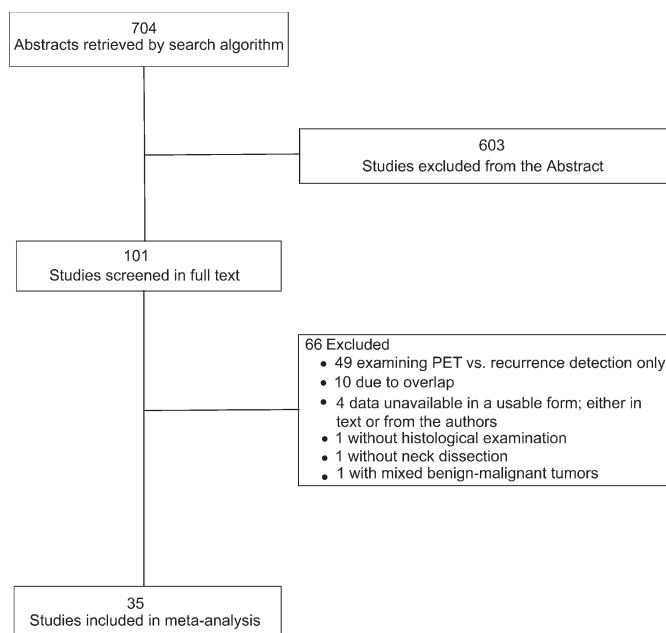


Figure 1. Flow chart of the search for eligible studies on the diagnostic accuracy of positron emission tomography with the radiolabeled glucose analogue ^{18}F -fluorodeoxyglucose for the detection of neck lymph node metastases.

The results were almost identical using different prior assumptions (data not shown). Moreover, there was no evidence of statistically significant lack of the fit of the hierarchical SROC model.

Comparison Against Conventional Diagnostic Methods

The comparison of ^{18}F -FDG PET performance with that of other diagnostic tools (CT, MRI, CT/MRI, and USFNA in 24 studies) suggested no major differences against any of these methods, although the point estimates suggested improvement for both sen-

sitivity and specificity by 5%–7% using ^{18}F -FDG PET over the conventional methods (Figure 4). ^{18}F -FDG PET had sensitivity of 80% (95% CI = 72% to 87%), specificity of 86% (95% CI = 82% to 90%), LR+ of 5.85 (95% CI = 7.83 to 34.39), and LR– of 0.23 (95% CI = 0.16% to 0.33%). The respective figures for the conventional methods were 75% (95% CI = 65% to 83%), 79% (95% CI = 72% to 85%), 3.56 (95% CI = 2.61 to 4.83), and 0.32 (95% CI = 0.23 to 0.50), respectively.

When the comparisons were to specific methods, ^{18}F -FDG PET again had higher sensitivity and specificity than CT (82% vs 74% and 86% vs 76%, respectively), but the confidence intervals still overlapped (Table 3). MRI had equally high sensitivity (78% vs 78%) and lower specificity (80% vs 85%) than ^{18}F -FDG PET, but again, the differences were not beyond chance. In addition, we observed no statistically significant differences when ^{18}F -FDG PET was compared with CT/MRI results or USFNA in the limited number of studies ($n = 4$ for each comparison) that addressed these comparisons (Supplementary Figure 1, available online).

Five studies (20,25,27,31,46) enrolled cN0 patients and performed both ^{18}F -FDG PET and a conventional diagnostic imaging method (CT, MRI, CT/MRI, and USFNA) on a total of 204 patients. ^{18}F -FDG PET had sensitivity of 52% (95% CI = 39% to 65%), specificity of 93% (95% CI = 87% to 96%), LR+ of 7.07 (95% CI = 3.79 to 13.20), and LR– of 0.52 (95% CI = 0.39 to 0.69). The respective figures for the conventional methods were 45% (95% CI = 25% to 67%), 87% (95% CI = 72% to 95%), 3.51 (95% CI = 1.82 to 6.74), and 0.63 (95% CI = 0.45 to 0.89), respectively. The data were too limited to compare according to type of conventional diagnostic test.

Discussion

This meta-analysis documents that ^{18}F -FDG PET is suboptimal in detecting metastatic lymph nodes in patients with HNSCC and

Table 2. Diagnostic accuracy of positron emission tomography using ^{18}F -fluorodeoxyglucose in detecting malignant lymph node metastases (per patient)*

Study characteristics	No. of studies (no. of patients)	Independent estimates (95% CI)		Likelihood ratio (95% CI)	
		Sensitivity	Specificity	LR+	LR–
All	32 (1236)	0.79 (0.72 to 0.85)	0.86 (0.83 to 0.89)	5.84 (4.59 to 7.42)	0.24 (0.17 to 0.33)
Clinical lymph node status					
N0	10 (311)	0.50 (0.37 to 0.63)	0.87 (0.76 to 0.93)	3.83 (1.90 to 7.75)	0.57 (0.43 to 0.77)
N+	6 (127)	0.94 (0.57 to 0.99)	0.70 (0.19 to 0.96)	3.16 (0.64 to 15.76)	0.08 (0.01 to 0.79)
Mixed	19 (798)	0.82 (0.75 to 0.87)	0.87 (0.83 to 0.90)	6.36 (4.83 to 8.37)	0.21 (0.15 to 0.29)
Design					
Prospective	13 (590)	0.76 (0.62 to 0.86)	0.83 (0.77 to 0.88)	4.60 (3.47 to 6.10)	0.29 (0.17 to 0.47)
Retrospective	10 (382)	0.77 (0.63 to 0.85)	0.89 (0.82 to 0.93)	6.77 (4.39 to 10.43)	0.27 (0.18 to 0.43)
Unclear	9 (264)	0.87 (0.77 to 0.93)	0.90 (0.82 to 0.94)	8.34 (4.70 to 14.79)	0.15 (0.08 to 0.27)
Blinding					
Yes	5 (278)	0.72 (0.51 to 0.87)	0.86 (0.76 to 0.92)	4.39 (2.32 to 8.30)	0.39 (0.21 to 0.66)
No	5 (108)	0.95 (0.54 to 0.99)	0.92 (0.63 to 0.99)	11.21 (1.98 to 63.49)	0.05 (0.003 to 0.82)
Unclear	22 (850)	0.78 (0.69 to 0.85)	0.86 (0.83 to 0.89)	5.77 (4.46 to 7.45)	0.25 (0.18 to 0.37)
Assessment of PET positivity					
Quantitative	8 (366)	0.82 (0.72 to 0.89)	0.81 (0.74 to 0.86)	4.30 (3.12 to 5.92)	0.23 (0.14 to 0.36)
Qualitative	19 (759)	0.80 (0.69 to 0.88)	0.88 (0.84 to 0.91)	6.81 (5.10 to 9.08)	0.23 (0.14 to 0.35)
Unclear	5 (111)	0.68 (0.29 to 0.92)	0.90 (0.75 to 0.97)	7.08 (2.20 to 22.80)	0.35 (0.11 to 1.12)

* CI = confidence interval; LR+ = positive likelihood ratio; LR– = negative likelihood ratio; PET = positron emission tomography.

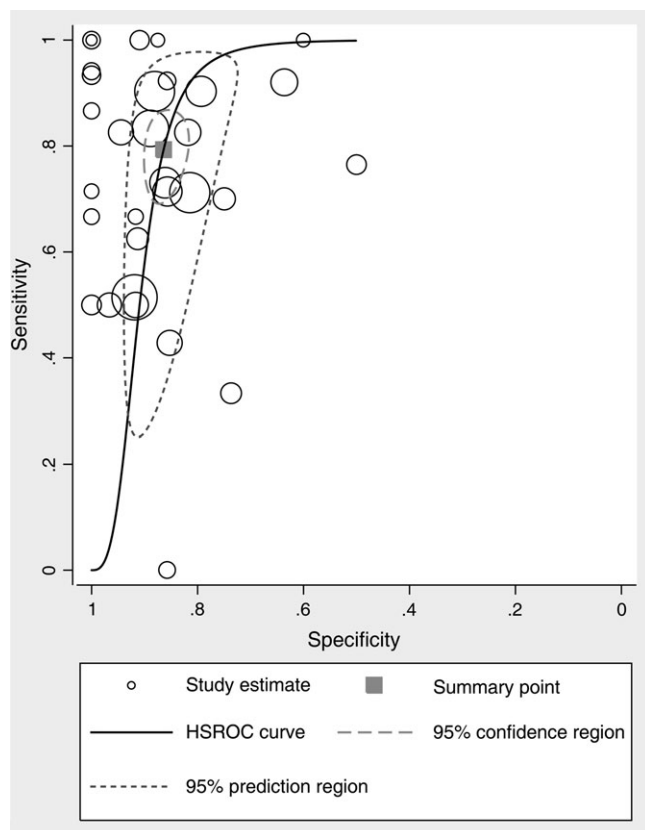


Figure 2. Hierarchical summary receiver operating characteristic (HSROC) curve for the diagnostic performance of positron emission tomography using the radiolabeled glucose analogue ^{18}F -fluorodeoxyglucose for all studies combined. The size of the **circles** indicates the weight of each study.

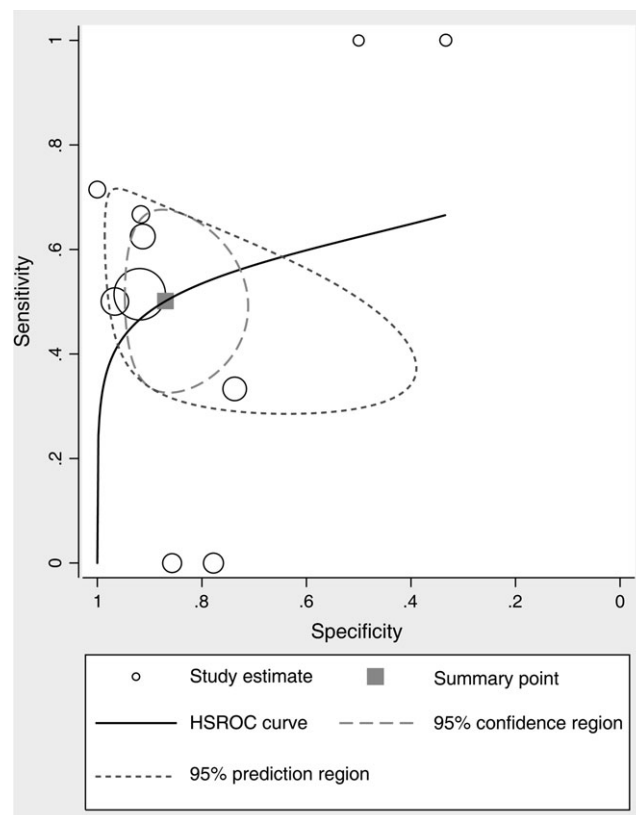


Figure 3. Hierarchical summary receiver operating characteristic (HSROC) curve for the diagnostic performance of positron emission tomography with radiolabeled glucose analogue ^{18}F -fluorodeoxyglucose for studies enrolling only patients with clinically negative neck. The size of the **circles** indicates the weight of each study.

clinically negative neck. Although its sensitivity reached 79% among all the examined patients (both cN0 and cN+), ^{18}F -FDG PET identified only half of the patients who had no palpable metastases in the neck but were metastasis positive by histopathologic examination. The specificity of ^{18}F -FDG PET in this setting was very good, in the range of 90%.

Treatment of patients with HNSCC and a cN+ neck is well established, and neck dissection is the surgical management of choice for these patients (3,53). Radiology and other diagnostic methods do not typically influence the decision to operate (5,6), although they may offer useful additional anatomical information and guide the surgical plan. ^{18}F -FDG PET (or any other diagnostic method) is not essential for the diagnosis of neck metastasis in a cN2 or cN3 patient.

Conversely, the treatment of patients with HNSCC and clinically negative neck remains controversial. The major question is whether to treat the neck or whether to adopt a wait-and-watch policy (1–4,54). Radiotherapy provides an alternative option for the treatment of N0 patients, but this approach does not provide information about the true nodal status because there is no specimen for histopathologic examination. Thus, the main dilemma is between elective neck dissection and the wait-and-watch policy. Some non-randomized data suggest increased survival rates in patients who receive elective neck dissection compared with those in the wait-and-watch group (55). However, the decision of whether to operate or not currently depends on the probability of occult neck

metastasis. Because of the high morbidity and the cost of the procedure, novel diagnostic methods are used to enhance the preoperative assessment of the cervical lymph node status to avoid unnecessary operations and to detect patients who would have the greatest benefit from an elective neck dissection. Based on the results of this meta-analysis, ^{18}F -FDG PET performance is not very satisfactory because half of the patients with cN0 who harbor metastases will have a negative test result. In addition, the 10% false-positive rate is similar to that reported for other widely used diagnostic methods, such as CT and MRI (5–11). Thus, there is little evidence to support the routine use of ^{18}F -FDG PET to evaluate possible lymph node metastasis among patients with HNSCC and a clinically negative neck. Some possible reasons for this failure of ^{18}F -FDG PET to detect metastases in these patients are reported by the individual studies (20) and include the close anatomic proximity of the lymph nodes to major salivary glands and other structures that are visualized with ^{18}F -FDG PET; the size of occult metastases, which might be below the spatial resolution of ^{18}F -FDG PET; and high glucose levels, which enhance the uptake of ^{18}F -FDG by the neck muscles and lower the contrast ratio in the area of interest. Furthermore, we should also note that the performance of the other diagnostic methods for cN0 patients was equally poor or even worse than that of ^{18}F -FDG PET.

We should acknowledge some limitations and caveats of this meta-analysis. First, the number of cN0 patients included in the

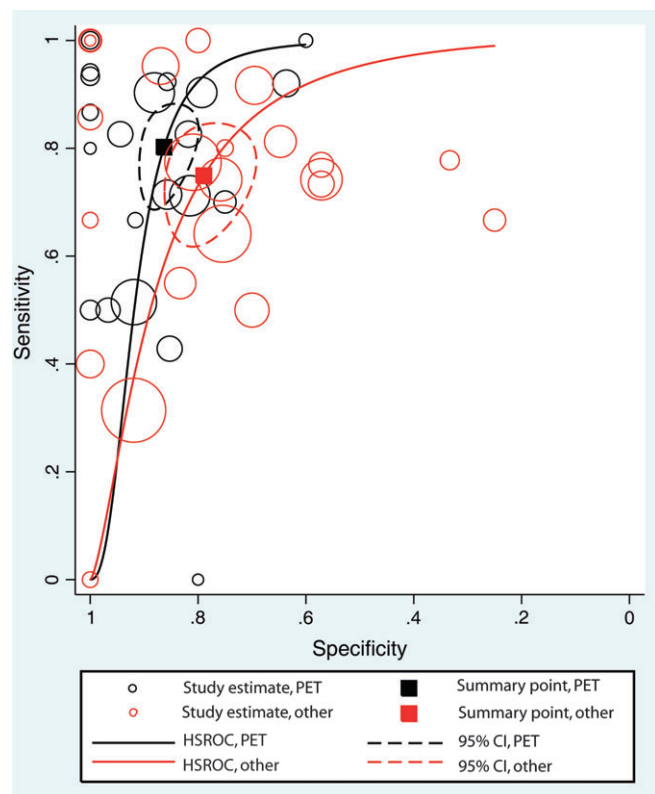


Figure 4. Hierarchical summary receiver operating characteristic (HSROC) curves for the diagnostic performance of positron emission tomography (PET) with radiolabeled glucose analogue ^{18}F -fluorodeoxyglucose compared with the other conventional diagnostic methods (computed tomography, magnetic resonance imaging, computed tomography/magnetic resonance imaging, and ultrasound with fine-needle aspiration). The size of the **circles** indicates the weight of each study. CI = confidence interval.

analysis was limited. The available data are consistent with a small improvement (in the range of 5%–10%) in sensitivity with ^{18}F -FDG PET over conventional imaging methods in these patients. However, the confidence intervals exclude a high sensitivity for ^{18}F -FDG PET in this patient group, so the potential incremental diagnostic benefit still leaves a large percentage of false negatives. Second, the rationale for the neck dissection was not clear in some of the studies; results of other diagnostic methods

might have influenced this decision, and these results may be correlated with the results of ^{18}F -FDG PET. However, this issue would not necessarily affect the estimated diagnostic performance of ^{18}F -FDG PET. Third, the interpretation of ^{18}F -FDG PET scans was performed qualitatively in the majority of the studies, and in the vast majority of these studies blinding was either unclear or absent. Thus, there is a risk of subjective interpretation, but it is more likely to be in favor of ^{18}F -FDG PET, and its diagnostic accuracy might be even lower. Fourth, selective reporting biases are well-known threats for many clinical research fields (56–61), including diagnostic tests (56). Again, the effect, if present, would be in favor of ^{18}F -FDG PET. Fifth, we did not perform analyses according to the location of the primary tumor because this would have required individual patient data. The location of the primary tumor might influence the probability for occult lymph node metastases (62) but is not likely to affect the diagnostic accuracy of a functional diagnostic tool such as ^{18}F -FDG PET. Finally, although the sensitivity of all tests in cN0 patients is low, it may increase if several tests are performed and a positive result is claimed when at least one test is positive. However, the one sizable study that has tried to correlate PET readings with CT/MRI results could improve sensitivity only from 50% to 57% (27), and three smaller studies (25,31,46) also suggest that only minor improvements in sensitivity may be anticipated with such combinations of tests.

In conclusion, we found no solid evidence to support the routine clinical application of ^{18}F -FDG PET in the pretreatment evaluation of the lymph node status in patients with HNSCC, including patients with clinically negative neck. Other imaging methods appear to have similarly limited or even worse diagnostic performance in these patients. Of course, imaging in patients with HNSCC may be performed for a variety of additional reasons besides staging (eg, baseline for future follow-up or identification of the association of the primary tumor with anatomical structures). Consideration of the cost (27) and potential complications against the yield of information can be made on a case-by-case basis. However, even with a prior probability of 20% of having node metastasis in a clinically negative neck, a negative test still does not decrease the probability of metastasis below 10%, based on the estimated NPV. Larger studies may better clarify whether there is indeed an incremental diagnostic improvement with this method over conventional imaging methods in cN0 HNSCC patients.

Table 3. Comparison of the diagnostic accuracy of positron emission tomography using ^{18}F -fluorodeoxyglucose with other diagnostic methods*

Diagnostic methods compared	No. of studies (references)	Independent estimates (95% CI)		Likelihood ratio (95% CI)	
		Sensitivity	Specificity	LR+	LR–
CT	16 (20,21,23,24,26,28,31,32,36,40,43–47,49,50)	0.74 (0.61 to 0.83)	0.76 (0.68 to 0.83)	3.12 (2.32 to 4.21)	0.35 (0.23 to 0.51)
^{18}F -FDG PET		0.82 (0.72 to 0.89)	0.86 (0.78 to 0.91)	5.64 (3.61 to 8.83)	0.22 (0.14 to 0.34)
MRI	9 (20,21,24,31,40,43,44,47,48,51)	0.78 (0.54 to 0.92)	0.80 (0.67 to 0.88)	3.86 (2.01 to 7.38)	0.27 (0.10 to 0.70)
^{18}F -FDG PET		0.78 (0.64 to 0.87)	0.85 (0.79 to 0.90)	5.07 (3.47 to 7.41)	0.27 (0.16 to 0.44)
CT + MRI	4 (19,27,34,47)	0.66 (0.44 to 0.82)	0.76 (0.53 to 0.90)	2.73 (1.43 to 5.19)	0.45 (0.28 to 0.72)
^{18}F -FDG PET		0.73 (0.58 to 0.84)	0.89 (0.84 to 0.93)	6.85 (4.50 to 10.42)	0.30 (0.18 to 0.49)
USFNA	4 (20,21,25,39)	0.42 (0.01 to 0.97)	0.96 (0.76 to 0.99)	10.87 (0.51 to 230.6)	0.61 (0.12 to 3.19)
^{18}F -FDG PET		0.45 (0.27 to 0.64)	0.88 (0.76 to 0.95)	3.79 (1.49 to 9.60)	0.63 (0.42 to 0.92)

* CI = confidence interval; LR+ = positive likelihood ratio; LR– = negative likelihood ratio; CT = computed tomography; ^{18}F -FDG PET = positron emission tomography using ^{18}F -fluorodeoxyglucose; MRI = magnetic resonance imaging; USFNA = ultrasound-guided fine-needle aspiration.

References

- Weiss MH, Harrison LB, Isaacs RS. Use of decision analysis in planning a management strategy for the stage N0 neck. *Arch Otolaryngol Head Neck Surg.* 1994;120(7):699–702.
- Snow GB, Patel P, Leemans CR, Tiwari R. Management of cervical lymph nodes in patients with head and neck cancer. *Eur Arch Otorhinolaryngol.* 1992;249(4):187–194.
- Ferlito A, Rinaldo A, Robbins KT, et al. Changing concepts in the surgical management of the cervical node metastasis. *Oral Oncol.* 2003;39(3):429–435.
- Byers RM, Wolf PF, Ballantyne AJ. Rationale for elective modified neck dissection. *Head Neck Surg.* 1988;10(3):160–167.
- Castelijns JA, van den Brekel MW. Imaging of lymphadenopathy in the neck. *Eur Radiol.* 2002;12(4):727–738.
- Castelijns JA, van den Brekel MW. Detection of lymph node metastases in the neck: radiologic criteria. *AJNR Am J Neuroradiol.* 2001;22(1):3–4.
- Hao SP, Ng SH. Magnetic resonance imaging versus clinical palpation in evaluating cervical metastasis from head and neck cancer. *Otolaryngol Head Neck Surg.* 2000;123(3):324–327.
- Stern WB, Silver CE, Zeifer BA, Persky MS, Heller KS. Computed tomography of the clinically negative neck. *Head Neck.* 1990;12(2):109–113.
- Feinmesser R, Freeman JL, Feinmesser M, Noyek A, Mullen JB. Role of modern imaging in decision-making for elective neck dissection. *Head Neck.* 1992;14(3):173–176.
- Som PM. Detection of metastasis in cervical lymph nodes: CT and MR criteria and differential diagnosis. *AJR Am J Roentgenol.* 1992;158(5):961–969.
- Curtin HD, Ishwaran H, Mancuso AA, Dalley RW, Caudry DJ, McNeil BJ. Comparison of CT and MR imaging in staging of neck metastases. *Radiology.* 1998;207(1):123–130.
- Ioannidis JP, Lau J. 18F-FDG PET for the diagnosis and grading of soft-tissue sarcoma: a meta-analysis. *J Nucl Med.* 2003;44(5):717–724.
- Pakos EE, Fotopoulos AD, Ioannidis JP. 18F-FDG PET for evaluation of bone marrow infiltration in staging of lymphoma: a meta-analysis. *J Nucl Med.* 2005;46(6):958–963.
- Lee JC, Kim JS, Lee JH, et al. F-18 FDG-PET as a routine surveillance tool for the detection of recurrent head and neck squamous cell carcinoma. *Oral Oncol.* 2007;43(7):686–692.
- Dietl B, Marienhagen J, Kuhnel T, Schreyer A, Kolbl O. The impact of FDG-PET/CT on the management of head and neck tumours: the radiotherapist's perspective [published online ahead of print September 6, 2007]. *Oral Oncol.* doi:10.1016/j.oraloncology.2007.06.014.
- Robbins KT, Clayman G, Levine PA, et al. American Head and Neck Society, American Academy of Otolaryngology—Head and Neck Surgery. Neck dissection classification update: revisions proposed by the American Head and Neck Society and the American Academy of Otolaryngology—Head and Neck Surgery. *Arch Otolaryngol Head Neck Surg.* 2002;128(7):751–758.
- Rutter CM, Gatsonis CA. A hierarchical regression approach to meta-analysis of diagnostic test accuracy evaluations. *Stat Med.* 2001;20(19):2865–2884.
- Pohar S, Brown R, Newman N, Koniarczyk M, Hsu J, Feiglin D. What does PET imaging add to conventional staging of head and neck cancer patients? [published online ahead of print March 26, 2007]. *Int J Radiat Oncol Biol Phys.* 2007;68(2):383–387. doi:10.1016/j.ijrobp.2006.12.044.
- Roh JL, Ryu CH, Kim JS, et al. Clinical significance of intrathoracic lesions detected by 18F-fluorodeoxyglucose positron emission tomography in the management of patients with head and neck cancer [published online ahead of print November 16, 2006]. *Oral Oncol.* 2007;43(8):757–763. doi:10.1016/j.oraloncology.2006.09.004.
- Krabbe CA, Dijkstra PU, Pruim J, et al. FDG PET in oral and oropharyngeal cancer. Value for confirmation of N0 neck and detection of occult metastases [published online ahead of print February 14, 2007]. *Oral Oncol.* 2008;44(1):31–36. doi:10.1016/j.oraloncology.2006.12.003.
- Troost EG, Vogel WV, Merckx MA, et al. 18F-FLT PET does not discriminate between reactive and metastatic lymph nodes in primary head and neck cancer patients. *J Nucl Med.* 2007;48(5):726–735.
- Schoder H, Carlson DL, Kraus DH, et al. 18F-FDG PET/CT for detecting nodal metastases in patients with oral cancer staged N0 by clinical examination and CT/MRI. *J Nucl Med.* 2006;47(5):755–762.
- Jeong HS, Baek CH, Son YI, et al. Use of integrated 18F-FDG PET/CT to improve the accuracy of initial cervical nodal evaluation in patients with head and neck squamous cell carcinoma. *Head Neck.* 2007;29(3):203–210.
- Hafidh MA, Lacy PD, Hughes JP, Duffy G, Timon CV. Evaluation of the impact of addition of PET to CT and MR scanning in the staging of patients with head and neck carcinomas [published online ahead of print May 25, 2006]. *Eur Arch Otorhinolaryngol.* 2006;263(9):853–859. doi:10.1016/j.amjoto.2006.03.004.
- Wensing BM, Vogel WV, Marres HA, et al. FDG-PET in the clinically negative neck in oral squamous cell carcinoma [erratum in *Laryngoscope.* 2006; 116(7 Pt 1):1302]. *Laryngoscope.* 2006;116(5):809–813.
- Ke Z, Liu M, Liu Y, He Z, Zhang Y, Zhang W. Diagnostic value of 18F-FDG PET/CT in the detection of the cervical lymph nodes metastasis [in Chinese]. *Lin Chuang Er Bi Yan Hou Ke Za Zhi.* 2006;20(6):243–245.
- Ng SH, Yen TC, Chang JT, et al. Prospective study of [18F]fluorodeoxyglucose positron emission tomography and computed tomography and magnetic resonance imaging in oral cavity squamous cell carcinoma with palpably negative neck. *J Clin Oncol.* 2006;24(27):4371–4376.
- Schwartz DL, Ford E, Rajendran J, et al. FDG-PET/CT imaging for preradiotherapy staging of head-and-neck squamous cell carcinoma. *Int J Radiat Oncol Biol Phys.* 2005;61(1):129–136.
- Zanation AM, Sutton DK, Couch ME, Weissler MC, Shockley WW, Shores CG. Use, accuracy, and implications for patient management of [18F]-2-fluorodeoxyglucose-positron emission/computerized tomography for head and neck tumors. *Laryngoscope.* 2005;115(7):1186–1190.
- Jones J, Farag I, Hain SF, McGurk M. Positron emission tomography (PET) in the management of oro-pharyngeal cancer. *Eur J Surg Oncol.* 2005;31(2):170–176.
- Brouwer J, de Bree R, Comans EF, Castelijns JA, Hoekstra OS, Leemans CR. Positron emission tomography using [18F]fluorodeoxyglucose (FDG-PET) in the clinically negative neck: is it likely to be superior? [published online ahead of print December 17, 2003]. *Eur Arch Otorhinolaryngol.* 2004;261(9):479–483. doi:10.1007/s00405-003-0727-3.
- Bruschini P, Giorgetti A, Bruschini L, et al. Positron emission tomography (PET) in the staging of head neck cancer: comparison between PET and CT. *Acta Otorhinolaryngol Ital.* 2003;23(6):446–453.
- Wax MK, Myers LL, Gona JM, Husain SS, Nabi HA. The role of positron emission tomography in the evaluation of the N-positive neck. *Otolaryngol Head Neck Surg.* 2003;129(3):163–167.
- Popperl G, Lang S, Dagdelen O, Jager L, Tiling R, Hahn K, Tatsch K. Correlation of FDG-PET and MRI/CT with histopathology in primary diagnosis, lymph node staging and diagnosis of recurrency of head and neck cancer [in German]. *Rofö.* 2002;174(6):714–720.
- Hlawitschka M, Neise E, Bredow J, et al. FDG-PET in the pretherapeutic evaluation of primary squamous cell carcinoma of the oral cavity and the involvement of cervical lymph nodes. *Mol Imaging Biol.* 2002;4(1):91–98.
- Hannah A, Scott AM, Tochon-Danguy H, et al. Evaluation of 18 F-fluorodeoxyglucose positron emission tomography and computed tomography with histopathologic correlation in the initial staging of head and neck cancer. *Ann Surg.* 2002;236(2):208–217.
- Hyde NC, Prvulovich E, Newman L, Waddington WA, Visvikis D, Ell P. A new approach to pre-treatment assessment of the N0 neck in oral squamous cell carcinoma: the role of sentinel node biopsy and positron emission tomography. *Oral Oncol.* 2003;39(4):350–360.
- Kresnik E, Mikosch P, Gallowitsch HJ, et al. Evaluation of head and neck cancer with 18F-FDG PET: a comparison with conventional methods. *Eur J Nucl Med.* 2001;28(7):816–821.
- Stokkel MP, ten Broek FW, Hordijk GJ, Koole R, van Rijk PP. Preoperative evaluation of patients with primary head and neck cancer using dual-head 18fluorodeoxyglucose positron emission tomography. *Ann Surg.* 2000;231(2):229–234.

40. Stuckensen T, Kovacs AF, Adams S, Baum RP. Staging of the neck in patients with oral cavity squamous cell carcinomas: a prospective comparison of PET, ultrasound, CT and MRI. *J Craniomaxillofac Surg*. 2000; 28(6):319–324.
41. Nowak B, Di Martino E, Janicke S, et al. Diagnostic evaluation of malignant head and neck cancer by F-18-FDG PET compared to CT/MRI. *Nuklearmedizin*. 1999;38(8):312–318.
42. Kau RJ, Alexiou C, Laubenbacher C, Werner M, Schwaiger M, Arnold W. Lymph node detection of head and neck squamous cell carcinomas by positron emission tomography with fluorodeoxyglucose F 18 in a routine clinical setting. *Arch Otolaryngol Head Neck Surg*. 1999;125(12):1322–1328.
43. Hanasono MM, Kunda LD, Segall GM, Ku GH, Terris DJ. Uses and limitations of FDG positron emission tomography in patients with head and neck cancer. *Laryngoscope*. 1999;109(6):880–885.
44. Adams S, Baum RP, Stuckensen T, Bitter K, Hor G. Prospective comparison of 18F-FDG PET with conventional imaging modalities (CT, MRI, US) in lymph node staging of head and neck cancer. *Eur J Nucl Med*. 1998;25(9):1255–1260.
45. Paulus P, Sambon A, Vivegnis D, et al. 18FDG-PET for the assessment of primary head and neck tumors: clinical, computed tomography, and histopathological correlation in 38 patients. *Laryngoscope*. 1998; 108(10):1578–1583.
46. Myers LL, Wax MK, Nabi H, Simpson GT, Lamonica D. Positron emission tomography in the evaluation of the N0 neck. *Laryngoscope*. 1998; 108(2):232–236.
47. Wong WL, Chevreton EB, McGurk M, et al. A prospective study of PET-FDG imaging for the assessment of head and neck squamous cell carcinoma. *Clin Otolaryngol Allied Sci*. 1997;22(3):209–214.
48. Laubenbacher C, Saumweber D, Wagner-Manslau C, et al. Comparison of fluorine-18-fluorodeoxyglucose PET, MRI and endoscopy for staging head and neck squamous-cell carcinomas. *J Nucl Med*. 1995;36(10):1747–1757.
49. Braams JW, Pruim J, Freling NJ, et al. Detection of lymph node metastases of squamous-cell cancer of the head and neck with FDG-PET and MRI. *J Nucl Med*. 1995;36(2):211–216.
50. McGuirt WF, Williams DW III, Keyes JW Jr, et al. A comparative diagnostic study of head and neck nodal metastases using positron emission tomography. *Laryngoscope*. 1995;105(4 Pt1):373–375.
51. Rege S, Maass A, Chaiken L, et al. Use of positron emission tomography with fluorodeoxyglucose in patients with extracranial head and neck cancers. *Cancer*. 1994;73(12):3047–3058.
52. Moya F, Gomez F, De Pedro M, et al. Utility of metabolic imaging in oral squamous cell carcinoma (SCC) staging. Experience in 30 Patients. *Clin Positron Imaging*. 2000;3(4):171.
53. Ferlito A, Rinaldo A, Silver CE, et al. Elective and therapeutic selective neck dissection [published online ahead of print June 23, 2005]. *Oral Oncol*. 2006;42(1):14–25. doi:10.1016/j.oraloncology.2005.03.009.
54. Wei WI, Ferlito A, Rinaldo A, et al. Management of the N0 neck—reference or preference [published online ahead of print June 24, 2005]. *Oral Oncol*. 2006;42(2):115–122. doi:10.1016/j.oraloncology.2005.04.006.
55. Haddadin KJ, Soutar DS, Oliver RJ, Webster MH, Robertson AG, MacDonald DG. Improved survival for patients with clinically T1/T2, N0 tongue tumors undergoing a prophylactic neck dissection. *Head Neck*. 1999;21(6):517–525.
56. Rutjes AW, Reitsma JB, Di Nisio M, Smidt N, van Rijn JC, Bossuyt PM. Evidence of bias and variation in diagnostic accuracy studies. *CMAJ*. 2006;174(4):469–476.
57. Kyzas PA, Loizou KT, Ioannidis JP. Selective reporting biases in cancer prognostic factor studies. *J Natl Cancer Inst*. 2005;97(14):1043–1055.
58. Kyzas PA, Denaxa-Kyza D, Ioannidis JP. Quality of reporting of cancer prognostic marker studies: association with reported prognostic effect. *J Natl Cancer Inst*. 2007;99(3):236–243.
59. Kavvoura FK, Liberopoulos G, Ioannidis JP. Selection in reported epidemiological risks: an empirical assessment. *PLoS Med*. 2007;4(3):e79.
60. Ioannidis JP. Why most published research findings are false [published online ahead of print August 30, 2005]. *PLoS Med*. 2005;2(8):e124. doi:10.1371/journal.pmed.0020124.
61. Kyzas PA, Denaxa-Kyza D, Ioannidis JP. Almost all articles on cancer prognostic markers report statistically significant results [published online ahead of print November 5, 2007]. *Eur J Cancer*. 2007;43(17):2559–2579. doi:10.1016/j.ejca.2007.08.030.
62. Pimenta Amaral TM, Da Silva Freire AR, Carvalho AL, Pinto CA, Kowalski LP. Predictive factors of occult metastasis and prognosis of clinical stages I and II squamous cell carcinoma of the tongue and floor of the mouth. *Oral Oncol*. 2004;40(8):780–786.

Notes

We are grateful to Dr C. Krabbe (Department of Maxillofacial Surgery, University Medical Center Groningen, Groningen, The Netherlands), Dr B. Nowak (Department of Nuclear Medicine, University of Technology, Aachen, Germany), Dr M. Schmidt (Klinik und Poliklinik für Nuklearmedizin, Klinikum der Universität zu Köln, Germany), Dr M. Wax (Department of Otolaryngology–Head and Neck Surgery, Oregon Health Sciences University, Portland, OR), Dr A. Sun (Section of Oncology, Department of Radiation Sciences, Umeå University Hospital, Umeå, Sweden), Dr A. Maldonado (Chief Physician, Grupo Recoletas, Madrid, Spain), Dr R. Bree (Department of Otolaryngology and Head and Neck Surgery, VU University Medical Center, Amsterdam, The Netherlands), Dr A. Zanation (Department of Otolaryngology—Head and Neck Surgery, University of North Carolina Hospitals, NC), Dr M. Stokkel (Department of Nuclear Medicine, University Hospital Utrecht, Utrecht, The Netherlands), Dr A. Kovacs (Department of Maxillofacial Plastic Surgery, University Medical School, Frankfurt am Main, Germany), Dr M. Hanasono (Department of Plastic Surgery University of Texas M. D. Anderson Cancer Center, Houston, TX), Dr H. Jeong (Otorhinolaryngology-Head & Neck Surgery, Samsung Medical Center, University School of Medicine, Seoul, Korea), Dr H. Schoder (Department of Radiology, Memorial Sloan-Kettering Cancer Center, New York, NY), Dr B. Wensing (Department of Otorhinolaryngology and Head & Neck Surgery, Radboud University Nijmegen Medical Centre, Nijmegen, The Netherlands), Dr N. Avril (Departments of Nuclear Medicine and Otorhinolaryngology, Technical University of Munich, Munich, Germany), Dr E. Troost (Department for Radiation Oncology, Radboud University Nijmegen Medical Centre, Nijmegen, The Netherlands), Dr S. Ng (Department of Diagnostic Radiology, Chang Gung Memorial Hospital, Taiwan), Dr Schwartz (Department of Radiation Oncology and Department of Experimental Diagnostic Imaging University of Texas M. D. Anderson Cancer Center, Houston, TX) for providing us additional data or useful information about their studies, upon request.

The sponsors had no role in the study design, the data collection or analysis, the interpretation of the results, the preparation of the manuscript, or the decision to submit the manuscript for publication.

Manuscript received November 27, 2007; revised February 21, 2008; accepted March 20, 2008.