

CASE REPORT

Delayed leg paraplegia associated with hyperextension injury in patients with diffuse idiopathic skeletal hyperostosis (DISH): case report and review of the literature

Tatsuya Yamamoto*, Yoshiomi Kobayashi, Yoji Ogura, Yohei Takahashi, Yoshio Shinozaki, and Jun Ogawa

Spine center, Japanese Red-cross Shizuoka Hospital, Shizuoka, Japan

*Correspondence address. Spine center, Japanese Red-cross Shizuoka Hospital, 8-2, Outemachi, Aoi-ku Shizuoka-shi, Shizuoka 420-0853, Japan.
Tel: +81-54-254-4311; E-mail: tacchan.0517@gmail.com

Abstract

Diffuse idiopathic skeletal hyperostosis (DISH) is characterized by calcifications and ossification of ligaments and tendon insertions. The patients with DISH are susceptible to spinal column injury with trivial trauma due to immobilization of vertebrae and this easily leads to spinal cord injury. However, only few reports on hyperextension injuries of the thoracolumbar spine with DISH exist. Here we report three cases of those who developed delayed leg paraplegia after hyperextension injuries of the thoracolumbar spine with DISH. All cases complained only lower back pain without neurological deficits and plain radiographs showed no fractures at an initial assessment. The spinal fracture caused by hyperextension injury was diagnosed with computed tomography (CT) and magnetic resonance image (MRI) after delayed leg paraplegia occurred. Many of the fractures caused by hyperextension injuries are not detected only with plain radiographs in patients with DISH. Further investigations using CT and/or MRI should be recommended.

INTRODUCTION

Diffuse idiopathic skeletal hyperostosis (DISH) is non-inflammatory systemic disease which leads to ossification of ligaments and entheses [1]. Especially ossification of longitudinal ligaments causes the ankylosing spine. According to Utsinger, DISH is diagnosed when radiographs present the ossification of at least four contiguous vertebral bodies [2]. Spinal fractures and following spinal cord injuries are easily caused by low-energy trauma in patients with DISH because

of immobilized spinal column [3, 4]. The pathogenesis is unknown and the prevalence of spinal DISH varies depending on region and ethnic differences; however, recently an age-related increase in prevalence is undisputed. The type of fracture has a great impact on the prognosis. Several studies suggested that delayed neurological deterioration tends to occur in the fracture caused by hyperextension injury [3]. Here we report three cases of those who developed delayed leg paraplegia after hyperextension injuries of the thoracolumbar spine with DISH.

Received: December 2, 2016. Accepted: February 20, 2017

Published by Oxford University Press and JSCR Publishing Ltd. All rights reserved. © The Author 2017.

This is an Open Access article distributed under the terms of the Creative Commons Attribution Non-Commercial License (<http://creativecommons.org/licenses/by-nc/4.0/>), which permits non-commercial re-use, distribution, and reproduction in any medium, provided the original work is properly cited. For commercial re-use, please contact journals.permissions@oup.com

CASE DESCRIPTION

Case 1

A 68-year-old male presented with back pain and no neurological deficits after the traffic accident. Plain radiographs showed ankylosing spine at T1 to L2 level; however, no fractures were identified at the first time visit to the hospital (Fig. 1a). The next day, he developed incomplete leg paraplegia of Frankel Grade C [5]. Although the plain radiographs at admission showed no major change (Fig. 1b), computed tomography (CT) scan revealed the hyperextension fracture at T12 (Fig. 1c). Magnetic resonance image (MRI) also showed hyperextension fracture and epidural hematoma compressing spinal cord (Fig. 1d). We performed posterior spinal fixation with decompression at T9 to L2 level. Neurological deficit improved after surgery (Table 1).

Case 2

A 77-year-old female presented with lower back pain and no neurological deficit after falling down. Plain radiographs showed no fractures (Fig. 2a). About 11 days after the injury, severe lower back pain and incomplete leg paraplegia of Frankel Grade B appeared. Plain radiographs at admission showed L1 fracture (Fig. 2b). CT scan revealed ankylosing spine at T1 to L2 and the hyperextension fracture at L1 (Fig. 2c). MRI showed severely compressed spinal cord by dislocation of the fracture (Fig. 2d). We performed posterior spinal fixation with decompression at T10 to L3 level. Neurological deficit improved after surgery (Table 1).

Case 3

A 79-year-old female presented with lower back pain after falling down. Plain radiographs showed multiple compression fractures in thoracolumbar spine (Fig. 3a). Because she had no neurological deficit, conservative treatment was selected. About 14 days after the injury, she developed complete leg paraplegia of Frankel Grade A and she was admitted to our

hospital. Second plain radiographs showed no major change, but CT revealed ankylosing spine at T5 to L2 and the hyperextension fracture at L1 (Fig. 3b and c). MRI showed severely compressed spinal cord by dislocation of the fracture (Fig. 3d). We performed posterior spinal fixation with decompression at T10 to L3 level. Neurological deficit improved (Table 1).

DISCUSSION

DISH and ankylosing spondylitis are known as ankylosing spinal disorders, which lead to ankylosis of spinal column. The prevalence of DISH is different between races ranging from 2.9% to 25% [6, 7], and its etiology is unclear. However, several studies showed association with advancing age, obesity and Type 2 diabetes mellitus [3].

DISH patients are susceptible to spinal fracture with trivial trauma due to immobilization of vertebrae. Low-energy trauma caused 32.5–69.1% of fractures [3, 4]. The previous studies reported that most fractures are localized in cervical spine, uncommon at thoracolumbar junction [3, 4, 8]. Hyperextension fracture is the most frequent type of fractures with DISH patients (51.2%) and induces the anterior distraction of vertebral bodies [9]. The fracture spreads transversely resulting in posterior element injuries. Upper and lower fused vertebral bodies make the stress concentration on fracture level, so spinal cord injury due to dislocation of fracture or epidural hematoma is easy to occur after an interval from first injury. Therefore secondary deterioration of neurological status is observed [3, 4, 8]. However, it is difficult to diagnose the hyperextension fracture at the initial assessment only with plain radiograph. Patients with unrecognized fractures commonly complain of only lower back pain until abrupt neurological deterioration occurs. Once after the neurological deficits occur, surgical treatment does not have the great influence to the clinical outcome. Therefore, the definitive treatment should be performed before the second neurological deterioration appears.

The series is summarized in Table 1. We analyzed the mechanism of injury, fracture level, direct cause of leg paraplegia, the duration from onset to paralysis, surgical procedure,

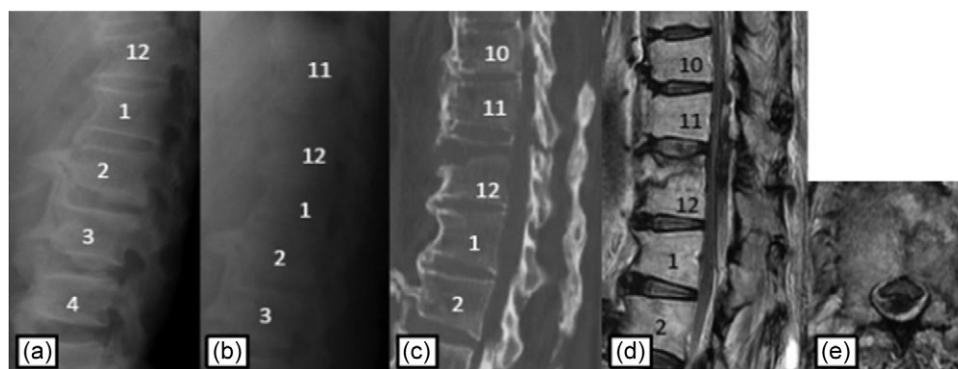


Figure 1: Plain radiographs on initial assessment (a) and on admission (b); Sagittal CT image (c) showing the hyperextension fracture at T12; MRI T2-weighted image (d, e) showing the epidural hematoma compressing the dura matter.

Table 1: Summary of three cases

| Case | Mechanism of injury | Injury level | Cause of paraplegia | Duration from injury to paraplegia | Frankel grade alteration |
|------|---------------------|--------------|---------------------|------------------------------------|--------------------------|
| 1 | High energy | T12 | Epidural hematoma | <24 h | C to D |
| 2 | Low energy | L1 | Dislocation | 10 days | B to C |
| 3 | Low energy | L1 | Dislocation | 14 days | A to B |

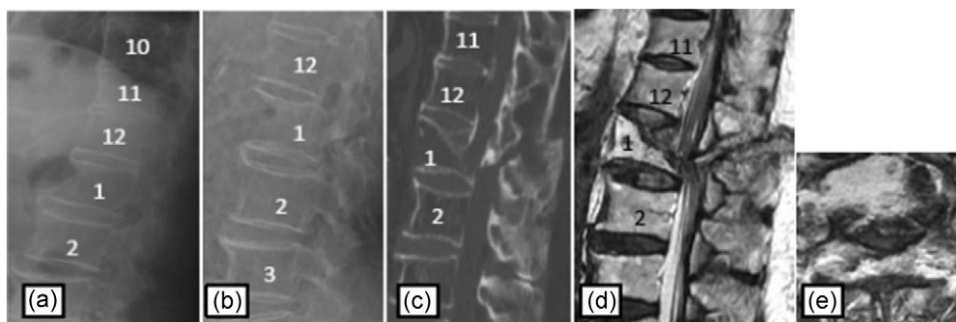


Figure 2: Plain radiographs on initial assessment (a) and on admission (b); Sagittal CT image (c) showing the hyperextension fracture at L1 and dislocation of it; MRI T2-weighted image (d, e) showing the severely compressed spinal cord at L1 level.

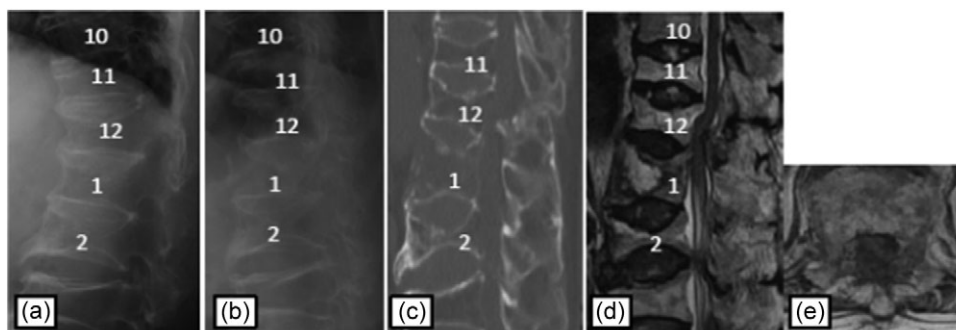


Figure 3: Plain radiographs on initial assessment (a) and on admission (b); Sagittal CT image (c) showing the hyperextension fracture at L1 and dislocation of it; MRI T2-weighted image (d, e) showing the severely compressed spinal cord at T12 level.

and neurological deficits before and after treatment. The mechanism of injury was high-energy trauma in Case 1, and low-energy trauma in Case 2 and Case 3. Fracture level was at thoracolumbar junction in all cases.

The most common cause of spinal cord injury is direct compression by fracture dislocation. Only a few reports mentioned the epidural hematoma causing spinal cord injury [10]. To the best of our knowledge, the timing of second neurological deterioration has not previously been reported. The cause of leg paraplegia was epidural hematoma within 24 h in Case 1, and dislocation of fracture over 1 week in Case 2 and Case 3. The epidural hematoma may be associated with the timing of the spinal cord injury.

A delay in diagnosis often occurs in hyperextension fractures with DISH [3, 4] because it is difficult to diagnose the fractures in plain radiographs due to ankylosing spine. The absence of major trauma may also mislead the diagnosis, this leads to second neurological deterioration.

All cases were treated conservatively at an initial treatment, because the hyperextension injuries in DISH were not recognized only with plain photographs. Further investigation using CT and/or MRI was needed for diagnosis. All patients improved by only one Frankel grade. We can find only a few reports that neurological deficits improved by more than two Frankel grade after surgical treatment [8], again, the definitive treatment should be performed before the second neurological deterioration appears.

CONCLUSION

We here reported three cases of the thoracolumbar hyperextension injuries in patients with DISH, those who developed

delayed leg paraplegia. The spinal fracture with DISH is difficult to diagnose only with plain radiograph, therefore screening of spinal column with CT and/or MRI should be recommended even if the fractures are not detected.

CONFLICT OF INTEREST STATEMENT

None declared.

REFERENCES

1. Forestier J, Rotes-Querol J. Senile ankylosing hyperostosis of the spine. *Ann Rheum Dis* 1950;9:321–30.
2. Utsinger PD. Diffuse idiopathic skeletal hyperostosis. *Clin Rheum Dis* 1985;11:325–51.
3. Westerveld LA, Verlaan JJ, Oner FC. Spinal fractures in patients with ankylosing spinal disorders: a systematic review of the literature on treatment, neurological status and complications. *Eur Spine J* 2009;18:145–56.
4. Westerveld LA, van Bommel JC, Dhert WJ, Oner FC, Verlaan JJ. Clinical outcome after traumatic spinal fractures in patients with ankylosing spinal disorders compared with control patients. *Spine J* 2014;14:729–40.
5. Frankel HL, Hancock DO, Hyslop G, Melzak J, Michaelis LS, Ungar GH, et al. The value of postural reduction in the initial management of closed injuries of the spine with paraplegia and tetraplegia. I. *Paraplegia* 1969;7:179–92.
6. Kim SK, Choi BR, Kim CG, Chung SH, Choe JY, Joo KB, et al. The prevalence of diffuse idiopathic skeletal hyperostosis in Korea. *J Rheumatol* 2004;31:2032–5.
7. Weinfeld RM, Olson PN, Maki DD, Griffiths HJ. The prevalence of diffuse idiopathic skeletal hyperostosis (DISH) in

- two large American Midwest metropolitan hospital populations. *Skeletal Radiol* 1997;**26**:222–5.
8. Balling H, Weckbach A. Hyperextension injuries of the thoracolumbar spine in diffuse idiopathic skeletal hyperostosis. *Spine (Phila Pa 1976)* 2015;**40**:E61–7.
 9. Le Hir PX, Sautet A, Le Gars L, Zeitoun F, Tubiana JM, Arrive L, et al. Hyperextension vertebral body fractures in diffuse idiopathic skeletal hyperostosis: a cause of intravertebral fluidlike collections on MR imaging. *AJR Am J Roentgenol* 1999; **173**:1679–83.
 10. Tauchi R, Imagama S, Satake K, Iwase T, Ishiguro N. Epidural hematoma associated with spinal fracture in diffuse idiopathic skeletal hyperostosis. *Turk Neurosurg* 2014; **24**:98–101.