

Original Article

Obituary to analgesic nephropathy—an autopsy study

Michael J. Mihatsch, Bettina Khanlari and Felix P. Brunner

Institute of Pathology and Division of Nephrology, Department of Medicine, University Hospital, Basle, Switzerland

Abstract

Background. To determine whether classic analgesic nephropathy with renal papillary and urothelial capillary sclerosis could still be detected at autopsy in the beginning of the 21st century, the present study which is similar to a previous one performed in 1980 was undertaken as suggested by the Ad Hoc Committee of the International Study Group on Analgesics and Nephropathy.

Methods. Consecutive autopsies of 616 adults performed at the Basle Institute of Pathology between November 2000 and February 2002 were analysed. Tissue samples of renal cortex and papilla of 1220 kidneys and of each ureter and main renal artery available were subjected to a very careful and meticulous study using classical histopathological methodology.

Results. A number of lesions was found macroscopically but not a single case of papillary necrosis or analgesic nephropathy could be detected preceding histological analysis. Histologically, the most frequent lesions were vascular in 57.8% of kidneys followed by glomerular lesions in 13.1% (mostly diabetic glomerulosclerosis). Tubulo-interstitial lesions, mostly pyelonephritis were detected in 9.3% with only a single case of classic analgesic nephropathy with bilateral complete papillary necrosis and ureteral capillary sclerosis in a female who had received a renal transplant 14 years before her demise at the age of 67. In another five cases, complete papillary necrosis was detected associated with pyelonephritis, hydronephrosis or in completely shrunken kidneys. However, in the absence of capillary sclerosis, a histopathological diagnosis of classic analgesic nephropathy could not be made in any of these five cases.

Conclusions. The Basle autopsy prevalence of analgesic nephropathy decreased continuously from some 3% in 1980 to 0.2% in 2000 as shown by the present study. Similarly, capillary sclerosis of the urinary tract, the initiating event in the pathophysiology of papillary necrosis and analgesic nephropathy and the

histological hallmark of the effect of toxic metabolites of phenacetin in analgesic abusers decreased from 4% of autopsy cases between 1978 and 1980 to the single case of the present study observed at the end of 2000. Thus, the classic analgesic nephropathy has disappeared some 20 years after the removal of phenacetin from the analgesic market despite the fact that mixed analgesics containing paracetamol, the main metabolite of phenacetin, have continued to be popular and widely used drugs.

Keywords: analgesic nephropathy; autopsy study; papillary necrosis; phenacetin abuse; prevalence of analgesic nephropathy

Introduction

The history of analgesic nephropathy is closely intertwined with that of papillary necrosis and the discovery and use of analgesics. The simple analgesics—salicylic acid, pyrazolones, phenacetin, paracetamol—were discovered toward the end of the 19th century and were soon introduced into clinical medicine [1]. Since the beginning of the 20th century, it has been known that overdosage of these drugs can result in disorders of renal function. As long as the analgesics concerned were taken as single drugs, they caused acute complications but no long-term side effects. In the 1940s and early 1950s, after the addition of caffeine and the introduction of combined preparations intended to optimize their effectiveness and minimize side effects [2], the consumption of analgesics became widespread and also addictive [3].

In 1950, 1953 and 1955, Spühler and Zollinger [4–8] described unusual forms of chronic interstitial nephritis which they first associated with the use of sulfonamides and later correctly with excessive intake of phenacetin-containing analgesics. Its pathogenetic history is best illustrated by the study of Gloor [9–11] in Basle. In the period from 1938 to 1942, only 2.7% of all patients with autopsy evidence of chronic interstitial nephritis had papillary necrosis, whereas in the period from 1958–1962 the corresponding figure was 57%. A number of

Correspondence and offprint requests to: M. J. Mihatsch, Institut für Pathologie, Schönbeinstrasse 40, CH – 4056 Basle, Switzerland.
Email: mjmhatsch@uhbs.ch

investigations contributed to the elucidation of the pathological entity we have come to know as analgesic nephropathy. Spühler and Zollinger [7] mistakenly assumed the condition to be primarily a form of chronic interstitial nephritis. Gloor and Burry *et al.* [9–12] were the first to regard papillary necrosis as the primary lesion. Sanerkin and Kincaid-Smith [13,14] interpreted the interstitial nephritis as a consequence and not as a cause of the papillary necrosis. Not until the 1970s was capillary sclerosis recognized by Munck *et al.*, Abrahams *et al.* and Torhorst [15–17] as an additional pathological feature of the condition. A number of Scandinavian pathologists and clinicians further contributed to the elucidation of the disease [18–25]. Finally, Mihatsch *et al.* [26,27] proved that capillary sclerosis is the cause of papillary necrosis and a pathognomonic lesion in analgesic nephropathy due to the abuse of phenacetin-containing mixed analgesics.

It was not until 1984 that analgesic nephropathy was recognized universally as an analgesic-associated disease [28]. Hultengren *et al.* [29] reported the occurrence of urinary tract tumours in analgesic abusers 12 years after the first description of analgesic nephropathy. Nanra *et al.* [30] integrated the broad range of adverse effects under the term analgesic syndrome consisting of analgesic nephropathy, urinary tract tumours and other disturbances.

At the time of our last review, classic analgesic nephropathy was defined as a bilateral chronic renal disease characterized by papillary necrosis, chronic interstitial nephritis, renal cortical atrophy, capillary sclerosis and sometimes a brownish discoloration of the renal papillae and the mucosa of the urinary tract [31]. At that time the authors believed that analgesic nephropathy was due to mixed analgesics containing (i) phenacetin or paracetamol; (ii) salicylates or other components (phenazone, pyrazole) and (iii) caffeine, codein or barbiturates. This chronic nephropathy has to be distinguished from other renal disorders caused by modern analgesics including non-steroidal anti-inflammatory drugs (NSAIDs).

By 1980, analgesic nephropathy as a cause of end-stage renal disease reached peak proportions of around 20% of all the patients starting renal replacement therapy in Belgium and in Australia, while its incidence had already declined in Denmark and quite dramatically in Sweden where legislation to remove phenacetin from the analgesic market had been introduced in the early 1960s [32,33]. In Switzerland, in 1980, over 25% of the patients starting renal replacement therapy suffered from analgesic nephropathy [32,33]. At the same time, based on the finding of capillary sclerosis in the ureter the prevalence of prior abuse of phenacetin containing analgesics in the Basle autopsy population was estimated to be about 4% overall and twice as high in women as in men [34–36]. At last in 1981, because of the high prevalence of analgesic nephropathy and urothelial cancer in patients with analgesic abuse, phenacetin was banned from mixed analgesics to disappear completely from Swiss

pharmacies and drugstores by the end of 1983. At that time one of the authors (M.J.M.) found the legal measures insufficient because in contrast to the other author (F.P.B.) he favoured the hypothesis that paracetamol, the major metabolite of phenacetin, taken in combination with salicylates might have been the main culprit in the pathogenesis of analgesic nephropathy.

Despite the unrestricted sale of mixed analgesics containing paracetamol, salicylates and caffeine, a steady decrease in the prevalence of analgesic nephropathy had occurred in Sweden and other countries [33] and had also been noticed at autopsy in Basle. Urothelial tumours of the renal pelvis or the ureter decreased as well. However, Elseviers and De Broe [37] in Belgium reported a persistently high prevalence of analgesic nephropathy in patients on renal replacement therapy, which they attributed to the use of mixed analgesics no longer containing phenacetin.

The controversy regarding the nephrotoxic potential of these newer mixed analgesic preparations was the reason for setting up the 'Ad Hoc Committee of the International Study Group on Analgesics and Nephropathy' and the authors of the present report were asked to perform an autopsy study similar to the one in 1980 [36] to answer the following questions [38]:

- (a) Is the classical picture of analgesic nephropathy as defined above still a frequent finding at autopsy?
- (b) Is capillary sclerosis as pathognomonic marker of phenacetin containing analgesics still detected at autopsy?

Patient population and methods

Consecutive autopsies of 616 adults (older than 20 years) performed between November 2000 and February 2002 were evaluated systematically. The following variables were recorded: age, sex, body height and weight, body mass index and serum creatinine in $\mu\text{mol/l}$ (representative baseline value within the last week before death). The following kidney parameters were systematically determined: kidney weight (after removing the renal capsule), semiquantitative determination of superficial renal scars (in percent of renal surface) after coronary sectioning of the kidneys, presence or absence of papillary necroses.

In general, for the histological study, two tissue blocks encompassing cortex and papilla were obtained from each kidney and in addition tissue blocks from the most severely affected kidney areas. Three tissue samples were taken from each ureter (proximal, middle and distal part) and a longitudinal section of each main renal artery. The tissue sections were embedded in paraffin and 3 μm thick sections were stained: kidney sections with HE, PAS, AFOG (trichrome) and Elastica van Gieson; ureter with PAS; renal artery with HE and Elastica van Gieson.

All sections were evaluated by B.K. and in the case of pathological or uncertain findings, also by M.J.M. All diagnoses were recorded separately for the right and the left kidney.

Table 1. Patient population ($n=616$) and kidney parameters ($n=1220$)

	Mean	SD	Med	Range
Age (yr)				
Male	73.0	13.1	75	22–98
Female	77.8	12.5	80	20–103
BMI (kg/m^2)				
Male	24.2	5.3	23.9	11–42
Female	23.4	6.4	22.3	10.5–46.5
Kidney weight, right (g)				
Male	152.0	44.1	150	11–310
Female	116.7	50.4	109	37–640
Kidney weight, left (g)				
Male	161.4	116.0	155	50–2086
Female	119.4	66.9	110	17–780
S-creatinine ($\mu\text{mol}/\text{l}$)				
Male ($n=284$)	170	150	122	32–950
Female ($n=263$)	151	132	107	20–950

Results

Patient population and kidney parameters

Consecutive autopsies were performed in 323 males and 293 females. Median age of all patients was 77 years (males 75, females 80) (Table 1). Body mass index (median 23.8) showed slightly greater variation in females compared to males.

The median kidney weight was 130 g for the right and 132 g for the left kidney. Male kidneys weighed some 40 g more than female kidneys. The majority (52%) of the kidneys failed to show superficial scars. For kidneys with superficial scars, the average scarred surface area was $57 \pm 42\%$ (median 60%) for both males and females. No correlation of kidney weight and scarred surface area respectively with renal function was found (data not shown). Serum creatinine values were available in 90% of the patients. With median serum creatinine concentrations of $122 \mu\text{mol}/\text{l}$ for males ($n=284$) and $107 \mu\text{mol}/\text{l}$ for females ($n=263$), the renal function appeared to have been normal up to the last week preceding death in close to 50% of the patients. Not in a single case could papillary necrosis or analgesic nephropathy be diagnosed macroscopically.

Histological findings

The prevalence of different types of renal lesions is summarized in Table 2. As shown, 15% showed no significant abnormalities at all, 16% more than one lesion, 70% of the kidneys had histological evidence of chronic lesions and 8.3% showed acute lesions such as signs of shock kidney (5%), pyelonephritis (3%) or others (each <1%). Tumours were recorded in 5.8% of the kidneys. The majority of tumours was metastatic (3%) followed by benign tumours (2.5%). Primary malignant tumours were found in a total of 13 patients (including prior nephrectomy). Ureteral pathology

Table 2. Prevalence of different types of renal lesions in 616 patients/1220 kidneys

Diagnosis	Both sides n (% of kidneys)
No significant lesions	189 (15.5)
Acute lesions	101 (8.3)
Chronic lesions	854 (70)
Pathology of the papilla	175 (14.3)
Pathology of the ureter	19 (1.6)
Tumours	71 (5.8)
Nephrectomy	12 (1 ^a)

^aCalculated on the basis of all kidneys ($n=1232$).

Table 3. 'Chronic' renal lesions in 616 patients/1220 kidneys

Diagnosis	Both sides n (% of kidneys)
No significant chronic lesions	366 (30)
Predominant glomerular lesions	160 (13.1)
Glomerulonephritis	24 (2.0)
Diabetic diffuse glomerulosclerosis	38 (3.1)
Diabetic nodular glomerulosclerosis	67 (5.5)
Glomerulosclerosis in liver disease	20 (1.6)
Idiopathic glomerulosclerosis	11 (0.9)
Vascular lesions	705 (57.8)
Arterio-arteriosclerotic scars	672 (55.1)
Infarct scars	14 (1.1)
'Subinfarct' scars	9 (0.7)
Contracted kidney due to renal artery stenosis	30 (2.5)
Cholesterol embolism	43 (3.5)
Metabolic lesions	80 (6.6)
Amyloidosis	8 (0.7)
Nephrocalcinosis	67 (5.5)
Uric acid tophi	5 (0.4)
Tubulo-interstitial lesions	113 (9.3)
Analgesic nephropathy	2 (0.2)
Pyelonephritis	92 (7.5)
Hydronephrosis	18 (1.5)
Lithiasis	1 (0.1)
Malformation	12 (1.0)
Polycystic (adult) kidney disease	6 (0.5)
Malformations, others	6 (0.5)
Contracted kidney not specified	5 (0.4)

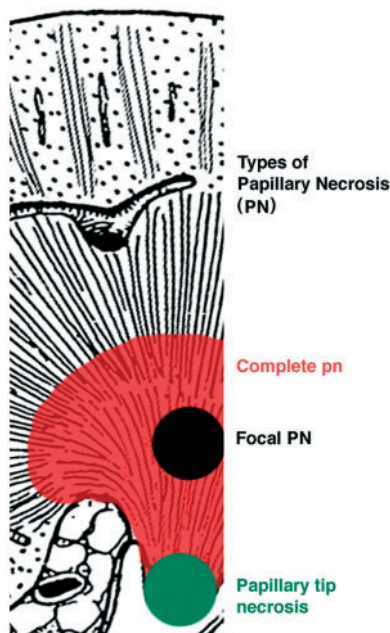
was found in 1.5% of the ureters of which metastatic tumours were the most prevalent (0.7%).

The predominant type of chronic pathology (Table 3) were vascular lesions (57.8%), mainly vascular scars in 55.1% of the kidneys followed in frequency by glomerular lesions (mostly diabetic glomerulosclerosis). Tubulo-interstitial lesions were found in 9.3% of the kidneys (mainly pyelonephritis) and metabolic lesions in 6.6% (mainly nephrocalcinosis of minor degree in 5.5%).

Papillary pathology is summarized in Table 4. Significant papillary lesions were absent from 85.7% of the kidneys. Fibrosis, mostly focal, was recorded in 7.4%. Papillary necroses (Figure 1) present in 8.4% of the kidneys were in the great majority areactive focal necroses of the papillary tip or of the medulla intermediate between the cortico-medullary junction

Table 4. Lesions of the renal papilla in 616 patients/1220 kidneys

Diagnosis	Both sides <i>n</i> (% of kidneys)
No significant lesions of the papilla	1045 (85.7)
Fibrosis	90 (7.4)
Focal fibrosis	87 (7.1)
Complete fibrosis	3 (0.2)
Necrosis	102 (8.4)
Areactive necrosis of the papillary tip	56 (4.6)
Areactive focal necrosis	22 (1.8)
Areactive complete necrosis	11 (0.9)
Necrosis in pyelonephritis	13 (1.1)
Others	46 (3.8)
Calcinosis	39 (3.2)
Cystoid dilatation of collecting ducts	2 (0.2)
Haemangioma	1 (0.1)
Amyloidosis of the papilla only	4 (0.3)

**Fig. 1.** Schematic description of the different types of papillary necrosis.

and the papillary tip. Areactive complete necrosis of at least one papilla was found in 0.9% of the kidneys but in only one patient was it associated with capillary sclerosis of both ureters (Table 5). This was the single case where a clear diagnosis of analgesic nephropathy could be made on histological grounds in the patient's own kidneys but not in her transplant. In another transplanted female with a clinical diagnosis of analgesic nephropathy, due to the abuse of phenacetin-containing mixed analgesics during the 1950s and 1960s, not a slightest trace of capillary sclerosis could be detected. However, her minuscule contracted kidneys showed histologically complete areactive papillary necroses (Figure 2 and Table 5).

Table 5. Analysis of kidneys with complete papillary necrosis

Autopsy Nr.	Sex	Age (yr)	Clinical diagnosis	S-creatinine (μmol/l)	Pathological diagnosis	Capillary sclerosis	Papillary necrosis
A00.500	F	67	Benign/malignant nephrosclerosis, kidney transplant	–	Analgesic nephropathy	Yes	Right and left
A01.117	M	79	Urosepsis	196	Chron PN right/left, vasc. scars right/left, urothelial bladder tumour	No	Right and left
A01.283	F	74	–	191	Chron PN right, vasc. scars right/left	No	Right
A01.390	M	74	–	119	PN right/left with obstruction	No	Right and left
A01.476	F	79	Analgesic nephropathy kidney transplant	–	Chron. PN right/left, undef. contracted kidney	No	Right and left
A02.035	F	83	–	204	Chron PN right/left, vasc. scars right	No	Right and left

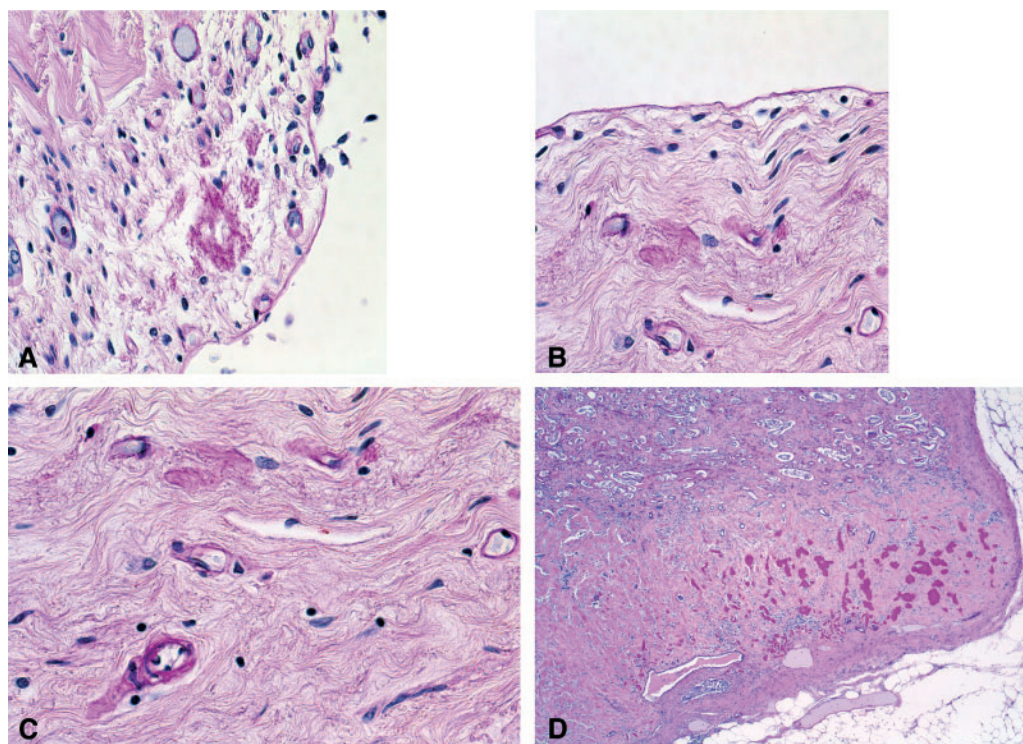


Fig. 2. Complete papillary necrosis in patient 1, Table 5. (A–C) Ureter with remnants of capillary sclerosis; (D) papillary necrosis with massive Tamm–Horsfall protein deposits (strong PAS-positive material).

None of the other 614 patients had evidence of papillary or urothelial capillary sclerosis.

Renal and urothelial malignancies

Among the 616 autopsy cases, a total of 10 patients had renal cell carcinoma (prior nephrectomy six cases, at autopsy four cases) and three patients had urothelial cell carcinomas of the renal pelvis (one prior nephrectomy, two autopsy cases). In addition, four patients had carcinoma of the bladder. There was one 79-year-old male with bilateral areactive papillary necrosis, who had undergone repetitive transurethral resections for papillary non-invasive bladder carcinoma 6–2 years before death. In none of the other cases with papillary necrosis were urothelial tumours detected in the lower urinary tract.

Discussion

Many analgesic compounds and phenacetin in particular were produced during the 20th century in the pharmaceutical metropolis of Basle which thus also became one of the world centres of analgesic abuse and its consequence: analgesic nephropathy [34,36]. The pathophysiological chain of events started with the abuse of phenacetin-containing analgesics which led to capillary sclerosis in the renal medulla causing papillary necrosis and consequently tubulo-interstitial

nephropathy with cortical atrophy [27,39]. It could be of no surprise, therefore, that capillary sclerosis was detected in 4% of autopsies performed in Basle in 1978–80 [36] when analgesic nephropathy reached its peak prevalence and was deemed responsible for end-stage renal disease in over 25% of the Swiss patients starting renal replacement therapy [33].

The present study of over 600 consecutive autopsies some 20 years later and also some 20 years after the disappearance of phenacetin from the analgesic market delineates a completely changed picture regarding analgesic nephropathy. Our systematic meticulous study of renal and urothelial histology detected only a single case of classic analgesic nephropathy with complete papillary necrosis in highly contracted kidneys associated with ureteral capillary sclerosis. This was the case of a female who would have died 14 years earlier had she not undergone renal replacement therapy including renal transplantation. None of the other five patients with unilateral or bilateral complete papillary necrosis had any evidence of capillary sclerosis. In one of these patients who had been a known analgesic abuser in the 1950s and 1960s and who had also undergone renal transplantation 14 years before death, classic analgesic nephropathy could not be proven because capillary sclerosis was no longer detectable. According to our earlier observations, 20–30 years without phenacetin intake is more than sufficient for capillary sclerosis to recede completely [27].

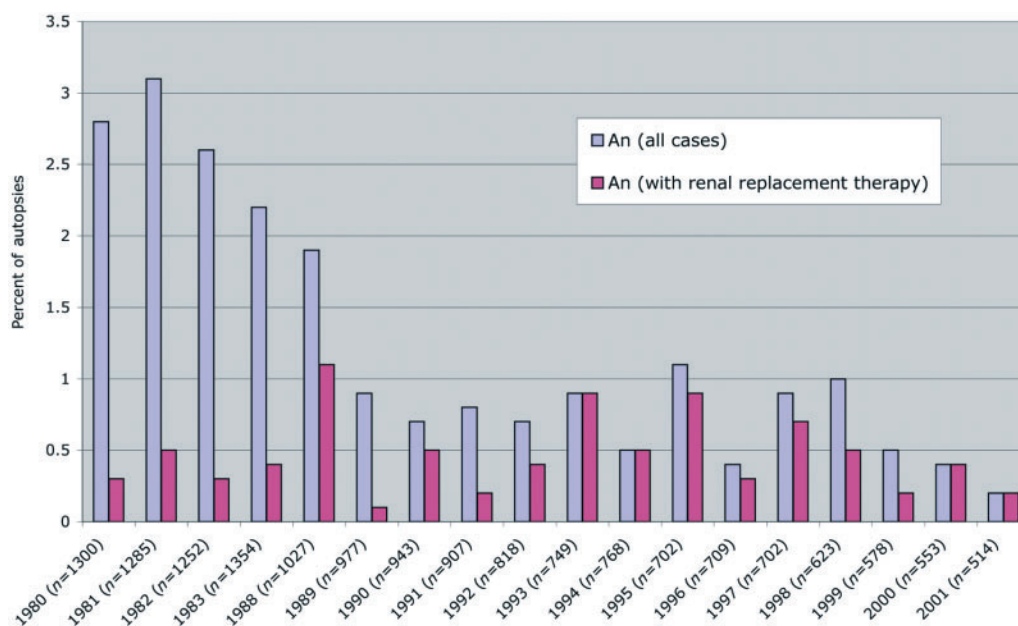


Fig. 3. Prevalence of analgesic nephropathy with and without renal replacement therapy (in percentage of autopsies per year).

The prevalence of primary renal tumours was in the expected range. However, compared to 1980, the autopsy prevalence of renal pelvic, ureteral and bladder carcinomata was much lower in the present study [40]. This might be due to the disappearance of carcinogenic metabolites of phenacetin, whereas paracetamol, the non-carcinogenic but analgesic metabolite of phenacetin, continues to be widely used.

All the other histological findings mentioned in the result section lack surprising features. The high prevalence of chronic vascular lesions, mainly arterio-arteriosclerotic scars, vascular scars due to renal artery stenosis and cholesterol embolism as well as the high prevalence of diabetic glomerulosclerosis, need clinical attention since most of these lesions may at least partially be prevented by early and consequent therapy of the underlying conditions such as hypertension, hyperlipidaemia, diabetes mellitus and smoking.

As noted earlier, it is—or better, it was—capillary sclerosis within the renal medulla developing due to toxic metabolites of phenacetin that was causing papillary necrosis and thus classic analgesic nephropathy. This initiating toxic event may have preceded the clinical diagnosis of analgesic nephropathy by decades. Epidemiological studies relating clinically diagnosed analgesic nephropathy to the intake of supposedly toxic drugs consumed during the preceding 5–10 years may thus easily miss earlier or shamefully unadmitted intake of the notorious phenacetin-containing analgesics. For this reason and in contrast to the opinion expressed by one group of Belgian authors [41], the case appears to be rather weak for mixed preparations containing analgesics other than phenacetin to cause chronic renal disease initiated by papillary necrosis [33,42].

The purpose of the present study was to see whether removal of phenacetin from analgesic mixtures was effective in reducing the prevalence of analgesic nephropathy. As shown in Figure 3, there was a steady continuous decrease in the prevalence of analgesic nephropathy in the autopsy statistics of the Basle Institute of Pathology. This decrease occurred despite the fact that mixed analgesics have continued to be popular drugs with paracetamol replacing phenacetin in many preparations since the 1970s and particularly since the early 1980s. The last and single autopsy case of proven classic analgesic nephropathy, detected only with the present sophisticated histological study at the end of the year 2000, can thus be taken as further evidence that this type of chronic renal disease was due to nothing but phenacetin-containing mixed analgesics. Some 20 years after the removal of phenacetin from the market, classic analgesic nephropathy is all but disappearing and will no longer be a health hazard in the 21st century.

Conflict of interest statement. None declared.

References

1. Haas H. History of antipyretic analgesic therapy. *Am J Med* 1983; 75: 1–3
2. Bürgi E. Die Gelonida antineuralgica als Kombinationsmittel. *Münchener Med Wschr* 1927; 16: 673–674
3. Gsell O. Nephropathie durch Analgetika. *Ergebn Inn Med Kinderheilk* 1974; 35: 68–175
4. Zollinger HU. Chronische interstitielle Nephritis bei Abusus von phenacetin-haltigen Analgetika (Saridon usw). *Schweiz Med Wschr* 1955; 85: 746–750

5. Spühler O, Zollinger HU. Die chronische interstitielle Nephritis. *Helv Med Acta - Series* 1950; 17: 564–567
6. Zollinger HU, Spühler G. Die nicht-eitrige chronische interstitielle Nephritis. *Path Bakteriolog* 1950; 13: 807–811
7. Spühler O, Zollinger HU. Die chronische interstitielle Nephritis. *Z Klin Med* 1953; 151: 1–50
8. Zollinger HU. *Relationship of Renal Toxicity of Drugs to Pyelonephritis. Biology of Pyelonephritis*. Little, Brown & Company, Boston, MA: 1960; 59–68
9. Gloor F. Über verschiedene Formen der Papillennekrose der Nieren. *Path Microbiol Basle* 1960; 23: 262–272
10. Gloor F. Die doppelseitige chronische nichtobstruktive interstitielle Nephritis. *Ergebn allg Path path Anat* 1961; 41: 64–207
11. Gloor F. Die doppelseitigen chronischen nichtobstruktiven interstitiellen Nephritiden. *Verh Dtsch Ges Pathol* 1965; 49: 92–107
12. Burry AF, Jersey de P, Weedon D. Phenacetin and renal papillary necrosis: Results of a prospective autopsy investigation. *Med J Australia* 1966; 2: 531–538
13. Sanerkin NG. Chronic phenacetin nephropathy (with particular reference to the relationship between renal papillary necrosis and “chronic interstitial nephritis”). *Br J Urol* 1966; 38: 361–370
14. Kincaid-Smith P. Pathogenesis of renal lesion associated with abuse of analgesics. *Lancet* 1967; 1: 859–862
15. Munk A, Lindlar F, Masshoff W. Pigmentierung der Nierenpapillen und der Schleimhaut der ableitenden Harnwege bei chronisch-sklerosierender interstitieller Nephritis (Phenacetinniere). *Virchows Arch A (Pathology)* 1970; 349: 323–331
16. Abrahams C, van Tonder H, Hesse V. Abnormal vessels in urinary tract following analgesic abuse in man. *Arch Pathol Lab Med* 1976; 100: 630–631
17. Torhorst J. Nierenschädigung durch Analgetika. Pathologische Anatomie und Morphogenese. *Nephrol Klinik Praxis* 1976; 3: 1345–1349
18. Nissen NT, Pedersen J. Pyelonephritis og phenacetin. *Ugeskrift Laegre* 1957; 119: 1639–1640
19. Larsen K, Möller CE. A renal lesion caused by abuse of phenacetin. *Acta Med Scand* 1959; 164: 53–71
20. Lindeneg O, Fischer S, Pedersen J, Nissen NI. Necrosis of the renal papillae and prolonged abuse of phenacetin. *Acta Med Scand* 1959; 165: 321–328
21. Lindvall N. Renal papillary necrosis. A roentgenographic study of 155 cases. *Acta Radiol (Stockholm)* 1960; 153 [Suppl]: 192
22. Hultengreen N. Renal papillary necrosis. A clinical study of 103 cases. *Acta Chir Scand* 1961; [Suppl]: 1–84
23. Nordenfeldt O, Ringertz N. Phenacetin takers dead with renal failure. *Acta Med Scand* 1961; 170: 385–402
24. Bengtsson U. A comparative study of chronic non-obstructive pyelonephritis and renal papillary necrosis. *Acta Med Scand* 1962; 388 [Suppl]:
25. Grimlund K. Phenacetin and renal damage at a Swedish factory. *Acta Med Scand* 1963; 74 [Suppl 405]: 1–26
26. Mihatsch MJ, Torhorst J, Amsler B, Zollinger HU. Capillarosclerosis of the lower urinary tract in analgesic (phenacetin) abuse. An electron-microscopic study. *Virchows Arch (Pathol-Anat)* 1978; 381: 41–47
27. Mihatsch MJ, Hofer HO, Gudat F, Knüsli C, Torhorst J, Zollinger HU. Capillary sclerosis of the urinary tract and analgesic nephropathy. *Clin Nephrol* 1983; 20: 285
28. Consensus Conference. Analgesic-associated kidney disease. *J Am Med Ass* 1984; 251: 3123–3125
29. Hultengreen N, Lagergren C, Ljungqvist A. Carcinoma of the renal pelvis in renal papillary necrosis. *Acta Chir Scand* 1965; 130: 314–320
30. Nanra RS, Stuart-Taylor J, de Leon AH, White K. Analgesic nephropathy: etiology, clinical syndrome, and clinicopathologic correlations in Australia. *Kidney Int* 1978; 13: 79–92
31. Mihatsch MJ, Brunner FP, Gloor FJG. Analgesic nephropathy and papillary necrosis. In: Tisher CG, Brenner BM, eds. *Renal Pathology*, J.B. Lippincott Company, Philadelphia: 1994; 905–936
32. Brunner FP, Broyer M, Brynger H *et al.* Combined report on regular dialysis and transplantation in Europe XV, 1984. *Proc E.D.T.A.* 22 (1985) 2
33. Brunner FP, Selwood NH. End-stage renal failure due to analgesic nephropathy, its changing pattern and cardiovascular mortality. *Nephrol Dial Transplant* 1994; 9: 1371–1376
34. Mihatsch MJ, Hofer HO, Gutzwiller F, Brunner FP, Zollinger HU. Phenacetinabusus I. Häufigkeit, Pro-Kopf-Verbrauch und Folgekosten. *Schweiz Med Wschr* 1980; 110: 108–115
35. Mihatsch MJ, Kernen R, Zollinger HU. Phenacetinabusus VI: eine Autopsiestatistik unter besonderer Berücksichtigung extrarenaler Befunde. *Schweiz Med Wschr* 1982; 112: 1383–1388
36. Mihatsch MJ, Hofer HO, Korteweg E, Zollinger HU. Phenacetinabusus V: Häufigkeit des Phenacetinabusus im Basler Autopsiegut 1978–1980. *Schweiz Med Wschr* 1982; 112: 1245–1249
37. Elseviers MM, De Broe ME. A long-term prospective controlled study of analgesic abuse in Belgium. *Kidney Int* 1995; 48: 1912–1919
38. Ad Hoc Committee of the International Study Group on Analgesics and Nephropathy. Alvan R. Feinstein (Chairman), Lothar A.J. Heinemann (Coordinator) *et al.* *Kidney Int* 2000; 58: 2259–2264
39. Mihatsch MJ (ed.) *Das Analgetikasyndrom. Folgen des langjährigen Schmerz-mittelmissbrauches. Grundlagen-Klinik-Prävention*. G. Thieme Stuttgart: 1986
40. Mihatsch MJ, Knüsli C. Phenacetin abuse, & malignant tumors. *Klin Wschr* 1982; 60: 1339–1349
41. De Broe ME, Elsevier MM. Analgesic nephropathy. *N Engl J Med* 1998; 338: 446–452
42. Michielsen P, De Schepper P. Trends of analgesic nephropathy in two high-endemic regions with different legislation. *J Am Soc Nephrol* 2001; 12: 550–556

Received for publication: 22.2.06

Accepted in revised form: 1.6.06