

or transfer of disease-inducing cells, although the lack of archived serum or urine prior to bone marrow transplantation precludes further investigation.

These two cases provide unique insight into the kinetics of overproduction of galactose-deficient IgA1 and its glomerular deposition and consequent renal injury in IgAN. We propose that IgAN developed after hematopoietic cell transplantation due to a non-GVHD-related multi-hit process associated with glomerular deposition of galactose-deficient IgA1.

Acknowledgements. The study was supported in part by National Institutes of Health grants DK078244, DK075868, DK080301, DK082753, DK077279, DK071802 and DK077279.

Conflict of interest statement. None declared.

References

- Hingorani S. Chronic kidney disease in long-term survivors of hematopoietic cell transplantation: epidemiology, pathogenesis, and treatment. *J Am Soc Nephrol* 2006; 17: 1995–2005
- Bruskamp K, Doyle AM, Bloom RD *et al*. Nephrotic syndrome after hematopoietic cell transplantation: do glomerular lesions represent renal graft-versus-host disease? *Clin J Am Soc Nephrol* 2006; 1: 685–694
- Kimura S, Horie A, Hiki Y *et al*. Nephrotic syndrome with crescent formation and massive IgA deposition following allogeneic bone marrow transplantation for natural killer cell leukemia/lymphoma. *Blood* 2003; 101: 4219–4221
- Chan GS, Lam MF, Au WY *et al*. IgA nephropathy complicating graft-versus-host disease, another nephropathy causing nephrotic syndrome after bone marrow transplantation. *Histopathology* 2004; 45: 648–651
- Moldoveanu Z, Wyatt R, Lee J *et al*. Patients with IgA nephropathy have increased serum galactose-deficient IgA1 levels. *Kidney Int* 2007; 71: 1148–1154
- Otani M, Shimojo H, Shiozawa S. Renal involvement in bone marrow transplantation. *Nephrology* 2005; 10: 530–536
- Suzuki H, Suzuki Y, Aizawa M *et al*. Th1 polarization in murine IgA nephropathy directed by bone marrow-derived cells. *Kidney Int* 2007; 72: 319–327
- Imasawa T. Roles of bone marrow cells in glomerular diseases. *Clin Exp Nephrol* 2003; 7: 179–185
- Cooley H, Snowden J, Grigg A *et al*. Outcome of rheumatoid arthritis and psoriasis following autologous stem cell transplantation for hematologic malignancy. *Arthritis Rheum* 1997; 40: 1712–1715
- Tomana M, Novak J, Julian B *et al*. Circulating immune complexes in IgA nephropathy consist of IgA1 with galactose-deficient hinge region and antiglycan antibodies. *J Clin Invest* 1999; 104: 73–81
- Suzuki H, Suzuki Y, Lyas CN *et al*. Urinary polypeptide biomarkers of IgA nephropathy. *J Am Soc Nephrol* 2008; 19: 665A
- Novak J, Tomana M, Matousovich K *et al*. IgA1-containing immune complexes in IgA nephropathy differentially affect proliferation of mesangial cells. *Kidney Int* 2005; 67: 504–513

Received for publication: 19.8.09; Accepted in revised form: 23.11.09

Nephrol Dial Transplant (2010) 25: 1713–1715

doi: 10.1093/ndt/gfp736

Advance Access publication 11 January 2010

An unusual clinical presentation of a rare renal tumour

Bhavneesh Sharma¹, Malik Reddy¹, Paul C Lee², Gracio Cortes¹ and Rammohan Gumpeni¹

¹New York Hospital Queens, Weill Medical College of Cornell University, Flushing, NY 11355, USA and ²New York Presbyterian Hospital, Weill Medical College of Cornell University, New York, NY 10065, USA

Correspondence and offprint requests to: Bhavneesh Sharma; E-mail: bhavneesh@hotmail.com

Abstract

We report an unusual clinical presentation of renal leiomyosarcoma. A woman, who received renal transplant from her mother, was diagnosed to have leiomyosarcoma in the donated kidney. The mother was found to have a right upper lobe lung mass 10 years later, which was diagnosed as leiomyosarcoma. It is possible that the mother had primary leiomyosarcoma of the donated kidney with micrometastases to the lung 10 years previously, which developed into a lesion in the donated kidney in her daughter. Ten years later, the slow-growing metastatic leiomyosarcoma developed into a lung mass.

Keywords: leiomyosarcoma; organ transplant; pulmonary; renal

Background

Leiomyosarcoma is a rare renal tumour. Smooth muscle tumours are extremely rare in solid organ transplant patients. We report an unusual clinical presentation of renal leiomyosarcoma.

Case report

A 64-year-old woman presented with cough and dyspnoea for 6 months. Ten years previously, the patient had donated a kidney to her daughter who had end-stage renal disease

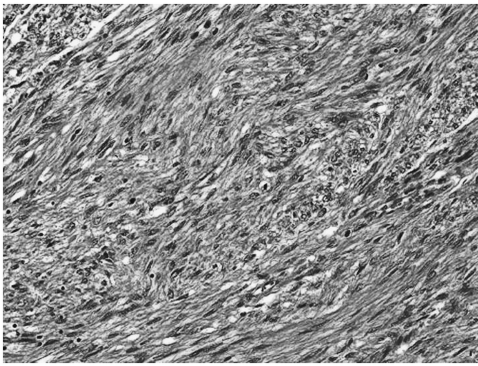


Fig. 1. Biopsy of the lesion in the transplanted kidney of the daughter showing leiomyosarcoma (haematoxylin–eosin stain, $\times 100$).

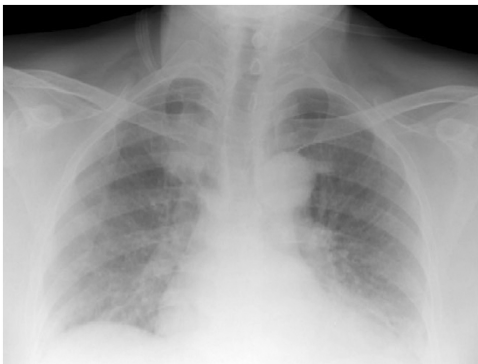

Fig. 2. Chest X-ray of the mother showing right upper lobe lung mass 10 years after donating her kidney.

due to systemic lupus erythematosus. Chest radiograph of the patient was normal before donating her kidney. Two years after the renal transplant, the patient's daughter was found to have a lesion in the transplanted kidney during workup for proteinuria. The renal lesion biopsy of the daughter showed leiomyosarcoma, which was surgically resected (Figure 1). Two months later, the patient's daughter had recurrence of leiomyosarcoma, which responded to further surgical resection and chemotherapy. The patient denied smoking and alcohol abuse.

Physical examination was normal. Routine blood tests including complete blood count and chemistry were normal. Chest X-ray was done which showed a right upper lobe lung mass (Figure 2). Positron emission tomography scan of the lungs showed increased uptake in the right upper lobe lung mass. The patient underwent wedge resection of the lung mass with mediastinal lymph node dissection.

Histopathology of the right lung mass showed low-grade leiomyosarcoma without mediastinal lymph node involvement (Figure 3). A possible diagnosis of primary leiomyosarcoma of the kidney with solitary lung metastasis was made.

Discussion

Leiomyosarcoma is a rare renal tumour. Renal leiomyosarcoma, like other types of sarcomas, tend to displace rather than invade the parenchyma, and it is characterized by

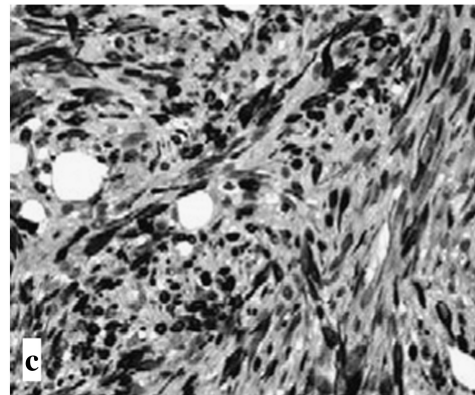
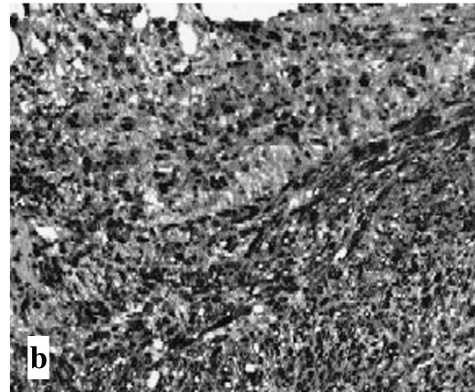
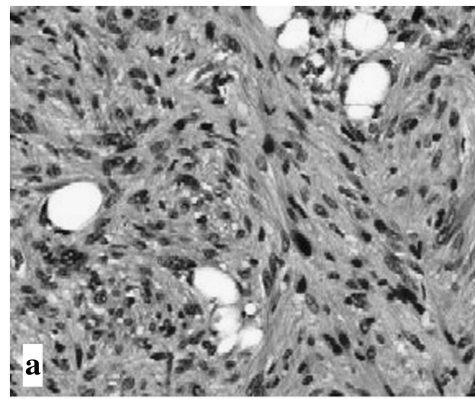


Fig. 3. Biopsy of right upper lobe lung mass of the mother showing low-grade leiomyosarcoma: (a) haematoxylin–eosin stain, $\times 200$, (b) smooth muscle actin stain, $\times 200$, (c) desmin stain, $\times 200$.

rapid growth rate, frequent metastasis and high local and systemic recurrence rates. High-grade sarcomas often metastasize, the lungs being the primary site of spread and prognosis is poor. The majority of patients die due to the progression of the disease within a matter of months. Low-grade sarcomas tend to pursue a more indolent course, although local recurrences are common. For the renal sarcomas, the best treatment modality is radical nephrectomy. Leiomyosarcomas, even when confined to the kidney, have a poor prognosis in general with 5-year survival rates of 29–36% [1]. In a case series on genitourinary leiomyosarcomas, the primary tumour site in 131 patients was the bladder in 20, the kidney in 26, parastitular in 57, the prostate in 21 and other in seven. The most common histological subtypes were leiomyosarcoma

in 29% of cases and liposarcoma in 26%. Seventy-eight percent of lesions were high grade [2].

Smooth muscle tumours arising in recipients of solid organ transplants are rare, with only 14 cases reported in the English-language literature. Incidence of sarcomas is 1.7% in solid organ transplant patients. Epstein–Barr virus (EBV) infection has been implicated in the pathogenesis of these tumours because of diminished immune function due to immunosuppressive therapy [3]. Ferri *et al.* reported a 61-year-old woman who had a leiomyosarcoma arising in a bronchus 29 years after renal transplantation [4]. The presence of EBV was demonstrated in tumour tissue by *in situ* hybridization. The interval of 29 years represents the longest interval from transplant to tumour in the literature. Chay *et al.* reported a 46-year-old female who received a single renal transplantation 10 years earlier for treatment of IgA nephropathy and was maintained on a regimen of azathioprine, cyclosporine and prednisolone. She presented with bilateral basal lung nodules and endobronchial mass in the left mainstem bronchus. A biopsy of the mass showed EBV associated smooth muscle tumour [5]. Sarcomas in solid organ transplant patients appear to have aggressive features with 62% being high grade and 40% metastatic at the time of primary diagnosis with a recurrence rate of 30%. The development of the renal leiomyosarcoma was more aggressive in the patient's daughter, most likely due to her immunosuppressive therapy.

Primary thoracic leiomyosarcomas are rare and occur in the mediastinum, heart, lung, pulmonary artery and superior vena cava. These tumours usually occur in the sixth decade or later and are more common in men. Leiomyosarcomas located in the mediastinum typically manifest clinically as a result of local mass effect (e.g. pain, cough, superior vena cava syndrome). Patients with pulmonary artery sarcomas present with chest pain, dyspnoea or intractable congestive heart failure. Primary pulmonary leiomyosarcomas are often asymptomatic, but patients can present with haemoptysis. The best available treatment option is complete resection of the tumour, which is associated with a reported 5-year survival of 29 to 40% [6]. As these tumours are resistant to both chemotherapy and radiotherapy, adjuvant therapies are not very effective. The

most consistent predictor of long-term survival is the grade of the tumour.

The clinical presentation of renal leiomyosarcoma in this case is unusual. It is possible that our patient had primary leiomyosarcoma of the donated kidney with micro-metastases to the lung 10 years back, which developed into a lesion in the donated kidney in her daughter. The slow-growing low-grade leiomyosarcoma developed into a metastatic solitary lung mass 10 years later in the patient. The patient's daughter had more aggressive manifestation of leiomyosarcoma in the transplanted kidney due to immunosuppressive therapy. Other possibilities include: (i) the daughter had renal leiomyosarcoma secondary to immunosuppression and not 'donated' by the mother, or (ii) the mother had two different primary sites of leiomyosarcoma (donated kidney and lung). However, these are less likely possibilities in our opinion.

In conclusion, we report an unusual clinical presentation of renal leiomyosarcoma. We are not aware of a similar clinical presentation of renal leiomyosarcoma in the medical literature.

Conflict of interest statement. None declared.

References

1. Demir A, Yazici CM, Eren F *et al.* Case report: good prognosis in leiomyosarcoma of the kidney. *Int Urol Nephrol* 2007; 39: 7–10
2. Dotan ZA, Tal R, Golijanin D *et al.* Adult genitourinary sarcoma: the 25-year Memorial Sloan-Kettering experience. *J Urol* 2006; 176: 2033–2038
3. Lee ES, Locker J, Nalesnik M *et al.* The association of Epstein–Barr virus with smooth-muscle tumors occurring after organ transplantation. *N Engl J Med* 1995; 332: 19–25
4. Ferri L, Fraser R, Gaboury L *et al.* Epstein–Barr virus-associated pulmonary leiomyosarcoma arising twenty-nine years after renal transplantation. *J Thorac Cardiovasc Surg* 2003; 126: 877–879
5. Chay WY, Penafiel A, Raghuram J *et al.* Dyspnea in a transplant recipient with pulmonary nodules. *Chest* 2009; 35: 865–870
6. Gladish GW, Sabloff BM, Munden RF *et al.* Primary thoracic sarcomas. *Radiographics* 2002; 2: 621–637

Received for publication: 27.5.09; Accepted in revised form: 5.12.09