

Case Report

Loss of Resistance Technique for Paravertebral Nerve Blockade Using the Episure™ Autodetect™ Syringe—A Case Report

Derick A. Munday, MD, Chester C. Buckenmaier III, MD, and Anthony R. Plunkett, MD

Walter Reed Army Medical Center, Washington, DC, USA

ABSTRACT

Introduction. Postoperative pain is a frequent occurrence following breast surgery. Some authors have reported the incidence of postoperative pain following mastectomy and breast reconstruction to be as high as 50% when general anesthesia and intravenous narcotics are the primary anesthetic. An alternative anesthetic technique for breast surgery and postoperative analgesia is paravertebral nerve blockade (PVB). Greengrass and Weltz have described improved patient satisfaction, less analgesic requirement, and less total anesthetic use in those patients with preoperative PVBs. One of the challenges in providing successful analgesia from PVBs is the ability to correctly identify the paravertebral space. Landmark-based anatomy with penetration of the superior costotransverse ligament 1 cm past the transverse process has been previously described. Boezaart has described the use of loss of resistance (LOR) when performing PVBs. One potential difficulty with this technique is the reliance on the subjective feel of resistance loss as the needle passes into the paravertebral space.

Case Report. The Episure™ Autodetect™ Syringe is currently indicated by the US Food and Drug Administration for use with an epidural needle for the verification for needle tip placement in the epidural space. The principle, however, of LOR is similar when performing PVBs. We report a case of the successful use of the Episure™ Autodetect™ Syringe (ADS) for confirming entry into the paravertebral space.

Conclusion. To our knowledge, this is the first described use of the ADS for performing PVB.

Key Words. Acute Pain; Pain Management; Postoperative Pain

Introduction

Postoperative pain is a frequent occurrence following breast surgery [1–3]. Some authors have reported the incidence of postoperative pain following mastectomy and breast reconstruction to be as high as 50% when general anesthesia and intravenous narcotics are the primary anesthetic [4,5]. An alternative anesthetic technique for breast surgery and postoperative analgesia is paravertebral nerve blockade (PVB). Greengrass et al. and Weltz et al. have described improved patient satisfaction, less analgesic requirement,

and less total anesthetic use in those patients with preoperative PVBs [6,7]. It has also been speculated that a preemptive analgesic effect leading to decreased postoperative pain may also occur [8,9]. One of the challenges in providing successful analgesia from PVBs is the ability to correctly identify the paravertebral space. The paravertebral space is formed by the ribs anteriorly, the superior costotransverse ligament posteriorly, the pleura laterally, and the vertebra medially. Within this space lies the intercostal (spinal) nerve, the dorsal ramus, the intercostal vessels, the rami communicantes, and the sympathetic chain. Local anesthetic injected into this space results in a dense unilateral sensory, motor, and sympathetic blockade. Thoracic PVB has been shown to block the cortical responses to thoracic dermatomal stimulation at

Reprint requests to: Anthony R. Plunkett, MD, Walter Reed Army Medical Center, Washington, DC 20307. Tel: 518-369-3543; Fax: 202-782-5066; E-mail: anthonyplunkett@comcast.net.

the block level and adjacent dermatomes [10]. This prevention of afferent input to the central nervous system is important in pain modulation [10]. Landmark-based anatomy with penetration of the superior costotransverse ligament 1 cm past the transverse process has been previously described [11]. Boezaart and Ram has described the use of loss of resistance (LOR) when performing PVBs [12]. One potential difficulty with this technique is the reliance on the subjective feel of resistance loss as the needle passes into the paravertebral space. The Episure™ Autodetect™ Syringe (ADS) (Indigo Orb, Inc., Irvine, CA) is currently FDA indicated for use with an epidural needle for the verification for needle tip placement in the epidural space. The principle, however, of LOR is similar when performing PVBs [12]. We report a case of the successful use of the Episure™ ADS for confirming entry into the paravertebral space. To our knowledge, this is the first described use of the ADS for performing PVB.

Case Report

A 61-year-old female, 93 kg, 165 cm, American Society of Anesthesiologists (ASA) classification II presented for left breast lumpectomy and sentinel node biopsy for infiltrating ductal carcinoma. Her medical history was significant for hypertension and mild asthma. The patient consented to have PVBs placed as the primary anesthetic, with intravenous sedation as needed in the operating room. Standard ASA monitors were applied, and supplemental oxygen at 6 L/min was administered via facemask. The patient was given divided doses of intravenous midazolam 2 mg and fentanyl 50 µg for moderate sedation during block placement. The PVB was performed using a modified LOR technique with the ADS. A 22-gauge Touhy needle was attached to extension tubing with a male Luer lock adaptor and a four-way stopcock. The ADS and 20-mL syringe both attached to the four-way stopcock (Figure 1). The 20-mL syringe was filled with 0.5% ropivacaine and epinephrine 1:400,000. Prior to entering the skin, the ADS was filled with 2 mL of the local anesthetic and epinephrine, and the four-way stopcock was placed in the off position toward the ADS. Once the transverse process of the target vertebra was contacted, the four-way stopcock was turned to the off position of the 20-mL syringe (Figure 2). The needle was then “walked off” the transverse process caudally until the superior costotransverse ligament was penetrated. If the superior costotransverse

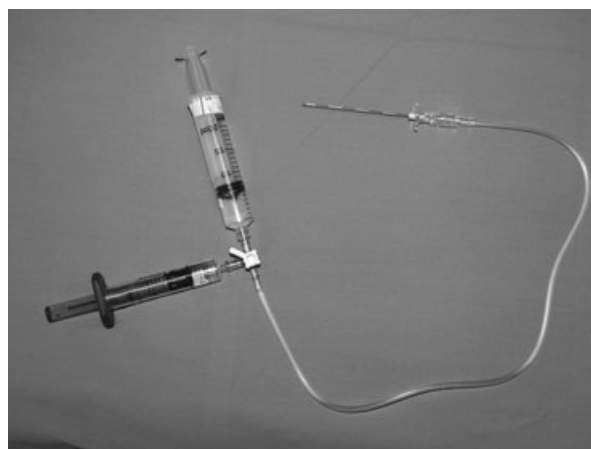


Figure 1 ADS set up.

ligament was felt to be traversed and the ADS did not activate, the assistant then turned the stopcock off to the ADS and palpated the 20-mL syringe. When this occurred in our case, the 20-mL syringe felt “tight” (suggesting that the needle tip was buried within the superior costotransverse ligament) and the Touhy needle was slowly advanced until the ADS was released, thus confirming the proper entrance into the paravertebral space. Another 2–4 mL of 0.5% ropivacaine and epinephrine was administered. This process was repeated at levels T1–T4.

After demonstration of adequate blockade by loss of sensation to pinprick and temperature sensation 20 minutes following block placement, the patient was transported to the operating room for surgery. The patient received an additional 2 mg midazolam and 100 µg fentanyl, and was placed on

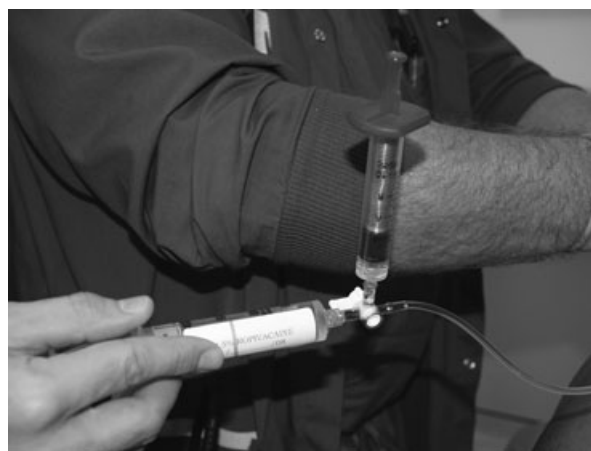

Figure 2 Application of ADS device for PVB.

a propofol infusion at 50 mcg/kg/min for sedation. The left breast lumpectomy and sentinel node biopsy was completed without complication, and the patient was transferred to the postanesthesia care unit (PACU) for recovery. Her initial pain assessment in the PACU by the verbal analog scale (0 = no pain, 10 = worst pain imaginable) was zero and she did not require any opioid medication while in the PACU. The patient was reevaluated 6 hours later with a pain score of zero and was discharged home. A phone interview was conducted at 24 hours postoperatively, and the patient reported her pain to be a 2/10 and was easily managed with oral nonsteroidal anti-inflammatory medication.

Discussion

We report the use of the ADS for performing PVB via the LOR technique. The ADS is a LOR syringe with an internal coaxial compression spring that applies constant pressure on the plunger. The plunger automatically depresses when the needle tip enters the epidural space [13,14]. Habib and colleagues [14] found that the use of the ADS resulted in reduced rates of failed epidurals and potentially less incidence of “false loss” in parturients. The ADS was felt to more accurately identify the paravertebral space and also aided in identifying a “false” LOR.

Currently, we rely heavily on the subjective feel of an assistant administering the local anesthetic through a regular 20-mL syringe. If the injection feels “tight” to the assistant or visually looks “tight” to the performer, we often will advance slightly more past 1 cm. The ADS may help minimize the subjectivity of an assistant manually pushing a syringe. The “pop” sensation described when penetrating the superior costotransverse ligament is not a consistent finding and may not be appreciated as a definitive give, which may be one of the factors leading to the reported failure rates of 6.1% and 10.1% for PVBs [15,16]. Hadzic and Vloka [17] also state that such a change in resistance is subtle and nonspecific at best. They do not utilize LOR and rely on the anatomical relationship of the advancement of the needle tip 1 cm past transverse process. In our practice, we often find that even when the needle tip is advanced 1 cm past transverse process, the feel of the syringe upon injection of the local anesthetic is “tight,” requiring slightly greater advancement into the space. In our case, the ADS would not deliver the

2 mL of local anesthetic when a subjective “pop” or “give” was felt by the anesthesiologist performing the block and required further penetration of the Touhy needle.

One of the risks associated with our technique is the potential inability to recognize intravascular penetration with the spring-loaded design of the ADS. Lonnqvist et al. prospectively evaluated complications after PVBs in 367 patients and observed the complication of vascular puncture to be 3.8% [16]. The authors felt that by limiting the amount of local to 2 mL in the ADS, if a blood vessel was entered, the volume of local would not be sufficient to produce patient morbidity, and the presence of epinephrine would help serve as a marker.

This case illustrates the potential advantages of using the ADS in further refining the technique of PVBs. The patient received excellent analgesia that continued into the postoperative period. At several levels, we failed to achieve LOR with the ADS, despite the anesthesiologist’s subjective feeling of traversing the superior costotransverse ligament. Had we injected the local anesthetic in this situation, the patient may not have had such profound analgesia. Further research is needed to determine if using the ADS can help decrease the current failure rate of PVBs by more accurately identifying the true paravertebral space.

References

- 1 Tasmuth T, von Smitten K, Hietanen P, et al. Pain and other symptoms after different treatment modalities of breast cancer. *Ann Oncol* 1995;6:453–9.
- 2 Fujii Y, Tanaka H, Toyooka H. Prophylactic antiemetic therapy with granisetron dexamethasone combination in women undergoing breast surgery. *Acta Anaesthesiol Scand* 1998;42:1038–42.
- 3 Quinn A, Brown J, Wallace P, Ashbury A. Studies in postoperative sequelae. Nausea and vomiting—still a problem. *Anaesthesia* 1994;49:62–5.
- 4 Vadivelu N, Schreck M, Lopez J, Kodumudi G, Narayan D. Pain after mastectomy and breast reconstruction. *Am Surg* 2008;74:285–96.
- 5 Cheville AL, Tchou J. Barriers to rehabilitation following surgery for primary breast cancer. *J Surg Oncol* 2007;95:409–18.
- 6 Weltz C, Greengrass R, Lysterly H. Ambulatory surgical management of breast carcinoma using paravertebral block. *Ann Surg* 1995;222:19–26.
- 7 Greengrass R, O’Brien F, Lysterly K, et al. Paravertebral block for breast cancer surgery. *Can J Anaesth* 1996;43:858–61.

- 8 Tverskoy M, Cozacov C, Ayache M, Bradley EL Jr, Kissin I. Postoperative pain after inguinal herniorrhaphy with different types of anesthesia. *Anesth Analg* 1990;70:29–35.
- 9 Richardson J, Sabanathan S, Mearns AJ, et al. Efficacy of pre-emptive analgesia and continuous extrapleural intercostals nerve block on post-thoracotomy pain and pulmonary mechanics. *J Cardiovasc Surg* 1994;35:219–28.
- 10 Richardson J, Jones J, Atkinson R. The effect of thoracic paravertebral blockade on intercostal somatosensory evoked potentials. *Anesth Analg* 1998;87:373–6.
- 11 Eason MJ, Wyatt R. Paravertebral thoracic block—A reappraisal. *Anaesthesia* 1979;34:638–42.
- 12 Boezaart AP, Raw RM. Continuous thoracic paravertebral block for major breast surgery. *Reg Anesth Pain Med* 2006;31:470–6.
- 13 Riley ET, Carvalho B. The Episure™ Syringe: A novel loss of resistance syringe for locating the epidural space. *Anesth Analg* 2007;105:1164–6.
- 14 Habib AS, George RB, Allen TK, Olufolabi AJ. A pilot study to compare the Episure™ Autodetect™ Syringe with the glass syringe for identification of the epidural space in parturients. *Anesth Analg* 2008;106:541–3.
- 15 Naja Z, Lonnqvist P-A. Somatic paravertebral nerve blockade incidence of failed block and complications. *Anaesthesia* 2001;56(12):1184–8.
- 16 Lonnqvist P-A, MacKenzie J, Soni AK, Conacher ID. Paravertebral blockade: Failure rate and complications. *Anaesthesia* 1995;50:813–5.
- 17 Hadzic A, Vloka JD. *Peripheral Nerve Blocks. Principles and Practice*, 1st edition. New York: The McGraw-Hill Companies, Inc.; 2004.