

# Etiology of Long-term Failures of Lumbar Spine Surgery

Alexis Waguespack, MD, Jerome Schofferman, MD, Paul Slosar, MD, and James Reynolds, MD

SpineCare Medical Group, San Francisco Spine Institute, Daly City, California

## ABSTRACT

*Background Context.* Patients who do not improve after lumbar surgery may be given the nonspecific label of “failed back surgery syndrome (FBSS).” Since 1981, there has not been a quantitative assessment of the etiologies of FBSS despite major improvements in surgical techniques and diagnostic testing.

*Purpose.* To define the causes of FBSS seen in a referral-based spine center.

*Study Design and Methods.* Retrospective review of 181 consecutive charts of patients seen at a single spine center because of continued pain after lumbar surgery performed elsewhere. Evaluation was individualized based on history and physical examination and included x-rays, CT scans, MRI, selective nerve root injections, discography, and psychiatric evaluation.

*Patient Sample.* There were 101 men and 80 women; mean age was 47 years. There were 118 patients with one prior surgery, 52 with two, 6 with three, and 5 with four. Mean interval from the last prior surgery to the first clinic visit was 33 months.

*Results.* A predominant diagnosis could be established in 170 of 181 (94%) patients, and included foraminal stenosis (29%), painful disc(s) (17%), pseudarthrosis (14%), neuropathic pain (9%), instability (5%), and psychological problems (3%).

*Conclusion.* We were able to establish a predominant diagnosis in 94% of our patients. Foraminal stenosis remains the leading cause of FBSS, but painful discs are also common. Recurrent disc herniation is seen less often than in the past, and there is increased recognition of neuropathic pain. Knowledge of the potential causes of FBSS leads to a more efficient and cost-effective evaluation of these patients.

*Key Words.* Failed Back Surgery; Foraminal Stenosis; Discogenic Pain; Neuropathic Pain

## Introduction

Some patients who undergo lumbar spine surgery do not improve, and are considered to have “failed back surgery syndrome (FBSS).” Most patients with FBSS seek further treatment for their ongoing pain and impairment. There are many treatment options available, and optimal therapy for each particular patient depends on the etiology of the FBSS. Because there are many causes of FBSS, it is important to know the differential diagnosis to evaluate patients efficiently and to provide the most specific and effective form of treatment.

Despite many published reviews, overviews, and discussions of FBSS, there are no recent studies that provide quantitative data about the most likely structural causes of the pain. The most recent quantitative study is more than 20 years old [1]. Since this landmark paper, there have been major improvements in the types of spine surgeries and in diagnostic testing. As a result, it is not known if the Burton data are still relevant.

In order to establish the differential diagnosis of FBSS in the modern spine era, we reviewed our recent experience with 181 patients who had not improved or who had worsened after lumbar spine surgery performed at other clinics or centers. All patients had undergone a comprehensive evaluation at our private practice, tertiary care spine center. In addition to the history and physical examination,

*Reprint requests to:* Jerome Schofferman, MD, 1850 Sullivan Avenue #200, Daly City, CA 94015. Tel: (650) 985-7500; Fax: (650) 985-7506; E-mail: jschofferman@spinecare.com.

we used computed tomography (CT) scans, magnetic resonance imaging (MRI) scans, psychiatric evaluations, discography, and other specialized spinal injections to establish the etiology of continued or recurrent low back or leg pain after prior lumbar spine surgery.

### Methods

We used a computerized data base to identify all patients seen at our clinic from December, 1995 through December 31, 1997 who had prior lumbar spine surgery. We included only those patients whose surgery had been performed at hospitals and by surgeons unassociated with our medical group. We identified those patients whose pain was the same or worse than before surgery, and who had a sufficient number of follow-up visits and adequate diagnostic testing to establish a diagnosis or to reach the conclusion that no firm diagnosis could be established. The diagnostic evaluation had been individualized based on the patient's history and physical examination. It included a combination of plain x-rays with standing flexion and extension views and a supine cross-table lateral view, high-resolution multiplanar CT, MRI, discography, other diagnostic spinal injections, and psychiatric evaluation.

### Functional Definitions of Terms

We used the following functional definitions for the clinical management and data accumulation, which are a composite of the definitions offered by the North American Spine Society [2] and the International Association for the Study of Pain [3], modified by the authors' clinical experiences.

- **Foraminal stenosis:** Pain predominantly in a leg or buttock, worsened by standing or walking, relieved by sitting; narrowing of the index nerve root foramen on MRI or CT scan; and temporary relief of leg pain after transforaminal epidural blockade of the suspected nerve root.
- **Discogenic pain:** Predominantly low back pain with or without referred buttocks or leg pain that arises from one or more discs; abnormal disc(s) appearance with desiccation and/or disc space narrowing on MRI scan; reproduction of the patient's usual pain by provocation discography of the putatively symptomatic disc with no pain provocation by provocative discography of at least one adjacent disc; no neural compression on MRI; and the pain cannot be ascribed to some other spine sources.
- **Pseudarthrosis:** Apparent nonunion on CT scan or abnormal motion at a fusion level on flexion versus extension x-rays; no other significant structural cause for the pain.
- **Neuropathic pain:** Predominance of leg pain, usually described as burning or dysesthetic, in one or two adjacent dermatomes due to nerve damage; pain must be constant, although it could be worsened by activity; no evidence of nerve root compression on MRI or CT scan.
- **Recurrent or residual disc herniation:** Pain in a leg in a dermatomal distribution that significantly exceeds any low back pain; radiographic evidence of compression of a spinal nerve by a disc herniation on CT or MRI scan.
- **Post-laminectomy instability:** Greater than 3 mm translation on standing flexion versus extension x-rays or neutral x-ray versus supine cross-table lateral view. (Note: If fusion had been attempted, patients with pseudarthrosis were not included in this group).
- **Psychological disorder:** Low back pain with or without leg pain, not attributable to any pathological structural cause or far out of proportion to pain usually produced by a structural abnormality present; the presence of a diagnosable psychological illness by DSM-IV criteria that has been shown to cause or markedly exacerbate pain.

### Results

There were 240 patients who were identified with FBSS. Of these, there were 181 patients (75%) for whom there was adequate diagnostic testing to establish a diagnosis or to reach the conclusion that no diagnosis could be established. Of these, 101 were men and 80 were women. The mean age was 47 years (range 22–74). There were 118 patients with one prior surgery, 52 with two, 6 with three, and 5 with four prior surgeries. The mean interval from the last prior surgery to the first clinic visit was 33 months (range 4 to 108 months).

We were able to establish a single primary diagnosis in 159 of the 181 (88%) and two coexisting diagnoses in 11 patients (6%) (Table 1). We were unable to establish a predominant diagnosis in only 11 patients (6%). Foraminal stenosis and one or more painful discs accounted for almost one half of the patients.

**Table 1** Etiology of long-term failures of lumbar spine surgery.

Diagnosis	Number	% of total
Foraminal stenosis	53	29
Painful disc(s)	31	17
Pseudarthrosis	26	14
Neuropathic pain	17	9
Recurrent HNP	10	6
Iatrogenic instability	9	5
PDDD within fusion	5	3
Psychological	5	3
Infection	2	1
Arachnoiditis	1	1
PDDD plus stenosis	9	5
RHNP plus stenosis	2	1
Total	170	94%

PDDD = painful degenerative disc disease; HNP = herniated disc

## Discussion

There is no precise or well-accepted definition of FBSS. Clinically, and for the purposes of this research, we used a functional definition: FBSS implies that the outcome of a lumbar spine surgery did not meet the expectations established by the patient and the surgeon *before* surgery. It does not mean failure to obtain total pain relief or failure to obtain totally normal function because, for some spinal conditions, it is clear before surgery that complete pain relief is not realistic. In these instances, the goal of surgery is meaningful improvement in pain and/or function. Certainly, all patients who are worse or no better than before surgery have FBSS.

The most important reason to define the precise cause of FBSS is to determine the best course of treatment. There are many potential interventions for FBSS including medications, functional restoration, neuro-augmentation, and revision surgery, among others. As with any medical or surgical condition, to most efficiently establish the cause in a particular patient, it is vital to know the differential diagnosis of the symptoms.

In 1981, Burton et al. reported an analysis of several hundred patients with FBSS [1]. They found that about 58% had lateral canal stenosis, 7 to 14% had central canal stenosis, 12 to 16% had recurrent (or residual) disc herniations, 6 to 16% had arachnoiditis, and 6 to 8% had epidural fibrosis. Other less common causes included nerve injury during surgery (neuropathic pain), chronic mechanical pain, painful segment (disc) above a fusion, pseudarthrosis, foreign body, and surgery performed at the wrong level. They were unable to establish a definitive diagnosis in less than 5% of their patients. Their study was done early in the CT scan era and before MRI scans were available. They did have discography avail-

able. Because there have been major advances in diagnostic testing over the last 20 years, it is not known whether the Burton results can be applied to current patients.

Several authors have presented their unquantified impressions and experiences about the causes of FBSS [4–7]. Fritsch reviewed 136 patients who had revision surgeries after clinical failure of an initial laminectomy and discectomy, and found a high prevalence of recurrent disc herniations and instability [7]. Kostuik reviewed the potential causes of failure of decompression, but provided no quantitative data [5,6]. The lack of quantified information about the causes of FBSS led us to review our experience.

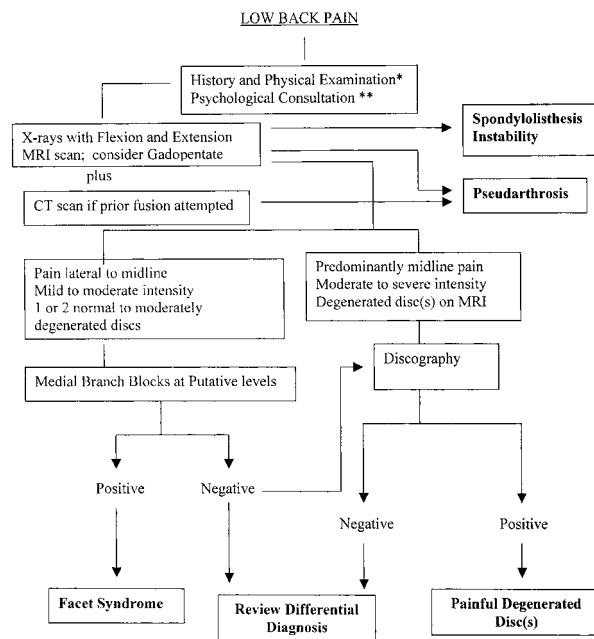
We were able to establish a predominant clinically relevant diagnosis in 94% of patients (Table 1). We observed that, in many instances, the surgery that failed may not have been the best choice for the specific structural disorder, the preoperative diagnosis was incorrect or incomplete, or the surgery performed did not adequately correct the structural disorder.

The most common diagnosis was lateral canal or foraminal stenosis, present in 53 (29%) of our patients. This is somewhat less than in Burton's study, perhaps because of better preoperative recognition of the diagnosis and more meticulous foraminal decompression.

There were painful degenerated disc(s) in 31 (17%) patients who did not have prior fusion. Five (3%) additional patients had a painful disc at a level contained within a solid fusion [8]. We hypothesize that some patients with discogenic pain had undergone a surgery that may not have been appropriate for the clinical condition. For example, patients with predominantly low back pain had decompression with or without partial discectomy, but not fusion. In other words, they had a "leg pain operation" when the major problem was low back pain. In other patients, a painful disc at a level adjacent to the index level was at least partly responsible for the pain, but this had not been recognized before surgery.

Pseudarthrosis was the predominant problem in 14% of our patients. Although a definitive diagnosis of pseudarthrosis requires surgical exploration, diagnosis by high resolution CT scan is reasonably accurate [9]. We did not collect sufficient data to establish the number of patients who had undergone an attempted fusion, and therefore it is not possible to know the clinical relevance of this number.

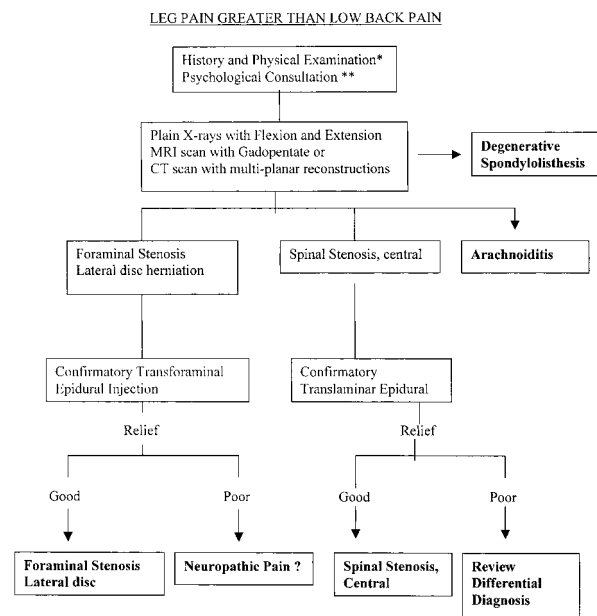
Neuropathic pain was the predominant problem in 9% of our patients. Burton et al. observed neuropathic pain in less than 5% of their patients, and it is not clear if there has been an increase in nerve



**Figure 1** Basic diagnostic algorithm for the evaluation of failed back surgery with low back pain greater than leg pain. Diagnoses in bold.

root injury or an increased recognition of neuro-pathic pain. Nerve roots can be damaged during surgery or by prolonged unrelieved compression by spinal stenosis or disc herniation [1]. We saw only one instance of arachnoiditis, less than Burton's group, perhaps because myelography was performed less frequently and, when done, water-soluble contrast agents were used.

The role of psychological causes of FBSS is complex. Psychological factors have been shown to be a significant contributor to the outcome of lumbar spine surgery. Patients with better psychological profiles tend to have better results from lumbar surgery than those with significantly abnormal psychological states. Although it is rare for a psychological illness to be the sole cause of pain, some psychological illnesses may result in a structural cause of pain hurting more. The most common psychological problems seen in patients with FBSS are depression, anxiety disorder, and substance abuse disorder [10]. In addition, there may be a high prevalence of childhood psychological abuse in patients with FBSS, especially in those with little structural pathology and continued pain [11,12]. In most instances, psychological problems that were present after surgery were already present to some degree before surgery—one reason to perform psychological risk assessment before surgery, not just after failed surgery [10].



\* May disclose symptoms suggestive of infection, cancer, diabetes, peripheral neuropathy, entrapment syndrome, or other systemic disease

\*\* May reveal underlying or secondary psychological cause or major contribution to low back pain.

**Figure 2** Basic diagnostic algorithm for the evaluation of failed back surgery with leg pain greater than low back pain. Diagnoses in bold.

There are several weaknesses to this study. It shares the problems inherent in all retrospective studies. The data analysis is subject to the information contained in the medical records. For most patients, we did not have access to prior medical records to document the indications for surgery, the diagnostic evaluation before surgery, or the details of the surgery performed. Therefore, we were not able to relate each cause of FBSS to the specific preoperative diagnosis or the type of surgery performed. A possible criticism is that we chose to include only patients who had their surgeries performed elsewhere. We felt this cohort would be most representative of the general population of patients with FBSS. We did not include our own operative failures, not because we do not have them, but because the care of patients at a specialized spine center may not reflect the surgical care in the community at large.

We did not evaluate the responses to treatment because this was not a goal of the study. Therefore, we are not able to say if knowledge of the differential diagnosis leads to improved treatment. However, we feel that this knowledge has allowed us to evaluate our new patients in a more efficient manner.

As a result of our findings, we can offer one useful way to begin the evaluation of a patient with FBSS.

Patients who have predominantly low back pain are most likely to suffer from one or more painful discs, instability, or in patients who had attempted fusion, pseudarthrosis. These patients are most efficiently evaluated with plain x-rays with flexion and extension (to look for instability), MRI (for degenerated discs or spinal stenosis), and discography (to determine if discs are painful) (Figure 1). Patients with primarily leg pain are most likely to have lateral canal stenosis, recurrent or residual disc herniations, or neuropathic pain. These patients are most efficiently evaluated with plain x-rays, multiplanar CT scan (for foraminal stenosis and pseudarthrosis) or possibly MRI (for spinal stenosis), and transforaminal epidural injections (to assess if stenosis is symptomatic) (Figure 2). Although we did not find facet syndrome in our patients, if this diagnosis is suspected, patients are best evaluated with medical branch blocks. Further testing should be based on the results of initial test results. Psychological evaluation can prove important for all patients with FBSS.

## References

- Burton CV, Kirkaldy-Willis WH, Yong-Hing K, Herthoff KB. Causes of failure of surgery on the lumbar spine. *Clin Orthop* 1981;157:191–9.
- Fardon DF, Herzog RJ, Mink JH, Simmons JD, Kahanovitz N, Haldeman S. Nomenclature and classification of lumbar disc disorders. In: Garfin SR, Vaccaro AR, eds. *Orthopaedic Knowledge Update-Spine*. Rosemont, IL: American Academy of Orthopaedic Surgeons, 1997: A3–A14.
- Merskey H, Bogduk N. *Classification of chronic pain*, second edition. Seattle: IASP Press; 1994.
- Frymoyer JW, Matteri RE, Hanley EN, Kuhlmann D, Howe J. Failed lumbar disc surgery requiring second operation. *Spine* 1978;3:7–11.
- Kostuik JP. Failures after spinal fusion. In: Frymoyer JW, editor. *The adult spine: principles and practice*, second edition. Philadelphia: Lippincott-Raven; 1997.
- Kostuik JP. The surgical treatment of failures of laminectomy. *Spine: state of the art reviews* 1997; 11:509–38.
- Fritsch EW, Heisel J, Rupp S. The failed back surgery syndrome: reasons, intraoperative findings, and long-term results: a report of 182 operative treatments. *Spine* 1996;21:626–33.
- Barrick WT, Schofferman JA, Reynolds JB, Goldthwaite ND, McKeehen M, Keaney D, et al. Anterior lumbar fusion improves discogenic pain at levels of prior posterolateral fusion. *Spine* 2000;25:853–7.
- Herzog RJ, Marcotte PJ. Imaging corner. Assessment of spinal fusion. Critical evaluation of imaging techniques. *Spine* 1996;21:1114–8.
- Polatin PB, Kinney RK, Gatchel RJ, Lillo E, Mayer TG. Psychiatric illness and chronic low-back pain. The mind and the spine—which goes first? *Spine* 1993;18:66–71.
- McMahon MJ, Gatchel RJ, Polatin PB, Mayer TG. Early childhood abuse in chronic spinal disorder patients. A major barrier to treatment success. *Spine* 1997;22:2408–15.
- Schofferman J, Anderson D, Hines R, Smith G, White A. Childhood psychological trauma correlates with unsuccessful lumbar spine surgery. *Spine* 1992; 17(6 suppl):S138–44.